



Title	Radical anterior decompression and fusion for cervical spondylotic myelopathy
Author(s)	Fang, D; Yin, Q; Remedios, ID; Yu, YL
Citation	Journal of the Hong Kong Medical Association, 1994, v. 46 n. 3, p. 175-181
Issued Date	1994
URL	http://hdl.handle.net/10722/45122
Rights	Creative Commons: Attribution 3.0 Hong Kong License

Seminar on Orthopaedic Surgery

Radical anterior decompression and fusion for cervical spondylotic myelopathy

D. Fang, Q. Yin, I. D. Remedios and Y. L. Yu

Abstract

Sixty-seven patients with cervical spondylotic myelopathy were treated by radical anterior decompression and anterior spinal fusion. Of the 51 patients followed post-operatively for an average of 4.02 years, 34 obtained complete or partial relief, nine were unchanged and two deteriorated. Early complete anterior decompression and spinal fusion led to the most favourable results.

Keywords: Anterior interbody fusion; Cervical spondylotic myelopathy

Cervical spondylotic myelopathy (CSM) occurs relatively commonly during and after middle age¹ and is a serious consequence of cervical intervertebral disc degeneration. Spinal cord compression caused by cervical spondylosis with posteriorly protruding discs was first described by Bailey and Casamajor in 1911 and then by Stookey in 1928.² Since then the aetiology, pathogenesis, natural history, and clinical spectrum have been lucidly defined.¹⁻⁴ Although CSM is usually insidious in onset, its effects may be as devastating as traumatic spinal cord injury. Predisposing factors are age, an intrinsically narrow cervical spinal canal and acquired narrowing due to laminar, facet joint or ligamentous hypertrophy.

Since the introduction of anterior removal of cervical discs and interbody fusion for the treatment of cervical disc syndrome by Smith and Robinson in the 1950s,⁵ the anterior surgical approach has gained increasing popularity as a means of relieving cervical cord and nerve root compression.⁶⁻¹¹ In view of difficult posterior access, as well as post-laminectomy

kyphosis and instability,¹²⁻¹⁵ the anterior approach is now the treatment of choice when the number of disc levels is less than three. However, controversy still exists as to the best approach for multi-segmental spondylotic myelopathy.^{9,16}

Several factors may influence the surgical results. The clinical spectrum of CSM is variable and non-uniform. Symptoms may be insidious, progressive and unrelenting, or intermittent, step-like, and associated with multiple remissions. Other factors include age of the patient and severity of myelopathy. Cervical spondylosis and all its manifestations are often a product of cervical disc degeneration. Disc degeneration, on the one hand, implies a mechanical breakdown of the integrity of a cervical disc productive of symptoms initially because of mechanical instability. Disc protrusion or rupture, on the other hand, produces symptoms by means of tension or pressure on the cord, which is often acute in onset. The development of discovertebral osteophytes commonly follows degeneration in which the involved segment becomes 'unstable' and the movement of the related vertebrae becomes uneven. Ossification of the posterior longitudinal ligament (OPLL) is a relatively newly recognized entity in which a segmentally or continuously ossified ligament may cause spinal cord compression and myelopathy.

The three pathologies mentioned above, i.e. disc protrusion, discovertebral osteophytes and OPLL were lesions surgically treated in our series. The purposes of this retrospective study were: (1) to review the

The University of Hong Kong, Queen Mary Hospital, Pokfulam, Hong Kong

Department of Orthopaedic Surgery

D. Fang, MChOrth, FRCSE

Q. Yin, MD, PhD

I. D. Remedios, MS(Orth), FRCS

Department of Medicine

Y. L. Yu, MD, FRCP

Correspondence to: Dr D. Fang, Room 306 Tak Shing House, 20 Des Voeux Road, Central, Hong Kong

results of anterior decompression and spinal fusion for CSM in Chinese patients, (2) to investigate the factors contributing to favourable results, especially the significance of duration of symptoms and different cervical pathologies, and (3) to suggest an approach to multi-level involvement.

Subjects and methods

From 1959 to 1987, 67 patients with CSM with or without radiculopathy were treated by anterior decompression and spinal fusion (ASF) in the Department of Orthopaedic Surgery, University of Hong Kong at Queen Mary Hospital. Sixteen had inadequate follow-up; only 51 patients were included in this series. The follow-up ranged from one year to 18 years post-operatively averaging 4.02 years. There were 39 males and 12 females. Their ages ranged from 30 to 80 years and averaged 55.3 years. Thirty-seven patients undertook light work and 14 heavy manual work. The duration between the onset of myelopathy and presentation to the hospital ranged from three days to two years and averaged 11.2 months. Four of these had definite injury prior to the onset of symptoms, while the rest were insidious in

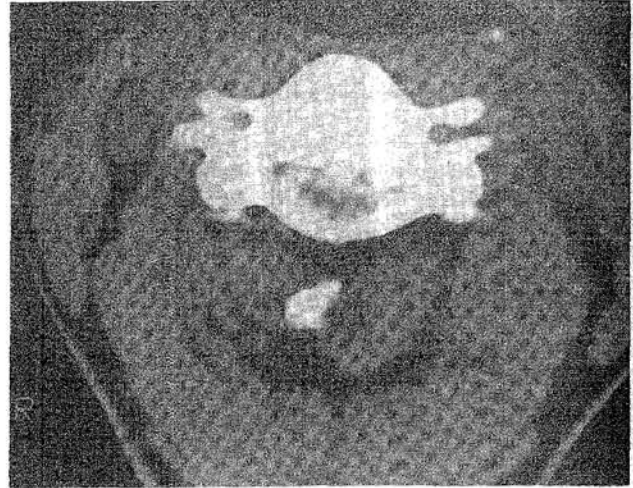


Fig. 1. CAM of 48-year-old man with CSM showing thecal compression by discovertebral osteophyte.

onset. The pre-operative status and post-operative progress of 36 patients were assessed using the Japanese Orthopaedic Association (JOA) score (Table 1), and 10-second hand tests were performed in 18 patients. Serial somatosensory evoked potentials (SEPs) were also performed in 25 cases.

Plain radiography and computer assisted myelography (CAM)¹⁷ (Fig. 1) or magnetic resonance imaging (MRI) (Fig. 2), as well as intra-operative findings showed disc protrusion with or without sequestration in 39 patients, osteophytic cord compression in 33 patients and OPLL in 10. Patients often had multiple pathologies compromising the cord. The number of disc levels involved in surgery were: single level in 18 patients, two levels in 21, three levels in 10 and four levels in two. The types of decompression performed (Table 2) were determined

Table 1. J.O.A score

	Scores
1. Motor upper limbs	
normal	4
chopstick not skilful	3
chopstick difficult	2
feed with spoon	1
unable to feed	0
2. Motor lower limbs	
normal	4
support not required	3
support on stairs	2
support on flat surface	1
locomotive inability	0
3. Sensory disturbances	
a. Upper limbs	
normal	2
mild disturbances	1
distinct disturbances	0
b. Lower limbs	
normal	2
mild disturbances	1
distinct disturbances	0
c. Trunk	
normal	2
mild disturbances	1
distinct disturbances	0
4. Bladder	
normal	3
mild (urgency)	2
severe (retention, incontinence)	1
anuria	0
Maximum total	17

Table 2. Types of surgery

Methods of operation	No.
Group 1: Discectomy (Excision of PLL) + ASF	32
Group 2: Partial spondylectomy + discectomy + osteophyctomy + ASF	16
Group 3: Partial spondylectomy + discectomy + removal of OPLL+ASF	5
Total	53*

PLL: Posterior longitudinal ligament

ASF: Anterior spinal fusion

OPLL: Ossification of posterior longitudinal ligament

Discectomy includes excision of posterior annulus and posterior longitudinal ligament.

Partial spondylectomy includes at least half of vertebral bodies above and below.

* two patients had repeated operations.

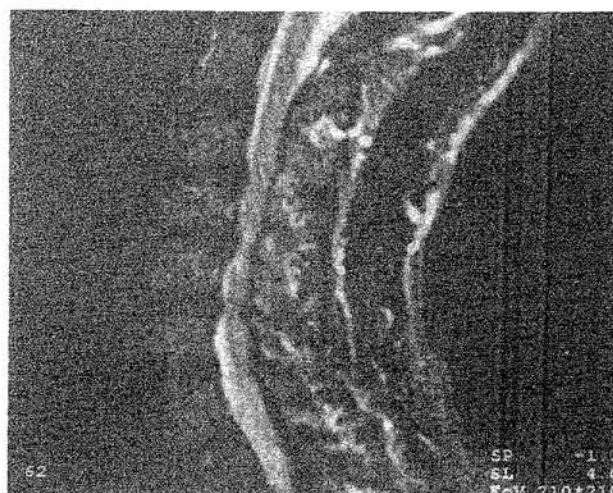by radiological and MRI findings and were divided into three groups.

Technique of operation

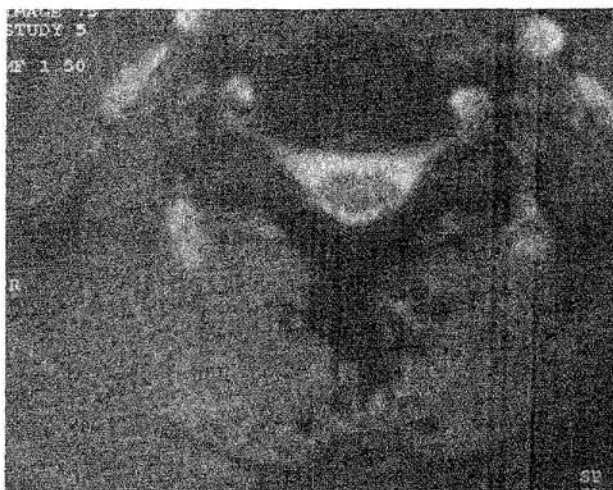The approach was that described by Smith and Robinson.⁵ The patient was placed in the supine position with the neck slightly extended. The direction of the skin incision depended on the number of vertebrae to be exposed. A transverse incision, which was more acceptable cosmetically, was sufficient for one or two disc levels. When more disc levels were involved, the incision was longitudinal along the anterior margin of the sternocleidomastoid.

The platysma muscle was incised in the direction of the wound and separated bluntly from the underlying structures. The sternocleidomastoid was retracted laterally and the middle layer of the cervical fascia was longitudinally divided to expose the omohyoid muscle which was usually divided. The middle thyroid vein must be divided to allow retraction and access. The carotid sheath was identified by palpation and gently retracted laterally with the sternocleidomastoid, and finally the oesophagus and trachea were retracted to the opposite side to expose the anterior aspect of the cervical spine.

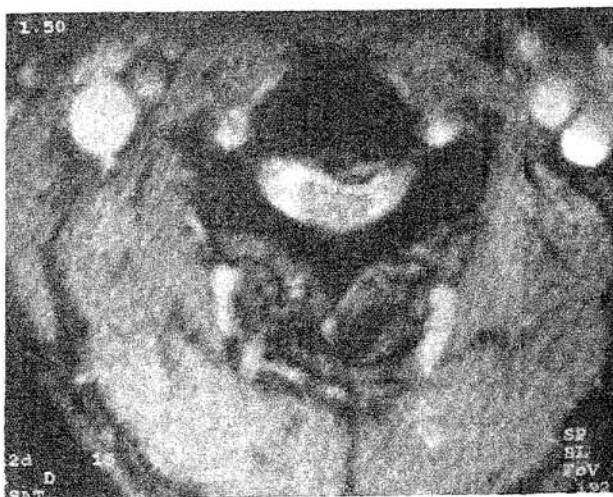The important structures encountered in this approach were the superior and inferior thyroid vessels, superior laryngeal nerve and cervical sympathetic chain. Special caution was needed to protect the recurrent laryngeal nerve on the right, and to a lesser extent the thoracic duct on the left. The longus colli muscles and anterior longitudinal ligament were elevated from the vertebral bodies to expose the disc at the predetermined level. A marker was introduced into the intervertebral disc and a lateral X-ray taken to check the level. The soft disc was incised and removed by pituitary rongeurs, and the cartilaginous plates were removed with curettes and burrs. Burring was preferred to osteotomes or chisels because of its haemostatic effect. A vertebral spreader was introduced to open the disc space allowing easy vision of the posterior discovertebral border. By meticulous burring the posterior lips of the vertebral body could be removed. A small hole was made through the posterior longitudinal ligament, and the ligament and any osteophytes were excised using Kerrison rongeurs until the anterior surface of the dura was clearly exposed. If the compressive lesions (either disc or osteophyte) went beyond the discovertebral margins, it was necessary to partially excise the upper and lower vertebral bodies for access. OPLL that was adherent to dura had to be left 'floating' by meticulous burring until it became paper thin. At the end of the decompression, the interspace was carefully measured in depth and width. A matching tri-cortical iliac autograft was obtained and inserted by tapping it into place and



A



B



C

Fig. 2. MRI of the same patient.
 A: Indentation of cervical cord at C3-4, C4-5, C5-6.
 B: Axial imaging (C4-5) showing disc protrusion and posterior osteophytosis.
 C: Normal axial imaging for comparison.

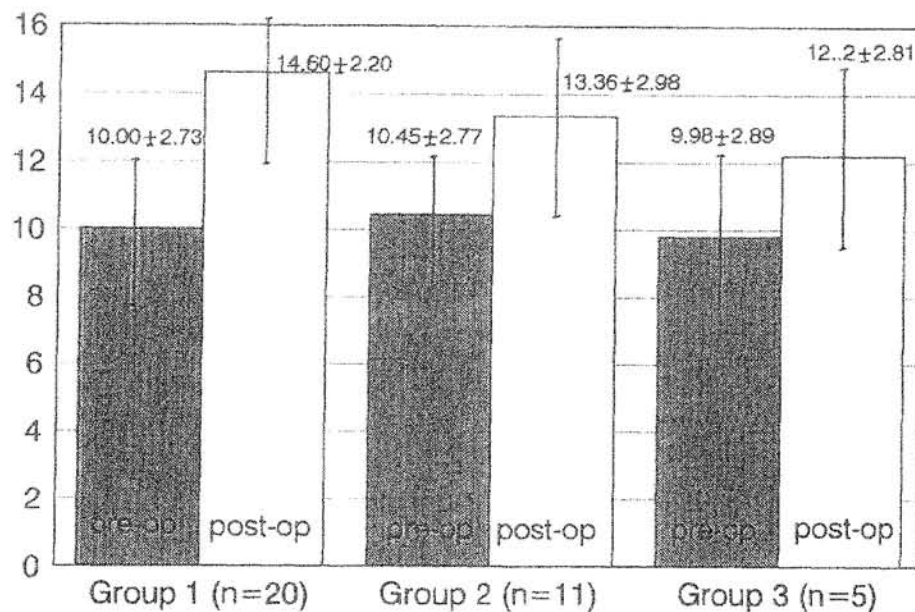


Fig. 3. Improvement in J.O.A. Scores

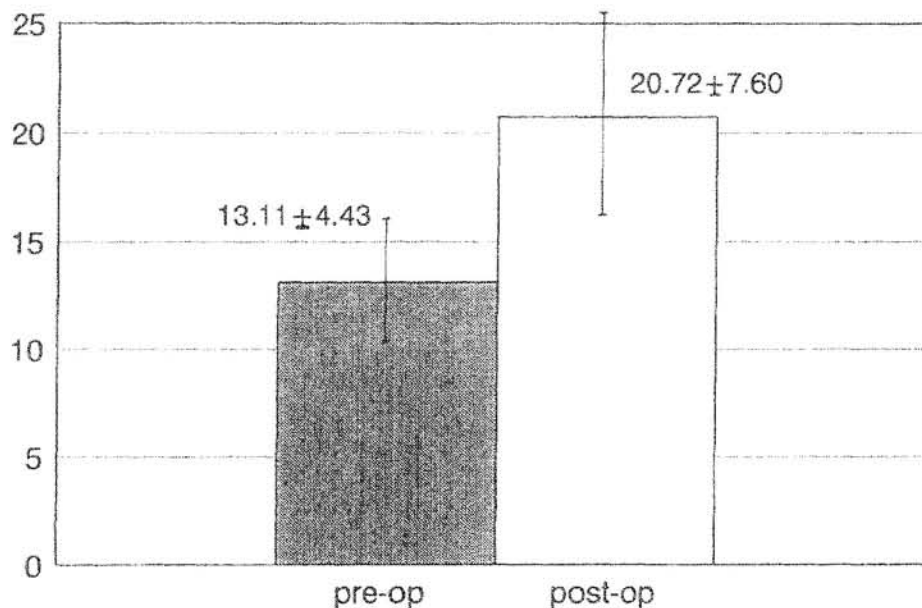


Fig. 4. Improvement in 10-second test

countersinking it while adequate longitudinal traction was applied to the head. Closure was in two layers with suction drainage. The patient was generally out of bed within 48 hours and treated in a soft cervical collar. A halo-vest was applied for six weeks where instability might result from extensive decompression and long grafts spanning three levels.

Results

Of the 51 patients, nine (18%) had complete recovery

after surgery; 25 (49%) had definite clinical improvement after surgery, both subjectively and objectively; five had only subjective improvement and one had only objective improvement (JOA score and 10-second test improved); nine patients had no change and two deteriorated post-operatively. Results of JOA scores of 36 patients in the three surgical groups are shown in Figure 3.

SEPs following median, ulnar and tibial nerves were recorded in 25 cases. The pre-operative findings correlated well with the clinical findings of CSM in 24 cases. In one case, the SEPs were within normal lim-

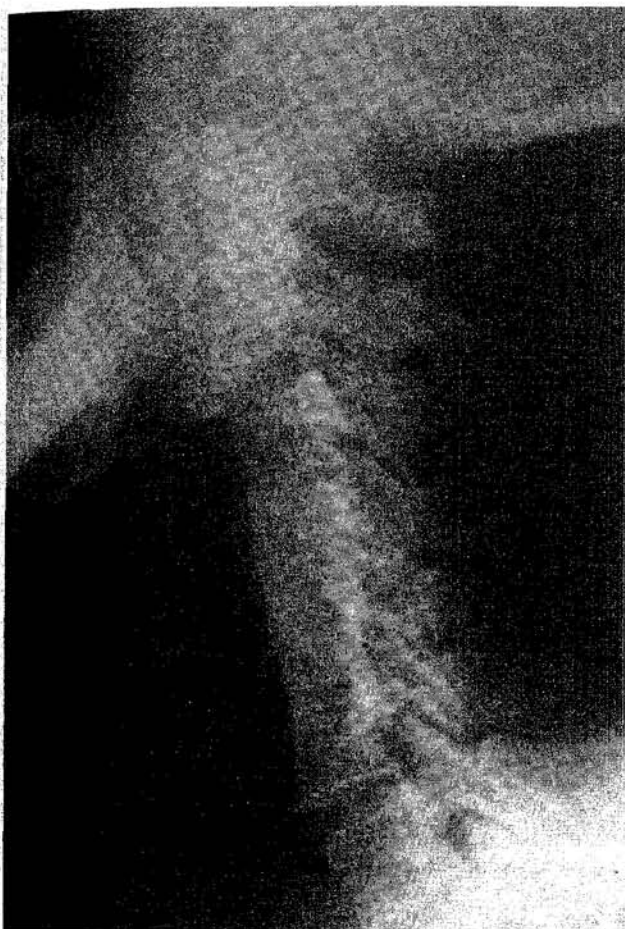


Fig. 5. Lateral X-ray of 61-year-old man with CSM showing solid fusion from C3 to C6 levels four years after surgery. The symptoms were completely relieved post-operatively.

its. SEPs were carried out in nine patients at follow-up. Five showed improvement in SEPs, but there was no correlation between the degree of clinical improvement by JOA score or 10-second test, and the improvement in the SEPs.

The 10-second test was done by asking the patient to grip and release the fingers as rapidly as possible with the arms forward and palms down. The number of complete cycles of movements within 10 seconds was counted. Normal adults can perform more than 20 complete cycles in 10 seconds. In 18 patients, the mean pre-operative value as a group was 13.11 times ($SD \pm 4.43$), and the post-operative value 20.72 times ($SD \pm 7.60$) (Fig. 4). On an individual basis, 16 patients had abnormal results pre-operatively, with 13 returning to normal post-operatively.

Radiological fusion (Fig. 5) took between six weeks to 16 months (average 8.44 months). This was confirmed by lateral flexion and extension films and in some cases also by computed tomography.

Complications occurred in nine patients: five had hoarseness of voice due to recurrent laryngeal nerve

injury, of whom four recovered completely within six months after surgery; one had a Horner's syndrome which recovered later; three had painless pseudoarthrosis. The complications related to anterior cervical decompression and fusion will be presented in detail in another paper.

Discussion

Although cervical laminectomy without fusion had been used to treat CSM, the long-term risks of post-laminectomy kyphosis and cervical instability are well documented.^{12-15, 18, 19} With recent advances in surgical technique and improved knowledge of CSM, anterior decompression and fusion has been widely used to treat CSM.^{5-10, 13, 14} In our series, 34 patients (68%) obtained satisfactory results, similar to previous reports.⁸⁻¹⁰

Considering the nine patients who made a complete recovery, the duration between the onset of myelopathy and presentation to the hospital varied between three days to four months with an average of 2.35 months. The remaining cases averaged 13.12 months, making a significant difference ($P < 0.01$). This indicates that early decompression is important for recovery possibly due to the restoration of reversible elements of the compressed spinal cord. Therefore we emphasize the importance of early surgical intervention if definite compressive myelopathy is shown and conservative methods fail.

Nine patients had no change in the clinical state after surgery. One of these had associated Parkinson's disease and another had a narrow cervical canal with multiple disc protrusions which were inadequately decompressed. In the third patient, there was persistent narrowing of the cord after adequate decompression as a result of spinal cord atrophy. Relief of extrinsic compression could not correct established changes. The others probably had irreversible changes of the spinal cord due to long-standing compression.

Deterioration in the post-surgical period occurred in two patients. In one of these, no cause could be determined. In the other case, there were four segmental levels of OPLL which could not be adequately decompressed. Laminoplasty was proposed, but the patient refused the surgery. For extensive OPLL or multiple level compressions, anterior decompression was usually inadequate and the complications were higher. We now routinely perform laminoplasty or the facet joint preserving type of laminectomy.

Late deterioration occurred in three patients between four years and 13 years after surgery. In one patient, no cause could be determined. In another two patients, deterioration was due to disc protrusions just above and below the previous fusion level. Anterior decompression and fusion was performed

Table 3. Improvement of JOA scores in different cervical pathologies after surgery

Group	Number of cases	X±SD	Group 1	Group 2	Group 3
1	20	4.90 ± 3.05		*	*
2	11	2.91 ± 2.79	*		
3	5	2.40 ± 1.51	*		

* Significantly different. (P<0.05)

Group 1: Simple disc protrusion (Operation: discectomy + ASF)

Group 2: Disc protrusion + posterior osteophytes (Operation: partial spondylectomy + discectomy + osteophytes + ASF)

Group 3: Disc protrusion + OPLL (Operation: Partial spondylectomy + discectomy + removal of OPLL)

at these levels in one patient who made a complete recovery post-operatively.

The pathology of cervical myelopathy can definitely influence the final results of CSM as shown in Table 3. It can be seen that simple disc protrusion without associated osteophytosis or OPLL produced the most favourable functional outcome.

The incidence of pseudoarthrosis after anterior cervical fusion has been reported to range from 0 to 37%.^{20, 21} It is more common when fusion spans multiple levels.^{19, 20} There were a total of three non-unions in our series. The rest showed solid union. The incidence of pseudoarthrosis increased when more levels were involved (Table 4). The three patients with painless pseudoarthrosis had a good clinical recovery and no evidence of instability. No further surgery was contemplated in view of the clinical improvement. We agree with White⁸ who found no significant difference in the distribution of good and excellent results in those patients with solid union compared to those without solid union. Therefore, provided no gross instability is produced, we feel that the crucial factor to good clinical results is early and adequate surgical decompression.

Conclusion

From this retro-spective review of 51 patients with

Table 4. The incidence of pseudoarthrosis

Levels	No. of cases	Incidence of pseudoarthrosis
1	18	0 (0%)
2	21	1 (5%)
3	10	1 (10%)
4	2	1 (50%)

CSM, we conclude that: (1) Anterior decompression and spinal fusion is a safe and effective form of treatment. 34 patients (67%) had excellent and good results in our series. (2) Early radical decompression led to the most favourable outcome. (3) Simple disc protrusion without associated osteophytosis or OPLL yielded the most satisfactory outcome. (4) If more than three disc levels are involved, we do not recommend the anterior approach and consideration should be given for a posterior approach such as laminectomy or laminoplasty.

References

1. Yu YL, Woo E, Huang CY. Cervical spondylotic myelopathy and radiculopathy. *Acta Neurol Scand* 1987; 75: 367-73.
2. Stookey B. Compression of spinal cord due to ventral extradural cervical chondromas. *Arch Neurol Psychiatry* 1928; 20: 275-91.
3. Nurick S. The pathogenesis of the spinal cord disorder associated with cervical spondylosis. *Brain* 1972; 95: 87-100.
4. Taylor AR. Vascular factors in the myelopathy associated with cervical spondylosis. *Neurology* 1964; 14: 62-8.
5. Smith GW, Robinson RA. The treatment of certain cervical spine disorders by anterior removal of the intervertebral disc and interbody fusion. *J. Bone and Joint Surg* 1958; 40A: 607-24.
6. Bohlman HH. Cervical spondylosis with moderate to severe myelopathy: a report of seventeen cases treated by Robinson anterior cervical discectomy and fusion. *Spine* 1977; 2: 151-62.
7. Fang D, Remedios ID, Leong JCY. Cervical spondylotic myelopathy. *J West Paci Orthop Assoc* 1990; 27: 17-8.
8. White AA, Southwick WO. Relief of pain by anterior cervical spine fusion for spondylosis. *J Bone and Joint Surg* 1973; 55A: 525-34.
9. Williams JL, Allen MB, Harkess JW. Late results of cervical discectomy and interbody fusion. *J Bone and Joint Surg* 1968; 50A: 277-86.
10. Yang KC, Lu XS. Cervical spondylotic myelopathy treated by anterior multiple decompression and fusion. *Clin. Orthop* 1987; 221: 161-4.
11. Crandall PH, Gregorius FK. Long term follow up of surgical treatment of cervical spondylotic myelopathy. *Spine* 1977; 2:139-46.
12. Callahan RA, Johnson RM, et al. Cervical facet fusion for control of instability following laminectomy. *J Bone and Joint Surg* 1977; 59A: 991-1002.
13. Cattell HS, Clark GL. Cervical kyphosis and instability following multiple laminectomies in children. *J Bone and Joint Surg* 1967; 49A: 713-20.
14. Shield CL Jr, Strauffer ES. Late instability in cervical spine fractures secondary to laminectomy. *Clin Ortho* 1976; 119: 141-7.
15. Zdeblick TA, Bohlman HH. Cervical kyphosis and myelopathy. *J Bone and Joint Surg* 1989; 71A: 170-82.
16. Itoh T, Tsuji H. Technical improvement and results of laminoplasty for compressive myelopathy in the cervical spine. *Spine* 1985; 10: 729-36.
17. Yu YL, du Boulay GH, Stevens JM, Kendall BE. Computer-assisted myelography in cervical spondylotic

- myelopathy: clinical correlations and pathogenetic mechanisms. *Brain* 1986; 109: 259-78.
18. Bailey RW, Badgley CE. Stabilization of the cervical spine by anterior fusion. *J Bone and Joint Surg* 1960; 42A: 565-94.
 19. Yonenobu K, Fuji T. Choice of surgical treatment for multisegmental cervical spondylotic myelopathy. *Spine* 1985; 10: 710-16.
 20. Farey ID, McAfee PC, Davis RF. Pseudoarthrosis of the cervical spine after anterior arthrodesis. *J Bone and Joint Surg* 1990; 72: 1171-7.
 21. Herkowitz HN. A comparison of anterior cervical fusion, cervical laminectomy, and cervical laminoplasty for the surgical management of multiple level spondylotic radiculopathy. *Spine* 1988; 13: 774-80.
 22. Yu YL, Jones SJ. Somatosensory evoked potentials in cervical spondylosis. *Brain* 1985; 108: 273-300.
 23. Fujiwara k, Yonenobu K, et al. The prognosis of surgery for cervical compression myelopathy. *J Bone and Joint Surg* 1989; 71B: 393-8.
 24. Wilson DH, Campbell DD. Anterior cervical discectomy without bone graft. Report of 71 cases. *J. Neurosurg* 1977; 47: 551-5.