



Title	ECG Round: Cardiac arrest
Author(s)	Chan, WK; Lau, CP
Citation	Hong Kong Practitioner, 1999, v. 21 n. 12, p. 587-588
Issued Date	1999
URL	http://hdl.handle.net/10722/45080
Rights	Creative Commons: Attribution 3.0 Hong Kong License

Cardiac arrest

W K Chan 陳偉光, C P Lau 劉柱柏

Clinical history:

This 42-year-old gentleman with good past health presented to the Emergency Department with cardiac arrest. Cardiac monitor showed ventricular fibrillation. He was resuscitated and a 12 lead ECG was obtained (**Figure 1**). His cardiac rhythm became stable later and another 12 lead ECG was obtained (**Figure 2**).

Figure 1

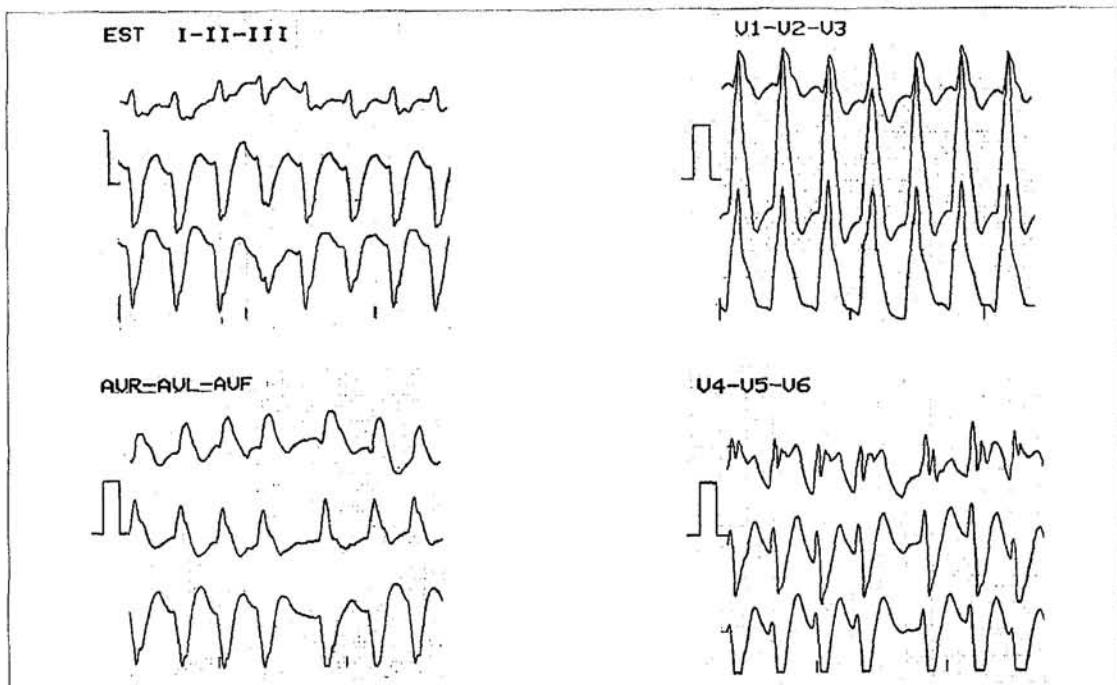
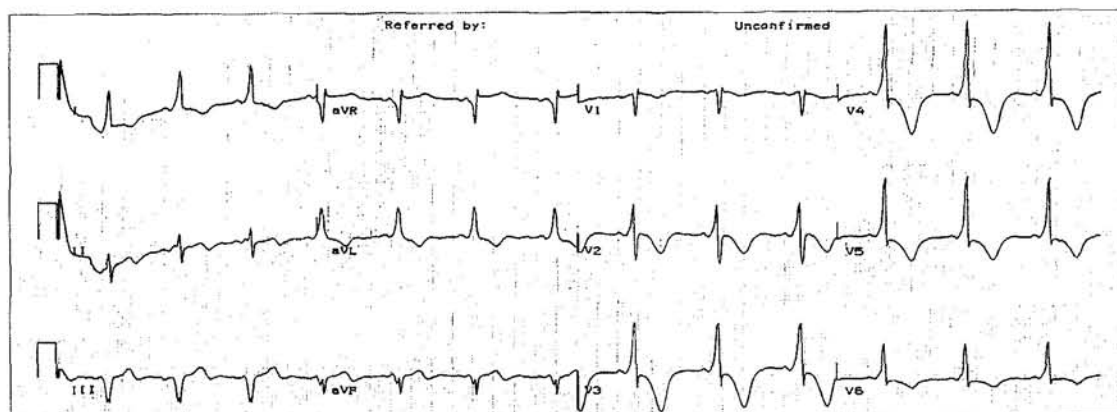


Figure 2



*See page 590
for the answers*

ECG Round

Question 1:

What was the cardiac rhythm shown in Figure 1?

- A. Sinus tachycardia
- B. Ventricular tachycardia
- C. Atrial fibrillation with aberrant conduction
- D. Preexcited atrial fibrillation (atrial fibrillation complicating Wolff-Parkinson-White Syndrome)

Question 2:

In view of the life-threatening nature of his arrhythmia, he underwent an interventional cardiological procedure under local anaesthesia. Figure 3 shows the ECG after that procedure. What was the procedure?

- A. Radiofrequency ablation of the accessory pathway
- B. Direct current ablation of the atrioventricular node

- C. Surgical division of the accessory pathway
- D. Coronary artery bypass grafting

Figure 3

