



Title	Corticosteroid injections for common soft tissue rheumatism
Author(s)	Lau, CS; Mok, MY
Citation	Hong Kong Practitioner, 1997, v. 19 n. 10, p. 535-545
Issued Date	1997
URL	http://hdl.handle.net/10722/45062
Rights	Creative Commons: Attribution 3.0 Hong Kong License

Corticosteroid Injections For Common Soft Tissue Rheumatism⁺

C S Lau,* MD(Honours), MRCP(UK), FHKAM(Medicine)

M Y Mok, MBBS, MRCP(UK)

Department of Medicine
The University of Hong Kong

Summary

Soft tissue injuries are probably the most commonly encountered rheumatic complaints and yet they are often overlooked. The diagnosis of most of these lesions relies on the physician's clinical acumen and a thorough understanding of the anatomy and function of the soft tissue involved is essential. A lot can be done to improve the patient's symptomatology once the diagnosis is made. Intralesional injection of corticosteroids is an effective form of treatment but care should be taken in the choice and dose of the steroid preparation used, the site of the injection and the monitoring of the patient's condition post-injection. In this article, the diagnosis and techniques of intralesional steroid injection of common soft tissue injuries are described. (HK Pract 1997;19:535-545)

摘要

軟組織損傷也許是風濕性疾病中最常見的現象，可是通常也容易被人疏忽。大部分這些損傷的診斷，需要依靠醫生敏銳的臨床洞察力和對軟組織的結構及功能從本質上的透徹了解。一旦確診了，就可以對症下藥以改善病人的症狀。局部注射皮質類固醇(Corticosteroids)是一種有效的治療方式，但要小心選擇適用的類固醇藥物及其劑量、注射位置，並監察病人注射後的身體反應。在這篇概要中，簡明地敘述了常見的軟組織損傷的診斷和局部注射類固醇的技術。

Introduction

Soft tissue injuries are commonly overlooked in the planning of the medical curriculum as well as that of the provision of health care. Yet single or multiple lesions of tendons and their sheaths, fasciae, bursae, joint capsules, and the enthesis (the tenoperiosteal junction) cause much morbidity and

loss of productivity. Together, they are probably the most abundantly encountered rheumatic complaints compared with any known arthropathies or connective tissue disorders. These lesions constitute a significant proportion of the workload of family physicians and hospital's accident, orthopaedic, and rheumatology departments.

Although the pathogenesis of soft tissue rheumatism syndromes is not fully understood, a large proportion of these conditions appear to be related to chronic low-grade trauma as a result of excessive and unaccustomed use both at work and at play. These factors may also cause partial interruption of the blood supply leading to incomplete attempts of healing and hence

+ Editor's Note

: This article is the third in a series of three articles on local steroid injection for rheumatic disorders.

* Address for correspondence

: Dr C S Lau, Associate Professor, Department of Medicine, The University of Hong Kong, Queen Mary Hospital, Pokfulam Road, Hong Kong.

CURRENT THERAPEUTICS

degeneration. Since the vascular supply to adult tendon is poor, healing of these lesions is slow. This is especially vulnerable in the middle-aged and the elderly in whom these lesions predominate. Soft tissue rheumatism syndromes may also be associated with systemic diseases, notably inflammatory arthropathies such as rheumatoid arthritis and ankylosing spondylitis; and diabetes mellitus as one of the clinical sequelae of a generalised vasculopathy associated with this condition.

Soft tissue rheumatism syndromes are clinically challenging as the diagnosis relies largely on the physician's clinical acumen as laboratory tests and radiological techniques are often unhelpful. Once the diagnosis is made, however, soft tissue rheumatism often responds to a range of treatments including selective rest of the involved region, use of oral and topical analgesics and anti-inflammatory drugs, physiotherapy, and intralesional infiltration of corticosteroid. Not all patients require corticosteroid injections. Indeed, most soft tissue rheumatism syndromes remit spontaneously and only few persist with significant symptoms beyond 6 months. Corticosteroid injections are usually only indicated if the patient has failed conservative treatment or the symptoms are so severe that daily activities are affected.

The choice of steroid has already been discussed in an earlier article. In general, long-acting preparations are appropriate but they should be used with caution for superficial lesions such as tennis

elbow because of potential skin atrophy as a complication. The use of gauge 23-25 needles and 1 ml syringes are recommended. After the injection, there may be an increase in symptoms for up to 48 hours and the patient should be warned of this possibility. This can be improved by prior or concomitant use of local anaesthetic (LA). Infiltrating the lesion with LA before steroid has the added advantage that it helps to confirm the diagnosis as the physical signs are often transiently reduced or abolished. The majority (>80%) of patients experience significant symptom improvement after one injection although others may require a repeat injection after 2-4 weeks. However, the same lesion should not be injected more than twice as it is unlikely then to be effective and the risk of side-effects is increased.

In this final article on the use of intralesional corticosteroid, the diagnosis and injection techniques of common soft tissue rheumatism syndromes are discussed (Table 1).

Common soft tissue rheumatism syndromes

I. Shoulder region

Soft tissue rheumatism is a frequent cause of shoulder pain. Common lesions include supraspinatus, infraspinatus, subscapularis and biceps tendinitis as well as subacromial bursitis. Clear diagnostic steps need to be taken to localise the lesion so as to lay the foundation for a successful injection. It is noteworthy that these lesions do not give

rise to passive limitation of glenohumeral movement. An articular condition or capsulitis (frozen shoulder) should be considered if pain is experienced during passive movement of the glenohumeral joint.

Supraspinatus, infraspinatus and subscapularis (rotator cuff) tendinitis

The supraspinatus, infraspinatus and subscapularis are part of the rotator cuff muscles (the fourth is the teres minor muscles) which are subjected to stresses when the arm is in the elevated position. The supraspinatus is most commonly affected by tendinitis while subscapularis tendinitis is an infrequent cause of shoulder pain. Presentation depends to a degree on the age of the patient and the likely aetiology. In young adults, rotator cuff tendinitis is commonly sports- or occupation-related and usually presents acutely after an activity such as throwing. The onset may be more gradual in the middle-aged who usually gives a history of recent repetitive or strenuous upper limb activity, and the elderly from whom often no history of a precipitating cause can be identified.

There is pain which is aggravated by movement into abduction on elevation. Patients often complain that they have difficulty reaching up behind their back when dressing. Pain may also occur at night especially when lying on the affected side and is usually felt in the deltoid region rather than the point of the shoulder. Physical examination shows a painful arc of

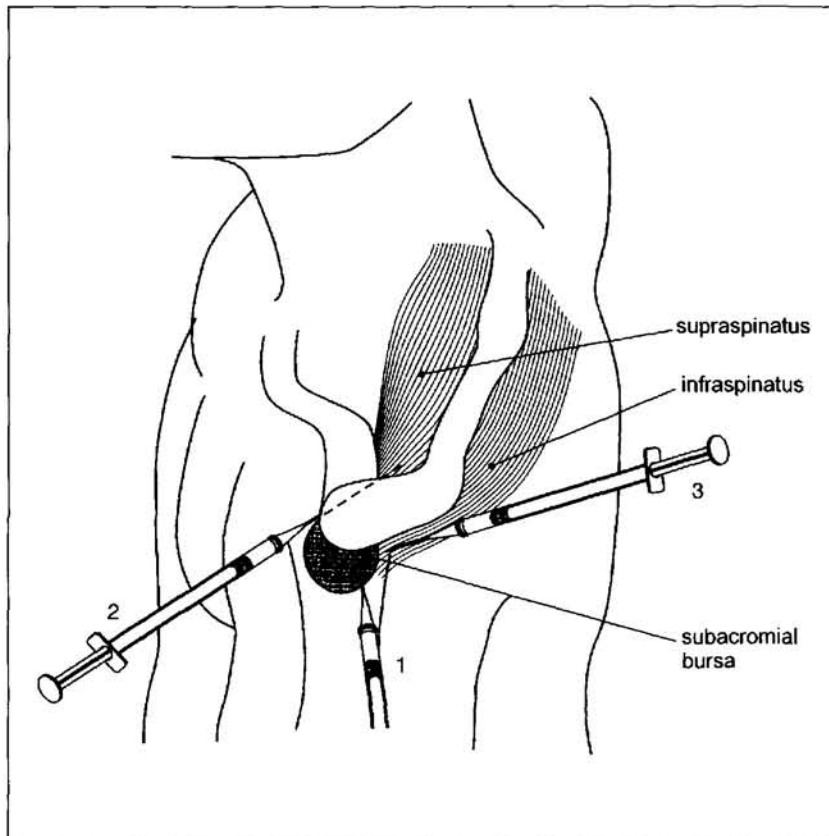
CURRENT THERAPEUTICS

Table 1: Clinical features and steroid injection site / dose of common soft tissue rheumatism syndromes

Soft tissue syndrome	Presenting feature(s)	Physical findings	Injection site and steroid dose (in mg methyl-prednisolone or equiv.)
Shoulder region			
Supraspinatus	Pain in deltoid region during shoulder abduction and at night when lying on the affected side	Normal passive shoulder movement. Painful arc (70 - 120°) during active abduction and a 'catch' of pain as the shoulder is lowered. Resisted shoulder abduction increases pain	Anterior edge of the acromion with the forearm resting on the thigh, or with the elbow bent at 90° and the forearm placed behind the back 20 - 40 mg
Infraspinatus	As for supraspinatus tendinitis	As for supraspinatus tendinitis but pain increase is elicited during resisted shoulder external rotation	Posterior to the acromial head with the patient sitting upright or lying face downwards, propped up on their elbows 20 - 40 mg
Biceps tendinitis	Often associated with rotator cuff tendinitis. Pain over the anterior aspect of the shoulder with radiation into the biceps muscle during overhead activities	Tenderness over the tendon as it runs in the bicipital groove	Along the biceps tendon (AVOID DIRECT INJECTION) 20 - 40 mg
Subacromial bursitis	Often associated with rotator cuff tendinitis with similar symptoms	Passive shoulder movement may be limited. Resisted abduction is painful from 45 - 90°. Passive rotation of the shoulder in the fully abducted position may be painful	Mid-point of the subacromion laterally. Aspirate any excess fluid 20 - 40 mg
Elbow region			
Lateral epicondylitis (Tennis elbow)	Pain over lateral epicondyle. Hand grip may be impaired	Lateral epicondyle tenderness. Worse by resisted wrist extension with the elbow extended	Over the lateral epicondyle 20 mg
Medial epicondylitis (Golfer's elbow)	Pain over medial epicondyle. Hand grip may be impaired	Medial epicondyle tenderness. Worse by resisted wrist flexion with the elbow extended	Over the medial epicondyle. KEEP INJECTION ANTERIOR TO AVOID ULNAR NERVE DAMAGE 20 mg
Wrist & hand region			
de Quervain's tenosynovitis (Diaper wrist)	Pain on using the thumb or wrist	Maximal tenderness in the anatomical 'snuff box'. Visible tender swelling over the radial styloid	Site of maximum tenderness. AVOID DIRECT INJECTION Avoid long acting steroid. Use corticosteroid 25 - 50 mg
Carpal tunnel syndrome	Pain and paraesthesia of the lateral 3 1/2 fingers. Worse in the morning and relieved by shaking the hand/forearm	Arm elevation or hyperflexion of the wrist produces pain and paraesthesia. Tinel's test may be positive. There may be thenar eminence wasting	Midpoint between the pisiform and scaphoid tubercle distal to the middle skin crease. Needle is directed at ~60° to the forearm. AVOID LA 20 - 40 mg
Stenosing digital tenosynovitis (Trigger fingers)	Triggering of the affected finger	Pain during resisted finger flexion and on stretching the tendon passively in extension. A tender nodule may also be felt	Over the involved tendon sheath. AVOID DIRECT INJECTION 12 - 20 mg
Foot and ankle region			
Achilles' tendinitis	Painful Achilles tendon during walking	Localised tenderness +/- nodular or diffuse swelling	INJECTION BEST AVOIDED
Plantar fasciitis	Pain on the undersurface of the heel on weight bearing. Worse after immobility	Localised tenderness, without swelling, over the anteromedial portion of the plantar surface of the calcaneum. Passive dorsiflexion of the toes worsens pain	From the side of the plantar fascia around the point of maximum tenderness. AVOID DIRECT INJECTION 20 - 40 mg

CURRENT THERAPEUTICS

Figure 1: Injection of subacromial bursitis (1) and supraspinatus (2) and infraspinatus tendinitis (3)



active abduction, usually occurring between 70 and 120°. As the shoulder is lowered, the patient may complain of a 'catch' of pain at mid-range due to impingement. Passive movement is usually full and pain free if there is adequate muscle relaxation.

It is possible to differentiate between tendinitis lesions of the supraspinatus, infraspinatus and subscapularis. Resisted abduction of the shoulder produces an increase in pain in patients with supraspinatus tendinitis. On the other hand, pain increase during resisted external rotation and internal rotation suggests the diagnosis of

infraspinatus tendinitis and subscapularis tendinitis respectively.

Injection of the supraspinatus tendon sheath can usually be achieved as shown in **Figure 1** with the forearm resting on the thigh, but if this is difficult, the elbow can be bent at a right angle, with the forearm placed behind the back. This fixes the arm in adduction and medial rotation, and the supraspinatus tendon is lying in the sagittal plane, emerging under the anterior edge of the acromion which is the site of injection. Following the use of a LA, a long acting steroid preparation, e.g. methylprednisolone 20-40 mg or equivalent, is infiltrated

along the line of the supraspinatus tendon at several points a few millimetres from each other, withdrawing and slightly changing the angle of the needle at each. For infraspinatus tendinitis, the patient can sit and the injection made posterior to the acromial head. Alternatively, the infraspinatus tendon can be rendered more prominent by the patient lying face downwards, propped up on their elbows.

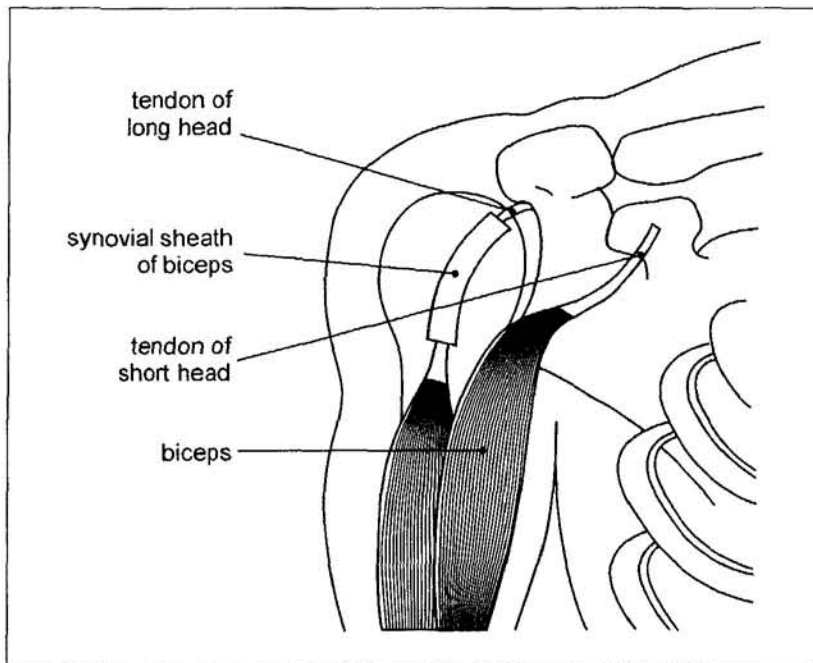
Biceps tendinitis

Biceps tendinitis is often associated with rotator cuff tendinitis or impingement. Primary involvement of the tendon is usually sports-related as in the case of weight-lifting where there is a repetitive stress placed upon the tendon, or after prolonged and repetitive carrying, e.g. of small children. Pain is usually felt over the anterior aspect of the shoulder with radiation into the biceps muscle during overhead activities and often with shoulder extension and elbow flexion. Physical examination may reveal well localised tenderness over the tendon as it runs in the bicipital groove (**Figure 2**), which is best felt with the patient's arm flexed and placed behind the back. Pain may be reproduced or exaggerated with resisted elbow flexion, supination and shoulder flexion.

Steroid, e.g. methylprednisolone 20-40 mg or equivalent, is infiltrated at several sites along the biceps tendon but care should be taken not to inject the tendon itself, which may result in rupture.

CURRENT THERAPEUTICS

Figure 2: The biceps tendon runs in the bicipital groove on the anterior aspect of the head of humerus



Subacromial bursitis

Most cases of subacromial bursitis co-exist with an underlying rotator cuff tendinitis and is a reactive phenomenon. Acute traumatic bursitis in the form of haemorrhage and oedema can occur as a result of a fall or a direct blow to the point of the shoulder. Passive glenohumeral movement may be slightly limited but not rigid or stiff. Resisted abduction is often painful from 45 to 90° and a painful arc may be present. Passive rotation of the shoulder in the fully abducted position may also be painful, although tendinitis, especially if severe, can also hurt with this test.

The subacromial bursitis is approached just below the mid-point of the acromion laterally (**Figure 1**). As the needle advances, a 'give way'

may be felt and it may be possible to aspirate fluid from the bursa which may in itself give symptom relief. The dose of steroid is 20-40 mg methylprednisolone or equivalent.

II. Elbow region

Several soft tissue problems can arise at the elbow but the commonest are lateral and medial epicondylitis. The lateral and medial epicondylar lesions may occur in the same elbow simultaneously or one or other of the problems in both elbows on the same or separate occasions, indicating the increased susceptibility of some people to this problem. Occasionally synovitis co-exists with an epicondylitis and it is important to observe that the elbow joint has a full active and passive pain-free range of movement.

Lateral epicondylitis (tennis elbow)

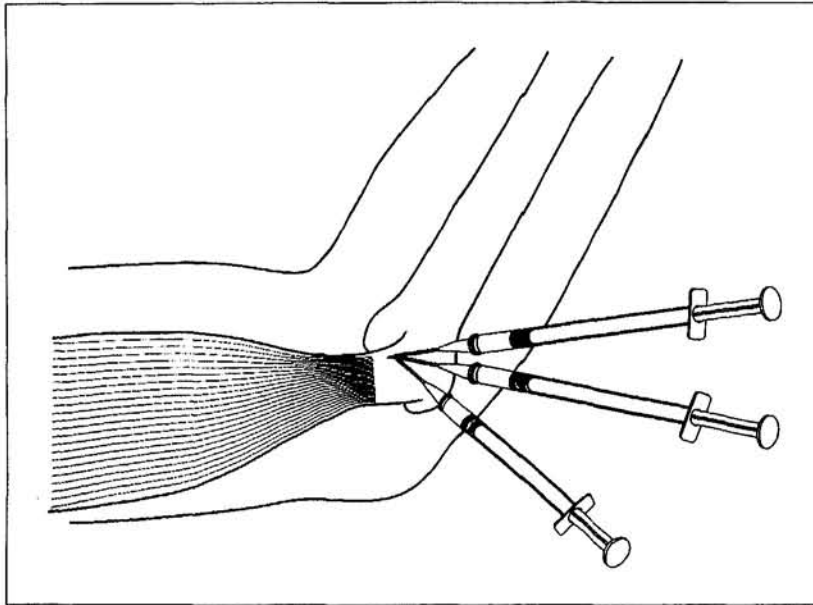
This condition is one of the most common lesions of the arm and around 1-3% of the population, mostly those aged between 40 and 60 years, are affected by it. Although the condition is also called tennis elbow and approximately 40-50% of tennis players (mainly older players) suffer with it, in clinical practice less than 5% of cases are due to the game. Indeed, most patients are not athletes or manual workers and do not recall any specific precipitating factors.

Lateral epicondylitis is usually slow in onset and pain is localised to the lateral epicondyle (which is in direct contrast to shoulder problems). Hand grip may be impaired due to pain and may result in restricted daily activities. Physical examination may reveal lateral epicondyle tenderness which can be made worse by resisted extension (dorsiflexion) of the wrist or the middle finger with the elbow extended. Resisted supination or extension of the elbow with the wrist flexed may also be painful.

During injection of the lateral epicondyle, the patient's arm is best held by the operator in the manner shown in **Figure 3**. The thumb of the non-operating hand should be used to stretch the skin over the epicondyle so that one can more accurately direct the injection. During the injection, the needle is directed on to the entheses and moved around to infiltrate with a few drops of steroid, e.g. methylprednisolone 20 mg or equivalent, at several sites within the area of tenderness on

CURRENT THERAPEUTICS

Figure 3: Injection of lateral epicondylitis. The needle is moved around to infiltrate with a few drops of steroid at several sites



the epicondyle, partially withdrawing and repositioning the needle at each one. After the injection, the patient should be advised to avoid using the arm unduly for at least 48 hours. They should be advised to resume normal activities gradually over the next week or so, except those which they know are liable to bring on the pain.

Medial epicondylitis (golfer's elbow)

This condition can be tested for in the same way at the points of significant enthesopathy, using resisted flexion of the wrist with the elbow fully extended as an additional guide. The injection technique and steroid dose are similar to those for lateral epicondylitis. Throughout the procedure, the cone of tissue to be injected is kept strictly anterior where in fact the lesion is, thus

avoiding any possibility of damaging the ulnar nerve.

III. Wrist and hand region

The hand is the major sensory organ of touch and is uniquely adapted for grasping. It is therefore prone to repeated minor trauma. Additionally, seropositive and seronegative arthritis have a predilection for inflammatory involvement of the synovial structures of the tendons and joints in this region. Tenosynovitis denotes an inflammation of the synovial lining of the tendon sheath, usually accompanied by inflammation of the contained tendon. The clinical manifestations are pain, tenderness, and swelling, with "crepitus" that is palpable when the tendon moves within the inflamed sheath.

de Quervain's tenosynovitis (Diaper wrist)

This is a stenosing tenosynovitis of the abductor pollicis longus and extensor pollicis brevis and typically represents an occupation or vocation-related repetitive strain injury due to chronic overuse of the wrist and hand. Indeed, de Quervain's tenosynovitis has long been reported in assembly-line workers involved in repetitive grasping movements of finger and thumb, and with rapid pronation-supination movements of the forearm. Additionally, de Quervain's tenosynovitis may also occur in association with rheumatoid arthritis, psoriatic arthritis, other inflammatory arthropathies, direct trauma, pregnancy and during the postpartum period.

There is pain on using the thumb or wrist. Tenderness is maximal in the anatomical 'snuff box' area between the tendons and there is often a visible, tender swelling about the radial styloid. Pain can also be induced by forced ulnar deviation after placing the patient's thumb in the palm.

Treatment consists of local heat therapy, anti-inflammatory drugs and selective rest of the tendon are usually effective in alleviating symptoms. However, in patients with more severe or persistent pain, one or more local corticosteroid injections can be helpful. The technique for injection is relatively simple and corticosteroid, e.g. hydrocortisone 25-50 mg, is infiltrated around the site of maximum tenderness (Figure 4). It

(Continued on page 543)

CURRENT THERAPEUTICS

is important to avoid direct injection into the tendon.

Carpal tunnel syndrome

The classical symptoms of carpal tunnel syndrome are usually easily recognised, with the numbness, tingling, burning or pain being more pronounced in the morning, often waking the patient early or during the night. These symptoms may be relieved by shaking the hand/arm. Motor dysfunction may occur early but thenar wasting usually much later. The syndrome may be secondary to other lesions within or around the wrist joint, for example, a ganglion, synovitis at the wrist, flexor tenosynovitis or any arm problem which reduces mobility in someone with a predisposition to carpal tunnel syndrome.

Several tests are used to assess the possible presence of the syndrome. Arm elevation may quickly bring on symptoms as can hyperflexion of the wrist, especially if the fingers are exercised at the same time. Tapping with the index finger over the carpal tunnel will often bring on or heighten the paraesthesiae (Tinel's sign). Since these tests are not always positive, nerve conduction studies may be required for confirmation of the diagnosis.

An injection is made at the midpoint between the pisiform (ulnar) and scaphoid tubercle (radial) distal to the middle skin crease. The needle is directed distally at $\sim 60^\circ$ to the forearm (**Figure 5**). Normally,

no LA is needed as it may mask the warning symptoms caused by injection of the median nerve by mistake. Occasionally, even when the correct techniques are followed, paraesthesiae or other symptoms in the fingers are evoked and if so, the injection should either be stopped or the angle of the needle changed slightly, withdrawing it a millimetre or so, and few drops of the solution injected. If these again evoke symptoms and anxiety on the part of the patient, the injection should be either abandoned for that day or the needle withdrawn and reinserted slightly to the ulnar aspect of the chosen site. Between half to 1 ml of steroid (equivalent to 20–40 mg methylprednisolone) can be used, depending on the patient's build. The patient should continue to wear

the wrist splint at night, or, if convenient, in the evenings as well, and during any task which exacerbates the symptoms.

Stenosing digital tenosynovitis (trigger finger or thumb)

This is the most common repetitive strain injury of the hand. Tenosynovitis of the flexor tendons of the finger or thumb results in pain over the area of the pulley and snapping or triggering movement of the finger or thumb. Pain along the course of the sheath with resisted flexion, and pain on stretching the tendon passively in extension, are common. Intermittent locking of the digit in flexion may also develop, particularly upon arising in the

Figure 4: Injection of de Quervain's tenosynovitis

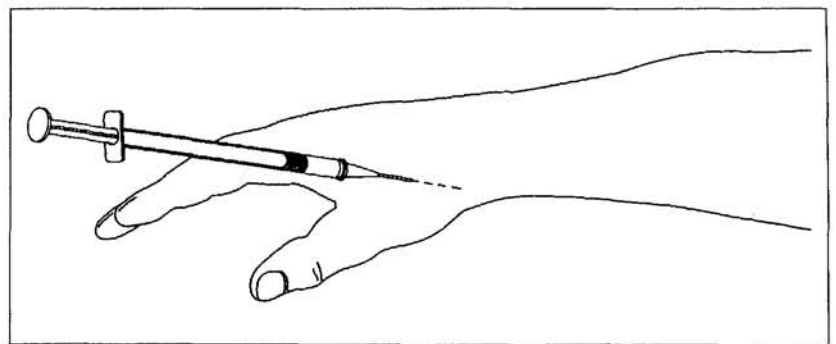
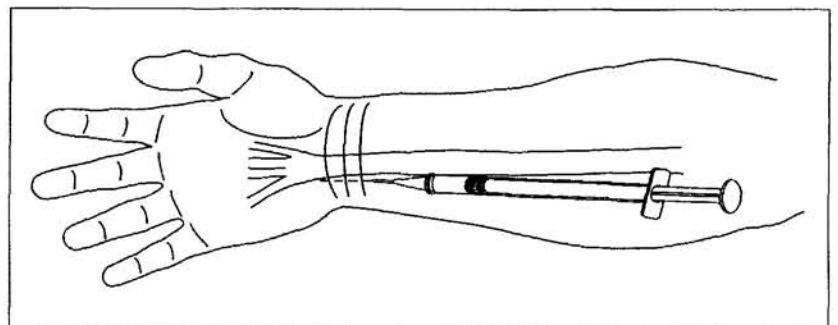


Figure 5: Injection of the carpal tunnel. The needle is directed distally at $\sim 60^\circ$ to the forearm



CURRENT THERAPEUTICS

morning. Passive extension of the proximal interphalangeal joint of the finger or interphalangeal joint of the thumb may produce a crepitus and a popping sensation as the digit is straightened. Examination reveals tenderness over the area of the proximal pulley often associated with tenderness and swelling of the flexor tendon sheath, and limitation of digital flexion and extension. A nodule can often be palpated in the palm just proximal to the metacarpophalangeal joint as it moves during finger or thumb flexion and extension.

The needle (gauge 25) is inserted through the skin (which can be rather sore in the palm), putting LA ahead of the needle as one pushes it down on to the tendon itself. On reaching the tendon, the flow of LA will be halted but will be resumed if the needle is withdrawn 1 mm or so and the same pressure maintained. This is the position for injecting the steroid into the tendon sheath. In most cases 0.3 ml (equivalent to 12 mg methylprednisolone) is all that is necessary, but thickened larger tendons may require 0.5 ml (equivalent to 20 mg methylprednisolone). There should be no feeling of significant resistance during injection.

Ankle and foot region

Soft tissue rheumatism lesions in this region may occur singly unaccompanied by other rheumatic conditions but it is important to be aware of the possibility of synovitis in the ankle and forefoot which can give rise to considerable pain and

stiffness. Therefore, any soft tissue lesion about the ankle must be accompanied by clinical assessment of the ankle, hind-foot including subtalar joint, and tarsal joints. Similarly, biochemical factors such as hyperlipidaemia and hyperuricaemia may affect the persistence of fasciitis. In the latter cases the lesion is more likely to be bilateral.

Achilles tendinitis

Achilles tendinitis can give rise to inflammation at several points, on the entheses, along the tendon and at the muscle-tendon junction. It may appear diffusely swollen or nodular, superficially in the sero-negative or rheumatoid arthropathies respectively. Enthesopathy on the posterior aspect of the heel, as well as plantar fasciitis, may occur in Reiter's syndrome and other reactive

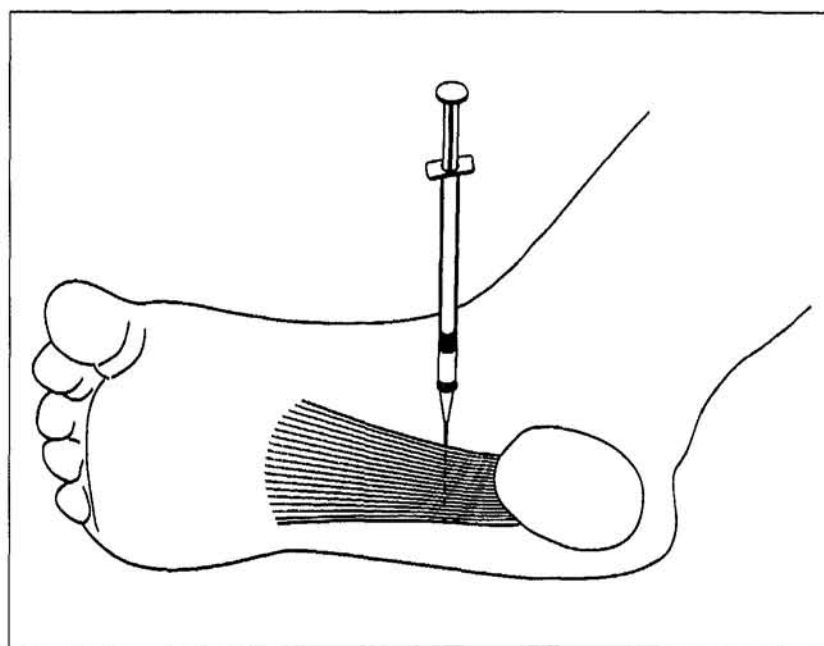
arthritides where erosive changes may also occur on a calcaneal spur.

Injection of the Achilles tendon is best avoided in case steroid induced atrophy of the tendon causes rupture.

Plantar fasciitis

This is the most common cause of heel pain and is usually quite easy to diagnose. Pain on the under-surface of the heel on weight bearing is the principal complaint. It may also be worse after immobility or until the ligaments have been stretched out e.g. on walking, but even then it may still be painful at the heel entheses, or less commonly, at other more distal sites. Examination may reveal localised tenderness, without swelling, over the anteromedial portion of the

Figure 6: Injection of plantar fasciitis



CURRENT THERAPEUTICS

plantar surface of the calcaneum. Passive dorsiflexion of the toes often accentuates the discomfort.

For this condition, the injection is best carried out from the side (Figure 6) since this is much less painful than going through the sole, although the latter method may still be used in some resistant cases. The

solution (20-40 mg methylprednisolone or equivalent) should be slowly injected.

Conclusion

In summary, soft tissue injuries are common rheumatic complaints. Patients often present with character-

istic signs and symptoms. There are many treatment options once the diagnosis is made. Local infiltration of steroid is indicated for patients with severe symptoms, and those who have failed less invasive therapy. Properly administered, this form of treatment may give long lasting symptom relief with few complications. ■



THE HONG KONG COLLEGE OF FAMILY PHYSICIANS

MEMBERSHIP APPLICATION

NAME : _____ ADDRESS : _____

TEL NO. : _____

FAX NO. : _____

PROFESSION : FAMILY PHYSICIAN (Please tick ✓)

SPECIALIST

(FIELD)

STUDENT

OTHER

(.....)

I wish to become a member of the HKCFP, please forward application form.

Please forward information regarding membership of the HKCFP.

Please return completed form to : *Hong Kong College of Family Physicians,
8th Floor, Duke of Windsor Social Service Building,
15 Hennessy Road, Wanchai, Hong Kong.
FAX: 2866 0616 or TEL: 2528 6618 for further information*