



Title	Liver transplantation for hepatocellular carcinoma
Author(s)	Lau, H; Lo, CM; Lai, CL; Fan, ST
Citation	Hong Kong Medical Journal, 1996, v. 2 n. 4, p. 322-324
Issued Date	1996
URL	http://hdl.handle.net/10722/45044
Rights	Creative Commons: Attribution 3.0 Hong Kong License

Liver transplantation for hepatocellular carcinoma

H Lau, CM Lo, CL Lai, ST Fan

Hepatocellular carcinoma is the third most common cancer in Hong Kong. Up to 80% of patients have inoperable tumour at presentation, either because of underlying cirrhosis or the advanced stage of the disease. This paper describes a case of orthotopic liver transplantation for hepatocellular carcinoma. Prognostic factors for survival and selection criteria for liver transplantation are discussed. The early referral of selected patients with hepatocellular carcinoma to a transplant centre can offer a hope of cure. The best candidate for transplantation is a young patient with an asymptomatic small tumour in a cirrhotic liver.

HKMJ 1996;2: 425-7

Key words: Liver neoplasms; Transplantation, hepatic; Carcinoma, hepatocellular

Introduction

With the current practice of screening cirrhotic patients by ultrasonography and measuring serum α -fetoprotein levels, an increasing number of subclinical hepatocellular carcinoma (HCC) cases have been diagnosed. Approximately 76% of patients with subclinical HCC are amenable to resection while the remainder are inoperable as a result of advanced cirrhosis.¹ For those who have inadequate hepatic functional reserve for resection, liver transplantation is the only curative treatment option. The role, however, of liver transplantation in the treatment of HCC is still controversial. We report a case of orthotopic liver transplantation (OLT) for HCC and review the indications and implications of this treatment modality.

Case report

A 45-year-old Chinese woman developed hyperbilirubinaemia, ascites, and deteriorating liver function

in April 1994. Hepatitis B surface antigen and core antibody were negative. A liver biopsy demonstrated chronic active hepatitis with features compatible with primary biliary cirrhosis. She was evaluated and accepted for liver transplantation at the Queen Mary Hospital, Hong Kong. She had regular follow up appointments at our transplant clinic and her ascites was controlled by diuretic therapy. Her serum α -fetoprotein level was regularly monitored and ultrasonography of the liver was repeated every three months. In April 1995, her serum α -fetoprotein level began to rise, reaching a peak of 982 ng/mL in June 1995. Ultrasonography of the liver showed a hyperechoic lesion that measured 2 cm in diameter in segment VII. Although a hepatic arteriogram did not reveal any definite tumour staining or neo-vascularisation, a post-lipiodol CT scan showed intense enhancement of the nodule at segment VII, suggestive of HCC (Fig 1). Because of the advanced cirrhosis, a hepatic resection was deemed impossible.

While waiting for liver transplantation, she received transarterial oily chemotherapy that consisted of a mixture of lipiodol and cisplatin on the 10th July 1995. Two days later, a cadaveric liver graft was available and an OLT was performed. University of Wisconsin solution was used as the preservation solution for organ harvesting. Recipient hepatectomy was performed with preservation of the inferior vena cava and veno-venous bypass

The University of Hong Kong, Queen Mary Hospital, Pokfulam, Hong Kong:

Division of Hepatobiliary Surgery, Department of Surgery

H Lau, MB, BS, FRCS (Edin)

CM Lo, MB, BS, FHKAM (Surgery)

ST Fan, MS, FHKAM (Surgery)

Department of Medicine

CL Lai, MD, FHKAM (Medicine)

Correspondence to: Dr CM Lo

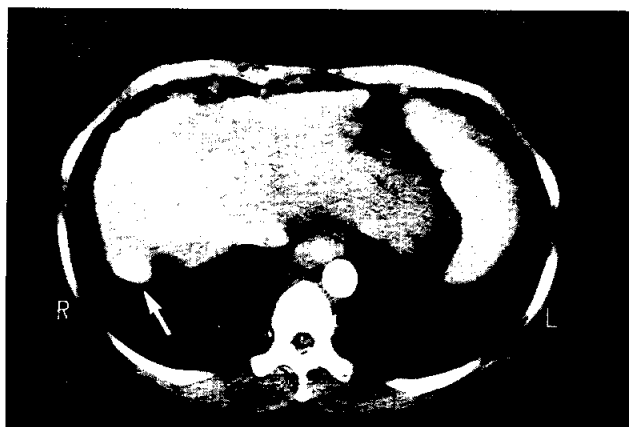

Fig 1. Post-lipoidal computed tomography scan of liver shows a nodule measuring 3 x 2 cm with intense enhancement at Segment VII (arrow)

was not used. The graft was implanted using the piggy-back technique and the cold ischaemic time was 7 hours 45 minutes. Histopathological examination confirmed the presence of a moderately differentiated HCC of TNM stage II. A triple-drug regimen of induction and maintenance immunosuppressive therapy, consisting of steroid, cyclosporine A, and azathioprine was used. She recovered quickly and was discharged from hospital on day 14 after the operation. Adjuvant systemic chemotherapy was not used. At 11 months after OLT, she was well with a normal serum α -fetoprotein level and liver biochemistry (Fig 2). Computed tomography of the abdomen has not revealed any evidence of recurrence.

Discussion

Recent advances in surgical technique and immunosuppression have greatly improved the outcome of liver transplantation. For benign liver diseases, a five-year survival rate of 80% after OLT can be achieved. Liver transplantation was initially believed to be a suitable therapeutic option for patients with advanced HCC without evidence of metastasis. However, early results from OLT for HCC were disappointing because tumour usually recurred one or two years after transplantation.² Even though extrahepatic spread has been excluded by bone scan and CT scan of the thorax and abdomen, micrometastases might have been missed and their growth is accelerated as a result of the post-operative immunosuppressive therapy.³ For this reason, many transplant centres conducted studies to identify unfavourable factors to help exclude certain patients from transplantation. Yokoyama et al⁴ identify the most significant adverse factor as macroscopic vascular invasion by tumour. Other poor prognostic indicators include tumour size greater than 5 cm, bilobar tumour involvement, lymph node metastases, infiltrative tumour, advanced TNM stage of tumour, and positive resection margin in the explanted liver.^{4,5} Better results were obtained in patients with early stage HCC. Three-year survival rates of 83% in France and 90% in Spain have been reported.^{5,6} Liver transplantation therefore gives worthwhile survival in selected HCC patients and the chance of a cure.

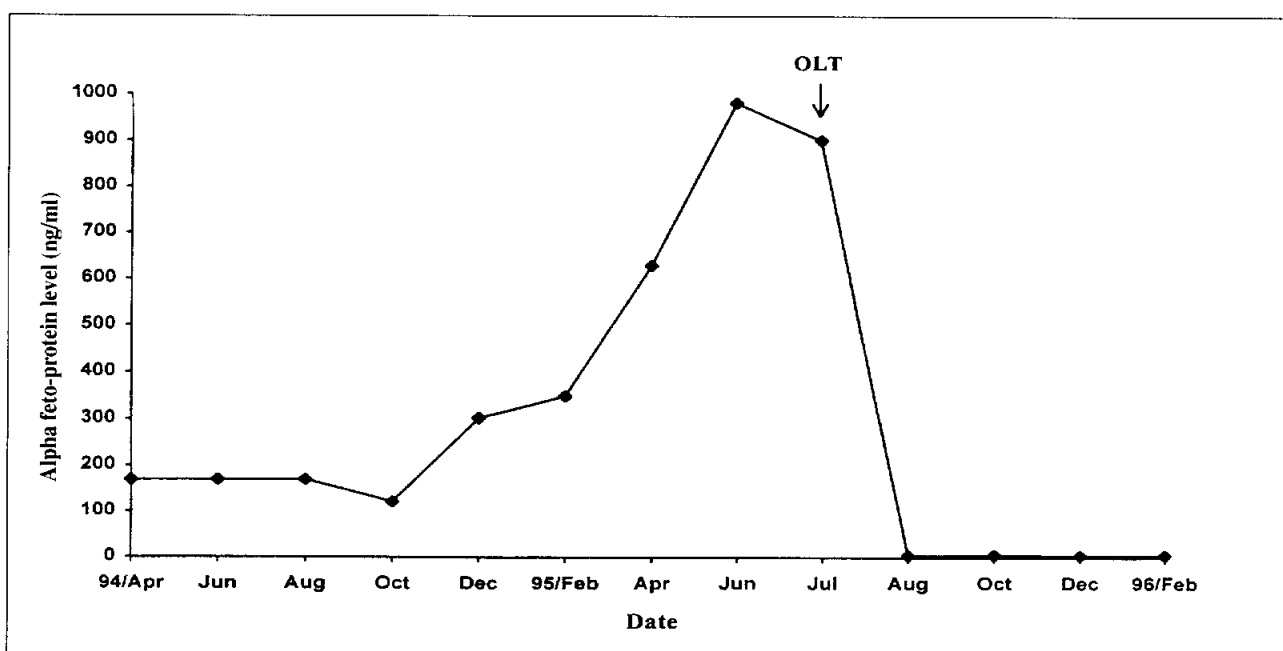


Fig 2. Trend of serum α -fetoprotein level before and after liver transplantation

Attempts have been made to reduce recurrence and improve survival by giving peri-operative adjuvant chemotherapy, either by systemic or regional administration. Spreafico et al⁷ evaluated the efficiency of transarterial oily chemo-embolisation of HCC in 33 patients who subsequently underwent liver transplantation. Tumour necrosis exceeding 90% of the tumour volume was detected in 12 patients. Carr et al⁸ demonstrated a significantly better survival rate in patients receiving OLT with pre-operative transarterial chemotherapy and post-operative systemic chemotherapy than those without chemotherapy. However, whether this combination treatment is of benefit to patients remains to be established.

From October 1991 to February 1996, 32 liver transplantations were carried out at Queen Mary Hospital and the one-year patient survival rate was 90%. The main difficulty of liver transplantation in Hong Kong is the shortage of liver grafts, because of religious and cultural traditions among the Chinese. Justification for performing OLT for malignancy must be balanced against the demand for organs for other benign indications and the high cost of the operation and post-operative immunosuppressive therapy. It should be noted, however, that long term survival has been observed in some cases. In Starzl's series,⁹ one patient with HCC was still alive 17 years after OLT. It is therefore unethical to deny treatment to patients with malignancy that is still potentially curable. Selected pa-

tients with small HCC associated with severe cirrhosis are suitable candidates for OLT.

References

1. Lai CL, Lau JY, Wu PC, et al. Subclinical hepatocellular carcinoma in Hong Kong Chinese. *Oncology* 1992;49:347-53.
2. Pichlmayr R, Brotsch C, Wonigeit K, et al. Experiences with liver transplantation in Hannover. *Hepatology* 1984;4:56S-60S.
3. Yokoyama I, Carr B, Saito H, Iwatsuki S, Starzl TE. Accelerated growth rate of recurrent hepatocellular carcinoma after liver transplantation. *Cancer* 1991;68:2095-100.
4. Yokoyama I, Sheahan DG, Carr B, et al. Clinicopathologic factors affecting patient survival and tumour recurrence after orthotopic liver transplantation for hepatocellular carcinoma. *Transplant Proc* 1991;23:2194-6.
5. Bismuth H, Chiche L, Adam R, Castaing D, Diamond T, Dennison A. Liver resection versus transplantation for hepatocellular carcinoma in cirrhotic patients. *Ann Surg* 1993;218:145-51.
6. Moreno P, Jaurrieta E, Figueras J, et al. Orthotopic liver transplantation: treatment of choice in cirrhotic patients with hepatocellular carcinoma. *Transplant Proc* 1995;27:2296-8.
7. Spreafico C, Marchiano A, Regalia E, et al. Chemo-embolization of hepatocellular carcinoma in patients who undergo liver transplantation. *Radiology* 1994;192:687-90.
8. Carr BI, Selby R, Madariaga J, Iwatsuki S, Starzl TE. Prolonged survival after liver transplantation and cancer chemotherapy for advanced-stage hepatocellular carcinoma. *Transplant Proc* 1993;25:1128-9.
9. Starzl TE, Todo S, Tzakis AG, et al. Liver transplantation: an unfinished product. *Transplant Proc* 1989;21:2197-200.