



Title	Advances in imaging of the solitary pulmonary nodule
Author(s)	Ooi, GC; Khong, PL; Yau, YY
Citation	Hong Kong Medical Journal, 2004, v. 10 n. 2, p. 107-116
Issued Date	2004
URL	http://hdl.handle.net/10722/44683
Rights	Creative Commons: Attribution 3.0 Hong Kong License

GC Ooi
PL Khong 孔碧蘭
YY Yau 游逸燕

Advances in imaging of the solitary pulmonary nodule

孤立肺小瘤影像術的發展

Objective. To review the radiological management of a solitary pulmonary nodule.

Data sources. MEDLINE literature search (1958-2002).

Study selection. All review articles and original articles. Key words for the literature search were 'solitary pulmonary nodule' and 'imaging'.

Data extraction. All relevant information and data.

Data synthesis. The solitary pulmonary nodule remains a perennial problem in radiological practice, particularly with current trends using low-dose computed tomography to screen for lung cancer. Determining the likelihood of malignancy forms the basis of the radiological approach of a solitary pulmonary nodule. Several factors that influence risk analysis include morphological and enhancement characteristics of the solitary pulmonary nodule on imaging, stability of the nodule, age of patient, smoking history, and history of malignant disease. Other ancillary procedures and imaging techniques that assist in the evaluation of a solitary pulmonary nodule include fluorodeoxyglucose positron-emission tomography, technetium Tc 99m depreotide imaging, bronchoscopy with bronchioloalveolar lavage and biopsy, image-guided transthoracic needle aspiration biopsy, video-assisted thoroscopic surgery, and thoracotomy.

Conclusions. The success of any radiological management of a solitary pulmonary nodule rests on careful clinical evaluation and risk stratification for malignancy before the implementation of appropriate imaging techniques.

目的：回顧有關孤立肺小瘤放射學的处理。

資料來源：Medline 文獻檢索 (1958 年至 2002 年)。

研究選取：所有綜述文獻及論著。文獻檢索的關鍵詞包括「孤立肺小瘤」、及「影像術」。

資料選取：回顧有關的資料及數據。

資料綜合：放射學研究範圍內，孤立肺小瘤至今仍是一個難題，尤其是現今有了利用低劑量的電腦斷層掃描來檢測肺癌的方法。使用放射學的方法檢測孤立肺小瘤最基本的功能是決定腫瘤是否惡性。影響風險評估的因素包括孤立肺小瘤影像的外形及確認特徵，小瘤的穩定性，病人年齡，抽煙紀錄，及腫瘤病歷紀錄。其他有助於評估孤立肺小瘤的輔助性步驟及影像技術包括氟18-去氧葡萄糖結合正子造影，鈎〔^{99m}Tc〕depreotide 影像術，結合支氣管肺泡灌洗及活組織檢查的支氣管鏡術，影像輔助肺針吸活檢，錄像輔助胸腔鏡手術，及胸廓切開術。

結論：要成功地進行孤立肺小瘤放射學的处理，取決於謹慎的臨床評估，及在施用適當的放射學技術前對腫瘤的風險階段評估。

Introduction

This review article aims to provide a synopsis of current opinions on the radiological management of a solitary pulmonary nodule (SPN). The findings from this review could be used as a practical guide to both clinicians and radiologists in their daily clinical practice. The changing roles of the ubiquitous chest radiograph, computed tomography (CT) techniques, and nuclear medicine imaging in the pursuit of diagnosing or excluding a malignant SPN will be discussed.

An SPN is arbitrarily defined as a focal round or oval opacity with a diameter of 3 cm or less, and which is completely surrounded by lung parenchyma.¹ Nodules larger than 3 cm have a substantially increased risk of malignancy and are referred to as masses.²⁻⁴ In large-scale radiographic surveys, the incidence of

Key words:

Diagnostic imaging;
Lung neoplasms;
Technology, radiologic;
Tomography, X-ray computed

關鍵詞：

診斷放射學；
肺腫瘤；
技術，放射性；
電腦斷層掃描

Hong Kong Med J 2004;10:107-16

Department of Diagnostic Radiology,
The University of Hong Kong,
Queen Mary Hospital, Pokfulam,
Hong Kong
GC Ooi, MRCP, FRCR
PL Khong, FRCR, FHKCR
Diagnostic Imaging Services, Hong Kong
Adventist Hospital, Hong Kong
YY Yau, FRANZCR, FHKCR

Correspondence to: Dr GC Ooi
(e-mail: cgcooi@hkucc.hku.hk)

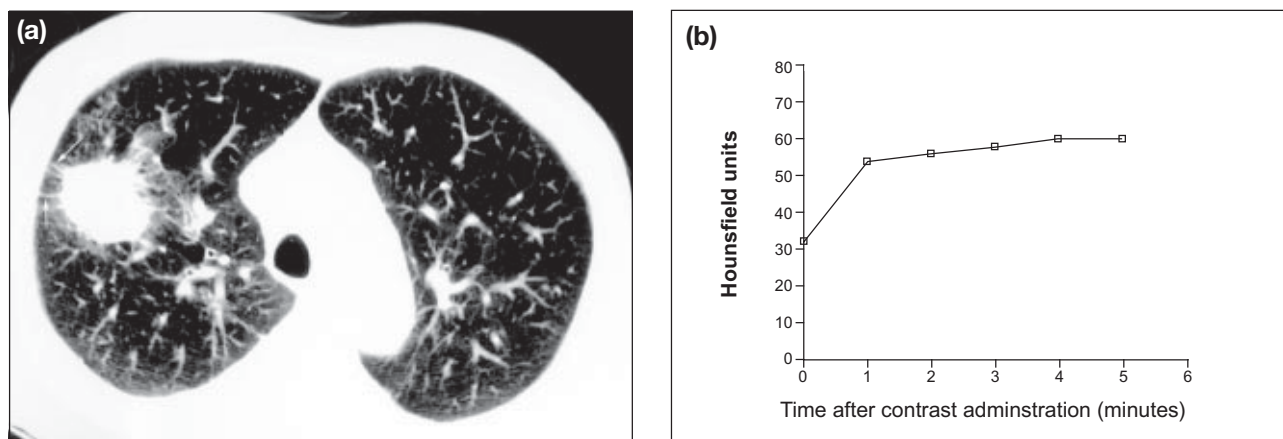


Fig 1. (a) High-resolution computed tomogram showing a 3-cm spiculated solitary pulmonary nodule in the right-upper lobe with pleural tags (arrows), later confirmed to be an adenocarcinoma; (b) Time-activity curve showing increase in enhancement, reaching a plateau by 5 minutes

SPN ranged from 0.09% to 0.20%⁵⁻⁷ and the incidence of malignant SPN ranged from 3% to 6%.^{3,5,8,9} Before the advent of CT, the incidence of malignant SPN as diagnosed by histological examination of resected SPN was 30% to 40%.^{4,7-9} However, since the use of CT in the presurgical diagnosis of benign SPN, the incidence of malignant SPN has increased substantially, ranging from 60% to 80%.^{2,10}

Lung cancer is the primary cause of malignant SPN, followed by solitary metastasis, which is found in 10% to 30% of cases of resected SPN.^{3,4,9,11-13} Carcinoid and primary lymphomas are other occasional causes of malignant SPN.¹³ Despite improved surgical techniques and the availability of new treatment regimens, the overall 5-year survival rate is 14% to 20%. The prognosis for patients who have malignant SPN with an early clinical tumour-node-metastasis (TNM) staging is significantly better than for other patients. For example, clinical stage 1A (T1N0M0) disease has a 5-year survival of 67% to 83%,¹⁴⁻¹⁶ compared with 20.2%, 5.1% and 7.9% for stage IIIA, IIIB, and IV respectively.¹⁵ A malignant SPN with a diameter of 3 cm or less thus represents potentially curable disease in which the 5-year survival is inversely related to nodule size at presentation.^{11,17}

In clinical practice, most cases of SPN are benign. Healed granulomas secondary to tuberculous or fungal infection are the most common benign entities encountered, whereas hamartomas, found in 10% of resected benign SPNs, represent the next most common type of benign SPN.^{4,9,17,18} Hence, diagnostic investigations of SPNs aim at facilitating the prompt and accurate identification of a benign lesion, thereby avoiding unnecessary thoracotomies and allowing prompt intervention if nodules are malignant.

Clinical evaluation

Before a physician starts characterising an SPN, several

clinical factors—such as age, smoking history, occupational exposure (eg to asbestos), and previous malignant disease—need to be addressed. Travel history to and from areas where tuberculosis or fungal infections (eg coccidioidomycosis and histoplasmosis) are endemic may be important. In patients younger than 30 years, lung cancer is rare unless there is a history of extrathoracic primary cancer, in which case metastatic SPN is likely. In contrast patients older than 40 years—particularly those with a history of smoking—have a markedly increased likelihood of having primary lung cancer.¹⁹

There is continuing debate over the clinical utility of obtaining sputum for cytology in the routine investigation of SPN.^{20,21} Nevertheless, in our practice at the Queen Mary Hospital, sputum cytology is still performed as one of the diagnostic tests of the SPN in persons in whom lung cancer is suspected. The diagnostic rate for positive sputum cytology in patients with malignant SPN is low (<20%) and contributes mainly to the diagnosis of squamous cell cancer because of its propensity for a central intrabronchial site.^{20,22} False-negative sputum cytology is prevalent (>60%) in patients with peripheral lung cancers.²¹

Nodule detection

Computed tomography remains the most commonly used and available radiological method to evaluate an SPN after initial detection with a chest X-ray.²⁰ A low-dose helical screening scan (of 7- or 10-mm slice thickness, 50 mA) can be performed in the first instance to locate the SPN and to screen for other nodules.²³ Retrospective reconstruction into thinner slice intervals or, with multislice scanners, reconstruction into thinner sections could be performed. The presence of other nodules in the lungs may suggest metastatic disease or infection—the latter condition is particularly indicated by the presence of satellite nodules.

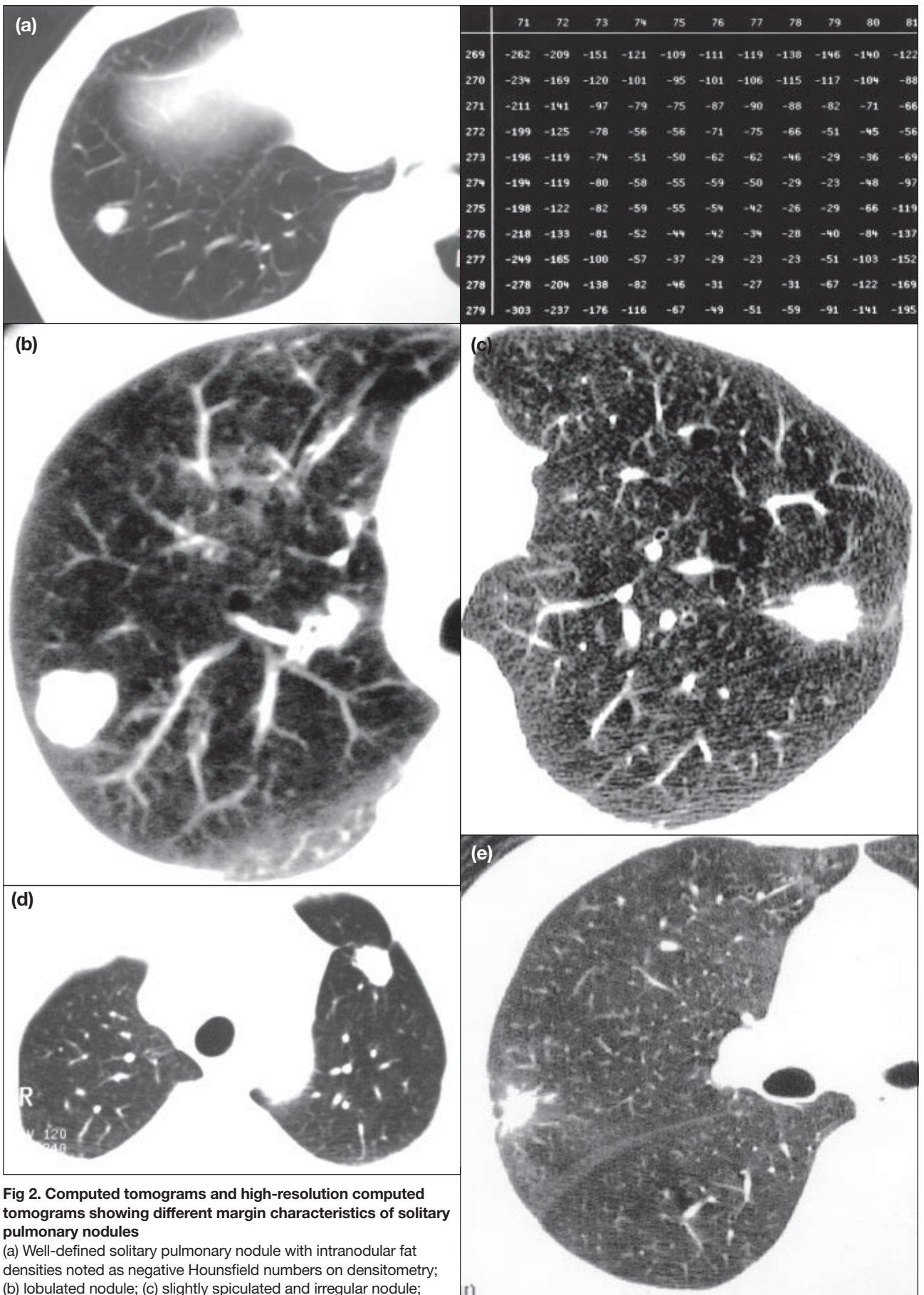


Fig 2. Computed tomograms and high-resolution computed tomograms showing different margin characteristics of solitary pulmonary nodules

(a) Well-defined solitary pulmonary nodule with intranodular fat densities noted as negative Hounsfield numbers on densitometry; (b) lobulated nodule; (c) slightly spiculated and irregular nodule; (d) polygonal nodule; and (e) a small nodule with surrounding ground-glass opacification (halo sign)

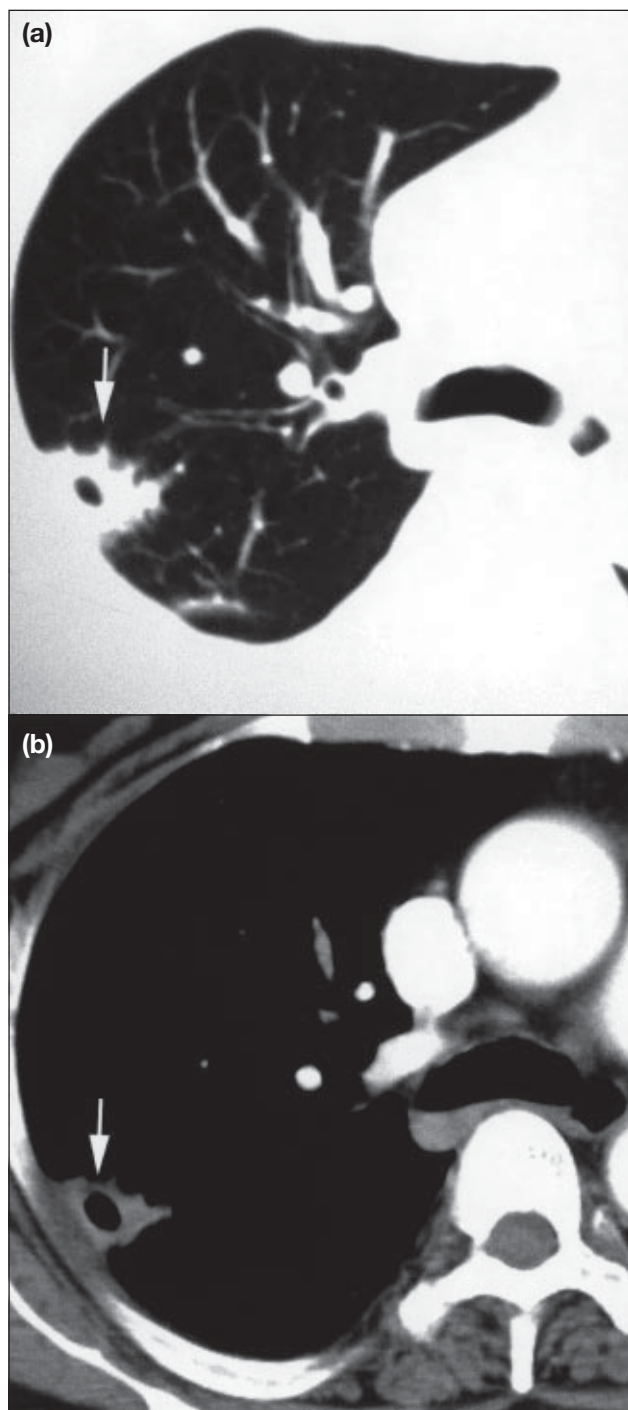


Fig 3. Computed tomograms showing a cavitating mycetoma
Note subpleural position of the solitary pulmonary nodule (arrow) with coarse spiculations and cavitation on (a) lung and (b) mediastinal window settings, respectively

Although synchronous tumours may exist when two nodules are found by CT, this situation is extremely rare.²⁴ We routinely perform contiguous high-resolution CT scans (at 1-3 mm) through the nodule to define morphology of an SPN, followed by contrast-enhanced helical scans through the nodule and rest of the thorax. Thin-section CT, particularly with high resolution, is more accurate in detecting calcification than is conventional CT. The detection of a

benign pattern of calcification can obviate further nodule evaluation.²

Nodule characterisation

The determination of the nature of an SPN using a method of imaging rests partly on its morphological features, such as nodule size, margins, density, presence of fat or calcification, and enhancement characteristics. A combination of certain features may suggest either a benign or malignant lesion. For example, a spiculated uncalcified 3-cm nodule with enhancement (Fig 1) in a 65-year-old man with a life-long history of smoking 20 packs of cigarettes per day would very likely be malignant. Conversely, the 1-cm non-enhancing nodule with smooth borders and intranodular fat in a 20-year-old athlete would in all likelihood be benign (Fig 2a). However, an overlap of features generally occurs, rendering the task of estimating the likelihood of malignancy in an SPN even more challenging.

Size

Whether one uses chest radiography or CT to evaluate SPN, a general rule is that the larger the nodule is, the more likely it is to be malignant; the smaller it is, the more likely it is to be benign.^{2,4,13,25} Gurney²⁶ analysed the likelihood ratios for malignancy in four groups of SPN derived from 1080 patients: nodules that were 2 to 3 cm and larger than 3 cm in diameter had substantially larger likelihood ratios for malignancy (3.67 and 5.23, respectively) than smaller SPNs of 1 to 2 cm and less than 1 cm in diameter (0.74 and 0.52, respectively).^{2,25,26} That is, at least 80% of SPNs larger than 2 cm that are identified by CT will be malignant.^{2,13,25} However, with low-dose CT to screen for lung cancer in high-risk populations, very small nodules (<1 cm) are increasingly reported to be malignant.²⁷⁻²⁹ In the Early Lung Cancer Action Project study, the annually repeated CT screening of high-risk patients yielded 16 cases with suspicious nodules, of which eight were proven to be lung cancer; the mean size of these nodules was 8 mm (range, 2-25 mm).²⁷ Furthermore, lung cancer was found in 38% of nodules of less than 1 cm that were removed during video-assisted thorascopic surgery in 37 patients without previous malignancy.²⁹

Margin characteristics

The four categories of nodular margin that are commonly described in clinical practice are (1) smooth and regular (Fig 2a); (2) moderately smooth or slightly lobulated (Fig 2b); (3) slightly spiculated or irregular (Fig 2c); and (4) grossly irregular with spiculations (Figs 1 and 3).²⁵ Most malignant SPNs have irregular and spiculated margins, whereas benign nodules are generally well defined and have smooth margins.^{2,25,26,30} However, malignant nodules may in some cases exhibit smooth and regular contours, and benign nodules may have spiculated irregular margins (Fig 3). Zwirwich et al³⁰ correlated high-resolution CT findings with disease state by using specimens of SPN obtained from 98 patients: although spiculation was observed

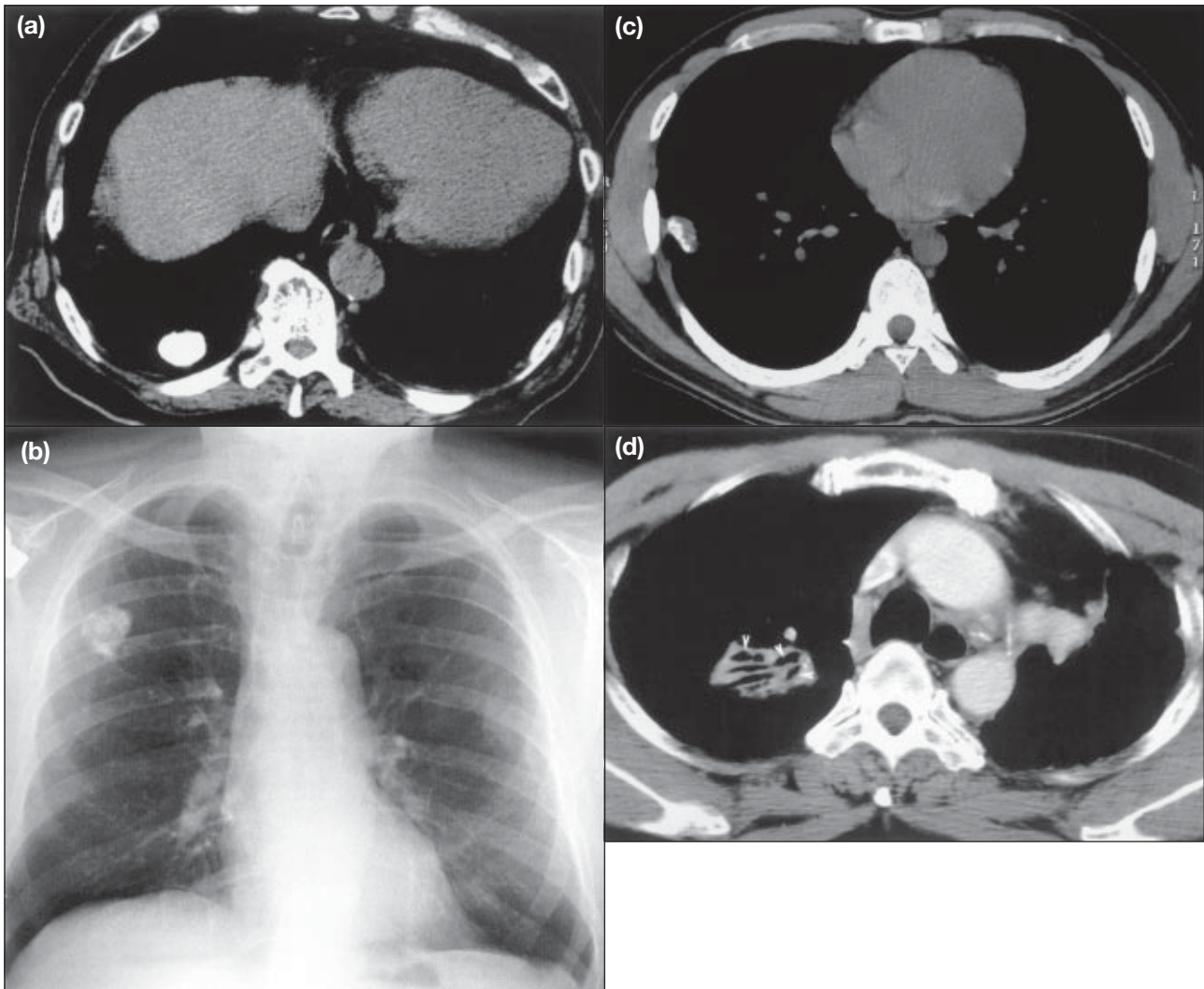


Fig 4. Computed tomograms and X-rays of a solitary pulmonary nodule

(a) a well-defined solitary pulmonary nodule with uniform calcification on plain computed tomogram; (b) a solitary pulmonary nodule with laminated calcification on chest X-ray; (c) a subpleural nodule with eccentric calcification on plain computed tomogram; and (d) a solitary pulmonary nodule with air bronchograms (arrowheads) confirmed to be bronchioloalveolar cell carcinoma in the right-upper lobe on contrast-enhanced computed tomogram

in 90% of primary lung cancers, it was also present in four of five tuberculous lesions and one of two inflammatory lesions.³⁰ The spiculations corresponded to a desmoplastic reaction that resulted in the radiation of fibrotic strands into the surrounding lung parenchyma. Pleural tags were an extension of this desmoplastic reaction, and although more commonly found in malignant nodules (Fig 1), they were also found in inflammatory nodules (Fig 3).³⁰ In the same study, lobulation of SPNs, which represents uneven growth, was more predictive of malignancy than spiculation: the likelihood ratio for malignancy of 2.07, compared with 1.29 for a spiculated nodule.

Two other margin types have been described: polygonal—defined as sharply demarcated angular margins concave towards the centre of nodule (Fig 2d)—and nodule surrounded by a ‘halo’ of opacification resembling ground glass (Fig 2e).³¹ The polygonal appearance is associated with benign SPN and is attributed to fibrosis, dense infiltration

of inflammatory cells, alveoli collapse, and organisation of the interlobular septae.³¹ However, surrounding emphysema and intranodule fibrosis in a malignant SPN can also result in a polygonal appearance.³¹

The CT halo sign was previously regarded as characteristic of invasive aspergillosis, but it is now acknowledged to be associated with infections such as candidiasis, cytomegalovirus, herpes pneumonia, and tuberculosis, as well as with non-infectious conditions such as Kaposi’s sarcoma, metastatic angiosarcoma, and lung cancer.³⁰⁻³³ The ground-glass opacification in malignant SPN is attributed to lepidic growth along the alveolar walls at the edge of the solid invasive component.^{30,33,34}

Internal characteristics

The presence of calcification, fat, cavitation, and air-bronchograms within an SPN are useful indicators of whether the nodule is benign or malignant. At our institution,

contiguous high-resolution thin CT sections (1-3 mm) through the nodule is routinely performed to detect calcification and characterise internal features, particularly in small nodules (<1 cm); this approach eliminates partial-volume effects, which are associated with the use of thicker conventional CT (8-10 mm) sections.^{2,18,20,21} The pattern of calcification within an SPN has been extensively studied and reviewed.^{2,25,35,36} Computed tomography is more sensitive and accurate than plain radiography in the detection and characterisation of calcification patterns.^{25,37} Uniform, central, laminated, and ‘popcorn’ calcification (Figs 4a and b) are indicative of a benign nodule such as granuloma or hamartoma,^{25,35,36,38} whereas SPNs with eccentric (Fig 4c) or stippled (dystrophic) calcification are suggestive of a more sinister pathology.^{1,30,39} Eccentric calcification may be due to tumour engulfment of pre-existing calcified granuloma, and stippled calcification may be due to dystrophic calcification of tumour necrosis.

The presence of intranodular fat (Fig 2a) of -40 to -120 Hounsfield units (HU) is even more indicative of a benign lesion such as hamartoma or lipoid pneumonia than is calcification.³⁹ Up to 50% of hamartomas will contain intranodular fat, of which a quarter will be in the typical

popcorn pattern on a CT scan.³⁸ Other internal features, such as low-density ‘bubbly’ areas (pseudo-cavitation) and air-bronchograms (Fig 4d), are suggestive of bronchioloalveolar carcinoma and lymphoma.^{30,40,41} Even though a benign SPN may display this sign, the prevalence (<6%) is much lower compared with malignant SPN (up to 65%).^{40,41} Cavitations can occur in both benign and malignant SPNs, although malignant cavitating SPNs generally have thick and irregular walls.^{30,42} A wall thickness of 4 mm or less has been reported to suggest benign pathology, whereas a wall thickness of 16 mm or more is almost always associated with a malignant nodule.⁴² A considerable overlap of benign and malignant entities, however, exists for wall thicknesses between 4 and 16 mm (Fig 3).

Densitometry

Densitometry was first used in 1980 to detect calcification in SPNs, whereby the detection of pixel densities of greater than 164 HU was indicative of a benign nodule.⁴³ This technique was not entirely successful because of technical factors arising from differences in scanner specifications and reconstruction algorithms, prompting the development of a reference ‘phantom’ with a density of 185 HU, against which measurement of a nodule could be compared.^{44,45} However, calcification could clearly be seen in 50% of nodules on thin-section CT without requiring the phantom.⁴⁴ In addition, improvements in scanner technology, such as use of helical and multislice scanning, have obviated the need for a phantom. At the Queen Mary Hospital, we perform densitometry without a phantom and regard nodules with pixel densities of more than 200 HU as indicative of the presence of calcification (Fig 5). It must be emphasised that densitometry has little place in the evaluation of a spiculated SPN, which should be treated in all cases with a high degree of suspicion for malignancy.

Nodule enhancement

The predictive value of nodule enhancement in the eva-

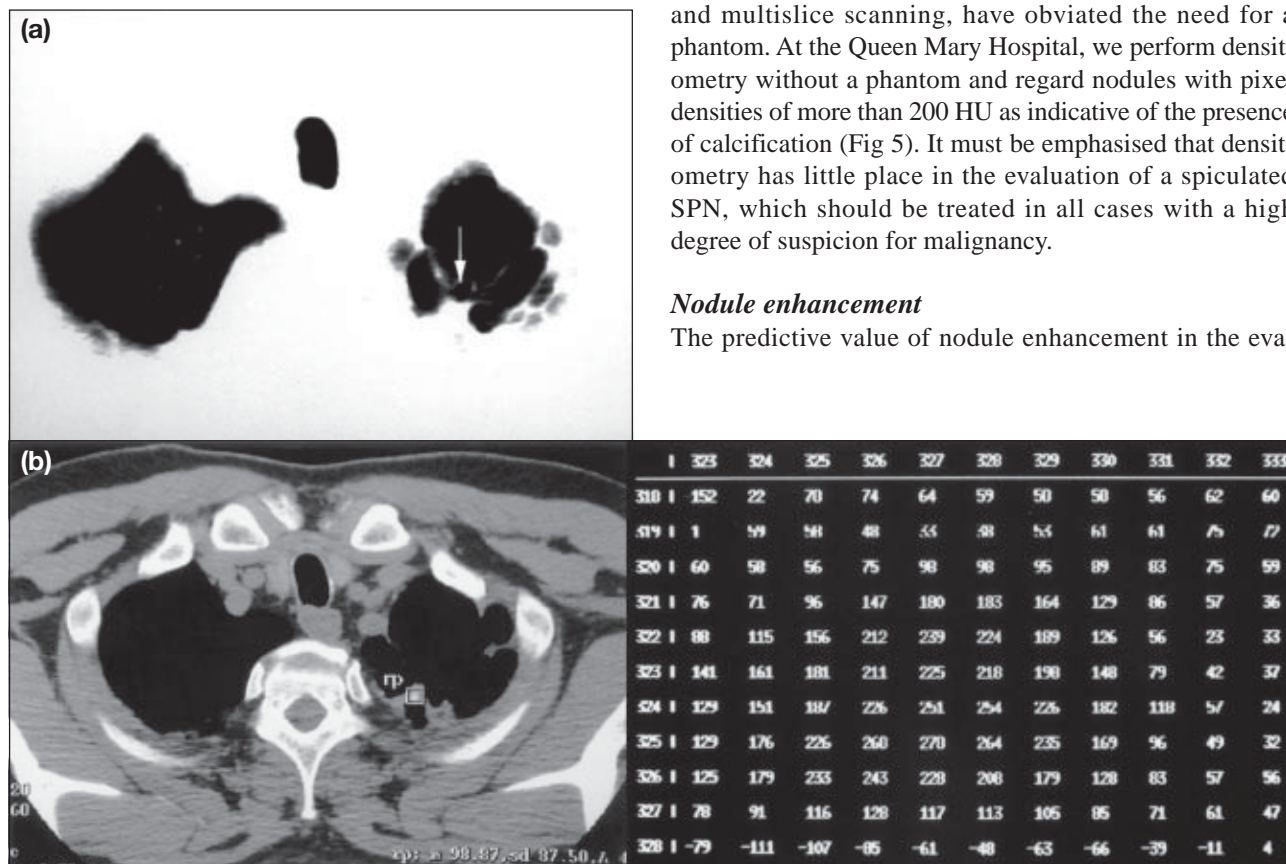


Fig 5. Low-dose computed tomograms of the thorax
 (a) Lung (arrow) and (b) mediastinal windows of a 52-year-old man with atypical cells on sputum analysis show fibrosis in the left lung apex with a small (<1 cm) nodule. Nodule density was measured to be 98.87 HU. On further interrogation with fine-section computed tomography and densitometry, central calcified foci of >200 HU were noted, suggesting this was a granuloma

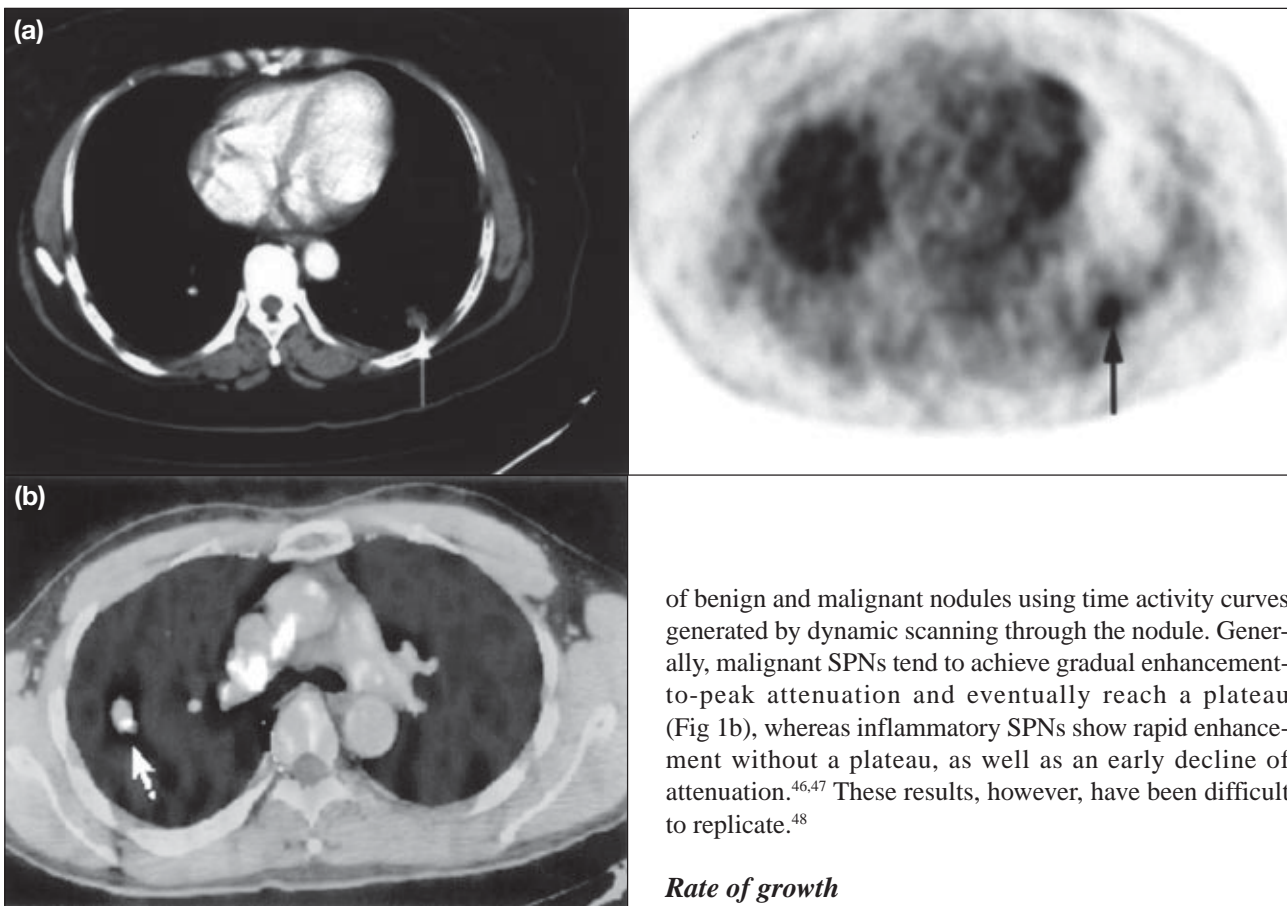


Fig 6. Positron-emission tomography/computed tomography scans

(a) Scan showing a single pulmonary nodule in the subpleural portion of the posterior segment of the right lower lobe. The nodule had a maximum specific uptake value of 3.8 without uptake elsewhere, suggesting metastatic nodal or distant spread; (b) Scan showing a false-positive scan in a solitary pulmonary nodule in the right-upper lobe, with a maximum specific uptake value of 4.2. Biopsy later proved it to be a tuberculoma

luation of SPN has been confirmed by several studies.⁴⁵⁻⁴⁸ The use of a threshold value of enhancement of up to 15 HU, as determined by subtracting the pre-enhancement density from the peak enhancement density during the first 4 minutes of dynamic scanning, has yielded a sensitivity, specificity, and accuracy of 98%, 58%, and 77%, respectively, for predicting a benign SPN.⁴⁸ This method, however, is meticulous and involves dynamic scanning through a nodule at 1, 2, 3, and 4 minutes after contrast administration; furthermore, regions of interest are within approximately 70% of the nodule's short- and long-axis diameters, as measured on mediastinal window settings. Respiratory misregistration, cardiac motion artefacts, and the lack of specificity are further limitations of this technique. Inflammatory lesions and benign nodules such as hamartomas also demonstrate significant enhancement above the threshold range. Yamashita et al⁴⁶ and Zhang and Kono⁴⁷ have attempted to clarify these ambiguities by evaluating the enhancement patterns

of benign and malignant nodules using time activity curves generated by dynamic scanning through the nodule. Generally, malignant SPNs tend to achieve gradual enhancement-to-peak attenuation and eventually reach a plateau (Fig 1b), whereas inflammatory SPNs show rapid enhancement without a plateau, as well as an early decline of attenuation.^{46,47} These results, however, have been difficult to replicate.⁴⁸

Rate of growth

The growth of an SPN is commonly measured in terms of the doubling time (interval required for the SPN to double in volume) and is an additional parameter that can be applied to determine SPN activity and therefore risk of malignancy. Because SPNs are typically spherical, the calculation of the doubling time is based on that of the volume of a sphere ($4/3\pi r^3$), whereby an increase in diameter of 26% indicates a doubling of its volume. Malignant SPNs grow exponentially with a variable range of doubling times, ranging from 30 to 1077 days and from 52 to 1733 days according to two studies.^{49,50} Benign nodules such as a hamartoma or granuloma are usually stable and have doubling times of more than 500 days.^{51,52} Inflammatory SPNs can grow even faster than malignant nodules, with a doubling time of less than 20 days.⁵¹ As a rule, doubling times that are less than 1 month may indicate infection, infarction, lymphoma, or fast-growing metastasis.^{52,53}

Although the absence of detectable growth over 2 years was previously used as an indicator of a benign nodule, the predictive value for this criterion is only 65%.^{39,54} The scientific basis for this concept has been challenged by several studies.^{49,50,55-57} It is now widely accepted that lung cancers differ in their doubling times. In addition, the rate of growth of lung cancers are also influenced by both their morphology on CT scans and the histological cell types. The doubling time is the longest for adenocarcinoma (mean doubling time, 116.0-223.1 days), and next longest for squamous cell carcinoma (88.0-104.8 days), large cell carcinoma (71.0-100.0 days), and small cell

carcinoma (30-80.9 days).^{49,55-57} In a study on small lung tumours that were diagnosed during a large-scale lung cancer CT screening programme, solid nodules on a high-resolution CT scan had the shortest doubling time (149 days), whereas tumours exhibiting focal ground-glass opacities had the longest (813 days).⁵⁰ Given these findings, some investigators recommend serial follow-up visits lasting more than 2 years, particularly if previous imaging, be it CT scan or chest radiographs, was not available.^{18,58} Tumour growth can be assessed with either plain chest radiography or CT using standard two-dimensional measurement. Current CT technology has also made it possible for quantification of volumetric growth rates in nodules.⁵⁹

Image-guided biopsies

Image-guided transthoracic needle aspiration biopsies (TNABs) are best reserved for SPNs that are peripherally located, whereas bronchoscopic biopsies are most accurate in sampling central and endobronchial lesions.²³ Computed tomography is invaluable in determining not only the site and position of an SPN for biopsy, but also in determining the most appropriate biopsy technique for the SPN. Fluoroscopy and CT remain the main imaging methods for image-guided biopsy, although ultrasonography can be used in peripheral SPNs, where the acoustic window is unlimited by intervening lung parenchyma. The drawbacks of CT-guided TNAB are the lack of real-time imaging and the long time taken for image generation and reconstruction; by comparison, fluoroscopic TNAB is inherently faster to perform. The yield from TNAB can be as high as 95% in a peripheral neoplastic nodule, and even higher in the presence of an on-hand cytologist.^{23,60,61} Transthoracic needle aspiration biopsies have a reported sensitivity and specificity of 80% to 95% and 50% to 88%, respectively.^{11,62} The method's diagnostic yield increases with nodule size, increasing from 60% in SPNs of 1 cm or smaller to 80% in SPNs of 2 cm.⁵⁸ False-negative TNAB results, however, are found in 3% to 29% of cases, and a pneumothorax complicates up to a third of TNABs.^{11,62,63}

Nuclear medicine imaging

The role of nuclear medicine imaging, such as fluorodeoxyglucose (FDG) positron-emission tomography (PET) and technetium Tc 99m depreotide imaging, in the evaluation of SPNs remain underutilised, partly because of availability and cost restraints.⁶⁴⁻⁶⁷ A recent meta-analysis examining the diagnostic accuracy of FDG PET (Fig 6a) in determining malignancy reported a mean sensitivity and specificity of 96.8% and 77.8%, respectively, for any focal lung lesion, and 93.9% and 85.8%, respectively, for pulmonary nodules.⁶⁷ The intermediate specificity of FDG PET stems from false-positive results when imaging inflammatory or infective tissue such as granulomas (Fig 6b), and histoplasmosis, aspergillosis, and coccidioidomycosis lesions. This problem is inherent in areas in which these

infections are endemic. Size limitations because of resolution constraints of the PET cameras have also resulted in reduced sensitivities for nodules of less than 1 cm in size.⁶⁵ In addition, bronchioloalveolar and carcinoid tumours may give rise to false-negative results on account of their relatively low metabolic rate. Despite these limitations, FDG PET not only has a role in determining the likelihood of malignancy in an SPN, but also helps in the staging of malignant nodules. The method is particularly useful in detecting occult metastasis, such as lymph node metastasis.

Technetium Tc 99m depreotide is a synthetic cyclic 6-amino acid peptide analogue of somatostatin, which has recently been approved in North America for use in the evaluation of SPNs. Although somatostatin receptor expression in non-small-cell lung carcinomas (NSCLCs) has not been demonstrated *in vitro*, NSCLC has been imaged using somatostatin-analogue scintigraphy.^{64,66} The reported sensitivity and specificity of technetium Tc 99m depreotide imaging ranges from 93% to 96.6% and 73.1% to 88%, respectively, which are comparable to those of FDG PET. However, the mean size of SPNs that were imaged with this technique ranged from 2.4 cm to 2.8 cm.^{64,66} Hence, the issue of accuracy in detecting malignant SPNs of less than 1 cm remains unresolved.

Determining the likelihood of malignancy

The likelihood that an SPN is malignant can be determined using likelihood ratios by the application of Bayesian analysis.^{21,68} The predictors of malignancy that are commonly used to assess the likelihood of malignancy are based mainly on the morphological appearance of the nodule; these predictors include margin, size, and presence of calcification and enhancement. Additional factors are patient's age, smoking history, and the stability of the nodule. Variables that predict malignancy are an age of older than 60 years, a nodule of larger than 1.5 cm diameter, history of smoking, spiculated or irregular nodular margins, eccentric or stippled calcification, a doubling time of 30 to 400 days, the absence of satellite lesions, and an enhancement by more than 20 HU.

Because patients' demographic characteristics, culture, and disease pattern, as well as the availability of imaging modalities and radiological and clinical expertise, may vary between institutions, it would be imprudent to suggest a specific decision pathway in the radiological approach to examining SPNs. Nevertheless, an attempt has to be made to determine the stability of a nodule either retrospectively using a previous chest X-ray or prospectively with serial chest X-rays. An SPN that has been stable for at least 2 years according to a previous chest X-ray could be regarded as currently stable, although further follow-up with 3-to-6 monthly serial chest radiography for another year is advocated.⁵¹ At the Queen Mary Hospital, if after characterisation with CT, an SPN has obvious malignant features,

we routinely perform bronchoscopy with broncho-alveolar lavage, and—depending on tumour site—we offer trans-bronchial biopsy or TNAB. Video-assisted thorascopic surgery of peripheral nodules and some central-lower lobe lesions is also performed on selected patients who have no contra-indications to surgery. This procedure carries markedly reduced mortality and morbidity compared with open thoracotomy for wedge resection,^{69,70} although the conversion rate to open thoracotomy is approximately 20%.⁷⁰ Other centres may advocate prompt thoracotomy in patients with obvious malignant nodules who have no obvious contra-indications to surgery.^{51,62}

Finally, FDG PET is increasingly used to determine malignancy of SPNs at our institution. Decision-analysis models have been used to study the impact of FDG PET on diagnosis of an SPN: FDG PET imaging alone was found to be superior to either traditional Bayesian approach or FDG PET plus Bayesian approach in accurately determining whether a nodule is malignant or benign.⁷¹ A similar study evaluating cost-effectiveness also found CT-plus-PET strategy to be superior to conventional approaches.⁶⁷ The combined CT-plus-PET strategy showed the best incremental cost-effectiveness ratio when the pre-test likelihood of a malignant SPN was between 12% and 69%, whereas a 'wait and see' approach was most suitable for SPNs with a pretest likelihood of less than 12%.⁷² Estimated cost savings of US\$91 to US\$2200 per patient would be generated using the CT-plus-PET strategy.⁷²

Conclusions

The radiological approach to studying an SPN involves initial clinical evaluation with particular emphasis on assessment of possible risk factors for malignancy. Previous chest X-rays should be retrieved in an attempt to retroactively assess the stability of the SPN. If the nodule has been stable for the previous 2 years, serial chest radiography is still advocated, by some, for another year. In the absence of previous chest X-rays, the SPN should be characterised in detail with CT, with and without enhancement. If a confident diagnosis of a benign nodule (calcified, fat-containing, and without enhancement) is made with CT, further follow-up is usually not necessary. In an SPN with malignant features, a more aggressive approach should be pursued depending on the set-up of the institution and wishes of the patient. Strategies that could be implemented in the determination of malignancy include FDG-PET, technetium Tc 99m depreotide imaging, bronchoscopy, TNAB, video-assisted thorascopic surgery, and thoracotomy.

References

1. O' Donovan PB. The radiologic appearance of lung cancer. *Oncology (Huntingt)* 1997;11:1387-402.
2. Zerhouni EA, Stitik FP, Siegelman SS, et al. CT of the pulmonary nodule: a cooperative study. *Radiology* 1986;160:319-27.

3. Steele JD. The solitary pulmonary nodule. Report of a cooperative study of resected asymptomatic solitary pulmonary nodules in males. *J Thorac Cardiovasc Surg* 1963;46:21-39.
4. Higgins GA, Shields TW, Keehn RJ. The solitary pulmonary nodule. Ten-year follow-up of veterans administration-armed forces cooperative study. *Arch Surg* 1975;110:570-5.
5. Holin SM, Dwork RE, Glaser S, Rikli AE, Stocklen JB. Solitary pulmonary nodules found in community-wide chest roentgenographic survey; a five-year follow-up study. *Am Rev Tuberc* 1959;79:427-39.
6. Comstock GW, Vaughan RH, Montgomery G. Outcome of solitary pulmonary nodules discovered in an x-ray screening program. *N Engl J Med* 1956;254:1018-22.
7. Good CA, Wilson TW. The solitary circumscribed pulmonary nodule; study of seven hundred five cases encountered roentgenologically in a period of three and one-half years. *J Am Med Assoc* 1958;166:210-5.
8. McClure CD, Boucot KE, Shilman GA, et al. The solitary pulmonary nodule and primary lung malignancy. *Arch Environ Health* 1961;3:127-39.
9. Bateson EM. An analysis of 155 solitary lung lesions illustrating the differential diagnosis of mixed tumours of the lung. *Clin Radiol* 1965;16:51-65.
10. Ward HB, Pliego M, Diefenthal HC, Humphrey EW. The impact of phantom CT scanning on surgery for the solitary pulmonary nodule. *Surgery* 1989;106:734-9.
11. Lillington GA. Management of solitary pulmonary nodules. *Dis Mon* 1991;37:271-318.
12. Toomes H, Delphendahl A, Manke HG, Vogt-Moykopf I. The coin lesion of the lung. A review of 955 resected coin lesions. *Cancer* 1983;51:534-7.
13. Libby DM, Henschke CI, Yankelevitz DF. The solitary pulmonary nodule: update 1995. *Am J Med* 1995;99:491-6.
14. Mountain CF. A new international staging system for lung cancer. *Chest* 1986;89(4 Suppl):225S-233S.
15. Naruke T, Goya T, Tsuchiya R, Suemasu K. Prognosis and survival in resected lung carcinoma based on the new international staging system. *J Thorac Cardiovasc Surg* 1988;96:440-7.
16. Bulzebruck H, Bopp R, Drings P, et al. New aspects in the staging of lung cancer. Prospective validation of the International Union Against Cancer TNM classification. *Cancer* 1992;70:1102-10.
17. Becker GL, Whitlock WL, Schaefer PS, Tenholder MF. The impact of thoracic computed tomography in clinically staged T1, N0, M0 chest lesions. *Arch Intern Med* 1990;150:557-9.
18. Midthun DE, Swensen SJ, Jett JR. Clinical strategies for solitary pulmonary nodule. *Annu Rev Med* 1992;43:195-208.
19. Cummings SR, Lillington GA, Richard RJ. Estimating the probability of malignancy in solitary pulmonary nodules. A Bayesian approach. *Am Rev Respir Dis* 1986;134:449-52.
20. Khouri NF, Meziane MA, Zerhouni EA, Fishman EK, Siegelman SS. The solitary pulmonary nodule. Assessment, diagnosis, and management. *Chest* 1987;91:128-33.
21. Webb WR. Radiologic evaluation of the solitary pulmonary nodule. *AJR Am J Roentgenol* 1990;154:701-8.
22. Frost JK, Ball WC Jr, Levin ML, et al. Early lung cancer detection: results of the initial (prevalence) radiologic and cytologic screening in the Johns Hopkins study. *Am Rev Respir Dis* 1984;130:549-54.
23. Rusinek H, Naidich DP, McGuinness G, et al. Pulmonary nodule detection: low-dose versus conventional CT. *Radiology* 1998;209:243-9.
24. Bower SL, Choplin RH, Muss HB. Multiple primary bronchogenic carcinomas of the lung. *AJR Am J Roentgenol* 1983;140:253-8.
25. Siegelman SS, Khouri NF, Leo FP, Fishman EK, Braverman RM, Zerhouni EA. Solitary pulmonary nodules: CT assessment. *Radiology* 1986;160:307-12.
26. Gurney JW. Determining the likelihood of malignancy in solitary pulmonary nodules with Bayesian analysis. Part I. Theory. *Radiology* 1993;186:405-13.
27. Henschke CI, Naidich DP, Yankelevitz DF, et al. Early lung cancer action project: initial findings on repeat screenings. *Cancer* 2001;92:153-9.

28. Henschke CI, McCauley DI, Yankelevitz DF, et al. Early Lung Cancer Action Project: overall design and findings from baseline screening. *Lancet* 1999;354:99-105.
29. Munden RF, Pugatch RD, Liptay MJ, Sugarbaker DJ, Le LU. Small pulmonary lesions detected at CT: clinical importance. *Radiology* 1997;202:105-10.
30. Zwirowich CV, Vedal S, Miller RR, Muller NL. Solitary pulmonary nodule: high-resolution CT and radiologic-pathologic correlation. *Radiology* 1991;179:469-76.
31. Furuya K, Murayama S, Soeda H, et al. New classification of small pulmonary nodules by margin characteristics on high-resolution CT. *Acta Radiol* 1999;40:496-504.
32. Primack SL, Hartman TE, Lee KS, Muller NL. Pulmonary nodules and the CT halo sign. *Radiology* 1994;190:513-5.
33. Gaeta M, Barone M, Caruso R, Bartiromo G, Pandolfo I. CT-pathologic correlation in nodular bronchioloalveolar carcinoma. *J Comput Assist Tomogr* 1994;18:229-32.
34. Vazquez MF, Yankelevitz DF. The radiologic appearance of solitary pulmonary nodules and their cytologic-histologic correlation. *Semin Ultrasound CT MR* 2000;21:149-62.
35. O'Keefe ME Jr, Good CA, McDonald JR. Calcification in solitary nodules of the lung. *Am J Roentgenol Radium Ther Nucl Med* 1957;77:1023-33.
36. Mahoney MC, Shipley RI, Corcoran HL, Dickson BA. CT demonstration of calcification in carcinoma of the lung. *AJR Am J Roentgenol* 1990;154:255-8.
37. Berger WG, Erly WK, Krupinski EA, Standen JR, Stem RG. The solitary pulmonary nodule on chest radiography: can we really tell if the nodule is calcified? *AJR Am J Roentgenol* 2001;176:201-4.
38. Siegelman SS, Khouri NF, Scott WW Jr, et al. Pulmonary hamartoma: CT findings. *Radiology* 1986;160:313-7.
39. Shaham D, Guralnik L. The solitary pulmonary nodule: radiologic considerations. *Semin Ultrasound CT MR* 2000;21:97-115.
40. Lee KS, Kim Y, Han J, Ko EJ, Park CK, Primack SL. Bronchioloalveolar carcinoma: clinical, histopathologic, and radiologic findings. *Radiographics* 1997;17:1345-57.
41. Kuriyama K, Tateishi R, Doi O, et al. Prevalence of air bronchograms in small peripheral carcinomas of the lung on thin-section CT: comparison with benign tumors. *AJR Am J Roentgenol* 1991;156:921-4.
42. Woodring JH, Fried AM, Chuang VP. Solitary cavities of the lung: diagnostic implications of cavity wall thickness. *AJR Am J Roentgenol* 1980;135:1269-71.
43. Siegelman SS, Zerhouni EA, Leo FP, Khouri NF, Stitik FP. CT of the solitary pulmonary nodule. *AJR Am J Roentgenol* 1980;135:1-13.
44. Zerhouni EA, Boukadoum M, Siddiky MA, et al. A standard phantom for quantitative CT analysis of pulmonary nodules. *Radiology* 1983;149:767-73.
45. Swensen SJ, Brown LR, Colby TV, Weaver AL. Pulmonary nodules: CT evaluation of enhancement with iodinated contrast material. *Radiology* 1995;194:393-8.
46. Yamashita K, Matsunobe S, Tsuda T, et al. Solitary pulmonary nodule: preliminary study of evaluation with incremental dynamic CT. *Radiology* 1995;194:399-405.
47. Zhang M, Kono M. Solitary pulmonary nodules: evaluation of blood flow patterns with dynamic CT. *Radiology* 1997;205:471-8.
48. Swensen SJ, Viggiano RW, Midthun DE, et al. Lung nodule enhancement at CT: multicenter study. *Radiology* 2000;214:73-80.
49. Usuda K, Saito Y, Sagawa M, et al. Tumor doubling time and prognostic assessment of patients with primary lung cancer. *Cancer* 1994;74:2239-44.
50. Hasegawa M, Sone S, Takashima S, et al. Growth rate of small lung cancers detected on mass CT screening. *Br J Radiol* 2000;73:1252-9.
51. Lillington GA. Management of solitary pulmonary nodules. How to decide when resection is required. *Postgrad Med* 1997;101:145-50.
52. Nathan MH, Collins VP, Adams RA. Differentiation of benign and malignant pulmonary nodules by growth rate. *Radiology* 1962;79:221-32.
53. Collins VP, Loeffler RK, Tivey H. Observations on growth rates of human tumors. *Am J Roentgenol Radium Ther Nucl Med* 1956;76:988-1000.
54. Yankelevitz DF, Henschke CI. Does 2-year stability imply that pulmonary nodules are benign? *AJR Am J Roentgenol* 1997;168:325-8.
55. Filderman AE, Shaw C, Matthay RA. Lung cancer. Part I: Etiology, pathology, natural history, manifestations, and diagnostic techniques. *Invest Radiol* 1986;21:80-90.
56. Geddes DM. The natural history of lung cancer: a review based on rates of tumour growth. *Br J Dis Chest* 1979;73:1-17.
57. Fujimori S, Suda S, Yamauchi A, et al. Tumour doubling time and PPD skin test reactivity in resectable lung cancer. *J Jpn Lung Cancer Soc* 1979;19:135-42.
58. Viggiano RW, Swensen SJ, Rosenow EC 3rd. Evaluation and management of solitary and multiple pulmonary nodules. *Clin Chest Med* 1992;13:83-95.
59. Yankelevitz DF, Reeves AP, Kostis WJ, Zhao B, Henschke CI. Small pulmonary nodules: volumetrically determined growth rates based on CT evaluation. *Radiology* 2000;217:251-6.
60. Conces DJ Jr, Schwenk GR Jr, Doering PR, Glant MD. Thoracic needle biopsy. Improved results utilizing a team approach. *Chest* 1987;91:813-6.
61. Khouri NF, Stitik FP, Erozan YS, et al. Transthoracic needle aspiration biopsy of benign and malignant lung lesions. *AJR Am J Roentgenol* 1985;144:281-8.
62. Ost D, Fein A. Evaluation and management of the solitary pulmonary nodule. *Am J Respir Crit Care Med* 2000;162:782-7.
63. Berquist TH, Bailey PB, Cortese DA, Miller WE. Transthoracic needle biopsy: accuracy and complications in relation to location and type of lesion. *Mayo Clin Proc* 1980;55:475-81.
64. Goldsmith SJ, Kostakoglu L. Role of nuclear medicine in the evaluation of the solitary pulmonary nodule. *Semin Ultrasound CT MR* 2000;21:129-38.
65. Goldsmith SJ, Kostakoglu L. Nuclear medicine imaging of lung cancer. *Radiol Clin North Am* 2000;38:511-24.
66. Blum J, Handmaker H, Lister-James J, Rinne N. A multicenter trial with a somatostatin analog (^{99m}Tc depreotide) in the evaluation of solitary pulmonary nodules. *Chest* 2000;117:1232-8.
67. Gould MK, Maclean CC, Kuschner WG, Rydzak CE, Owens DK. Accuracy of positron emission tomography for diagnosis of pulmonary nodules and mass lesions: a meta-analysis. *JAMA* 2001;285:914-24.
68. Gurney JW. Determining the likelihood of malignancy in solitary pulmonary nodules with Bayesian analysis. Part I. Theory. *Radiology* 1993;186:405-13.
69. DeCamp MM Jr, Jaklitsch MT, Mentzer SJ, Harpole DH Jr, Sugarbaker DJ. The safety and versatility of video-thoracoscopy: a prospective analysis of 895 consecutive cases. *J Am Coll Surg* 1995;181:113-20.
70. Landreneau RJ, Hazelrigg SR, Ferson PF, et al. Thoracoscopic resection of 85 pulmonary lesions. *Ann Thorac Surg* 1992;54:415-20.
71. Dewan NA, Shehan CJ, Reeb SD, Gobar LS, Scott WJ, Ryschon K. Likelihood of malignancy in a solitary pulmonary nodule: comparison of Bayesian analysis and result of FDG-PET scan. *Chest* 1997;112:416-22.
72. Gambhir SS, Shephard JE, Shah BD, et al. Analytical decision model for the cost-effective management of solitary pulmonary nodules. *J Clin Oncol* 1998;16:2113-25.