



<b>Title</b>	<b>Radiological conference. Medullary sponge kidney</b>
<b>Author(s)</b>	<b>Peh, WCG</b>
<b>Citation</b>	<b>Hong Kong Practitioner, 1999, v. 21 n. 1, p. 30-33</b>
<b>Issued Date</b>	<b>1999</b>
<b>URL</b>	<b><a href="http://hdl.handle.net/10722/44674">http://hdl.handle.net/10722/44674</a></b>
<b>Rights</b>	<b>Creative Commons: Attribution 3.0 Hong Kong License</b>

# RADIOLOGICAL CONFERENCE

## Clinical History:

A 22-year-old man presented with bilateral loin pain. He passed out a small stone on the day of his intravenous urogram (IVU). Preliminary radiograph (Figure 1) and IVU (Figure 2) were performed.

Figure 1: Frontal radiograph coned to the kidney

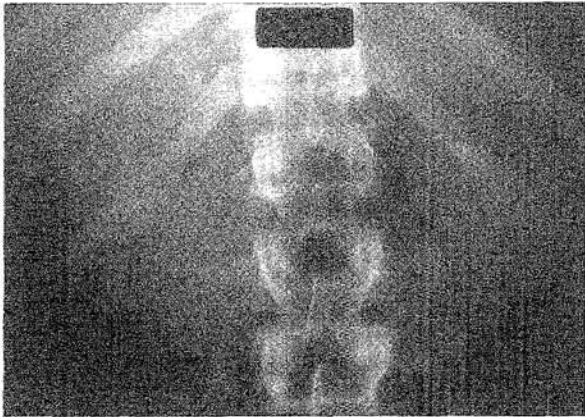
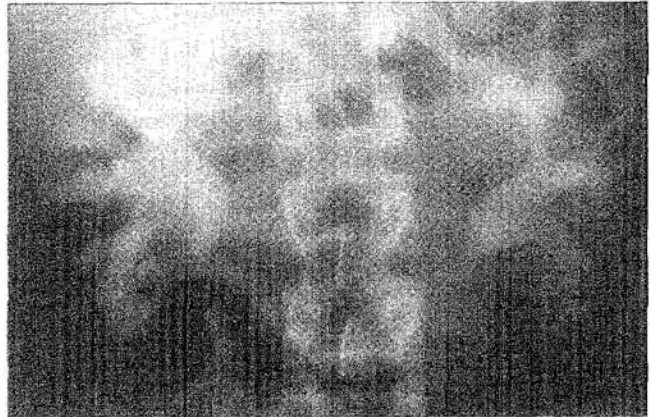

Figure 2: Ten-minute IVU film (frontal projection)



Answer  
on  
page 31

## What is the diagnosis?

- a) Medullary sponge kidney
- b) Tuberculosis
- c) Renal cell carcinoma
- d) Renal papillary necrosis
- e) Enteric hyperoxaluria

This radiology case was prepared by: **Professor W.C.G. Peh,**  
Department of Diagnostic Radiology,  
The University of Hong Kong,  
Queen Mary Hospital.

## RADIOLOGICAL CONFERENCE

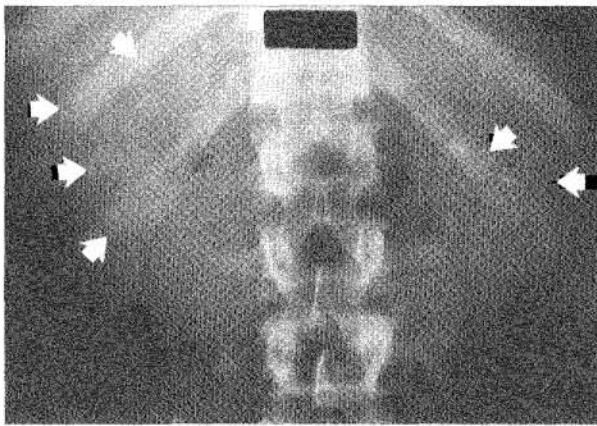
### Answer:

- a) Medullary sponge kidney

### Radiological findings

On the preliminary radiograph, multiple small rounded calcifications are projected over both renal outlines. The calcifications are clustered, producing a "bunch of grapes" appearance. These calcifications are typical of parenchymal calcifications or nephrocalcinosis (Figure 3). IVU shows slight enlargement of both kidneys. The medullary papillae are swollen, and contain multiple contrast-opacified cysts and streaks. The calcifications lie within these opacified areas. Appearances are typical of medullary sponge kidney.

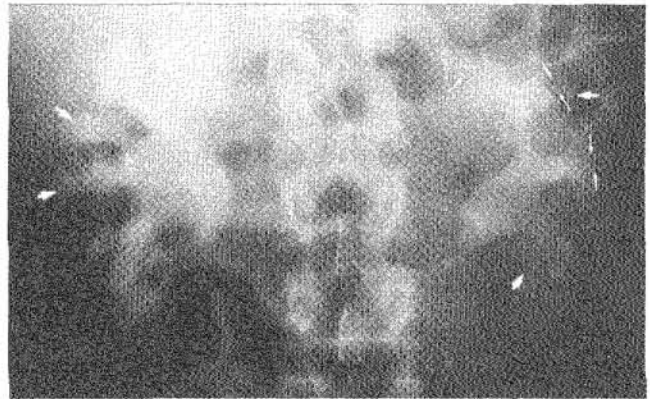**Figure 3: Same radiograph as Figure 1 with the addition of arrows. Multiple clustered calcifications are seen, resembling "bunches of grapes" (arrows)**



### Discussion

Medullary sponge kidney is a congenital disease in which the collecting ducts are abnormally dilated. This produces a sponge-like appearance in the papillary medulla. Numerous cysts, varying in size from 1 to 3 mm in diameter, communicate with these dilated tubules. The dense streaks of contrast in the medullary pyramids give a "bunch of flowers" appearance. Calculi are present in 80% of the cysts, presumably due to urinary pooling.<sup>1,3</sup>

**Figure 4: Same radiograph as Figure 2 with the addition of arrows. Both pelvicalyceal systems are opacified by contrast. Tiny cysts (arrowheads) and streaks (small arrows) are present within the enlarged medullary papillae**



This disease may affect the whole or part of one or both kidneys. Unilateral involvement is present in 25% of cases. It typically affects young to middle-aged adults, and has an incidence of 0.5%. Uncomplicated disease is usually clinically silent. Secondary infection or passage of calculi, such as in our patient, may produce symptoms. Obstruction by calculi or repeated infection may lead to impaired renal function. Medullary sponge kidney may be associated with Ehlers-Danlos syndrome, parathyroid adenoma or Caroli disease.<sup>1-3</sup>

### Tuberculosis

The earliest sign of tuberculosis of the kidney is papillary erosion, which is seen as a central cavity on IVU. Cavitation may spread to involve the rest of the renal parenchyma. Fibrosis causes calyceal neck stenosis, producing obstruction of the calyces. Tuberculosis is characterised by multiple sites of involvement, i.e. the kidneys, ureters and bladder. Calcification may be nodular, curvilinear or amorphous, and usually involves one kidney or part of one kidney. If renal tuberculosis is untreated, the whole kidney may become completely calcified, producing the so-called autonephrectomy.<sup>1,2</sup> This diagnosis can be excluded in our patient on radiological grounds.

(Continued on page 33)

## RADIOLOGICAL CONFERENCE

### Renal cell carcinoma

Calcification is seen in only 6% of renal cell carcinomas. Calcification, if present, is usually amorphous or irregular. Only one kidney or part of the kidney involved by the tumour is calcified. On IVU, the pelvicalyceal system may be invaded and amputated by a mass lesion. The patient may present with the classical clinical triad of flank mass, pain and haematuria.<sup>1,2</sup> These clinical and imaging features were not present in our patient.

### Renal papillary necrosis

Renal papillary necrosis may be caused by a variety of disorders, the most important of which are diabetes, analgesics and sickle cell anaemia. The kidneys are usually small with smooth outlines. On IVU, there may be papillary swelling in the early stage of the disease. Later, papillary slough results in fissuring and cavitation which communicates with the calyces. Sloughing may give the calyces an irregular dilated appearance. The shed papillae may cause ureteric obstruction and if bilateral, acute renal failure. Infection and dehydration

may occur. In the late stage, calcification of necrotic papillae may occur. This disease is bilateral in 80% with multiple papillae affected.<sup>1,2</sup> In our patient, this diagnosis can be excluded clinically and by imaging.

### Enteric hyperoxaluria

This is a rare condition due to a disturbance of bile acid metabolism. It occurs in patients with small bowel disease, such as Crohn's disease or surgical resection. Hyperoxaluria produces pure calcium oxalate calculi. The pattern of calcifications seen in our patient is different from that of renal calculi. On IVU, calculi are located in the pelvicalyceal systems, not within the medullary papillae. ■

### References

1. Sherwood T. Uroradiology. *Blackwell Scientific*, Oxford, 1980;pp87-210.
2. Chapman S, Nakielny R. *Aids to Radiological Differential Diagnosis*. 3rd ed. WB Saunders, London. 1995;pp294-297.
3. Dähnert W. *Radiology Review Manual*. 3rd ed. Baltimore: Williams & Wilkins, 1996;pp576-577.