



<b>Title</b>	<b>Percutaneous transluminal angioplasty for stenosis of arteriovenous fistulae: a review of local experience</b>
<b>Author(s)</b>	<b>Tang, S; Lo, CY; Tso, WK; Lo, WK; Li, FK; Chan, DTM</b>
<b>Citation</b>	<b>Hong Kong Medical Journal, 1998, v. 4 n. 1, p. 36-41</b>
<b>Issued Date</b>	<b>1998</b>
<b>URL</b>	<b><a href="http://hdl.handle.net/10722/44662">http://hdl.handle.net/10722/44662</a></b>
<b>Rights</b>	<b>Creative Commons: Attribution 3.0 Hong Kong License</b>

# Percutaneous transluminal angioplasty for stenosis of arteriovenous fistulae: a review of local experience

S Tang, CY Lo, WK Tso, WK Lo, FK Li, TM Chan

The stenosis and subsequent thrombosis of arteriovenous fistulae may lead to a loss of vascular access sites; this is a major problem in chronic haemodialysis patients. Percutaneous transluminal angioplasty has been a popular way of correcting such lesions in recent years. We have reviewed patients who underwent this operation from 1993 to 1996 at the Queen Mary Hospital. Among 11 patients who were documented as having arteriovenous fistula stenosis, 60% of lesions were in the anastomotic area while 40% were in the venous limb. All patients had abnormal dialysis blood line pressures corresponding to the actual site of stenosis. The initial success rate of percutaneous transluminal angioplasty in treating the stenotic lesions was 73%. This method is thus a promising form of semi-invasive treatment for symptomatic arteriovenous fistula stenosis.

*HKMJ 1998;4:36-41*

*Key words: Angioplasty, balloon; Arteriovenous fistula/radiography; Arteriovenous fistula/therapy; Hemodialysis*

## Introduction

In patients with end-stage renal failure, vascular access remains the Achilles' heel of maintenance haemodialysis. Successful haemodialysis requires repetitive access to large vessels that are capable of providing rapid extracorporeal blood flow. The primary arteriovenous fistula (AVF), created by an anastomosis of the radial artery with the cephalic vein, was first described by Brescia et al in 1966.<sup>1</sup> The cephalic vein becomes arterialised and will theoretically stay uncollapsed even when blood is drawn from it at high flow-rates. Throughout the past decades, this technique has remained the preferred mode of achieving vascular access during haemodialysis.

Maintaining patent vascular access remains a major challenge, especially in an ageing haemodialysis population. Cumulative data shows that vascular access is lost predominantly from an inability to resolve a thrombotic episode.<sup>2</sup> Over 85% of the documented

episodes of thrombosis have an anatomical cause, the most common being stenotic lesions at the arteriovenous anastomosis or along the proximal venous limb. Prospective detection and preventive treatment of a high-grade venous stenosis are important, since they will improve the patency of vascular access and hence decrease the incidence of haemodialysis failure due to fistula loss. Percutaneous transluminal angioplasty (PTA) has been gaining favour in recent years as a means of correcting venous stenosis, thereby improving fistula function and prolonging fistula survival. The majority of the available data on this form of treatment, however, has come from Caucasian patients.

This article reviews the clinical course and treatment outcome of performing PTA for AVF stenosis among Chinese patients on maintenance haemodialysis. Two patients with different problems and outcomes will be highlighted.

## Subjects and methods

### Subjects

Patients on maintenance haemodialysis who underwent PTA between 1993 and 1996 at the Queen Mary Hospital were reviewed. Clinical suspicion of AVF stenosis was based upon abnormal dialysis blood line pressures. Venous dialysis pressures were measured with a mechanical electrical strain gauge and read from the venous pressure monitor of a Gambro AK-10 or similar haemodialysis machine (Gambro Inc., Lincoln-

---

Queen Mary Hospital, Pokfulam, Hong Kong:

Department of Medicine

S Tang, MB, BS, MRCP

CY Lo, MB, BS, MRCP

WK Lo, MB, BS, FRCP

FK Li, MB, BS, MRCP

TM Chan, MRCP, MD

Department of Diagnostic Radiology

WK Tso, MB, BS, FRCP

Correspondence to: Dr S Tang

shire, Illinois, USA). Venous dialysis pressures were measured for the first 30 minutes of each treatment session, while the extracorporeal blood flow through a standard 16 gauge needle was 100 to 150 mL/min. Under such conditions, venous pressures of more than 100 mm Hg, if recorded on three consecutive occasions, were considered abnormal. The arterial blood flow was then increased to the maximum rate. Arterial inflow pressures were reflected indirectly from an air cushion situated between the arterial blood line and the blood pump.

Patients with abnormal dialysis pressures underwent an elective diagnostic venogram (fistulogram). Briefly, patients were admitted as day-cases for fistulograms. A 16 gauge needle was inserted and secured pointing towards the AVF anastomosis. With a sphygmomanometer cuff applied to the upper arm and inflated to above the diastolic blood pressure, 20 to 30 mL of Iopamiro (iopamidol; Bracco, Milan, Italy) were administered using an automated injection gun at a rate of 200 mL/min while fistulograms were taken in rapid succession. This was followed by flushing with normal saline to alleviate any local discomfort in the forearm. The entire procedure was sometimes repeated without the sphygmomanometer cuff to visualise the more proximal venous run-off.

#### **Angioplasty technique**

A 6-French vascular introducer sheath was inserted percutaneously into the venous limb of the AVF, and was directed retrogradely towards the stenotic segment to be dilated. A set of diagnostic fistulograms was produced. The length and diameter of the stenotic segment was measured using the radiograph of the fistulogram. An angioplasty balloon with a diameter that was 1 mm larger than the adjacent normal vascular segment (usually 5 to 6 mm in diameter) was selected for PTA. The stenosis was traversed with a 0.035-inch guide-wire (Terumo, Tokyo, Japan) via the introducer sheath. Three thousand units of heparin were administered through the side port of the introducer sheath into the AVF. The selected balloon catheter was then inserted across the stenosis using the guide-wire; this was assisted by fluoroscopy. The balloon was inflated with a pressure inflation syringe until it opened up fully (ie until the waist of the stenosis impinged on the balloon). Inflation was sustained for 60 seconds and the process was repeated two or three times. Heparin infusion was started immediately for 24 hours followed by oral aspirin 150 mg/day as maintenance prophylaxis against thrombosis.

After PTA, a set of arteriovenous fistulograms

was again performed to document the result of the angioplasty. The PTA was considered technically successful if the degree of residual stenosis was less than 30% as visualised using the fistulogram. A clinically successful PTA procedure was defined as a reduction of venous dialysis pressure to less than 100 mm Hg (for venous stenoses) and/or a reduction of arterial inflow (negative) pressure to less than 75 mm Hg while maintaining a dialysis blood flow rate of more than 150 mL/min.

#### **Results**

Eleven patients (eight men, three women; mean age,  $43.0 \pm 11.5$  years; duration on haemodialysis, 50 months [median, 18 months]) underwent a total of 12 PTA procedures for symptomatic stenosis of their AVF as shown on their fistulogram. The mean follow-up duration was  $15.2 \pm 11.4$  months (range, 2-42 months). The sites of stenosis and their treatment outcome are shown in the Table.

Seven anastomotic and five venous stenotic lesions were detected among the 11 patients who were all receiving maintenance haemodialysis via a native AVF in their forearms. They presented with abnormal dialysis pressures with physical evidence of stenosis. Four had elevated venous dialysis pressures, six had low arterial inflow pressures, while one (patient H) had both abnormal venous dialysis and arterial inflow pressures. Conclusions relating to recirculation could not be made since recirculation was not routinely tested. Nine of the 11 patients received a Doppler ultrasound scan which showed areas of turbulent blood flow in the AVF, suggestive of the presence of stenosis. All 11 patients underwent a fistulogram to delineate the exact anatomical location of the stenosis. No correlation was found between the presence of stenosis and any of the demographic characteristics of the patients such as age, sex, or duration on dialysis.

Percutaneous transluminal angioplasty performed in eight patients (73%) was deemed to have both technical and clinical success (as defined in the Methods). One of these patients (patient G) had an apparently successful procedure but developed thrombosis 1 month later; another (patient I) had a technically but not clinically successful PTA. Two patients (patients D and H) had fistula thrombosis almost immediately after the procedure and required surgical revision. Apart from acute fistula thrombosis as described, none of the patients displayed any major complications from the procedure. Two patients had different problems and treatment outcomes.

**Table. Sites of stenosis and treatment outcome**

Patient	Sex/age (years)	Underlying disease	Duration on haemodialysis before PTA* (months)	Site of stenosis	Outcome
A	M/19	Chronic glomerulonephritis	22	A <sup>†</sup>	Successful
B	M/46	PKD <sup>‡</sup>	2	V <sup>§</sup>	Successful; recurrent stenosis 9 months later; had another successful PTA
C	M/44	HSP <sup>  </sup>	129	A	Successful
D	M/38	IgA nephropathy	136	V	Acute thrombosis
E	M/41	FSGS <sup>¶</sup>	6	A	Successful
F	M/55	Chronic glomerulonephritis	43	V	Successful; thrombosis 28 months later
G	F/31	Lupus nephritis	8	A	Successful; thrombosis 1 month later
H	F/54	Unknown	180	V	Acute thrombosis; surgical revision needed
I	F/58	Diabetes mellitus	18	A & V	Technical success; clinical failure
J	M/48	Diabetes mellitus	4	A	Successful
K	M/36	Unknown	5	A	Successful

\*PTA percutaneous transluminal angioplasty

<sup>†</sup>A anastomotic lesion or lesions close to the anastomosis, distal to the arterial needle

<sup>‡</sup>PKD polycystic kidney disease

<sup>§</sup>V stenosis along the venous limb

<sup>||</sup>HSP Henoch-Schönlein purpura

<sup>¶</sup>FSGS focal sclerosing glomerulonephritis

### Patient A

A 19-year-old young man with chronic glomerulonephritis had been receiving haemodialysis via an AVF in his left forearm since 1994. In March 1996, he was found to have a poor arterial inflow of 125 mm Hg (acceptable limit, <75 mm Hg). The fistulogram revealed 90% stenosis just distal to the anastomosis (Fig 1); PTA was carried out 1 week later and was considered technically and clinically successful (Fig 1). The patient recovered satisfactory AVF haemodynamics and did not develop any further problems with haemodialysis.

### Patient B

A 46-year-old man who had polycystic kidneys started maintenance haemodialysis via an AVF that had been created in his left forearm since 1995. Two months later, he had high venous dialysis pressure (150-200 mm Hg; acceptable limit, <100 mm Hg). A long segment of narrowing that resembled a chain of beads was demonstrated in the venous limb on the fistulogram (Fig 2). Percutaneous transluminal angioplasty was carried out by placing the angioplasty balloon at contiguous locations so that the entire length of the stenosed segment was dilated. There was a satisfactory technical and clinical outcome. The lesions recurred 9 months later, and the patient underwent a second successful PTA.

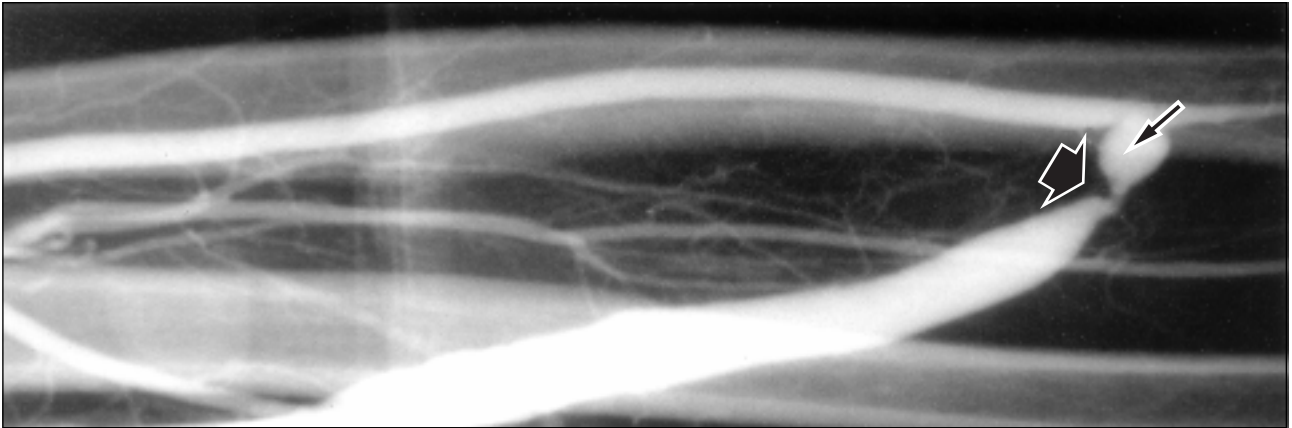
### Discussion

Establishing and maintaining vascular access in haemodialysis patients are important prognostic factors for patient survival. Indeed, the loss of vascular access remains one of the most challenging problems confronting nephrologists. Stenotic lesions of native and synthetic fistulae are the most common anatomical causes of thrombosis and account for approximately 85% of cases of fistula dysfunction.<sup>2</sup> In a small percentage of cases, thrombosis is caused by hypotension, inadvertent external compression, trauma, or infection.

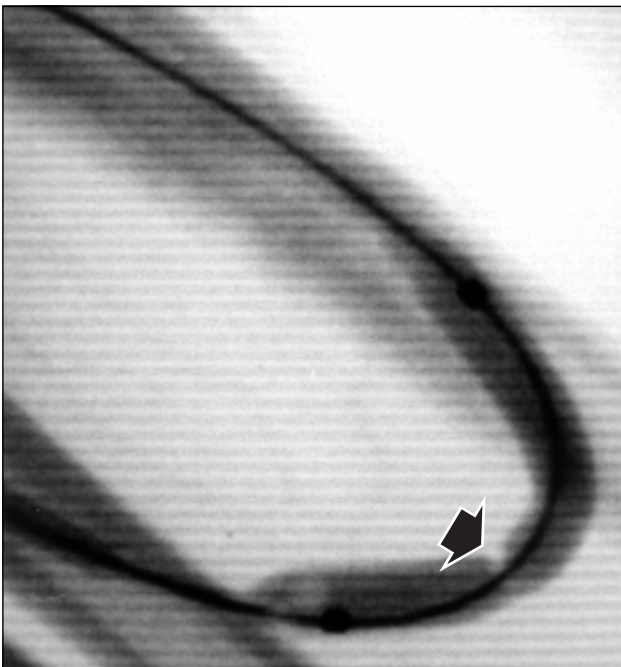
The prospective identification and correction of stenoses are of great importance in decreasing fistula thrombosis rates.<sup>3</sup> Only by doing this can fistula function and longevity be maintained. Methods to detect high-grade stenoses include the use of clinical indicators,<sup>4</sup> the objective measurement of venous dialysis pressure<sup>3</sup> and urea/non-urea recirculation,<sup>5</sup> and colour Doppler ultrasonography.<sup>6</sup>

Venous stenoses have traditionally been corrected surgically, but this extends the fistula further up the involved extremity, thereby minimising future vascular access sites. Transcatheter techniques have, in

1a.



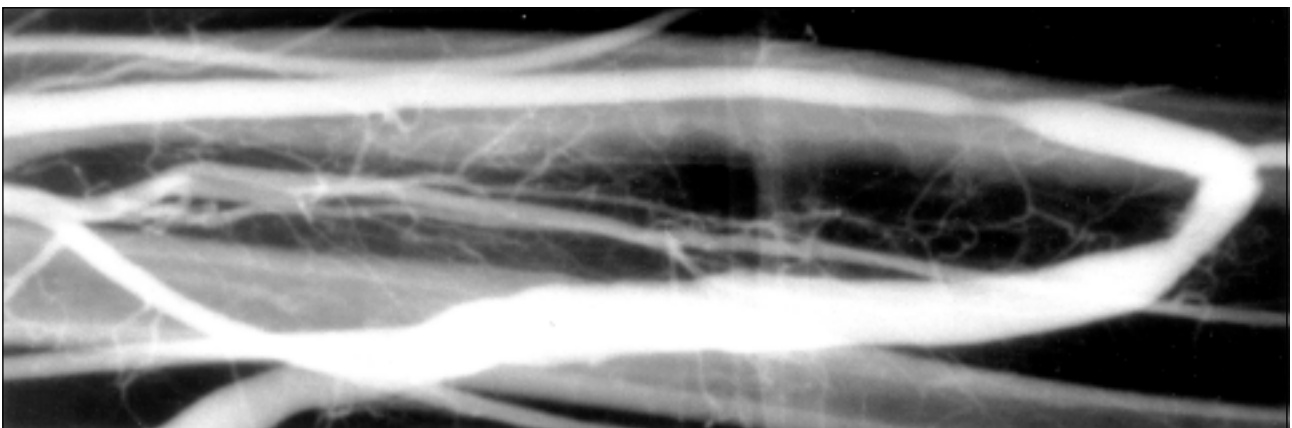
1b.



1c.



1d.



**Fig 1. Fistulograms showing various stages of percutaneous transluminal angioplasty: patient A**  
(1a) balloon dilatation of a stenosis (large arrow) which was adjacent to the arteriovenous fistula (small arrow); (1b) balloon inflation with a 'waist' (impression cast on balloon by stenosis) [arrow] at the stenotic site; (1c) balloon inflation with the waist fully opened up; (1d) removal of stenosis after angioplasty

recent years, made it possible to treat these lesions percutaneously, and PTA is an excellent means of correcting venous stenosis in both native and synthetic fistulae.<sup>7</sup> It has the advantages of being a shorter procedure than surgery, inciting less stress and discomfort to patients, obviating the need for prolonged hospitalisation, having a lower chance of infection, sparing the patient's veins, and, in selected cases, enabling immediate dialysis without the need for a temporary central venous catheter.

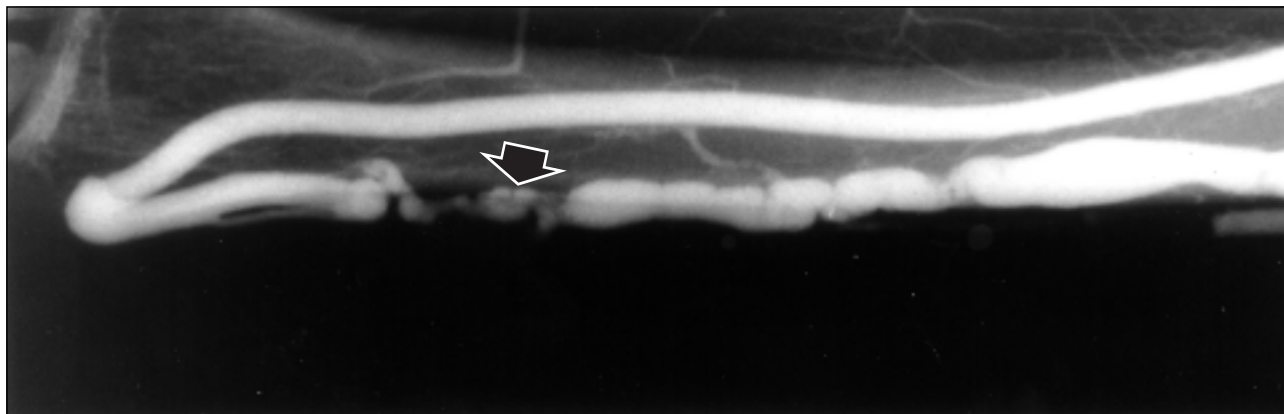
The pathogenesis of venous stenosis is not fully understood. Stenoses are produced by neo-intimal proliferation, which has been attributed to the effects of elevated venous pressure and turbulent blood flow.<sup>8,9</sup> Turmel-Rodrigues et al<sup>10</sup> reported that two thirds of stenoses occur distal to the arterial needle in the anastomotic area, while the remaining third occurs in the venous limb proximal to the arterial needle. In our series, anastomotic stenoses account for about 58% (7 of 12) of the lesions; this contrasts with synthetic arteriovenous grafts, where most of the lesions are at the venous anastomosis (Table). The success rate of PTA varies in different centres. In general, the cumulative primary patency is in the range of 70% to 80%, 40% to 60%, and 30% to 40% at 3, 6, and 12 months,

respectively.<sup>7,11</sup> Although PTA and surgery have comparable initial success rates, recurrence is invariably more frequent after the former.<sup>3,7</sup> Multiple PTA procedures, however, are possible upon a single lesion in a given fistula, thereby prolonging its life span without extension of the fistula further up the arm.

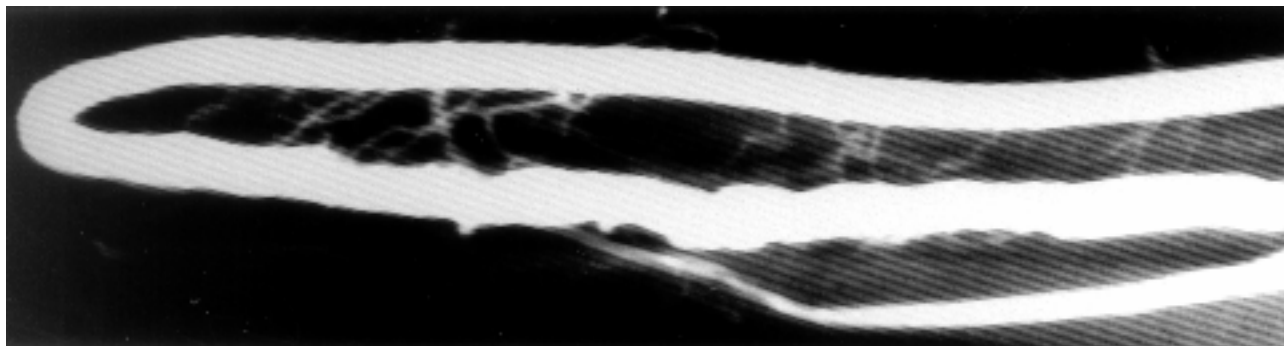
Complications arising from PTA are rare. In one series<sup>10</sup> involving 147 PTA procedures, the overall morbidity was 4.8% with one immediate rupture, four delayed pseudo-aneurysms, and two patients with peri-procedural bacteraemia. In contrast, the most common complication in our series was immediate loss of access due to acute thrombosis, despite the intra-operative delivery of heparin followed by its infusion postoperatively and the use of antiplatelet prophylaxis. In fact, despite years of research, there is currently no consensus with regard to the use of anticoagulation prophylaxis for PTA. While most centres would administer heparin 2000 to 4000 U intravenously during PTA procedures, the long-term use of antiplatelet agents such as low-dose aspirin or sulphinpyrazone has been favoured by only some,<sup>12</sup> and disputed by others.<sup>13</sup>

In conclusion, this study confirms the efficacy of PTA in the treatment of vascular access stenosis in the

2a.



2b.



**Fig 2. Fistulograms showing various stages of percutaneous transluminal angioplasty: patient B** (2a) balloon dilatation of a stenotic segment (arrow) on the venous limb of a dialysis fistula; (2b) removal of stenosis after angioplasty

local haemodialysis population. Elevated dialysis blood line pressure can be the first sign of fistula stenosis. Although our series is small, we have nevertheless demonstrated that the concerted efforts of nephrologists, interventional radiologists, and surgeons are the key to maintaining and prolonging vascular access survival in this group of patients.

## References

1. Brescia MJ, Cimino JE, Appel K, Hurwich BJ. Chronic hemodialysis using venipuncture and a surgically created arteriovenous fistula. *N Engl J Med* 1966;275:1089-92.
2. Fan PY, Schwab SJ. Vascular access: concepts for the 1990's [editorial]. *J Am Soc Nephrol* 1992;3:1-11.
3. Schwab SJ, Raymond JR, Saeed M, Newman GE, Dennis PA, Bollinger RR. Prevention of hemodialysis fistula thrombosis. Early detection of venous stenoses. *Kidney Int* 1989;36:707-11.
4. Gray RJ, Horton KM, Dolmatch BL, et al. Use of Wallstents for haemodialysis access-related venous stenoses and occlusions untreatable with balloon angioplasty. *Radiology* 1995; 195:479-84.
5. Windus DW, Audrain J, Vanderson R, Jendrisak MD, Picus D, Delmez JA. Optimization of high-efficiency hemodialysis by detection and correction of fistula dysfunction. *Kidney Int* 1990;38:337-41.
6. Dousset V, Grenier N, Douws C, et al. Hemodialysis grafts: color Doppler flow imaging correlated with digital subtraction angiography and functional status. *Radiology* 1991;181: 89-94.
7. Beathard GA. Percutaneous transvenous angioplasty in the treatment of vascular access stenosis. *Kidney Int* 1992;42: 1390-7.
8. Valji K. Transcatheter treatment of thrombosed hemodialysis access grafts. *AJR Am J Roentgenol* 1995;164:823-9.
9. Rekhter M, Nicholls S, Ferguson M, Gordon D. Cell proliferation in human arteriovenous fistulas used for hemodialysis. *Arterioscler Thromb* 1993;13:609-17.
10. Turmel-Rodrigues L, Pengloan J, Blanchier D, et al. Insufficient dialysis shunts: improved long-term patency rates with close hemodynamic monitoring, repeated percutaneous balloon angioplasty, and stent placement. *Radiology* 1993;187: 273-8.
11. Vorwerk D, Bucker A, Alzen G, Schurmann K, Ritzerfeld M, Gunther RW. Chronic venous occlusions in haemodialysis shunts: efficacy of percutaneous treatment. *Nephrol Dial Transplant* 1995;10:1869-73.
12. Abedon SI, Le H, Valji K, Bookstein JJ, Roberts AC. Effect of aspirin on hemodialysis graft patency [abstract]. *Radiology* 1993;189:175.
13. Domoto DT, Bauman JE, Joist JH. Combined aspirin and sulfipyrazone in the prevention of recurrent hemodialysis vascular access thrombosis. *Thromb Res* 1991;62:737-43.