



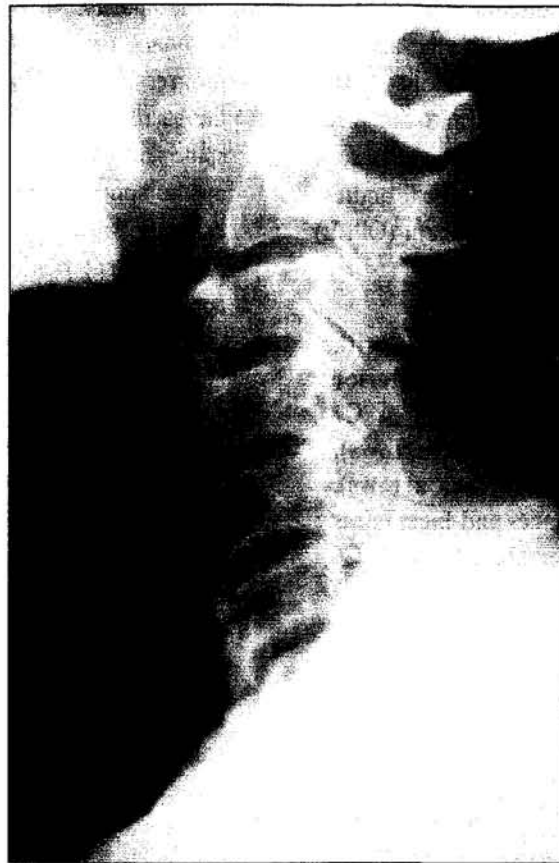Title	Radiological conference. Diffuse idiopathic skeletal hyperostosis (DISH)
Author(s)	Peh, WCG
Citation	Hong Kong Practitioner, 1997, v. 19 n. 5, p. 273-275
Issued Date	1997
URL	http://hdl.handle.net/10722/44660
Rights	Creative Commons: Attribution 3.0 Hong Kong License

RADIOLOGICAL CONFERENCE

Clinical History:

A 60-year-old man presented with a complaint of long-standing recurrent neck stiffness. There was no low back nor radiculopathic symptoms. Physical examination was normal except for mild limitation of neck movements, particularly during flexion and extension. A cervical spine radiograph was taken (**Figure 1**).

Figure 1: Lateral radiograph of the cervical spine



Answer
on
page 274

What is the diagnosis?

- a) Ankylosing spondylitis
- b) Osteoarthritis
- c) Fluorosis
- d) Psoriatic spondyloarthritis
- e) Diffuse idiopathic skeletal hyperostosis

This radiology case was prepared by:

Dr. W.C.G. Peh, Associate Professor,
Department of Diagnostic Radiology,
The University of Hong Kong,
Queen Mary Hospital.

RADIOLOGICAL CONFERENCE

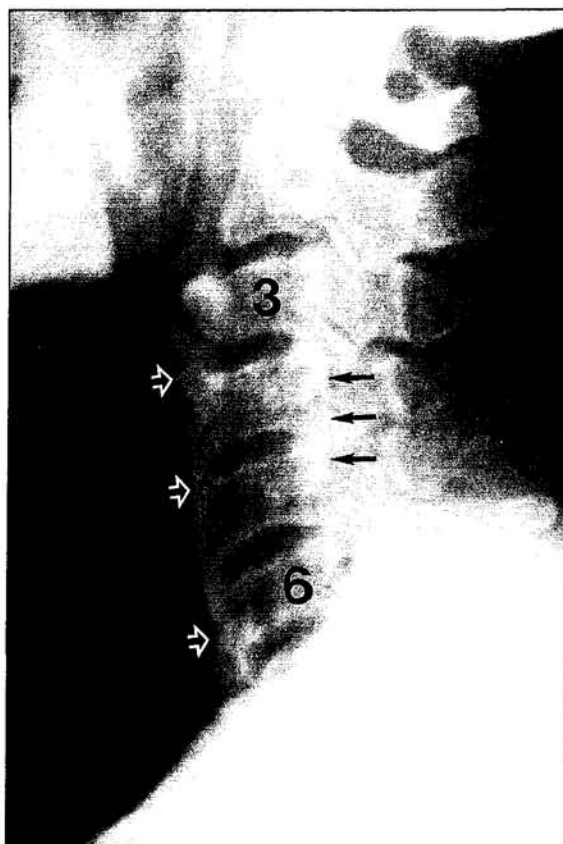
Answer:

e) Diffuse idiopathic skeletal hyperostosis (DISH)

Radiological findings

Flowing ossification along the anterior aspects of C3 to C7 vertebral bodies, corresponding to anterior longitudinal ligament ossification, is present. The intervertebral disc heights are preserved and the facet joints are intact. In addition, a dense linear band is seen posterior to C4 and upper half of C5 vertebral bodies, due to an ossified posterior longitudinal ligament (OPLL) (Figure 2).

Figure 2: This figure is identical to Figure 1 with addition of arrows. Flowing anterior ossification is seen linking C3 to C7 vertebral bodies (white open arrows). Dense OPLL is arrowed (black arrows). Intervertebral disc spaces and facet joints are normal. [3=C3 vertebral body; 6=C6 vertebral body]



Discussion

a. Ankylosing spondylitis

Ankylosing spondylitis is a form of seronegative inflammatory arthritis which affects the cartilaginous and synovial joints, and also manifests as an enthesopathy. It typically occurs in young men and is characterized by intermittent back pain and progressive stiffness. The initial changes occur in the sacro-iliac joints, followed by the thoracolumbar spine and lumbosacral regions, eventually progressing up the spine to involve the neck. Radiographically, extensive and symmetrical syndesmophytes bridge the vertebral bodies, leading to the 'bamboo spine' appearance. The interspinous processes, facet joints and costovertebral joints are also eventually ankylosed.^{1,2} These clinical and radiographic features are not present in our patient.

b) Osteoarthritis

Osteoarthritis (or degenerative joint disease) is probably the commonest form of arthritis encountered radiologically. On radiographs, the hallmarks of osteoarthritis are joint space narrowing, sclerosis and osteophytes. In the spine, osteophytes may arise as a result of shear stresses across a degenerative disc. The tip of these traction-type osteophytes do not usually protrude beyond the horizontal plane of the vertebral endplates.^{1,3} The orientation of the anterior cervical ossification, and lack of disc narrowing and sclerosis in our patient, excludes the diagnosis of osteoarthritis.

c) Fluorosis

Fluorosis results from long-term intake of large amounts of fluorine. This is usually due to fluorine in drinking water in endemic areas, although it can also be caused by therapy with sodium fluoride for osteoporosis. Radiographs show dense bone with cortex thickened at the expense of medulla, and calcification of ligaments, tendons and interosseous

RADIOLOGICAL CONFERENCE

membranes. Calcification of the sacrotuberous ligament is considered to be characteristic of fluorosis.^{1,3} This diagnosis can be discounted in our patient based on the history and radiographic features.

d) Psoriatic spondyloarthritis

Joint involvement in psoriasis occurs in 5% of patients and may antedate skin changes. Spondyloarthritis is one of five recognized clinico-radiological subtypes. In the spine, there is ossification of the paravertebral connective tissue which, unlike the syndesmophytes of ankylosing spondylitis, is separated from the edge of the vertebral body and disc. This ossification is usually large, coarse and asymmetrical. Bony ankylosis may occur. In the cervical spine, psoriasis may cause C1-C2 subluxation, mimicking rheumatoid arthritis.^{1,2} None of these radiographic patterns are seen in our case.

e) Diffuse idiopathic skeletal hyperostosis (DISH)

DISH, also known as ankylosing hyperostosis or Forestier's disease, is characterized by exuberant new bone formation linking the vertebral bodies. At least 4 contiguous vertebrae should be affected for this diagnosis to be considered. Ossification is typically located anterolaterally, causing undulating ossification of the anterior longitudinal ligament, outer fibres of the annulus fibrosus and the intervertebral disc itself. Ossified posterior

longitudinal ligament (OPLL) is recognized to be associated with DISH, occurring in 50% in one series.⁴ Unlike ankylosing spondylitis, the facet joints and posterior elements are not affected, and the sacro-iliac joints are normal. It is differentiated from osteoarthritis by the absence of disc space narrowing and sclerosis.

The cause of DISH is unknown. Postulated aetiologies include altered vitamin A metabolism and long-term ingestion of retinoid derivatives. It generally afflicts patients over the age of 50 years, being commonest in men.⁴ The condition by itself is usually clinically insignificant. When OPLL is present in the cervical spine, the bony protrusions may encroach upon the oesophagus, giving rise to discomfort during swallowing.² Large OPLL may also compromise the spinal canal diameter and compress the spinal cord, producing neurological signs and symptoms.⁴ ■

References

1. Chapman S, Nakielny R. *Aids to Radiological Differential Diagnosis*. 3rd ed. Balliere Tindall. London. 1995; pp 11, 85, 521, 589.
2. Forrester DM, Wesson JW. *The Radiology of Joint Disease*. W.B. Saunders, Philadelphia. 1973; pp 402-403, 409, 421-425.
3. Helms CA. *Fundamentals of Skeletal Radiology*. 2nd ed. W.B. Saunders, Philadelphia. 1995; pp 116-119, 160.
4. Resnick D, Niwayama G. Diffuse idiopathic skeletal hyperostosis (DISH): ankylosing hyperostosis of Forestier and Rotes-Querol. In: Resnick D. *Diagnosis of Bone and Joint Disorders*. 3rd ed. W.B. Saunders, Philadelphia. 1995; pp 1463-1495.