



Title	Radiological conference. Colonic obstruction due to sigmoid tumour
Author(s)	Peh, WCG; Chu, KW
Citation	Hong Kong Practitioner, 1997, v. 19 n. 3, p. 149-152
Issued Date	1997
URL	http://hdl.handle.net/10722/44658
Rights	Creative Commons: Attribution 3.0 Hong Kong License

RADIOLOGICAL CONFERENCE

Clinical History:

A 68-year-old man presented with a three-week history of abdominal pain and increasing constipation. He noticed weight loss of 10 pounds over this period and occasional bleeding per rectum. On examination, his abdomen was distended and diffusely tender, hyperactive bowel sounds were auscultated and blood staining was noted on rectal examination. Supine (**Figure 1**) and erect (**Figure 2**) abdominal radiographs were performed.

Figure 1: Supine abdominal x-ray

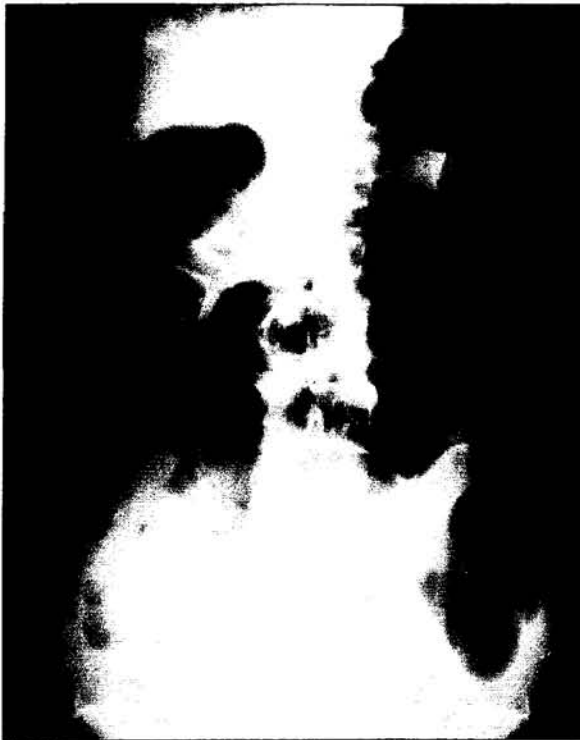
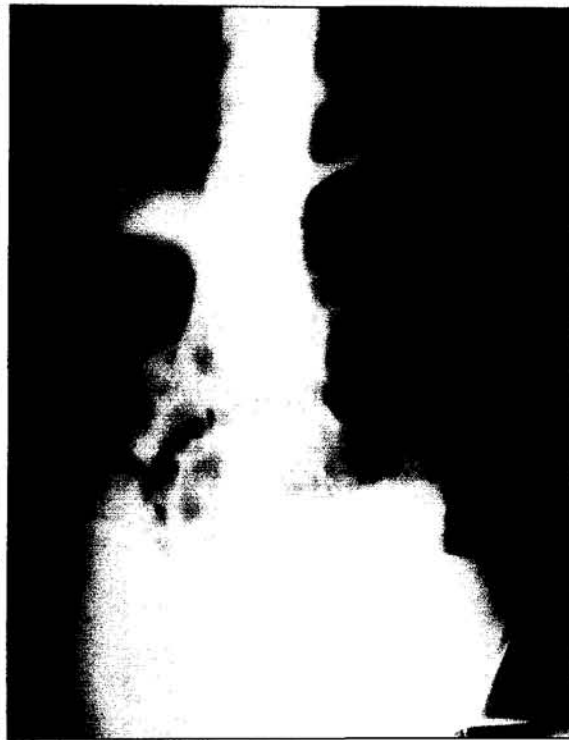
Figure 2: Erect abdominal x-ray



Answer
on
page 150

What is the diagnosis?

- a) Colonic obstruction due to sigmoid tumour
- b) Paralytic ileus
- c) Toxic megacolon
- d) Sigmoid volvulus
- e) Small bowel obstruction secondary to adhesions

This radiology case was prepared by:

Dr. W.C.G. Peh, Associate Professor,
Department of Diagnostic Radiology.

Dr. K.W. Chu, Consultant,
Department of Surgery,
The University of Hong Kong,
Queen Mary Hospital.

RADIOLOGICAL CONFERENCE

Answer:

- a) Colonic obstruction due to sigmoid tumour

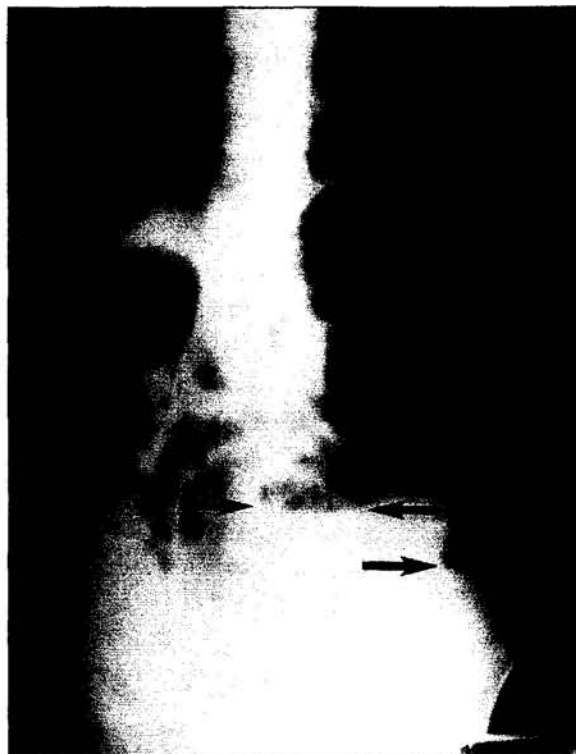
Radiological findings

The supine radiograph (Figure 3) shows loops of air-filled dilated bowel distributed mainly around the periphery of the abdomen. The bowel loops have a haustral pattern. On the erect radiograph (Figure 4), air-fluid levels are seen within the dilated colon. In both radiographs, there is paucity of gas in the left iliac fossa, distal to the dilated descending and proximal sigmoid colon.

Figure 3: Figure is identical to Figure 1 with addition of arrows. Loops of dilated colon are distributed in the periphery of the abdomen (arrowheads). There is a paucity of gas at the site of obstruction (star)

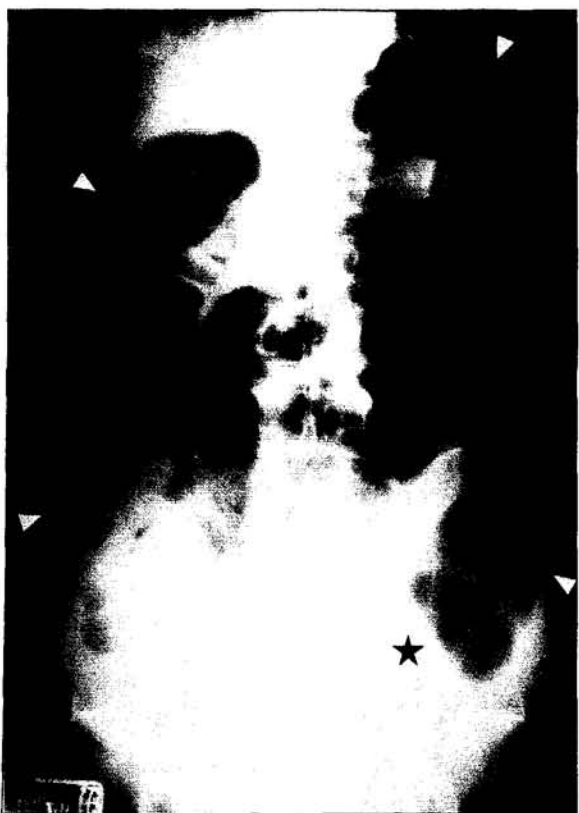

Figure 4: Figure is identical to Figure 2 with addition of arrows. Air-fluid levels are demonstrated within the bowel loops (arrows), indicative of obstruction



Discussion

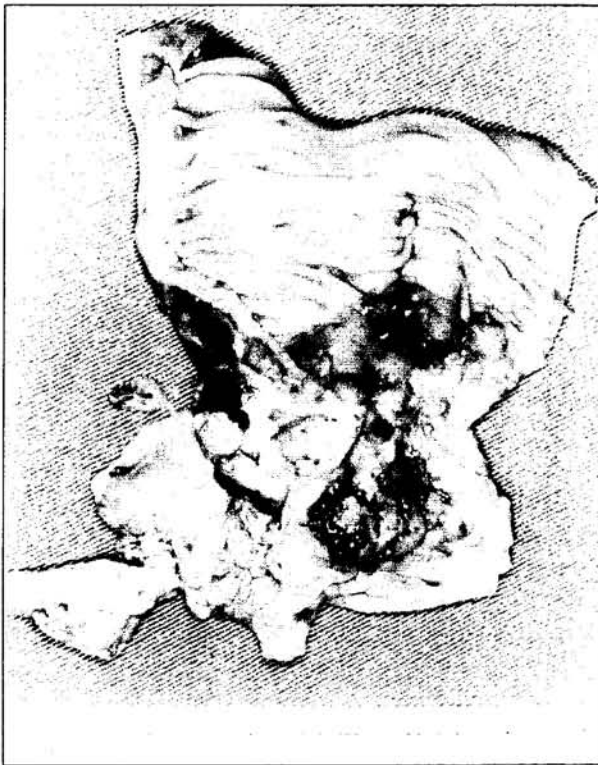
Urgent fibre-optic sigmoidoscopy confirmed the presence of an obstructing tumour 15 cm from the anal orifice. At laparotomy, a large rectosigmoid carcinoma causing gross colonic distension and obstruction was found. Tumour resection (Figure 5) and primary anastomosis were performed. The patient made an uneventful recovery.

The radiographic diagnosis of intestinal obstruction depends on demonstration of dilated bowel loops proximally, and collapsed or non-dilated bowel distal to the point of obstruction. It is important to determine whether the obstructed intestine is small or large bowel, or both types. Differentiating features include distribution, size, number and markings of the bowel

RADIOLOGICAL CONFERENCE

loops. The dilated colon is usually distributed in the periphery of the abdomen, exceeds 5 cm in width, and consists of a few loops with a relatively large radius. Large bowel has haustra which often produces a thick, incomplete transverse band shadow across the bowel.¹

Figure 5: Resected specimen shows a large fungating tumour at the rectosigmoid junction



There are three recognized patterns of colonic obstruction, depending on the competency of the ileocaecal valve.² In type IA obstruction, the ileocaecal valve is competent, with dilatation being confined to the large bowel. With time, the small bowel distends progressively against the closed ileocaecal valve, giving the type IB appearance. The significance of both these type I obstructions is the massive caecal distension produced, with risk of ischaemia and perforation. In type II obstruction, the ileocaecal valve is incompetent, hence back pressure from the colon leads to small bowel distension.² The commonest cause of large bowel obstruction is carcinoma, 60% of which are situated in the sigmoid colon.¹

Paralytic ileus

Paralytic ileus may be difficult to distinguish from large bowel obstruction as fluid and gas also accumulates in dilated small and large bowel in this condition. The pathogenesis is however due to cessation of peristalsis, which may be caused by a variety of conditions. Common causes include post-operation, peritonitis and electrolyte imbalance.¹ In our patient, this diagnosis can be excluded from the clinical history and auscultatory findings.

Toxic megacolon

Toxic megacolon is a fulminant form of colitis which carries an increased risk of morbidity and mortality. Radiographically, the bowel is grossly dilated with mucosal islands due to oedema and sloughing. The presence of intra-mural gas indicates imminent perforation.³ These changes are most often seen in the transverse colon and were not present in our patient.

Sigmoid volvulus

Sigmoid volvulus is classically caused by twisting of the sigmoid loop around its mesenteric axis, and usually occurs in an acute-on-chronic fashion. Radiographically, it forms a huge inverted U-shaped loop, with its apex being located under the left hemidiaphragm or at the level of the 10th thoracic vertebra. The two limbs of the gas-filled anastomotic loop converge inferiorly to the left iliac fossa. None of these features were present in this case.

Small bowel obstruction secondary to adhesions

Radiographic changes usually develop within 3-5 hours following small bowel obstruction. In contrast to colonic obstruction, dilated loops of small bowel are usually distributed centrally in the abdomen, are 3-5 cm in diameter, consist of several loops with each having a relatively small radius, and have valvulae conniventes.¹ The erect radiograph shows hoop-shaped loops with

RADIOLOGICAL CONFERENCE

multiple air-fluid levels at various heights. A 'string-of-beads' appearance may be seen on the supine film, as a result of pockets of air trapped between the valvulae conniventes in largely fluid-filled bowel. Most obstructions in the small bowel are due to either adhesions or strangulated hernia.⁴ In our patient, this diagnosis can be excluded on clinical and radiographic grounds. ■

References

1. Field S. The acute abdomen. In: Sutton D (ed). *Textbook of Radiology and Imaging*. 4th ed. Churchill Livingstone, Edinburgh. 1987; pp 929-957.
2. Love L. Large bowel obstruction. *Semin. Roentgenol.* 1973; 8: 299-322.
3. Chapman S, Nakielny R. *Aids to Radiological Differential Diagnosis*. 3rd ed. W.B. Saunders, London. 1995; pp 247.
4. Bartram CI, Kumar P. The acute abdomen. In: *Clinical Radiology in Gastroenterology*. Blackwell Scientific, Oxford. 1981; pp 217-220.



CUMULATIVE HIV/AIDS STATISTICS IN HONG KONG

香港愛滋病毒感染及愛滋病統計數字

Updated 31 December, 1996
截至一九九六年十二月三十一日

		TOTAL 總數	(AIDS) 愛滋病人數
SEX 性別	Male 男	683	(225)
	Female 女	93	(20)
ETHNICITY 種族	Chinese 華裔	534	(183)
	Non-Chinese 非華裔	242	(62)
ROUTES OF TRANSMISSION 傳染途徑	Sexual Contacts 性行為	630	(214)
	- Heterosexual 異性	389	(127)
	- Homosexual 同性	195	(67)
	- Bisexual 雙性	46	(20)
	Injecting Drug Users 注射毒品人仕	14	(4)
	Blood/Blood Products Recipients 輸入血液/血製品人仕	66	(14)
	Perinatal 母嬰傳播	4	(2)
	Undetermined 不詳	62	(11)
	TOTAL 總數	776	(245)

Enquiries may be directed to the AIDS Unit (Telephone: 2780 8622)