



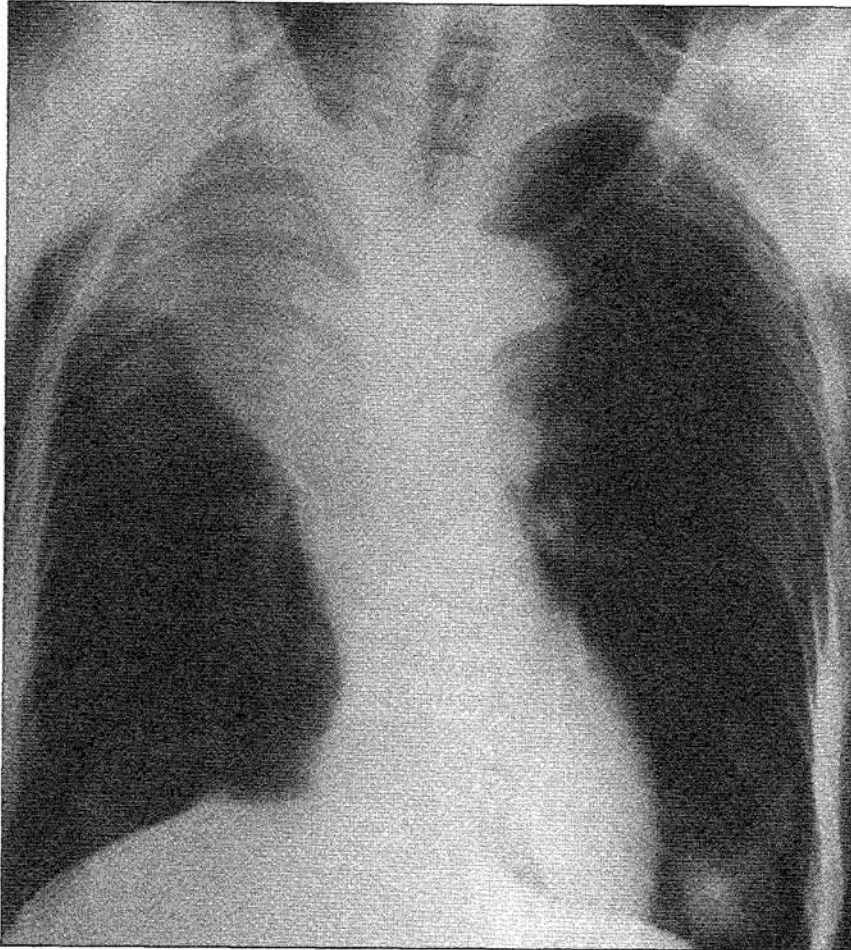
Title	Radiological conference. Right upper lobe collapse due to bronchogenic carcinoma
Author(s)	Peh, WCG
Citation	Hong Kong Practitioner, 1996, v. 18 n. 8, p. 423-426
Issued Date	1996
URL	http://hdl.handle.net/10722/44651
Rights	Creative Commons: Attribution 3.0 Hong Kong License

RADIOLOGICAL CONFERENCE

Clinical History:

A 71-year-old woman presented with dyspnoea and cough. She also had recent weight loss and anorexia.

Figure 1: Frontal chest radiograph



Answer
on
page 425

What is the diagnosis?

- a) Right upper lobe collapse due to bronchogenic carcinoma
- b) Lung infarction
- c) Progressive massive fibrosis
- d) Radiation pneumonitis
- e) Lobar pneumonia.

This radiology case was prepared by:

Dr. Wilfred C.G. Peh, Associate Professor,
Department of Diagnostic Radiology,
The University of Hong Kong,
Queen Mary Hospital.

(Continued on page 425)

RADIOLOGICAL CONFERENCE

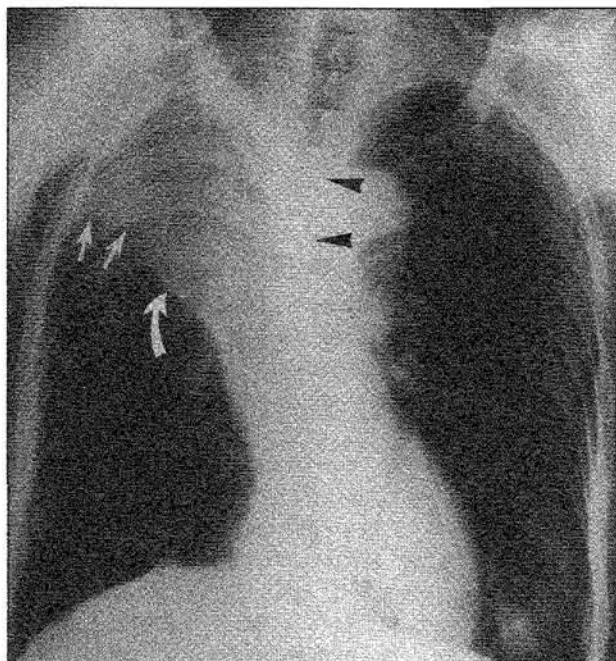
Answer:

- a) Right upper lobe collapse due to bronchogenic carcinoma.

Radiological findings

The frontal chest radiograph (Figures 1 and 2) shows a homogeneous opacity in the upper zone of the right lung field. It has a sharply-defined lower border formed by elevation of the horizontal fissure. Other evidence of volume loss includes deviation of the trachea to the right and compensatory hyperinflation of the right middle and lower lobes. The cause of the right upper lobe collapse was a proximally-located bronchogenic carcinoma, which produces the reverse S-shaped curve (S sign of Golden) seen on the frontal radiograph.

Figure 2: This figure is identical to Figure 1 with addition of arrows. The displaced horizontal fissure (small white arrows) forms the upwardly-convex lower border of the collapsed right upper lobe. Bulging of the medial end of the displaced horizontal fissure, from mass effect of the causative bronchogenic carcinoma (curved arrow) produces the S sign of Golden. Deviation of the trachea towards the right (arrowheads) is present



Discussion

Collapse (or atelectasis) refers to partial or complete loss of volume in a lung with diminished volume of air. In contrast, consolidation implies a reduced amount of air associated with normal lung volume. Paré and Fraser described 4 mechanisms of lung collapse, namely:

- (1) Passive collapse secondary to air or fluid collection in the pleural space;
- (2) Cicatrization collapse due to decreased lung compliance e.g. in pulmonary fibrosis;
- (3) Adhesive collapse from decreased alveolar surface tension e.g. respiratory distress syndrome; and
- (4) Resorption collapse resulting from bronchial obstruction where gases in the distal alveoli are continuously resorbed without being replenished. Bronchogenic tumours are an important cause of the last-mentioned type of collapse.

On chest radiographs, the only direct sign of collapse is displacement of the interlobar fissure. In right upper lobe collapse seen in our patient, the horizontal fissure, which is usually horizontally-orientated at the level of the anterior end of the right fourth rib, is elevated and bowed upwards. The upper half of the oblique fissure is displaced forwards, pivoting about the hilum; this latter sign may be appreciated on the lateral radiograph. Indirect signs of lobar collapse include:

- (1) loss of aeration, seen as increased density of the collapsed lung;
- (2) crowding of blood vessels in partial lobar collapse;
- (3) crowding of bronchi, best appreciated where an air bronchogram is present;
- (4) mediastinal displacement, evidenced by tracheal deviation in upper lobe collapse;
- (5) compensatory hyperinflation of the adjacent normal lung; and
- (6) elevation of the hemidiaphragm, usually seen in lower lobe collapse.

Lung collapse can be caused by various types of tumours, inflammatory conditions, mucous plugging from

RADIOLOGICAL CONFERENCE

different aetiologies, foreign body inhalation and miscellaneous diseases. In an older patient presenting with persistent lobar collapse or recurrent pneumonia, the possible diagnosis of bronchogenic carcinoma should always be considered first. The appropriate line of further investigation can then be pursued.

Lung infarction

Lung infarction occurs in 10-15% of patients with pulmonary thromboembolism. It is more likely to develop in the presence of cardiopulmonary disease with obstruction of pulmonary venous outflow. The lower lobes are predominantly affected. Chest radiographic signs are generally non-specific and include segmentally distributed consolidation, associated cavitation of infarcted lung, pleural effusion and elevation of the ipsilateral hemidiaphragm. A sign said to be highly characteristic but uncommonly seen is the "Hampton Hump". This refers to a pleural-based cone-shaped consolidation located in the costophrenic sulcus. In this case, the clinical presentation, lack of predisposing features, and site of lesion are against the diagnosis of lung infarction.

Progressive massive fibrosis (PMF)

PMF develops or progresses as a complication of pneumoconiosis. The lesion is located almost exclusively in either the posterior segment of the upper lobe or the superior segment of the lower lobe. PMF is usually seen as bilaterally distributed large confluent shadows, which migrate towards the hila with time. The remainder of the lungs have background nodular opacities due to pneumoconiosis. None of these features were present in this case.

Radiation pneumonitis

Acute changes of radiation pneumonitis are usually seen a month or so post-treatment, taking up to 6 months to appear. Consolidation, corresponding to shape of the radiation portal, develops initially. This is followed by fibrosis, which is complete by 9-12 months. If severe, fibrosis may produce significant volume loss and mediastinal shift. The diagnosis of radiation pneumonitis is based on the history and its characteristic radiographic shape, features not present in this case.

Lobar pneumonia

Lobar pneumonia is demonstrated radiographically as consolidation involving the air spaces of an anatomically recognizable lobe. The commonest causative organism is *Streptococcus pneumoniae*, which produces unilobar pneumonia. *Klebsiella pneumoniae* tends to involve multiple lobes, often cavitate and causes lobar enlargement. *Staphylococcal aureus* affects children, with pneumatoceles, empyema and pneumothorax being common complications. If the entire lobe is not involved or if there is associated segmental collapse, lobar pneumonia may superficially resemble lobar collapse. In this case, the lack of clinical features of infection and typical radiographic signs of an upper lobe collapse due to obstructing tumour excludes this condition. ■

References

1. Paré JAP, Fraser RG. Roentgenologic signs of atelectasis. In: Synopsis of Diseases of the Chest. Philadelphia: WB Saunders Co. 1983; pp 178-188.
2. Eisenberg RL. S sign of Golden. In: Atlas of Signs in Radiology. Philadelphia: JB Lippincott Co. 1984; pp 264.
3. Rubens MB. The pleura-collapse and consolidation. In: Sutton D (ed). A Textbook of Radiology and Imaging. 4th ed. Edinburgh: Churchill Livingstone. 1987; pp 392-420.
4. Dähnert W. Radiology Review Manual. 2nd ed. Baltimore: Williams & Wilkins. 1993; pp 262-263.