



Title	Pseudoarthrosis in ankylosing spondylitis
Author(s)	Peh, WCG; Luk, KDK
Citation	Annals Of The Rheumatic Diseases, 1994, v. 53 n. 3, p. 206-210
Issued Date	1994
URL	http://hdl.handle.net/10722/44648
Rights	Annals of the Rheumatic Diseases: the EULAR journal. Copyright © B M J Publishing Group.

Pseudoarthrosis in ankylosing spondylitis

Wilfred C G Peh, Keith D K Luk

Clinical history

A 32 year old Chinese man presented with a recent severe exacerbation of spinal pain at the thoraco-lumbar junction. He had a history of

chronic low back pain and stiffness, of gradual onset, for 10 years. He was living in China previously, receiving herbal applications and pain killers without relief. There were no peripheral joint symptoms. On examination, the patient had loss of normal lumbar lordosis. The thoracic and lumbar spine were completely stiff, with tenderness on percussion of the thoraco-lumbar junction. Chest expansion was reduced but the shoulders, hips and other peripheral joints showed satisfactory ranges of movement.

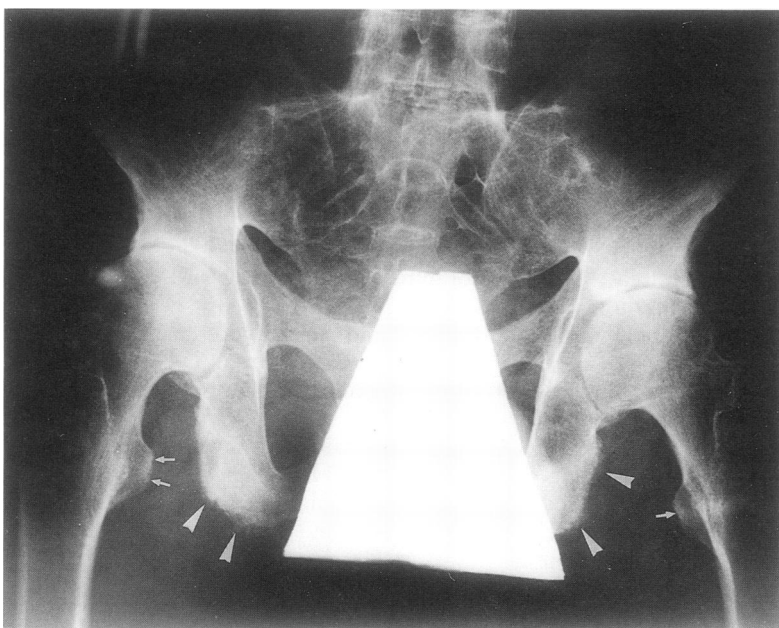


Figure 1 Pelvic radiograph shows fusion of both sacro-iliac joints. Whiskering is present at both ischial tuberosities and rami (arrowheads). Irregularity and sclerosis of the lesser trochanters are arrowed. Hip joints are concentrically narrowed.

Plain radiographic findings

Pelvic radiograph showed complete fusion of both sacro-iliac joints, consistent with grade IV sacro-iliitis (fig 1). Enthesopathic changes were manifested as whisker-like new bone formation at the ischial tuberosities as well as irregularity and sclerosis at both lesser trochanters. Hip joints showed concentric joint space narrowing.

Antero-posterior (AP) and lateral radiographs of the thoraco-lumbar spine demonstrated a widened disc space at T12/L1 level, with irregular sclerotic margins. There was a linear fracture line, with sclerotic rims, through the fused posterior elements at the same level. This lesion produced mild kyphotic angulation of an otherwise straight spine (fig 2A,B). The

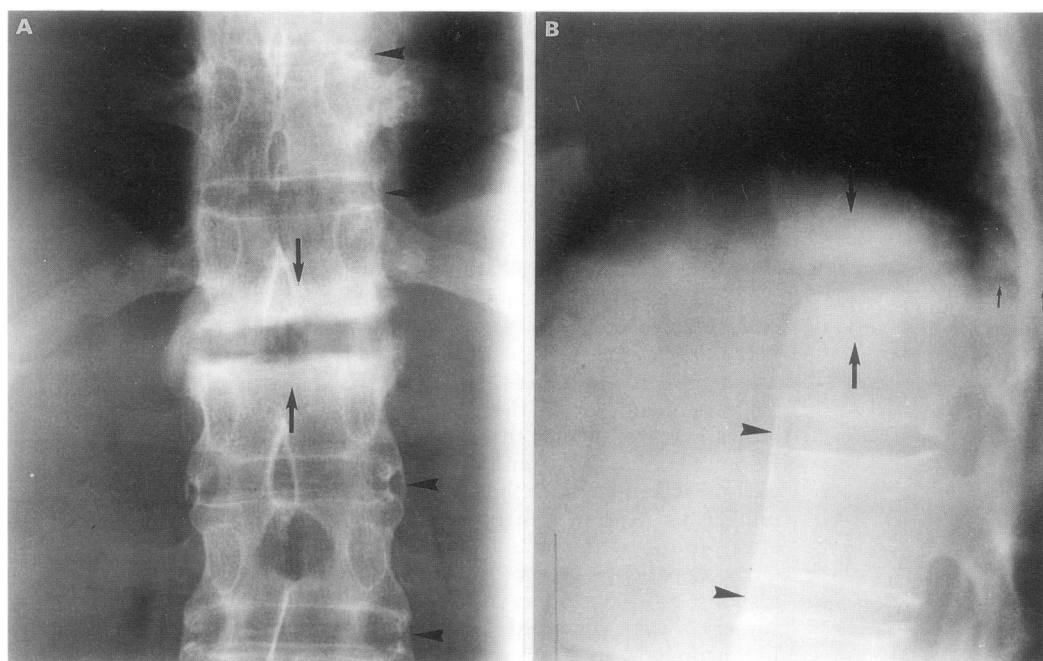


Figure 2 (A) AP and (B) lateral radiographs show T12/L1 pseudoarthrosis. There is destructive change at the intervertebral space with surrounding sclerosis (arrows). A transverse linear break continues through the fused posterior elements at the same level (small arrows). Syndesmophytes are present above and below this level (arrowheads).

Departments of
Diagnostic Radiology,
and Orthopaedic
Surgery,†
University of
Hong Kong,
Queen Mary Hospital
and Duchess of Kent
Hospital,
Hong Kong
W C G Peh
K D K Luk†

*Department of
Radiodiagnosis,
The Robert Jones and
Agnes Hunt Orthopaedic
Hospital,
Oswestry,
Shropshire SY10 7AG,
United Kingdom

Correspondence to:
Dr W C G Peh,
Department of Diagnostic
Radiology,
University of Hong Kong,
Queen Mary Hospital,
Hong Kong.

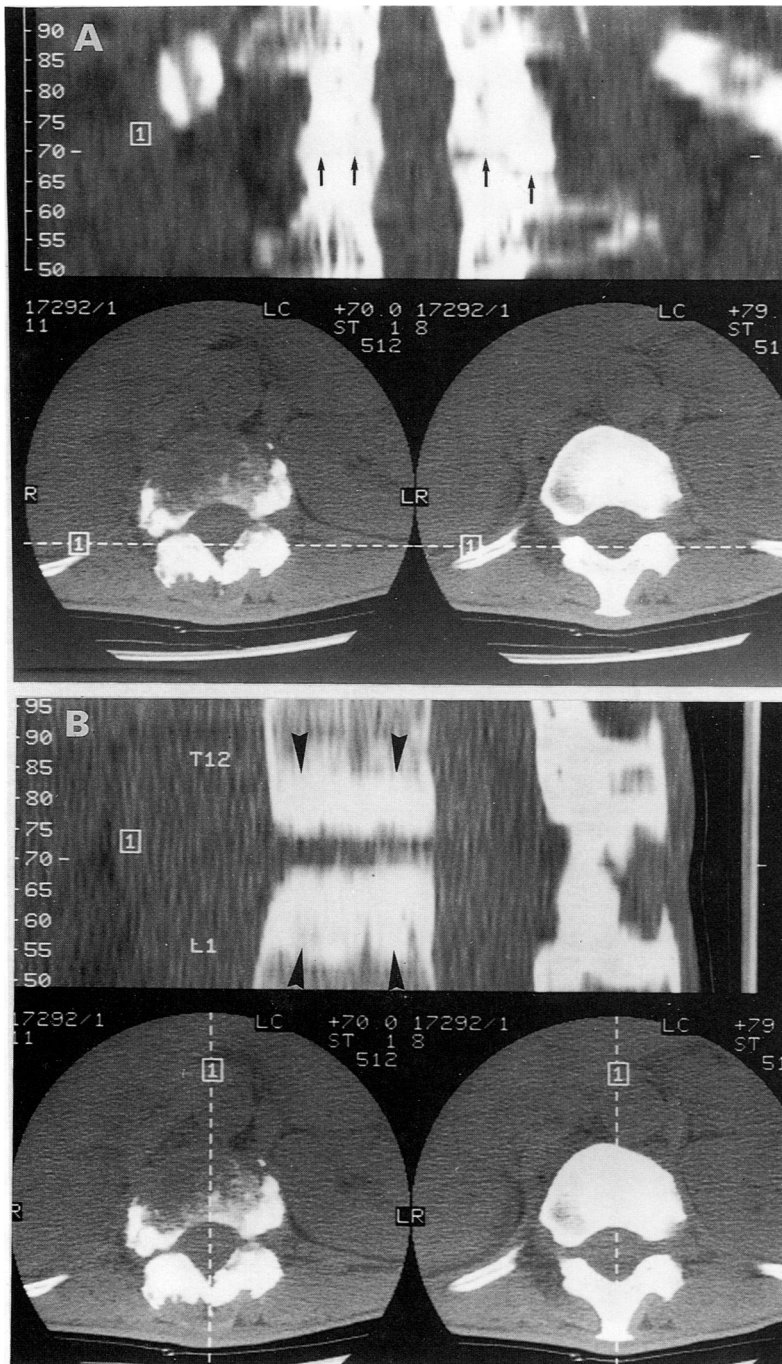


Figure 3 Reformatted (A) posterior coronal and (B) midline sagittal CT images show transverse linear breaks through the posterior elements bilaterally (arrows). The facet joints are fused, hypertrophied and sclerotic. Discovevertebral lesion with adjacent sclerosis is well demonstrated (arrowheads).

adjacent vertebral bodies above and below this unfused level had a 'squared' appearance, and were linked together by extensive syndesmophytes. The thoracic and lumbar facet joints were fused.

Differential diagnosis

This patient had all the characteristic radiographic features of advanced ankylosing spondylitis. The clinical picture was consistent with this diagnosis although the recent severe onset of pain together with the presence of the T12/L1 disco-vertebral lesion strongly suggested the development of a stress fracture, with non-union and a pseudoarthrosis. An infective process was the only alternative

diagnosis of the intervertebral disc changes. Conventional tomograms or computerised tomograms (CT) with reconstructions were therefore valuable in demonstrating posterior element defects typically seen in pseudoarthrosis (fig 3A,B), and excluding the paravertebral soft tissue mass of a pyogenic or tuberculous lesion.

Diagnosis: pseudoarthrosis in ankylosing spondylitis

The patient continued to have persistent thoraco-lumbar junction pain, and did not respond to conservative treatment. A T12/L1 anterior spinal fusion with resection of the pseudoarthrosis was performed (fig 4A,B). The patient's symptoms improved considerably after the operation. At follow up five years later, he was free of pain with no thoraco-lumbar spine tenderness. A repeat radiograph showed good healing of the previous site of pseudoarthrosis (fig 5).

Discussion

Spinal pseudoarthrosis is an important complication in patients with long-standing ankylosing spondylitis as it may result in severe disabling back pain, deformity and neurological deficit. It is a state of mobile non-union which occurs transversely through the disc space or less commonly, the vertebral body of a spinal segment. The classification of pseudoarthrosis as a 'non-inflammatory' type of destructive disco-vertebral (or Andersson) lesion is generally accepted (fig 6).¹ The presence of a posterior element defect from either a fracture or unfused facet joint is an essential component in the development of the anterior vertebral lesion.^{2,3} A recent paper has introduced the term 'pseudopseudoarthrosis' to describe extensive discovertebral destruction without fracture or posterior element pseudoarthrosis but having abnormal motion between two fused spinal segments.⁴ Recent authors are, however, in agreement with the 'mechanical' hypothesis for development of pseudoarthrosis.¹⁻⁸

Clinically, pseudoarthrosis should be suspected in patients who develop localised back pain in previously quiescent disease as spinal symptoms tend to diminish with progression of intervertebral ossification. There may or may not be a history of recent minor trauma. The thoraco-lumbar junction, being a site of stress concentration in an ankylosed spine, is the commonest site of pseudoarthrosis.³ The presence and degree of neurological deficit depends on the severity of pseudoarthrosis, with the possibility of quadriplegia and death occurring in cervical spine involvement.

Plain radiographic appearances of discovertebral destruction are often mistakenly diagnosed as an infective lesion, especially in Asian or Oriental patients in whom tuberculosis is not uncommon. Absence of osteophytes, presence of surrounding sclerosis and posterior element defect are useful

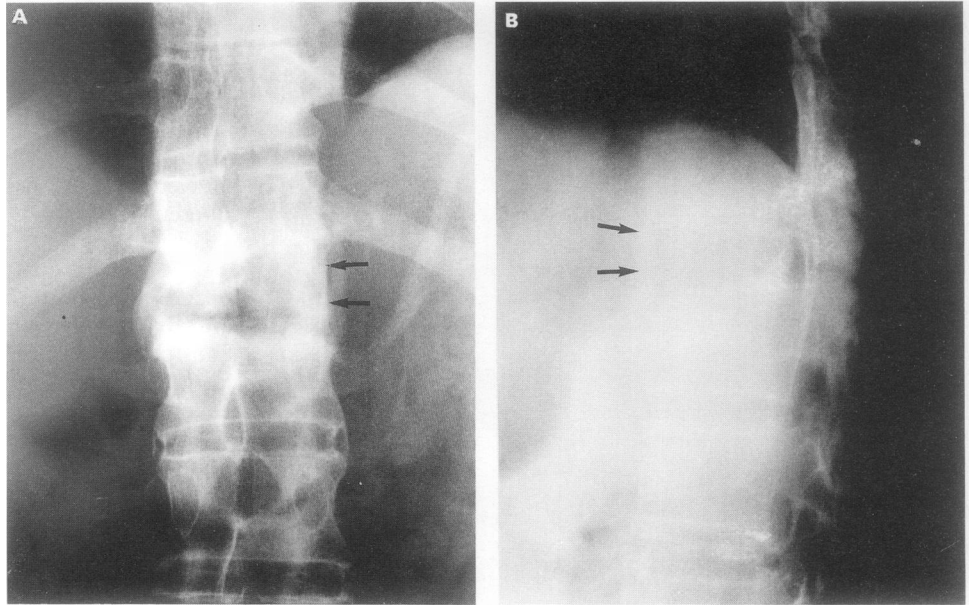


Figure 4 (A) AP and (B) lateral radiograph three weeks after anterior spinal fusion show satisfactory position of bone graft at the T12/L1 space (arrows).

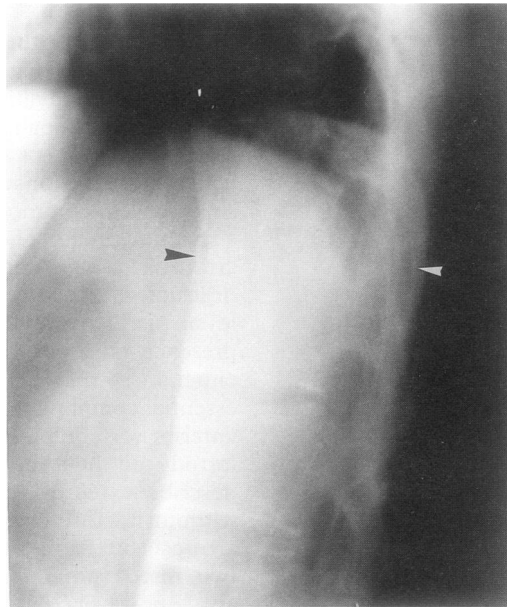


Figure 5 Radiograph taken three years post-surgery shows complete fusion of anterior and posterior elements at the T12/L1 junction (arrowheads).

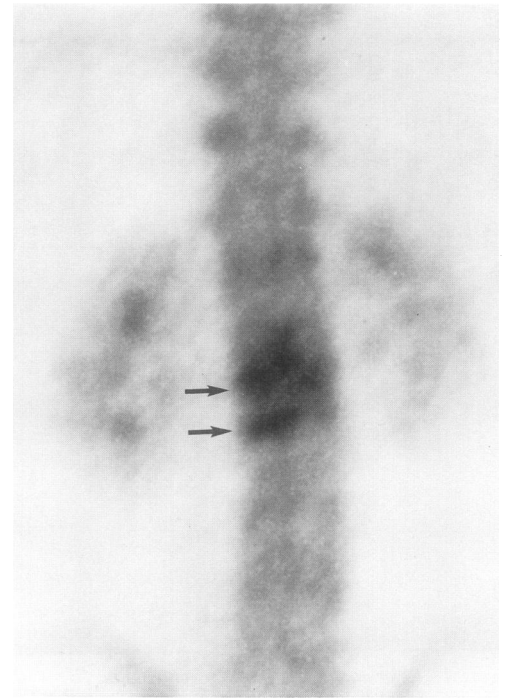


Figure 7 Technetium 99m bone scan (three hour image) shows two horizontally orientated areas of focal uptake at L1 and L2 vertebrae in a 25 year old man with ankylosing spondylitis (arrows). Pseudoarthrosis at this site was subsequently confirmed radiographically.

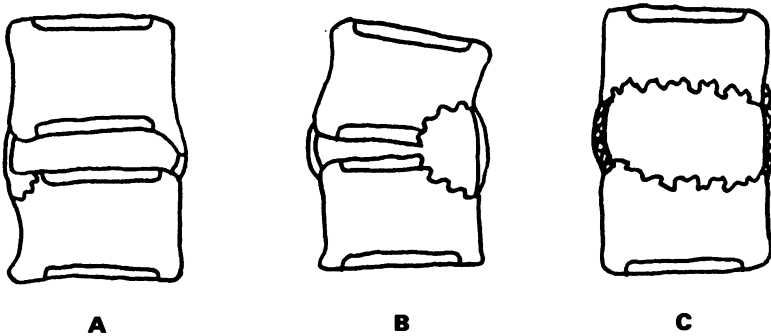


Figure 6 Types of disco-vertebral lesions in ankylosing spondylitis. (A) Romanus lesion is seen as a superficial anterior or antero-lateral corner erosion in very early disease, with healing and bony repair resulting in syndesmophyte formation. (B) 'Inflammatory' type of Andersson lesion occurs at a relatively early stage of disease as a circumscribed defect in the vertebral end plate, often with disc space narrowing, angular kyphosis and reactive sclerosis. (C) Pseudoarthrosis (or 'non-inflammatory' Andersson lesion) is characterised by prominent osteolytic destruction of adjacent vertebral bodies, variable subjacent sclerosis, an associated posterior element defect and occurs in advanced disease.

distinguishing features. Where pseudoarthrosis is suspected clinically, but is not apparent radiographically, isotope bone scans are very sensitive in demonstrating the lesion as areas of focal increased uptake on either side of a transverse spinal defect (fig 7). Isotope bone scans may also reveal a second clinically occult pseudoarthrotic segment.⁹ CT with 2D-reconstructions is superior to conventional tomography in differentiating posterior element fractures from mobile facet joints, demonstration of detailed features of pseudoarthrosis and associated spinal canal stenosis.¹⁰ Utilisation of MRI has recently been described

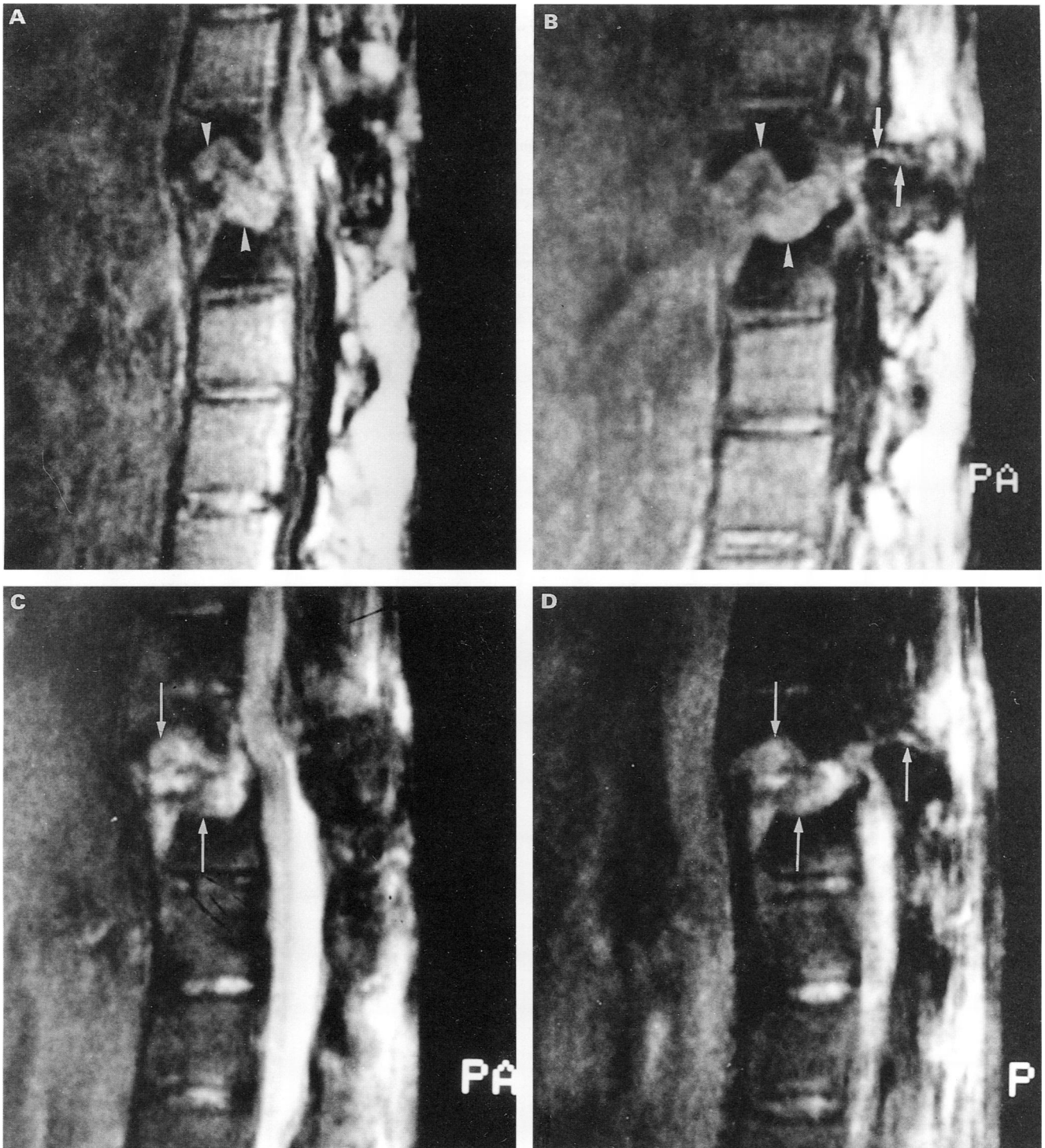


Figure 8 MRI of 30 year old man with ankylosing spondylitis. T1 weighted (A) mid sagittal and (B) parasagittal images demonstrate the pseudoarthrotic site as a band of intermediate intensity running obliquely through the T11/T12 disc space (arrowheads) and fused T11 posterior elements (arrows). There is loss of normal signal in the adjacent vertebral bodies. Corresponding T2 weighted images, figures (C) and (D), show linear high signal intensity (long arrows) consistent with vascularised fibrous tissue and organising exudate found in pseudoarthrosis.

and may be useful in the early detection of pseudoarthrosis (fig 8).¹¹

As well as the initial diagnosis and assessment of pseudoarthrosis, imaging plays an important role in determining progression or healing of lesions in patients undergoing conservative treatment. Plain radiographs, supplemented by CT, form the main modalities in assessing deformity, progressive osteolysis, or spinal canal compromise. In patients not responding to conservative management, surgical fusion of the painful unstable spinal segment may be necessary. Excision of pseudoarthrosis and

spinal fusion through an anterior approach is recommended.¹² Postoperatively, bony healing is also assessed radiologically. It is important to be able to detect refracture or non-healing of a posterior element defect, as an additional posterior surgical fusion may be required to stabilise the spine and prevent redevelopment of an anterior lesion.¹² Persistent postoperative back pain may signal recurrent pseudoarthrosis at a different site, also known as migrating pseudoarthrosis. These lesions are difficult to treat, the options being repeat surgery or external bracing.¹³

- 1 Dihlmann W, Delling G. Disco-vertebral destructive lesions (so-called Andersson lesions) associated with ankylosing spondylitis. *Skeletal Radiol* 1978; **3**: 10-6.
- 2 Rivelis M, Freiburger R H. Vertebral destruction at unfused segments in late ankylosing spondylitis. *Radiology* 1969; **93**: 251-6.
- 3 Chan F L, Ho E K W, Fang D, Hsu L C S, Leong J C Y, Ngan H. Spinal pseudoarthrosis in ankylosing spondylitis. *Acta Radiol* 1987; **28**: 383-8.
- 4 Furst S R, Kindynis P, Gundry C, Haghghi P, Sartoris D J, Resnick D. Pseudopseudoarthrosis in a patient with ankylosing spondylitis. *J Rheumatol* 1990; **17**: 258-62.
- 5 Cawley M I D, Chalmers T M, Kellgren J H, Ball J. Destructive lesions of vertebral bodies in ankylosing spondylitis. *Ann Rheum Dis* 1972; **31**: 345-58.
- 6 Pastershank S P, Resnick D. Pseudoarthrosis in ankylosing spondylitis. *J Can Assoc Radiol* 1980; **31**: 234-5.
- 7 Hunter T, Dubo H I C. Spinal fractures complicating ankylosing spondylitis. *Arthritis Rheum* 1983; **26**: 751-9.
- 8 Wu P C, Fang D, Ho E K W, Leong J C Y. The pathogenesis of extensive discovertebral destruction in ankylosing spondylitis. *Clin Orthop* 1988; **230**: 154-61.
- 9 Park W M, Spencer D G, McCall I W, Ward D J, Watson Buchanan W, Stephens W H. The detection of spinal pseudoarthrosis in ankylosing spondylitis. *Br J Radiol* 1981; **54**: 467-72.
- 10 Chan F L, Ho E K W, Chau E M T. Spinal pseudoarthrosis complicating ankylosing spondylitis: comparison of CT and conventional tomography. *AJR* 1988; **150**: 611-4.
- 11 Peh W C G, Ho T K, Chan F L. Pseudoarthrosis complicating ankylosing spondylitis - appearances on magnetic resonance imaging. *Clin Radiol* 1993; **47**: 359-61.
- 12 Fang D, Leong J C Y, Ho E K W, Chan F L, Chow S P. Spinal pseudoarthrosis in ankylosing spondylitis. Clinicopathological correlation and the results of anterior spinal fusion. *J Bone Joint Surg* 1988; **70B**: 443-7.
- 13 Ho E K W, Chan F L, Leong J C Y. Postsurgical recurrent stress fracture in the spine affected by ankylosing spondylitis. *Clin Orthop* 1989; **247**: 87-9.