



Title	Brainstem auditory evoked potentials after irradiation of nasopharyngeal carcinoma - Report on two cases with myelopathy of the brainstem
Author(s)	Lau, SK; Wei, WI; Choy, D; Sham, JST; Engzell, UCG
Citation	Journal Of Laryngology And Otology, 1988, v. 102 n. 12, p. 1142-1146
Issued Date	1988
URL	http://hdl.handle.net/10722/44632
Rights	Journal of Laryngology and Otology. Copyright © Cambridge University Press.

Clinical Records

Brainstem auditory evoked potentials after irradiation of nasopharyngeal carcinoma—Report on two cases with myelopathy of the brainstem

S. K. LAU*, W. I. WEI*, D. CHOY†, J. S. T. SHAM† and U. C. G. ENGZELL* (Hong Kong)

Abstract

Brainstem auditory evoked potentials (BAEP) were recorded in two patients with nasopharyngeal carcinoma (NPC) irradiated 14 and three years ago respectively and compared with 15 healthy controls. The patients had features of post-irradiation myelopathy of the brainstem with reduced gag reflex, unilateral vocal cord paralysis and fasciculation of the tongue. The first patient had a blind left eye. The second patient had quadriplegia. All ears revealed post-irradiation otitis media changes and mixed deafness. BAEP was not recognizable in the left ear of the first patient and was normal in the left ear of the second patient. Simultaneous electrocochleogram and BAEP were recorded from the right ear of the first case. The wave I-V latency interval were prolonged in both right ears. In the absence of local recurrence and brain secondaries, these BAEP changes are attributed to the post-irradiation myelopathy of brainstem.

Introduction

Radiotherapy is the primary mode of treatment of nasopharyngeal carcinoma (NPC). The whole auditory system including the middle ear, cochlea, auditory nerve, brainstem and auditory cortex is close to the irradiated volume for treatment of nasopharyngeal carcinoma, although not necessarily within the high dose target volume. Some radiation energy

falling on to the above structures is inevitable after an adequate dose of radiotherapy to the nasopharynx. Post-irradiation changes of the auditory system may lead to hearing impairment.

Radiation has a damaging effect on the middle ear (Gyorkey and Pollock 1960, Schuknecht and Karmody 1966, Elwany 1985), the cochlear and cochlear nerve fibre (Bohne *et al.*, 1985) and the temporal bone. Radiation myelopathy of brain-

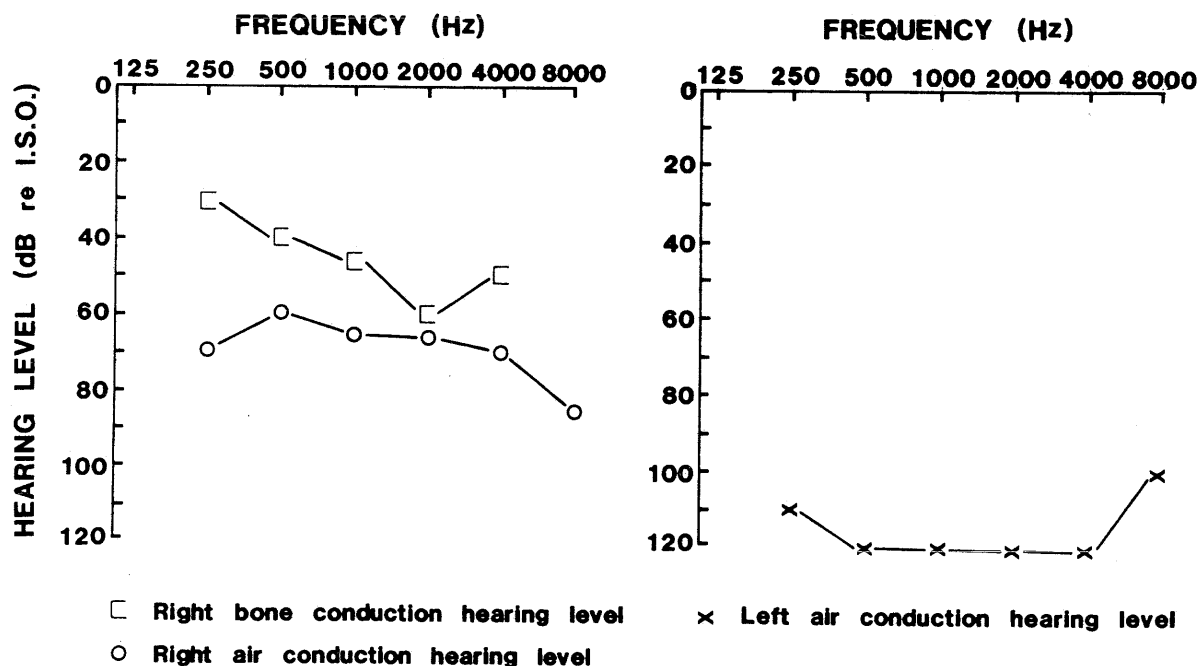


FIG. 1
Case 1: Pure tone audiogram.

* ENT Unit, Department of Surgery, University of Hong Kong.

† Department of Radiotherapy and Oncology, Queen Mary Hospital, Hong Kong.

stem is a recognized, rare late complication after radiotherapy for extracranial head and neck malignancy (Berge *et al.*, 1974; Manz *et al.*, 1979; Smith *et al.*, 1979). Brainstem auditory evoked potential (BAEP) is widely used for the diagnosis of brainstem pathology. The effects of radiotherapy for extracranial head and neck malignancy on brainstem auditory evoked potential has rarely been reported. Nightingale *et al.* (1984) recorded prolongation of wave I-V latency interval by 0.18 msec, in five patients, eight months after radiotherapy for unilateral extracranial head and neck malignancy. However, this prolongation is not statistically significant. They explained that post-irradiation brainstem myelopathy occurred in an idiosyncratic manner. Hulcrantz (1985) also demonstrated peak to peak latency differences in the BAEP from irradiated animals compared to non-irradiated ones indicating some type of disturbance in central auditory pathway after irradiation. The present report deals with the BAEP findings of two patients with myelopathy of the brainstem after radiotherapy of NPC. To our knowledge similar findings have not been reported in previous literature.

Case 1

A 58-year-old Chinese male presented with nasal obstruction

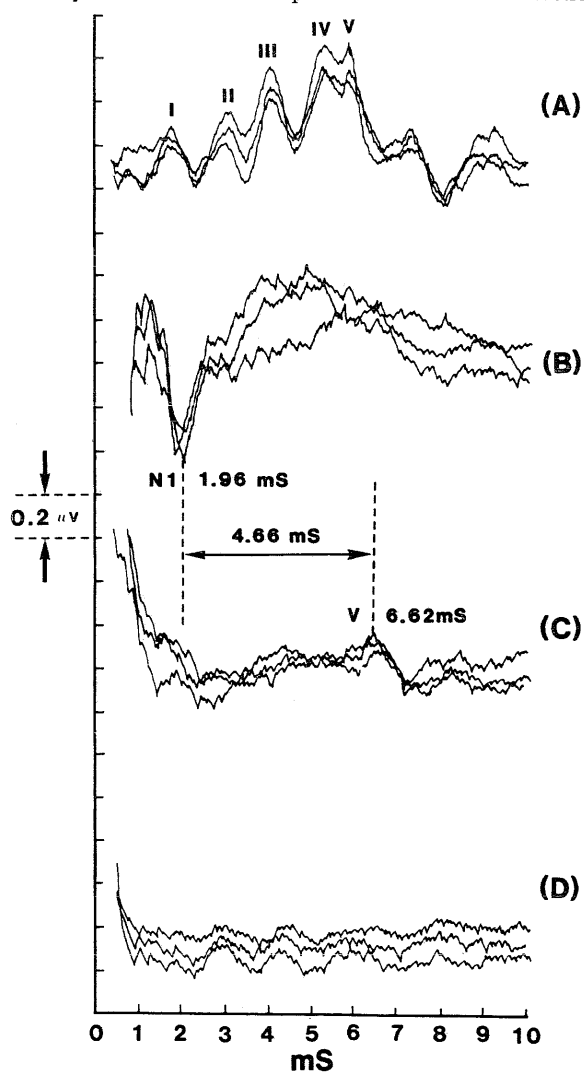


FIG. 2

- (A) BAEP of a normal 58-year-old Chinese male (70 dB nHL alternate click).
 (B) Case 1: E Coch G of right ear (extratympanic electrode; 90 dB nHL alternate click).
 (C) Case 1: Simultaneous BAEP of right ear.
 (D) Case 1: BAEP of left ear (90 dB nHL alternate click).

for two months. There was no cranial nerve palsy at time of presentation. A biopsy of the nasopharynx showed squamous cell carcinoma. He received radiotherapy to the nasopharynx and both sides of the neck in 1972. A total dose of 5320 rad was given in 25 fractions over 37 days. Estimated radiation dose at anterior surface of brainstem was 4900 rad.

The patient has remained free of recurrence. Immediately after radiotherapy, he noted that the vision in his left eye and the hearing in his left ear had deteriorated. He also noticed that there was a more gradual deterioration in the hearing of the right ear over the eight year period following radiotherapy. He did not have any otorrhoea. On physical examination, 14 years after irradiation, his neck was stiff due to the radiotherapy to the cervical region. His left eye was blind and the gag reflex was reduced. Clinical examination showed a left vocal cord paralysis and fasciculation of the whole tongue musculature; there was no detectable weakness in the limbs. Both tympanic membranes were thickened and intact. Serum TSH, thyroxine and cortisol levels were below normal. A pure tone audiogram showed a hearing loss as illustrated in Figure 1. Tympanometry showed an almost flat tracing with a compliance of 0.15 and 0.2 ml in the right and left ears respectively. A CT scan of the brain and chest radiograph, were normal. The BAEP was recorded using a Medelec MS92A signal averager. Alternate click generated by 100 μ sec current from Medelec ST10 stimulator were presented to patient through TDH-49P earphone at a rate of 10/sec. The high pass filter was 200 Hz and the low pass filter was 2 KHz. Response to 2048 alternate clicks at intensities of 90 dB nHL (normal hearing level) were recorded. The contralateral ear was masked with white band noise. Electrodes were placed on the vertex, and the ipsilateral and contralateral mastoid processes, the latter acting as ground electrodes. Three tests were done on each occasion to ascertain the reproducibility of the evoked potential. In the right ear of this patient, only wave V was recognizable. BAEP was therefore repeated with simultaneous electrocochleogram (E Coch G) recording using two channel facilities. An extratympanic electrode was placed close to annulus without anaesthesia. The latency of N1 of E Coch G was taken as latency of N1 of the BAEP.

Fifteen Chinese males aged from 45 to 60 with no otological complaints acted as control; the hearing level of the controls is shown in Table I. BAEP were recorded at 70 dB nHL. The BAEP findings of the controls and patient are shown in Tables II and III and Figure 2. The latency of N1 of the compound nerve action potential of the E Coch G of the right ear was 1.96 msec. Wave V latency was 6.62 msec. Thus the wave I-V latency interval of the right ear was 4.66 msec (prolongation is greater than 2.5 standard deviation). Wave II, III and IV were absent. There was no response on stimulation of the left ear.

Case 2

A 49-year-old Chinese male presented in 1983 with a 20 month history of blood-stained nasal discharge and left sided tinnitus. There was no neurological deficit at the time of presentation. Biopsy of the nasopharynx showed anaplastic squamous cell carcinoma. He received radiotherapy with a total dose of 5950 rad in 32 fractions over 40 days directed to the nasopharynx. The estimated dose at the anterior surface of brainstem was 5200 rad. Immediately after the radiotherapy, he noticed that his hearing was impaired. Two months after completion of radiotherapy, his right ear started to discharge. One year after completion of radiotherapy, he noticed weakness of all four limbs and his voice became weak and husky. Physical examination revealed right chronic suppurative otitis media with a posterior central perforation. The left tympanic membrane was intact but thickened. The gag reflex was reduced. Indirect laryngoscopy showed a right vocal cord paralysis. There was fasciculation of the whole tongue musculature.

TABLE I
MEAN AIR CONDUCTION THRESHOLD HEARING LEVEL OF CONTROL

Frequency dB	0.25K 21	0.5K 23	1K 21	2K 23	4K 41	8K 34
--------------	-------------	------------	----------	----------	----------	----------

TABLE II
LATENCY (MS) OF WAVES OF BAEP AND WAVE I-V LATENCY INTERVAL

Controls (n = 30 ears)	I 1.66 (0.34)*	II 2.70 (0.41)*	III 3.83 (0.35)*	IV 5.04 (0.39)*	V 5.80 (0.40)*	I-V 4.14 (0.40)*
Case I R Ear	1.96	N	N	N	6.62	4.66
Case I L Ear	N	N	N	N	N	N
Case II R Ear	1.82	N	N	N	6.93	5.11
Case II L Ear	1.99	N	4.35	N	6.30	4.31

N = Wave not recognizable.
In case I, latency of N1 of E Coch G is taken as wave I.
* Mean value (2 standard deviation).

TABLE III
AMPLITUDE (µV) OF WAVES OF BAEP

Controls (N = 30 ears)	I 0.23 (0.20)*	II 0.15 (0.14)*	III 0.22 (0.19)*	IV 0.08 (0.08)*	V 0.40 (0.23)*
Case I R ear	N	N	N	N	0.23
Case I L Ear	N	N	N	N	N
Case II R Ear	0.12	N	N	N	N
Case II L Ear	0.13	N	0.10	N	0.33

N = Wave not recognizable.
* Mean value (2 standard deviation).

ture, and weakness of all limbs. A pure tone audiogram showed a mixed deafness in both ears (Fig. 3). The compliance of the left ear was 0.25 ml. Computerized tomography of the brain and the base of skull, and chest radiograph, were normal. The clinical signs have remained static for the last two years and he has been free of recurrence since the radiotherapy. BAEP findings are shown in Tables II and III and Figure 4. On stimulation of the right ear, the latencies of waves I and V were 1.82 msec and 6.93 msec respectively, with a I-V wave interval of 5.11 msec (prolongation was greater than 4.5 standard deviation).

tion). Normal responses were obtained on stimulation of the left ear.

Discussion

The pons and medulla are only separated from the nasopharynx by the basiocciput. Radionecrosis of the pons and the medulla is a rare but recognized complication of radiotherapy for NPC. The interval between radiotherapy for head

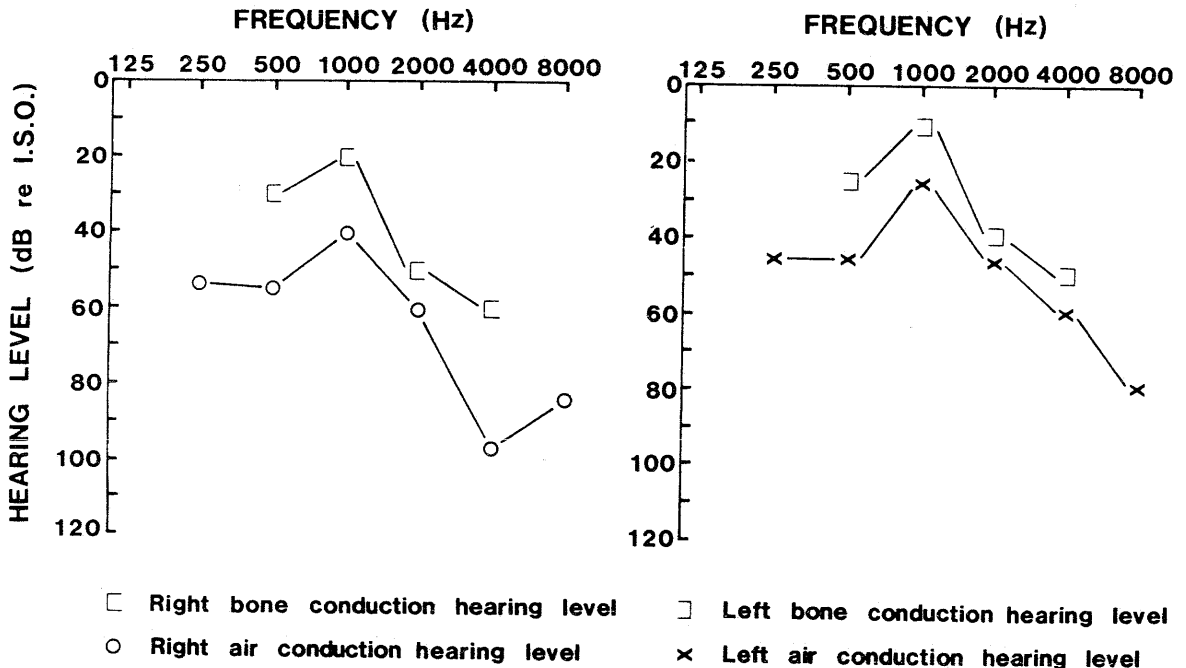


FIG. 3
Case 2: Pure tone audiogram.

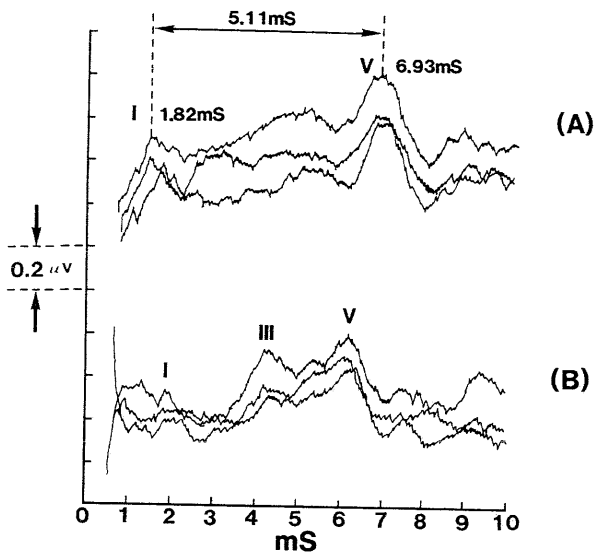


FIG. 4

Case 2: BAEP of right (A) and left (B) ear (90 dB nHL alternate click).

and neck malignancies and onset of symptom of radionecrosis of brain stem varies from three to 26 months (Manz *et al.*, 1979). Radionecrosis of the brainstem usually manifests itself as blindness, multiple cranial nerve palsies, hemiparesis, hemisensory deficit, and ataxia (Berge *et al.*, 1974; Manz *et al.*, 1979; Lampert and Davis, 1964).

Berge *et al.*, (1974) described four zones of irradiation reactions in the brainstem of a patient with oropharyngeal carcinoma. The most anterior zone, nearest to the centre of the irradiation field, showed complete necrosis with fibrosis, exudation, vessel wall degeneration and complete demyelination. Posterior to the above is a zone which received less radiation and showed intensive reactive changes with proliferation of astroglial cells; the blood vessels although dilated remained intact. There was partial demyelination. More posteriorly was a zone of mild reaction and then a zone of normal brain tissue which had received the least amount of radiation energy.

The irradiation injury to nervous tissue depends on the total dose of radiation, the size of the dose and the number of fractions (Safdari *et al.*, 1985). All the patients in reported cases of radionecrosis of the brainstem have died within seven months of the clinical onset of the signs of radiation damage. The radiation damage to the brainstem in our two patients were mild enough to allow them to survive.

Brainstem auditory evoked potentials can reflect abnormalities involving the brainstem reported previously in acoustic neuromas (Setlers and Brachmann, 1977), midbrain tumours, multiple sclerosis and brain death (Starr and Achor, 1975).

In multiple sclerosis, there is delay of the later waves of BAEP and a high test and retest variability and prolongation of Wave I-V interpeak latency interval (Robinson and Rudge 1977; Antonelli *et al.*, 1986).

In moderate cochlear deafness, wave I-V latency interval of BAEP elicited by high intensity click is within normal limits, whereas in some retrocochlear deafness, it is prolonged. In some subjects with hearing loss wave I can be absent and determination of wave I-V latency interval is therefore impossible. Under these circumstances simultaneous recordings of E Coch G and BAEP can be rewarding. Latency of N1 E Coch G can be regarded as that of wave I (Singh and Mason, 1981).

One of the four ears of the two patients had chronic otitis media with a dry central perforation. The other three ears had an intact but thickened tympanic membrane; the compliances

of these three were reduced. All the middle-ear changes were most probably due to the radiotherapy. In order to overcome the conductive hearing loss, the ears are stimulated with 90 dB nHL instead of 70 dB nHL which was used for the control group.

The first patient had unilateral blindness immediately after the radiotherapy probably due to radiation retinopathy (Brown *et al.*, 1982a) or radiation optic nerve myelopathy (Brown *et al.*, 1982b). He also had post-irradiation IXth, bilateral left Xth and bilateral XIIth cranial nerve neuropathy. His serum TSH and thyroxine and cortisol levels were reduced, features of post-irradiation hypothalamic pituitary axis dysfunction (Lam *et al.*, 1987). Therefore, it is inferred that the brain stem also had post-radiation changes. The second patient had a quadriplegia 12 months after radiotherapy caused by radiation myelopathy involving the cortico-spinal fibres which are situated in the anterior part of the brainstem. The right Xth and bilateral XIIth cranial nerves were also involved. Both patients had a prolonged wave I-V latency interval in their right ears indicating abnormalities in their brainstems.

As the patients showed features of post-irradiation myelopathy of the brain stem, we believe that the prolonged wave I-V latency interval is attributable to radiation-induced damage of the brainstem involving the auditory pathways. Probably the BAEP changes reflected the demyelination in brainstem of our two cases. Distinction between myelopathy due to radiotherapy and tumour recurrence is essential. In our two cases, tumour recurrence is most unlikely because both have survived without further treatment and there has been no deterioration of the neurological signs; this is supported by the normal CT scan findings.

References

- Antonelli, A. R., Bellotto, R., Bertazzoli, M., Busnelli, G. P., Nunez Castro, M., Felisati, G. and Romagnoli, M. (1986) Auditory brain stem response test battery for multiple sclerosis patients: evaluation of test findings and assessment of diagnostic criteria. *Audiology* 25: 227-238.
- Berge, G., Brun, A., Hakansson, C. H., Lindgren, M. and Nordberg, U. B. (1974) Sensitivity to irradiation of the brainstem. Irradiation myelitis in the treatment of a nasopharynx carcinoma. *Cancer* 33: 1263-1268.
- Bohne, B. A., Marks, J. E. and Glasgow, G. P. (1985) Delayed effects of ionizing radiation on the ear. *Laryngoscope* 95: 818-828.
- Brown, G. C., Shields, J. A., Sanborn, G., Augsburger, J. J., Savino, P. J. and Schatz, N. J. (1982a) Radiation retinopathy. *Ophthalmology (Rochester)* 89: 1494-1501.
- Brown, G. C., Shields, J. A., Sanborn, G., Augsburger, J. J., Savino, P. J. and Schatz, N. J. (1982b) Radiation optic neuropathy. *Ophthalmology (Rochester)* 89: 1489-1493.
- Elwany, S. (1985) Delayed ultrastructural radiation induced changes in human mesotympanic middle ear mucosa. *Journal of Laryngology and Otology* 99: 343-353.
- Gyorkey, J. and Pollock, F. J. (1960) Radiation necrosis of ossicles. *Archives of Otolaryngology* 71: 793-796.
- Hulcrantz, M. (1985) Structure and function of adult inner ear in mouse following prenatal irradiation. *Scandinavian Audiology (Suppl)* 24: 1-24.
- Lam, K. S. L., Tse, V. K. C., Wang, C., Yeung, R. T. T., Ma, J. T. C. and Ho, J. H. C. (1987) Early effects of cranial irradiation on hypothalamic-pituitary function. *Journal of Clinical Endocrinology and Metabolism* 64(3): 418-424.
- Lampert, P. W. and Davis, R. L. (1964) Delayed effects of radiation on the human central nervous system; 'Early and late' delayed reactions. *Neurology (Minneapolis)* 14: 912-917.
- Manz, H. J., Woolley, P. V. and Ornitz, R. D. (1979) Delayed radiation necrosis of brainstem related to fast neutron beam irradiation. Case report and literature review. *Cancer* 44: 473-479.
- Nightingale, S., Schofield, I. S. and Dawes, P. J. D. K. (1984) Visual, cortical somatosensory and brain stem auditory evoked potentials following incidental irradiation of the rhomben-

- cephalon. *Journal of Neurology, Neurosurgery and Psychiatry* **47**: 91-93.
- Robinson, K. and Rudge, P. (1977) Abnormalities of the auditory evoked potential in patients with multiple sclerosis. *Brain* **100**, **PTI**: 19-40.
- Safdari, G. H. H., Fuentes, J. M., Dubois, J. B., Alirezai, M., Castan, P. and Vlahovitch, B. (1985) Radiation necrosis of brain: time of onset and incidence related to total dose and fractionation of radiation. *Neuroradiology* **27**: 44-47.
- Schuknecht, H. F. and Karmody, C. S. (1966) Radionecrosis of the temporal bone. *Laryngoscope* **76**: 1416-1428.
- Selters, W. A. and Brackmann, D. E. (1977) Acoustic tumour detection with brain stem electric response audiometry. *Archives of Otolaryngology* **103** (4): 81-87.
- Singh, C. B. and Mason, S. M. (1981) Simultaneous recording of extratympanic electrocochleography and brainstem evoked responses in clinical practice. *Journal of Laryngology and Otolology* **95**: 279-290.
- Smith, B. M., McGinnis, W., Cook, J. and Latourette, H. (1979) Central nervous system changes complicating the use of radiotherapy for the treatment of a nasopharyngeal neoplasm in a diabetic patient. *Cancer* **43**: 2239-2242.
- Starr, A. and Achor, L. J. (1975) Auditory brainstem responses in neurological disease. *Archives of Neurology* **32**: 761-768.

Address for correspondence:
Mr Sai-kit Lau,
ENT Unit,
Department of Surgery,
University of Hong Kong,
Queen Mary Hospital,
Hong Kong.