



Title	Cephalometric norms for the upper airway in a healthy Hong Kong Chinese population
Author(s)	Samman, N; Mohammadi, H; Xia, J
Citation	Hong Kong Medical Journal, 2003, v. 9 n. 1, p. 25-30
Issued Date	2003
URL	http://hdl.handle.net/10722/44553
Rights	Creative Commons: Attribution 3.0 Hong Kong License

N Samman 岑立標
H Mohammadi
J Xia 夏 焯

Cephalometric norms for the upper airway in a healthy Hong Kong Chinese population

香港健康華人上呼吸道的顛測量規範

Objective. To obtain normative data for cephalometric measurements of the upper airway in the local Chinese population.

Design. Observational study.

Setting. University department and teaching hospital out-patient clinic.

Subjects and methods. Subjects included 74 healthy patients, 29 males (age range, 18-35 years) and 45 females (age range, 16-42 years), with normal skeletal facial profile, no history of snoring, sleep apnoea, upper airway disease, tonsillectomy or adenoidectomy, obesity, or pathology in the pharynx. Twenty cephalometric airway measurements, including size of the tongue, soft palate, nasopharynx, oropharynx, hypopharynx, and relative position of the hyoid bone and valleculae were obtained. Landmarks on cephalometric radiographs were digitised and measurements were made using a specially designed computer programme. Error analysis of measurements was performed and comparison of measurements according to sex was made.

Results. Significant sex dimorphism was seen for the majority of measurements, with the exception of minimal depth of the airway, oropharyngeal depth of the airway, and the soft palate angle with the hard palate.

Conclusion. A minimum sagittal dimension of the upper airway was evident despite differences in measurements between sexes. Findings from this study should be a useful reference for the assessment of sleep apnoea in the local population.

目的：量度本地華人上呼吸道顛測量的標準化數據。

設計：觀察研究。

安排：大學及教學醫院的門診部。

參與者及方法：參與者包括 74 名健康人士，其中 29 名為男性(年齡範圍，18-35 歲)，45 名為女性(年齡範圍，16-42 歲)；他們均有正常骨骼面輪廓，並沒有打鼾、睡眠窒息、上呼吸道疾病、曾切除扁桃腺或增殖腺、肥胖、或咽病等病歷。本研究量度了 20 個顛及上呼吸道的尺寸，包括舌頭、軟齶、鼻咽、口咽、及咽喉的大小，及舌骨與谷的相對位置。把顛測量放射照片的定點位置數碼化，並以特別設計的電腦程式取得量度數據。此外，進行了測量誤差分析，並按性別進行了數據比較。

結果：除了呼吸道的最小深度、口咽深度、及軟齶與硬齶角之外，大多數測量結果顯示有明顯的性別差異。

結論：儘管兩性的測量結果有所差異，上呼吸道的最小矢狀尺寸是清晰的。本研究結果對於評估本地人口的睡眠窒息症有參考意義。

Key words:

Cephalometry;
Mongoloid race;
Pharynx

關鍵詞：

顛測量法；
華人；
咽

Hong Kong Med J 2003;9:25-30

Oral and Maxillofacial Surgery, The
University of Hong Kong, Prince Philip
Dental Hospital, 34 Hospital Road,
Hong Kong

N Samman, FRCS (Edin), FDSRCS
H Mohammadi, MDS, FDSRCS
J Xia, DDS, PhD

Correspondence to: Prof N Samman

Introduction

Cephalometric radiographs have been used for many years to evaluate facial growth and development.^{1,2} Cephalometry enables analysis of dental and skeletal anomalies as well as soft tissue structures and form. Many studies have assessed the anatomic conformation of the upper airway with more sophisticated and expensive techniques, including cine-computed tomography,³ fluoroscopy,⁴ acoustic reflection,⁵ fiberoptic pharyngoscopy,⁶ and magnetic resonance imaging.⁷ Cephalometry is, however, less expensive, more useful,

easily achieved with reduced radiation, and correlates with other investigations such as computed tomography (CT) or somnofluoroscopy carried out during wakefulness or sleep.^{8,9} Cephalometric measurements of the posterior airway space, although a two-dimensional analysis, have proved very reliable in diagnosing pharyngeal volumes.^{10,11} Posterior airway space, as measured by lateral cephalometric radiography, was highly correlated with measurements using three-dimensional CT scan, with a 92% accuracy in predictability.¹²

Many authors have used cephalometry for assessment of the airway in craniofacial syndromes,¹³⁻¹⁶ in patients with obstructive sleep apnoea (OSA),^{11,16-23} and following orthognathic surgery,²⁴⁻²⁹ and for evaluation of the airway in various dentofacial deformities.³⁰⁻³² Understanding of the upper airway in normal subjects can assist management of OSA syndrome and in identifying potential sites of obstruction of the upper airway after surgical correction of dentofacial deformities.

Cephalometric measurements of the airway vary according to ethnic group and sex. There are very few reports of cephalometric analysis of the normal upper airway in the Chinese population—one in a northern Chinese group³³ and another in an unidentified Chinese group.³⁴ There may be, however, significant differences in body size between northern Chinese and southern Chinese populations. Therefore, the purpose of this study was to carry out a systematic, cephalometric evaluation of the upper airway in a large group of normal subjects in order to establish cephalometric reference values of the upper airway in the local (mainly southern Chinese) population.

Subjects and methods

Subjects

Male and female Hong Kong Chinese subjects were selected from a large pool of patients attending the Prince Philip Dental Hospital, University of Hong Kong, for dental treatment. Patients were interviewed and examined for the purpose of selection. The selection criteria included Hong Kong Chinese, normal visual harmony of facial and skeletal profile, and normal dental occlusion (Class I), with 2 mm to 4 mm of overbite and intact dental arch. Exclusion criteria included previous orthodontic treatment or corrective jaw (orthognathic) surgery, active periodontal disease, habitual snoring, habitual mouth breathing, obesity or assessed as clinically overweight, OSA, chronic respiratory disease, previous tonsillectomy and/or adenoidectomy, pathology in the area of study (eg nasopharyngeal carcinoma), and irradiation to the head and neck area.

Cephalometric analysis

Lateral cephalometric radiographs were taken using a standardised technique, with the jaw in centric relation and the teeth in occlusion, the lips relaxed, and the head in the natural head position. The subject stood with the sagittal

plane parallel to the film and with bilateral ear rods gently inserted into the external auditory meatus to stabilise the head position during exposure. Two types of X-ray machines were used. The older was a General Electric GE 100 (General Electric Dental Systems, Milwaukee, US) and the films used were Kodak Ortho-G 24x30 (Eastman Kodak Company, Rochester, US). Distance from the anode to the mid-sagittal plane of the patient was 150 cm, while distance from the mid-sagittal plane to the film was 13 cm. The newer machine was a Philips Orthoralix SD (Philips Medical Systems, Monza, Italy) and the film used Kodak Ortho-G 15x30 (Eastman Kodak Company, Rochester, US). The mid-sagittal plane to film distance was 15 cm with this machine. All films were processed under standardised conditions.

The magnification factors of the lateral cephalometric radiographs taken with the older and newer X-ray machines were measured separately, and corrected for the later cephalometric measurements on the processed films. The magnification factor was measured by the following formula:

$$M = (X' - X) / X$$

where X is the radiopaque ruler used when the radiograph was taken, and X' is the figure measured from the magnified ruler on the radiograph.

Landmarks and measurements

The reference points and lines used in analysis are shown in the Fig. Box 1 provides a description of the landmarks used, while Boxes 2a and 2b give descriptions of the measurements undertaken and the relevant abbreviations. The methods of measurement used were a modification of those used by Lyberg et al,^{20,21} and have been widely used in other studies.^{22,23,33}

Seventeen variables—including 12 linear distances, one angle, four area measurements, and three ratios of area values (Table)—were identified and calculated for each cephalometric radiograph on the basis of their clinical relevance in determining the patency of the nasopharyngeal, oropharyngeal, and hypopharyngeal airway space. The tongue was measured in sagittal length (VT), height ($H \perp VT$), and a defined sagittal area (TA). The soft palate was also measured in length (PM-U), thickness (SPT), and a defined sagittal area (SPA). The width of the upper airway space was measured in the sagittal plane at four levels: the nasopharynx (PM-UPW), oropharynx (U-MPW), hypopharynx (V-LPW), and the region of minimal airway space (PASmin). The position of the soft palate was represented by the angle (NL/PM-U) between its long axis (PM-U) and the nasal line (NL). In addition, the oral area (OA), nasopharyngeal area (NOPA), and three ratios of area values were calculated for further analysis.

All lateral cephalometric radiographs were scanned by a HP ScanJet 4C scanner. The image was visualised on a 1280x1024 non-interlaced monitor. The landmarks were

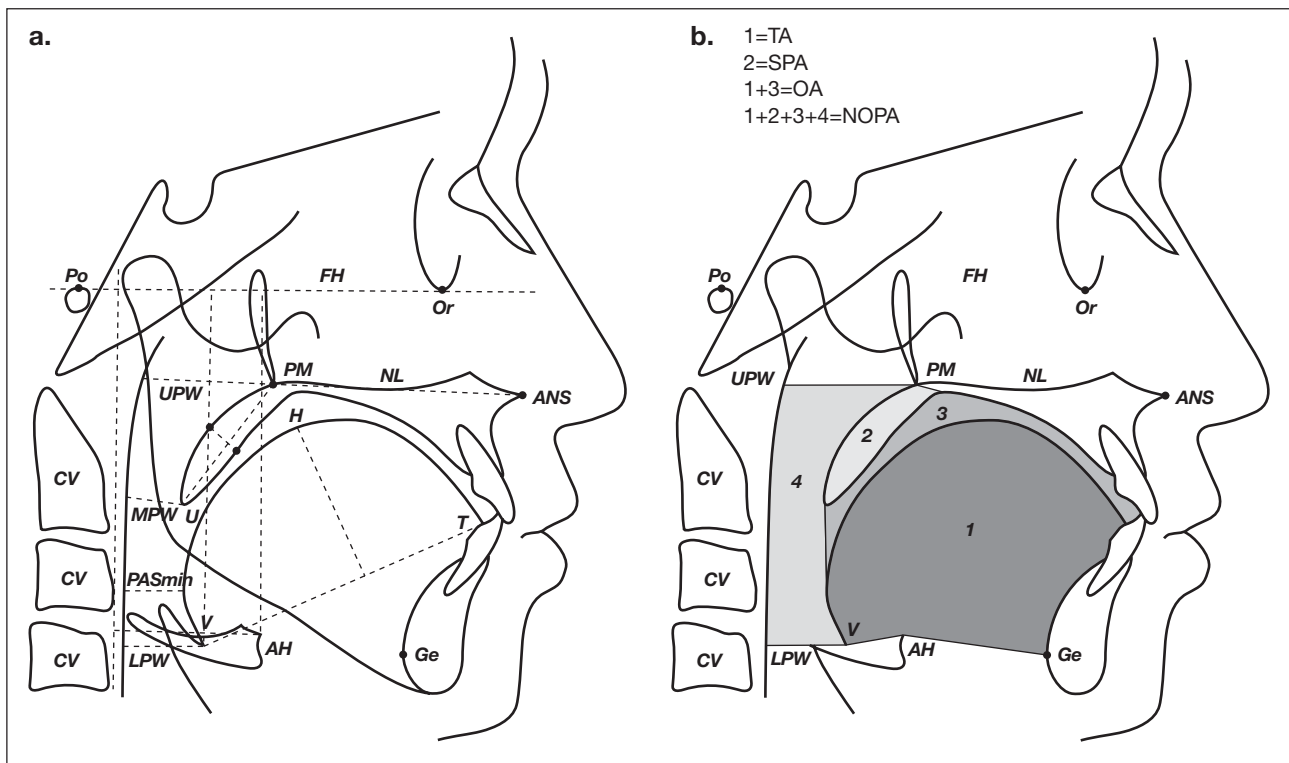


Fig. Diagrammatic representation of the oronasopharynx (sagittal view)

(a) Landmarks and reference lines used in the analysis of lateral cephalometric radiographs; and (b) area measurements used in the study. Abbreviations and descriptions of landmarks used are listed in Box 1, while definitions for measurements undertaken are listed in Boxes 2a and 2b

digitised, and the Frankfort plane was used as the horizontal plane during the measurements. Linear, angular, area, and ratio variables were measured and analysed by computer software designed for that purpose.³⁵ The digitisation and measurements were performed by the same investigator. The magnification factor was taken into account for each cephalometric radiograph. The computer used in this study was an IBM compatible 486/66 D2 CPU-based personal computer with 16 MB RAM.

Reliability and error analysis

A random sample of 30 scanned cephalometric tracings was selected and digitised. The measurements were completed twice on two separate occasions, 4 weeks apart, by the same investigator. The mean value of the variables measured on each of the two occasions were compared using paired *t* tests to detect any systematic error in measurements made.

Statistics

Cephalometric variables for male and female subjects were compared using the Student's *t* test and a P value less than 5% was considered significant. The statistical package used was the Statistical Package for Social Science (Windows version 6.0; SPSS Inc., Chicago, US).

Results

Twenty-nine males and 45 females were included in the study. Males ranged in age from 18 to 35 years, and females from 16 to 42 years. The results of the error analysis

Box 1. Landmarks used in cephalometric analysis

AH	Anterior hyoid, the most anterior and superior point on the body of the hyoid bone, representing the inferior part of the tongue
ANS	Anterior nasal spine, the tip of the median, sharp bony process of the maxilla
CV	Cervical vertebrae, the line overlying the anterior surface of the 2nd and 3rd cervical vertebrae was used
FH	Frankfort horizontal plane, line joining the orbitale to the porion
GE	Genial tubercle, representing the most posterior point of the mandibular symphysis and the antero-inferior part of the tongue
H	Superior part of the tongue, the most superior point of the tongue in relation to the line from V to T
LPW	Lower pharyngeal wall, intersection of the perpendicular line from V to the posterior pharyngeal wall
MPW	Middle pharyngeal wall, intersection of the perpendicular line from U to the posterior pharyngeal wall
NL	Nasal line, line between the anterior nasal spine (ANS) and the posterior nasal spine (PNS)
Or	Orbitale, the lowest point on the average of the left and right inferior borders of the bony orbit
PM	Pterygo-maxillare, the point at the junction of the pterygo-maxilla and the posterior nasal spine
PNS	Posterior nasal spine, the most posterior point at the sagittal plane on the bony hard palate
Po	Porion, the mid point of the line connecting the most superior point of the external auditory canal on both sides
T	The tip of the tongue
U	Uvula, the tip of the uvula
UPW	Upper pharyngeal wall, point of intersection of the line perpendicular to the posterior pharyngeal wall from the posterior nasal spine
V	Vallecula, the intersection of the epiglottis and the base of the tongue

Box 2a. Definitions of linear measurements (mm) and angle measurement (degree) used

AH-CV	Position of hyoid bone in horizontal plane, from AH to CV and parallel to FH
AH⊥FH	Position of hyoid bone in vertical plane, from AH perpendicular to FH
H⊥VT	Tongue height, measured as perpendicular distance from H to VT line
NL/PM-U	Inclination of the long axis of the soft palate relative to the nasal line
PASmin	The shortest distance between the base of the tongue and the posterior pharyngeal wall, the narrowest sagittal airway space
PM-U	Length of soft palate, distance from PM to U
PM-UPW	Depth of nasopharyngeal airway space from PM to UPW
SPT	Soft palate thickness, represents the maximal thickness of soft palate measured perpendicular to PM-U line
U-MPW	Depth of oropharyngeal airway space from U to MPW
V-CV	Position of vallecula in horizontal plane, a line from V to CV and parallel to FH
V⊥FH	Position of vallecula in vertical plane, a perpendicular line from V to FH
V-LPW	Depth of hypopharyngeal airway space from V to LPW
VT	Length of tongue, measured as distance from V to T

found no significant difference between any of the paired measurements. The values for cephalometric airway measurements in males and females are compared in the Table. Fourteen of the 20 measurements demonstrated a significant difference according to sex and, overall, larger values were recorded for male subjects. The measurements for which no significant differences were seen between males and females included NL/PM-U, U-MPW depth, PASmin, and the three ratios of the area measurements TA/OA, (TA + SPA)/NOPA, and (SPA/NOPA - OA).

Discussion

This study contained a group of Hong Kong Chinese subjects based on their clinically normal facial profile and dental

Box 2b. Definitions of area measurements (mm²) and ratios used

NOPA	Naso-oro-pharyngeal area, the computed naso-oro-pharyngeal area, including OA and the area defined by points PM, UPW, LPW and V along the posterior pharyngeal wall and the dorsal outline of the tongue including the soft palate area (SPA)
OA	Oral area, the computed oral area including tongue area and extending superiorly to the outline of soft and hard palate
SPA	Soft palate area, the outline was defined along the anterior and posterior contour of the soft palate, the superior border was a line through PM perpendicular to the PM-U line
SPA/(NOPA-OA)	Relationship between the soft palate and the difference between the naso-oro-pharyngeal and oral areas (ie pharyngeal area)
TA	Tongue area, the upper outline was defined by the dorsal contour of the tongue from V through H to T. The lower outline was reduced to a geometric polygon, of which the boundary was defined by line segments connecting the points V, AH, GE, and T
TA/OA	Relationship between the tongue and oral area
(TA+SPA)/NOPA	Relationship between combined tongue and soft palate areas and naso-oro-pharyngeal area

occlusion, and absence of any reported abnormality of the upper airway. The cephalometric measurements of the upper airway in this group are thus appropriate to use as normative data for future comparison. Shen et al³³ have previously reported a cephalometric study of the upper airway space in a normal Chinese population. In that study, cephalometric measurements of 116 normal subjects were analysed to determine normative data for the local Shanghai population of northern Chinese. These researchers used the same measurement method as the current study and reported similar results.

Significant sex dimorphism in airway measurements was evident in both the current and Shen et al's study,³³ although

Table. Comparison of results of cephalometric analysis of the upper airway in male and female subjects

Measurement	Male, n=29		Female, n=45		P value
	Mean	SD	Mean	SD	
VT	72.0	4.1	64.8	4.0	<0.001
H⊥VT	36.9	3.3	32.9	3.9	<0.001
PM-U	34.3	3.9	30.6	3.7	<0.001
SPT	10.1	1.4	8.9	1.2	<0.001
PM-UPW	25.9	2.6	24.1	2.3	<0.01
U-MPW	9.9	2.8	9.9	2.4	1
V-LPW	18.7	2.6	16.5	3.1	<0.01
PASmin	10.1	3.1	10.0	2.8	0.89
V⊥FH	91.2	6.4	78.9	5.3	<0.001
V-CV	23.0	2.9	20.4	2.8	<0.001
AH⊥FH	92.4	6.3	78.5	5.8	<0.001
AH-CV	36.4	3.0	31.2	2.9	<0.001
NL/PM-U	127.4	5.3	128.3	5.2	0.47
TA	2746.1	214.8	2259.5	244.5	<0.001
SPA	280.1	44.1	222.3	35.8	<0.001
OA	3094.4	267.9	2614.7	231.0	<0.001
NOPA	4144.0	316.2	3455.9	316.6	<0.001
TA/OA	0.8865	0.05	0.8635	0.07	0.13
(TA+SPA)/NOPA	0.7317	0.04	0.7195	0.05	0.27
SPA/(NOPA-OA)	0.2763	0.06	0.2691	0.05	0.58

slightly different patterns were observed. In the study by Shen et al,³³ the variables which did not demonstrate sex dimorphism were: PM-UPW, PASmin depth, and the ratio of TA/OA. This last finding is difficult to explain since one would not expect to see sex dimorphism of angle measurements or ratios. In the current study, all measurements bar six demonstrated sex dimorphism. The exceptions were NL/PM-U, U-MPW depth, PASmin, and all three ratios of area measurement. The two further variables that did not demonstrate sex dimorphism were the U-MPW depth and PASmin. These latter measurements are directly related to the patency of the airway, being the predominant levels at which the pharyngeal airway is reported to narrow in OSA.^{10,12} Furthermore, oropharyngeal depth is the most variable measurement in the pharyngeal airway. Several studies in patients with OSA have demonstrated a significant reduction in two-dimensional and three-dimensional measurements at the oropharyngeal level, although this was not a consistent finding across subjects.^{16,17,35} Two further measurements of clinical relevance to the patency of the airway are the PM-UPW depth and the V-LPW depth. It is evident from this study that although the majority of airway measurements demonstrate sex dimorphism, those that are most important to the patency of the airway are not dimorphic. This suggests that a minimal sagittal dimension of the upper airway is required for normal patency.

Bacon et al³⁶ used 40 normal subjects aged between 20 and 26 years (mean age, 23.7 years) as a control group in the cephalometric evaluation of pharyngeal obstructive factors in patients with OSA. These researchers reported the mean soft palate length in the male control group to be 38.7 mm (standard deviation [SD], 3.2 mm). Riley et al¹¹ reported a normal soft palate length in Caucasian males of 37.0 mm, while our results indicate a soft palate length of 34.3 mm (SD, 3.9 mm). Hochban and Brandenburg,³⁷ in a cephalometric evaluation of OSA, reported the following measurements from their control group of Caucasian males (mean age, 43 years): length of the soft palate, 45.1 mm; thickness of the soft palate, 12.2 mm; angle of the soft palate to the palatal plane, 54.5 degrees; hypopharyngeal depth of the airway, 22 mm; and tongue length, 87 mm. Lyberg et al^{20,21} performed cephalometric analysis of patients with OSA and reported the norms obtained from the control group of Caucasian males (n=10; mean age, 23.6 years). They reported a magnification factor of approximately 6% but did not correct for this in their measurements. Neither of the studies conducted by Lyberg et al^{20,21} included females as control subjects. Cephalometric norms for nasopharyngeal measurements were also reported by Poole et al.³⁸ Norms were calculated for various ages (6 and 16 years) and both sexes, and found to vary according to age and sex. In establishing norms, however, these researchers used a random sample of patients for whom the presence or absence of nasopharyngeal obstruction was not known. In addition, all measurements were at the level of the nasopharynx and in the horizontal plane only, a limited representation of the upper airway as a whole.

Thus, although a small number of studies have made cephalometric analyses of upper airway measurements, these had notable limitations and reported results are not directly comparable to the current study for the following reasons:

- (1) The majority of investigations did not use a control group and hence lacked reference measurements for the norms. Rather, comparisons between two or more abnormal groups were made (such as OSA with post-surgical groups) in order to identify changes in upper airway measurements.
- (2) The magnification factor in many of these investigations was either not considered or not reported.
- (3) The majority of studies did not include female control subjects, as most studies related to OSA which predominantly occurs in males.³⁹
- (4) With the exception of Shen et al's³³ and Peh et al's³⁴ studies, subjects have not been drawn from the Chinese population. This limits comparison of measurements across studies, the results of which cannot be presumed to be applicable for the diagnosis of abnormalities in the local Hong Kong population.

In the current study, detailed cephalometric analysis of the upper airway was conducted, with due consideration of the magnification error for each cephalometric radiograph. The findings showed that there were significant differences between males and females in the size of the tongue, soft palate, nasopharynx, hypopharynx, and oral cavity, and in the relative position of the vallecula and the hyoid bone.

Conclusion

Cephalometric norms for the pharyngeal airway in the Hong Kong population have been established in this study. Significant sex dimorphism was evident for measurements other than oropharyngeal depth of the airway, minimal depth of the airway, and the soft palate angle, suggesting that a minimal sagittal dimension is needed for normal patency of the upper airway. Data derived from this study should thus prove useful as a reference for assessment of OSA and other conditions in the Hong Kong population.

References

1. Steiner CC. Cephalometrics in clinical practice. *Angle Orthod* 1959; 29:8.
2. Khouw FE, Proffit WR, White RP. Cephalometric evaluation of patients with dentofacial disharmonies requiring surgical correction. *Oral Surg* 1970;29:789-98.
3. Haponik EF, Smith PL, Bohlman ME, Allen RP, Goldman SM, Bleecker ER. Computerized tomography in obstructive sleep apnea. Correlation of airway size with physiology during sleep and wakefulness. *Am Rev Respir Dis* 1983;127:221-6.
4. Suratt PM, Dee P, Atkinson RL, Armstrong P, Wihoit SC. Fluoroscopic and computed tomographic features of the pharyngeal airway in obstructive sleep apnea. *Am Rev Respir Dis* 1983;127:487-92.
5. Bradley TD, Brown IG, Grossman RF, et al. Pharyngeal size in snorers, nonsnorers, and in patients with obstructive sleep apnea. *N Engl J Med* 1986;315:1327-31.
6. Remmers JE, deGroot WJ, Sauerland EK, Anch AM. Pathogenesis of upper airway occlusion during sleep. *J Appl Physiol* 1978;44:931-8.

7. Rodenstein DO, Dooms G, Thomas Y, et al. Pharyngeal shape and dimensions in healthy subjects, snorers, and patients with obstructive sleep apnoea. *Thorax* 1990;45:722-7.
8. Maltais F, Carrier G, Cormier Y, Series F. Cephalometric measurements in snorers, non-snorers, and patients with sleep apnoea. *Thorax* 1991;46:419-23.
9. Pepin JL, Ferretti G, Veale D, et al. Somnofluoroscopy, computed tomography, and cephalometry in the assessment of the airway in obstructive sleep apnoea. *Thorax* 1992;47:150-6.
10. deBerry-Borowiecki B, Kukwa A, Blanks RH. Cephalometric analysis for diagnosis and treatment of obstructive sleep apnea. *Laryngoscope* 1988;98:226-34.
11. Riley R, Guilleminault C, Herran J, Powell N. Cephalometric analysis and flow-volume loops in obstructive sleep apnea patients. *Sleep* 1983;6:303-11.
12. Riley RW, Powell NB. Maxillofacial surgery and obstructive sleep apnea syndrome. *Otolaryngol Clin North Am* 1990;23:809-26.
13. Friede H, Lopata M, Fisher E, Rosenthal IM. Cardiorespiratory disease associated with Hallermann-Streifff syndrome: analysis of craniofacial morphology by cephalometric roentgenograms. *J Craniofac Genet Dev Biol Suppl* 1985;1:189-98.
14. Figueroa AA, Glupker TJ, Fitz MG, BeGole EA. Mandible, tongue, and airway in Pierre Robin sequence: a longitudinal cephalometric study. *Cleft Palate Craniofac J* 1991;28:425-34.
15. Gallagher DM, Hyler RL, Epker BN. Hemifacial microsomia: an anesthetic airway problem. *Oral Surg Oral Med Oral Pathol* 1980;49:2-4.
16. Lowe AA, Gionhaku N, Takeuchi K, Fleetham JA. Three-dimensional CT reconstructions of tongue and airway in adult subjects with obstructive sleep apnea. *Am J Orthod Dentofacial Orthop* 1986;90:364-74.
17. Lowe AA, Santamaria JD, Fleetham JA, Price C. Facial morphology and obstructive sleep apnea. *Am J Orthod Dentofacial Orthop* 1986;90:484-91.
18. Jamieson A, Guilleminault C, Partinen M, Quera-Salve MA. Obstructive sleep apneic patients have craniomandibular abnormalities. *Sleep* 1986;9:469-77.
19. Guilleminault C, Riley R, Powell N. Obstructive sleep apnea and abnormal cephalometric measurements. Implications for treatment. *Chest* 1984;86:793-4.
20. Lyberg T, Krogstad O, Djupesland G. Cephalometric analysis in patients with obstructive sleep apnoea syndrome. I. Skeletal morphology. *J Laryngol Otol* 1989;103:287-92.
21. Lyberg T, Krogstad O, Djupesland G. Cephalometric analysis in patients with obstructive sleep apnoea syndrome. II. Soft tissue morphology. *J Laryngol Otol* 1989;103:293-7.
22. Tangugsorn V, Skatvedt O, Krogstad O, Lyberg T. Obstructive sleep apnoea: a cephalometric study. Part I. Cervico-craniofacial skeletal morphology. *Eur J Orthod* 1995;17:45-56.
23. Tangugsorn V, Skatvedt O, Krogstad O, Lyberg T. Obstructive sleep apnoea: a cephalometric study. Part II. Uvulo-glossopharyngeal morphology. *Eur J Orthod* 1995;17:57-67.
24. Yu LF, Pogrel MA, Ajayi M. Pharyngeal airway changes associated with mandibular advancement. *J Oral Maxillofac Surg* 1994;52:40-3.
25. Farole A, Mundenaer MJ, Braitman LE. Posterior airway changes associated with mandibular advancement surgery: implications for patients with obstructive sleep apnea. *Int J Adult Orthodon Orthognath Surg* 1990;5:255-8.
26. Hochban W, Brandenburg U, Peter JH. Surgical treatment of obstructive sleep apnea by maxillomandibular advancement. *Sleep* 1994;17:624-9.
27. Greco JM, Froberg U, Van Sickels JE. Cephalometric analysis of long-term airway space changes with maxillary osteotomies. *Oral Surg Oral Med Oral Pathol* 1990;70:552-4.
28. Greco JM, Froberg U, Van Sickels JE. Long-term airway space changes after mandibular setback using bilateral sagittal split osteotomy. *Int J Oral Maxillofac Surg* 1990;19:103-5.
29. Wenzel A, Williams S, Ritzau M. Relationships of changes in craniofacial morphology, head posture, and nasopharyngeal airway size following mandibular osteotomy. *Am J Orthod Dentofacial Orthop* 1989;96:138-43.
30. Dahl E, Kreiborg S, Jensen BL, Fogh-Andersen P. Comparison of craniofacial morphology in infants with incomplete cleft lip and infants with isolated cleft palate. *Cleft Palate J* 1982;19:258-66.
31. McWilliam J. Hypoplasia of the middle third face - a morphological study. *Angle Orthod* 1976;46:260-7.
32. Fields HW, Warren DW, Black K, Phillips CL. Relationship between vertical dentofacial morphology and respiration in adolescents. *Am J Orthod Dentofacial Orthop* 1991;99:147-54.
33. Shen GF, Samman N, Qiu WL, Tang YS, Xia J, Huang YL. Cephalometric studies on the upper airway space in normal Chinese. *Int J Oral Maxillofac Surg* 1994;23:243-7.
34. Peh WC, Ip MS, Chu FS, Chung KF. Computed tomographic cephalometric analysis of Chinese patients with obstructive sleep apnoea. *Australas Radiol* 2000;44:417-23.
35. Xia J. Quantitative analytic system of velopharyngeal function. *Shanghai J Bioeng* 1992;10:16-9.
36. Bacon WH, Turlot JC, Krieger J, Stierle JL. Cephalometric evaluation of pharyngeal obstructive factors in patients with sleep apneas syndrome. *Angle Orthod* 1990;60:115-22.
37. Hochban W, Brandenburg U. Morphology of the viscerocranium in obstructive sleep apnoea syndrome—cephalometric evaluation of 400 patients. *J Craniomaxillofac Surg* 1994;22:205-13.
38. Poole MN, Engel GA, Chaconas SJ. Nasopharyngeal cephalometrics. *Oral Surg Oral Med Oral Pathol* 1980;49:266-71.
39. Gislason T, Almqvist M, Eriksson G, Taube A, Boman G. Prevalence of sleep apnea syndrome among Swedish men—an epidemiological study. *J Clin Epidemiol* 1988;41:571-6.