



Title	Oral Candida infections--a review.
Author(s)	Samaranayake, LP; Nair, RG
Citation	Indian Journal Of Dental Research : Official Publication Of Indian Society For Dental Research, 1995, v. 6 n. 3, p. 69-82
Issued Date	1995
URL	http://hdl.handle.net/10722/44546
Rights	Creative Commons: Attribution 3.0 Hong Kong License

ORAL CANDIDA INFECTIONS - A REVIEW

Lakshman P. Samaranayake, BDS, DDS, MIBiol, CBiol, MRCPATH¹
Raj G. Nair, BDS²

Oral Biology Unit, Faculty of Dentistry,
University of Hong Kong, Hong Kong

ABSTRACT : *Candida* species are the commonest agents of oral mycoses. They cause a variety of diseases including the new variant, erythematous candidosis, which is frequently described in HIV infection. Due to these and other reasons the classification of oral candidosis has been recently revised, and further more new therapeutic regimes have been described. Hence in this article an overview of oral *Candida* infections is presented with special emphasis on current concepts related to classification and treatment.

INTRODUCTION

Oral candidosis is one of the commonest fungal infections of man and manifests itself in a variety of ways. The widespread use of antibiotics, immunosuppressant drugs and the increasing proportion of the elderly population are the main reasons for the high incidence of oral candidosis seen in the Western World. It is noteworthy that the pandemic of human immunodeficiency virus (HIV) infection has had a significant impact on the prevalence of the disease as oral candidosis is one of its earliest manifestations. The disease now appears as novel clinical entities, the latest being the erythematous candidosis, first described in HIV infection. Clinicians should therefore be aware of these uncommon as well as common oral manifestations of the disease together with the new management approaches. The aim of this review article is to outline the recent developments in oral *Candida* infections.

THE ORGANISM

Yeasts which belong to the genus *Candida* are imperfect unicellular fungi which multiply primarily by the production of buds from ovoid blastospores (yeast cells). *Candi-*

da is the predominant commensal fungus inhabiting the human oral cavity - and indeed the human body (Fig. 1). About 50 - 60% of humans carry candidal species in the oral cavity, and intraoral prevalence dramatically increases when a prosthesis such as a denture is introduced.

Candida albicans is one of many candidal species residing in the oral cavity, and this organism is responsible for most oral candidal infections. A minority of infections are caused by at least 12 other species, including *C. glabrata*, *C. tropicalis*, *C. parapsilosis*, *C. pseudotropicalis* (now *C. kefyr*), and *C. krusei*.

All forms of oral candidosis are considered opportunistic, and the epithet 'diseases of the of diseased' has been applied to these infections. Nevertheless, it is often difficult to identify the exact predisposing factor despite intensive investigations.

PREDISPOSING FACTORS

A variety of local and systemic factors have been implicated in the pathogenesis of oral candidosis Table 1. The old and the very young are particularly susceptible to the disease - probably because of immature immunity in the young and debility and

1 - Reader in Oral Biology and
Associate Dean (Research and
Postgraduate Affairs.

2 - Research Associate

* Address for Communication :
The Prince Philip Dental Hospital
34 Hospital Road, Hong Kong.

L. P. Samaranayake

malnourishment in the old. In addition, intractable oral candidosis may be the first sign of an endocrine abnormality or immune deficiency.

Local trauma from ill-fitting dentures and poor denture hygiene are important co-factors in the aetiology of Candida-associated denture stomatitis (chronic atrophic candidosis). A high intake of dietary carbohydrate has been implicated in oral candidosis, as well as nutritional deficiency - particularly of iron, folic acid and vitamin B₁₂. There is a strong association between topical and systemic broad-spectrum antibiotic therapy and oral candidosis. These agents suppress the host bacterial flora and foster the proliferation of the commensal yeast species. Prolonged use of steroid inhalers can result in oral thrush. (Fig. 2)

A variety of endocrine disorders are associated with intractable oral candidosis, and uncontrolled diabetes mellitus predisposes to either a higher oral carriage of yeasts or clinical candidosis. As a fully functional cellular immune system plays a key role in combating candidal infection, immunological defects, whether acquired or (more rarely) congenital, predispose individuals to oral candidosis.

Oral candidosis is associated with oral malignancy in two ways. Firstly, there is a well-recognised relationship between candidal leukoplakia and malignant transformation. Secondly, candidosis can complicate oral neoplasias, probably as a result of local factors associated with generalized debility due to the neoplasia or to iatrogenic factors such as irradiation and cytotoxic therapy.

Overt xerostomia or reduction of salivary flow predisposes individuals to oral candidosis in conditions such as primary or secondary Sjogren's syndrome. Patients who have received head and neck irradiation frequently develop oral candidosis due - in part at least - to xerostomia as a consequence of salivary gland damage.

CLASSIFICATION

By tradition, Candida infections of the oral cavity has been divided into acute and chronic forms which in turn has been subdivided as acute pseudomembranous (thrush), acute atrophic (Candida glossitis), chronic atrophic (denture induced stomatitis) and chronic hyperplastic (candidal leukoplakia) variants. Chronic hyperplastic candidosis was further subdivided into four groups based on localisation patterns and endocrine involvement as chronic oral candidosis (candida leukoplakia), endocrine candidosis syndrome, chronic localised mucocutaneous candidosis and chronic diffuse candidosis.

In a recent classification Samaranayake (1990) proposed that the last subdivision of chronic hyperplastic candidosis generates some confusion, as it lumps together hyperplasias which are purely localised to the oral cavity as well as those related to oral manifestations of mucocutaneous candidosis, where the lesions manifest both systemically and in oral tissues. Hence a dichotomous classification which categorises candidoses exclusively confined to the oral and perioral tissues - termed *primary oral candidoses*, and lesions distributed in other parts of the body as well as the oral cavity - termed *secondary oral candidoses*, has been proposed, and accepted (Fig 3).

As the secondary oral candidoses are associated with rare disorders such as thymic aplasia and endocrine candidosis syndrome these entities will not be dealt further in this review.

The primary oral candidoses are further subdivided into three categories according to their clinical presentation (as opposed to previous classifications where a mix of both clinical and pathological criteria were used) as i) pseudomembranous, ii) erythematous and iii) plaque like or nodular variants. Each of these clinical entities may be categorised as either acute or chronic lesions depending on the duration of the lesion.

Whereas these represent the clinical presentation of the primary oral candidoses

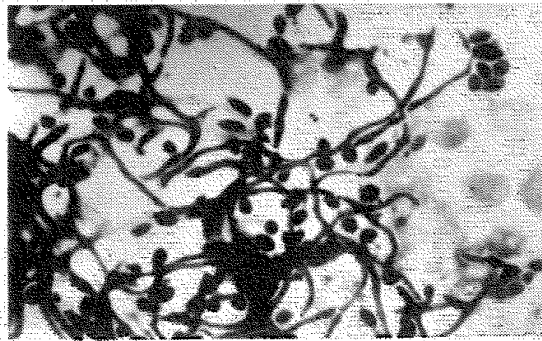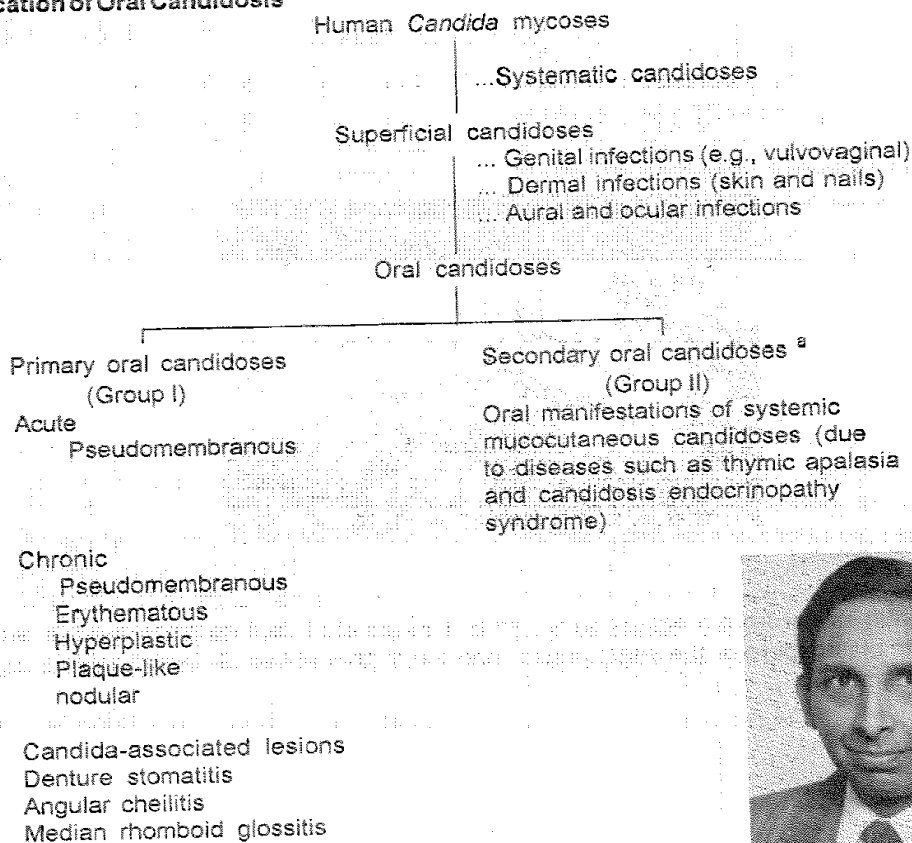


Fig 1. A palatal smear from a patient with *Candida*-associated denture stomatitis showing the characteristic blastospore or the yeast phase, and the hyphal phase of the organisms together with epithelial debris.

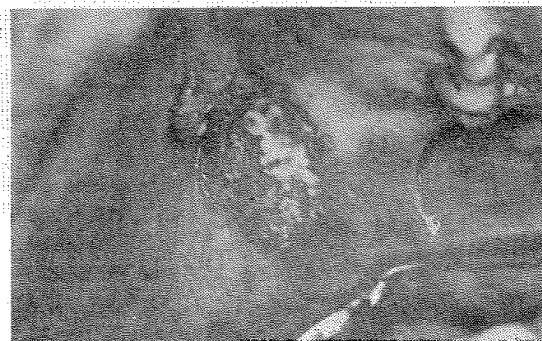

Fig 2. Thrush or pseudomembranous candidosis of the palate in an HIV-infected individual.

Classification of Oral Candidosis



^a See Table 2




Figure 3: Classification of oral candidosis (From; Samaranayake 1991)

there exist a group of disorders that are not always associated with *Candida* infection and seem to have a bacterial, fungal or other aetiology. Consequently such lesions do not always respond to antifungal therapy and usually resolve when the associated cofactors such as bacterial infections or nutritional deficiencies are treated. Examples which fall into this category include denture-induced stomatitis, angular cheilitis and median rhomboid glossitis. Nonetheless, as the entities are frequently associated with candidal infections they are categorised as *Candida* associated lesions and may present generally as

erythematous lesions.

The following describes the common oral candidoses in detail with short notes on the rare variants of the disease.

(i) Pseudomembranous candidosis

Pseudomembranous variant of oral candidosis in the form of thrush is classically an acute infection but it may persist for many months or even years in patients using corticosteroids topically or by aerosol, in HIV-infected individuals, and in other immunocompromised patients.

Pseudomembranous candidosis may be seen in neonates and among terminally

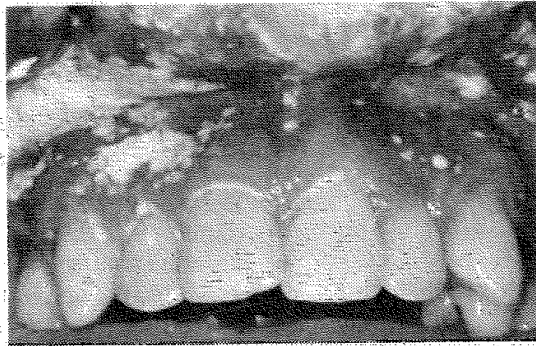


Fig 4. Curd-like, white appearance of pseudomembranous candidosis in an AIDS patient. Note the infection which has progressed to gingival crevicular area due to the severe immunodeficiency.

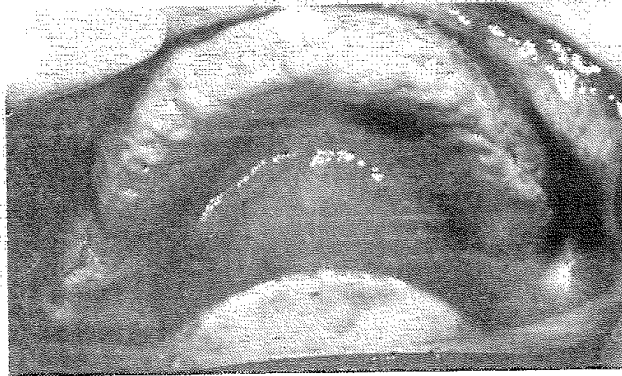


Fig 5. *Candida*-associated denture stomatitis showing the erythematous and oedematous denture bearing palatal mucosa. This lesion could be categorised into Newton's Type II.

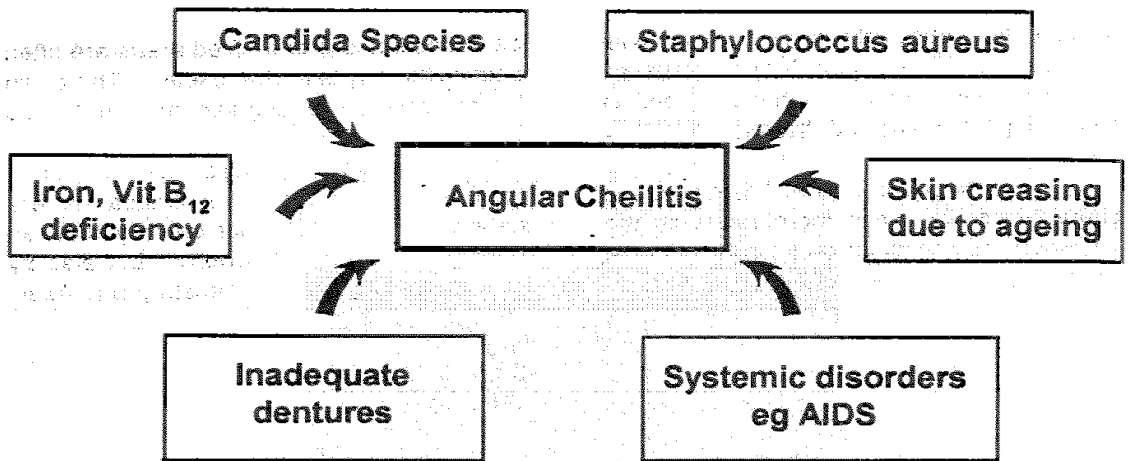


Table 1: Factors predisposing to oral candidosis

Chronic local irritants including ill-fitting appliances, and
inadequate care of appliances

Disturbed oral ecology or marked changes in the oral microbial
flora by antibiotics, corticosteroids, xerostomia

Dietary factors

Immunological, endocrine and haematological disorders

Radiation to the head and neck

Age

Hospitalisation

Oral epithelial dysplasia

Heavy smoking

ill patients particularly in association with serious underlying conditions, such as leukaemia and other malignancies, and is increasingly seen in HIV disease.

As the name implies this disease is characterised by white membranes on the surface of the oral mucosa, tongue and elsewhere (Fig 4). The lesions develop to form confluent plaques that resemble milk curds, and can be wiped off to reveal a raw, erythematous and sometimes bleeding base.

The pseudomembranes are made up of necrotic material and desquamated epithelia, penetrated by *C. albicans* yeast cells and hyphae which invade as far as the stratum spinosum. Oedema and micro-abscesses containing polymorphonuclear leukocytes (PMNL) are found in the outer layers of epithelium. The deeper parts of the epithelium show acanthosis, and the inflammatory response in the connective tissue comprises lymphocytes, plasma cells and PMNL.

Oropharyngeal thrush may sometimes spread to the adjacent mucosa, particularly those of the upper respiratory tract and the oesophagus. The combination of oral and oesophageal candidosis is particularly prevalent in HIV-infected patients (Holmstrup and Samaranayake, 1990).

(ii) Erythematous Candidosis

Erythematous candidosis, previously described as atrophic candidosis, is an uncommon and poorly understood condition associated with corticosteroids and topical or systemic broad spectrum antibiotics or in HIV disease. It may arise as a consequence of persistent acute pseudomembranous candidosis when the pseudomembranes are shed, may develop de novo or in HIV infection may precede pseudomembranous candidosis.

The clinical presentation is of erythematous areas generally on the dorsum of the tongue, palate or buccal mucosa. Lesions on the dorsum of the tongue present

as depapillated areas. Red areas are often seen in the palate in HIV disease. There can be an associated angular stomatitis (see below).

The value of using the term "atrophic" to describe the red areas is limited, as redness may be caused not only by reduced epithelial thickness - atrophy - but also by increased vascularity (Holmstrup and Axell, 1990).

(iii) Plaque-like or nodular variant of candidosis

These lesions were previously termed hyperplastic candidosis or candidal leukoplakia. The latter terminology is not used in the current review as the new classification of oral candidosis, avoids pathologic nomenclature.

These lesions are almost always chronic in nature presenting as discrete raised lesions that vary from small, palpable, translucent, whitish areas to large, dense, opaque plaques hard and rough to the touch - plaque-like lesions. Homogeneous areas or speckled areas with small nodules, which do not rub off are relatively infrequently seen. These are the nodular lesions. Speckled leukoplakia counts for 3-50% of all candidal leukoplakias, and they are often symptomatic. Candidal leukoplakias usually occur on the inside surface of one or both cheeks, less often on the tongue.

Biopsy is important as the condition is premalignant and shows varying degrees of dysplasia. Oral cancer supervenes in 9-40% of candidal leukoplakias compared with the 2-6% risk of malignant transformation cited for leukoplakias in general. The risk of carcinoma developing in candidal leukoplakia will depend on whether the lesion is speckled or homogeneous, the presence and degree of epithelial dysplasia, and the management adopted.

The pathology of candidal leukoplakia includes parakeratosis and epithelial hyperplasia and *Candida* invasion restricted

Table 2. Classification of secondary oral candidoses

Subgroup	Condition	Onset	Affected sites and Clinical features
1	Familial Chronic mucocutaneous candidosis	First decade of life	Mouth, nails, skin, mainly chronic hyperplastic lesions
2	Diffuse chronic mucocutaneous candidosis	Before 5 years of age	Mouth, nails, skin, eyes, pharynx and larynx : chronic hyperplastic lesions
3	Candidosis-endocrinopathy syndrome	By the second decade	Mouth : associated with hypoparathyroidism, hypothyroidism, hypoadrenocorticism and diabetes mellitus; chronic hyperplastic lesions
4	Familial mucocutaneous candidosis	In the first year of life	Mouth, nails, scalp, flexures; chronic hyperplastic lesions
5a	Severe combined immunodeficiency	Childhood	Mouth, skin, nails, psudomembraneous or hyperplastic lesions
5b	Di George's syndrome		
5c	Chronic granulomatous disease		
6	HIV disease and Acquired immuno deficiency syndrome (AIDS)	Any age	Mouth, oesophagus, may manifest as psudomembraneous, erythematous or hyperplastic lesions

to the upper layers of epithelium. The condition has associated in a minority with iron and folate deficiencies and with defective cell-mediated immunity and hence it is important to check for these deficiencies in recalcitrant infections which do not respond to antifungal therapy alone.

CANDIDA-ASSOCIATED LESIONS

Candida-associated denture stomatitis

This condition was classically termed chronic atrophic candidosis or denture-induced stomatitis or denture stomatitis. It is the most common oral fungal infection in the elderly denture wearers in the West, and estimates in Denmark indicate that more than half of the denture wearers over 65 years of age suffer from Candida-associated denture stomatitis.

The characteristic presenting signs of this variant are chronic erythema and oedema of the mucosa that contacts the fitting surface of the denture. The mucosa below lower dentures is hardly ever involved.

The patient may occasionally experience slight soreness, but is usually free of symptoms. The only presenting complaint is often a sometimes-associated angular stomatitis. In one study, 28% of patients were aware of a burning or tingling sensation under dentures but the remainder were asymptomatic. A higher proportions of women than men complain of the condition possibly because of the higher incidence of edentulism among women and because of the tendency for women to seek dental treatment more often than men.

Newton (1962) classified denture-induced stomatitis into three clinical types: type I: a localised simple inflammation or a pinpoint hyperaemia; type II: an erythematous or generalised simple type presenting as more diffuse erythema involving a part of, or the entire, denture-covered mucosa (Fig 5) and type III: a granular type (inflammatory papillary hyperplasia) commonly involving the

central part of the hard palate and the alveolar ridge.

Histologic examination of the soft tissue beneath dentures has shown proliferative or degenerative responses. Insertion of the denture alters the microbiological milieu and plaque collects between the mucosal surface of the denture and the palate, especially due to poor denture hygiene. In addition, the salivary flow beneath the denture-fitting surface is restricted.

The generalised simple and the granular types of Candida-associated denture stomatitis are most often caused by the accumulation of microbial plaque (bacteria or yeasts) on the fitting surface of the denture and the underlying mucosa. However, denture-induced stomatitis is not exclusively associated with Candida and occasionally, other factors such as bacterial infection, mechanical irritation or an allergic reaction to the denture base material may be implicated. None the less, there are no clinical criteria which can reliably distinguish between a Candida-associated, a bacteria-induced, a trauma-induced denture stomatitis or an allergic reaction to the denture base material.

Candida-Associated Angular Cheilitis

Angular cheilitis, also called perleche or angular stomatitis is multifactorial in origin and affect the angles of the mouth, either unilaterally or bilaterally, especially in the elderly denture wearers.

It is characterised by soreness, erythema and fissuring and, commonly, is associated with denture-induced stomatitis. Both yeasts and bacteria (*especially Staphylococcus aureus*) are involved, as interacting, predisposing factors (Fig 6). However, angular stomatitis is, very occasionally, an isolated initial sign of anaemia or vitamin deficiency, such as vitamin B₁₂ deficiency, and resolves when the underlying disease has been treated. Iron deficiency anaemia and other vitamin deficiencies have been cited as other predisposing factors. In un-

common conditions such as orofacial granulomatosis, up to 20% of individuals have angular cheilitis although *Candida* species are not often isolated. Recently angular cheilitis have been described in HIV disease, even in the young. Few authors consider that the lesion results solely from maceration due to deep, occlusive folds of skin at the mouth angles in individuals with facial height reduced by old age or edentia.

Median Rhomboid Glossitis

Midline glossitis, or glossal central papillary atrophy, is characterised by an area of papillary atrophy which is elliptical or rhomboid in shape, symmetrically placed centrally at the midline of the tongue, anterior to the circumvallate papillae. Occasionally median rhomboid glossitis presents with a hyperplastic exophytic, or even lobulated appearance. The relevance of *Candida* to the condition has been controversial, with some authors claiming that the *Candida* causes the condition, particularly the papillary atrophy. Histopathologically, candidal hyphae infiltrate the superficial layers of the parakeratotic epithelium and a polymorphonuclear leukocyte infiltrate occupies the epithelium, with elongated hyperplastic rete ridges, and a lymphocyte infiltration in the corium. However, it has been demonstrated that the condition frequently shows a mixed bacterial/fungal microflora.

Chronic multifocal oral candidosis

In a minority of individuals, chronic candidal infection may be seen in multiple oral sites, with various combinations including: 1) angular stomatitis (unilateral or bilateral), 2) retrocommissural leukoplakia which is the most constant component, 3) median rhomboid glossitis, and 4) palatal lesions. Further the lesions should be of more than one month duration in the absence of predisposing medical conditions or therapeutic conditions such as antibiotics or immunosuppressive drugs which generally predisposes to *Candida* infection.

Most patients are adult males and tobacco smokers in their fifth or sixth decade at presentation. Antifungal therapy will clear the infection and produce clinical improvement, but recurrence is common, unless smoking can be reduced.

A NOTE ON SECONDARY ORAL CANDIDOSIS

While the candidoses included in Fig 3 are limited mainly to the oral cavity, it is important to recognise that oral candidal infections can occasionally manifest as a result of systemic complications, Table 2.

A few of these patients have chronic candidosis from an early age sometimes with a definable immune defect (e.g. chronic mucocutaneous candidosis). The number of patients immunocompromised by diseases such as HIV infection, haematological malignancy and treatment protocols including aggressive cytotoxic therapy, however, has increased during recent years and comprises by far the largest such group.

Chronic Mucocutaneous Candidosis (CMC)

CMC is the term given to the group of rare syndromes, sometimes with a definable immune defect, in which there is persistent mucocutaneous candidosis that responds poorly to topical treatment. In general, the more severe the candidosis, the greater the likelihood that immunological defects (particularly of cell-mediated immunity) can be identified. The main types of these rare disorders and their features are shown in Table 2.

HIV-Related oral candidosis

Candida infections, with oral thrush and oesophagitis as frequent clinical manifestations, are the most common opportunistic infections encountered in HIV disease, occurring in some 75 - 92% of individuals. Ever since the first clinical definition of AIDS (1981) the CDC/WHO have recognised candidosis of the mouth, oesophagus, trachea, bronchi and lungs as "major" opportu-

nistic infections and important indicator diseases.

The main cause of infection in HIV disease is the immune impairment but the associated xerostomia is also contributory. Recent studies have demonstrated that oral Langerhans cells are infected by HIV and may also play a role in the disease. Further, *Candida* may, by itself induce immunosuppression, and influence the prognosis.

The manifestations of candidal infections in HIV infection are usually restricted to superficial candidosis of varying degrees of severity. Although not life-threatening, these infections are persistent and debilitating. Pseudomembranous candidosis, the most clinically obvious variant of candidosis, may involve any area of the oral mucosa, but is seen frequently on the tongue, hard and soft palate and buccal mucosa. Oral thrush can manifest at variable time before Kaposi's sarcoma or other life-threatening opportunistic infections.

The erythematous (atrophic) type of oral candidosis is found predominantly in the palatal mucosa and dorsum of the tongue. Some believe that erythematous candidosis is as serious a prognostic indicator as pseudomembranous candidosis, because the erythematous form is more difficult to recognise and, hence, is underdiagnosed.

Oesophageal candidosis in a person with no other known cause for diminished resistance to the disease is also considered indicative of AIDS. This variant is notable for its persistence, but dissemination does not appear to result. Oesophageal candidosis gives rise to dysphagia and retrosternal discomfort and, in some, tenderness on pressing on the sternum.

Also, candidosis presenting like median rhomboid glossitis is not uncommon in HIV disease. Angular stomatitis is not infrequent and its appearance in a non-denture wearer, particularly if in a high-risk group or if it is recalcitrant to treatment, now raises the suspicion of the presence of HIV or other

immune defect.

Oral candidosis appears also to be a frequent sign of HIV infection in children. Most children with perinatal HIV infection develop mucocutaneous candidosis in the first year of life, as opposed to a small percentage of children who are diagnosed after this period as having AIDS. Therefore, in the young infants with HIV infection, chronic mucocutaneous candidosis may act as a warning sign for early and severe morbidity. There is a considerable risk of toxicity, which may manifest as fever, vomiting, as renal, bone marrow, cardiovascular and neurological toxicity.

ANTIFUNGAL THERAPY

Detection and treatment of predisposing factors should be complementary to antifungal therapy in effecting a cure for the patient's oral candidosis.

Two main groups of antifungal agents available for the treatment of oral candidosis and angular cheilitis are the polyenes and the imidazole groups. Agents from the polyene group, nystatin and amphotericin B, are not absorbed systemically. Nystatin is available in the form of tablets (500 000 units), suspension (100 000 u/mL), pastilles (100 000 u/g), and ointment (100 000 u/g). The duration of therapy is gauged by the clinical response, and should be continued for a period (approximately 2 weeks) following clinical resolution. Amphotericin B is available also in the form of tablets (100-mg), lozenges (10-mg) or ointment (3%).

The clinical indications for the form of polyene therapy to be used depend partly on the age of the patient, on the site of infection, and on patient compliance. A suspension or mixture is best suited to neonates or young children. Tablets have a bitter taste and may prejudice patient compliance; pastilles, which are flavoured, may be better tolerated. Creams are emulsions of either oil-in-water or water-in-oil which rub into the skin and are easily washed off, they are, therefore, useful in cases of angular cheilitis, in which dryness

and flaking may be present. Creams, unlike ointments, contain preservatives which occasionally give rise to sensitivity reactions. Ointments contain no water and are less easily washed off than creams; therefore, they may be applied to the denture base in cases of chronic atrophic candidosis.

The imidazole group of antifungals, such as miconazole (Daktarin), is increasingly being used in the treatment of oral candidosis. Miconazole in the form of cream (2%) or oral gel (25 mg/ml) has a two-pronged action, being bacteriostatic in addition to fungicidal. This drug is particularly useful in the treatment of angular cheilitis, which has a bacteriological and/or fungal aetiology. The oral gel preparation is recommended to be retained intraorally near the lesion in a volume of 5-10 mL four times a day before swallowing. For younger individuals (<2 years) the dose is 2.5 mL twice a day increasing to 5 mL twice a day for those aged 2-6 years and 5 mL four times a day for those over 6 years. Since the imidazole group of antifungal agents is absorbed systemically, the potentiation of warfarin and other coumarin agents as well as of phenytoin is possible.

Chlorhexidine oral rinses are frequently used in Scandinavian countries as an adjunct to the treatment of oral candidosis. This biguanide is essentially fungicidal, although its property of suppressing colonization and yeast attachment to the host mucosa and denture surfaces is less well known. Its main drawback, however, is the staining of teeth associated with recurrent use.

ANTIFUNGAL THERAPY OF SPECIFIC OROFACIAL CANDIDOSES

The treatment of orofacial candidosis should always take into account the possibility of underlying disease.

PSEUDOMEMBRANOUS CANDIDOSIS

Several treatment regimens have been proposed for this condition. The use of ointments (nystatin or amphotericin) is contraindicated. In neonates, nystatin or

amphotericin suspension four times a day for at least 2 weeks is the treatment of choice; in adults, amphotericin tablets or lozenges or nystatin pastilles four times a day for 4 weeks. Miconazole oral gel can alternatively be employed, four times a day for a similar period.

ERYTHEMATOUS CANDIDOSIS

The treatment of erythematous candidosis is identical to pseudomembranous candidosis. In both conditions the avoidance of broad-spectrum antibiotic therapy - or steroid therapy, if possible - will also hasten resolution. In some individuals this is not practicable, and long-term antifungal therapy is warranted.

PLAQUE-LIKE AND NODULAR (HYPERPLASTIC) CANDIDOSIS

This condition is premalignant, and all such patients require long-term review. Mucosal biopsy is essential to confirm the diagnosis. Immunological investigations may be required to rule out the possibility of a rare mucocutaneous candidosis syndrome. Long-term amphotericin (lozenges) or nystatin (pastilles) are likely to be best tolerated by patients, taken four times a day until clinical resolution occurs. Miconazole (gel) three times a day until clinical resolution occurs has also been recommended. There is no place for empirical therapy unless the lesion has been biopsied.

The newer triazole, fluconazole (one tablet (50 mg) per day given for one week or more until the lesion resolves has been very efficacious in recent trials. But due to the high efficacy of this drug in systemic candidoses (especially in treating fungal infections in HIV disease), and the possibility of emergence of resistant *Candida* strains this drug should be used only as a last resort in recalcitrant cases.

CANDIDA-ASSOCIATED DENTURE STOMATITIS

This condition, which may usually

present as erythematous and rarely as hyperplastic lesions of the palate, only occurs in individuals with an oral prosthesis (e.g. complete or partial dentures or, occasionally, an orthodontic appliance). Treatment involves denture hygiene measures and antifungal therapy. If patients have an acrylic prosthesis, overnight soaking in a hypochlorite solution is mandatory, as the prosthesis is the main reservoir of infection. Patients with chrome-cobalt dentures will find that soaking in hypochlorite blackens the metal; they should therefore brush the fitting surface with soap and water followed by thorough rinsing. In both groups of patients the necessity to avoid wearing the denture at night should be stressed. As mentioned above chlorhexidine gluconate (2%) can be substituted for hypochlorite, but denture discolouration is a problem.

Antifungal therapy involves either amphotericin (tablets lozenges) or nystatin (pastilles) four times a day for 5 weeks. In addition, amphotericin (ointment or paste) or nystatin (ointment) is applied to the fitting surface of the prosthesis twice a day for 4 weeks. The polyenes can be difficult to remove from acrylic surfaces, and miconazole gel can be used three times a day to the fitting surface of the prosthesis.

CANDIDA-ASSOCIATED ANGULAR CHEILITIS

This is an endogenous infection, and successful management involves elimination of the reservoirs of infection. When *Candida* is isolated the reservoir is the oral cavity, and when *Staphylococcus aureus* is isolated the reservoir is the anterior nares. When candidal species alone are involved, evidence of intraoral candidosis can be sought; even if not clinically detected, treatment as for *Candida*-associated denture stomatitis should be instituted. In addition, topical amphotericin (paste or ointment) or nystatin (ointment) should be applied four times a day for 4 weeks to both angles. As an alternative, miconazole (gel) may be applied three times a day for 4

weeks.

When *Staphylococcus aureus* is isolated from the angles, the antibiotic sensitivity of the organism should be determined, if possible. However, in general, as the majority of the *Staph aureus* are sensitive to fusidic acid the latter (Fucidin) should be applied four times a day for 4 weeks. Patients are given two tubes of Fucidin: one for exclusive use of the angle and one for both anterior nares (as the reservoir of the organisms is the anterior nares). Miconazole gel can be used if the organism is resistant to fusidic acid, as it has some Gram-positive bacteriostatic action.

If resolution does not occur, then both patient compliance and underlying disease should be questioned. Occasionally individuals are encountered with chronic nose-mouth habits that encourage the spread of staphylococci. In other cases the prolonged occupational wearing of face masks in warm environments (e.g. operating theatres) seems to predispose some individuals to recurrent attacks, despite good compliance with therapy and the absence of underlying disease.

CHRONIC MUCOCUTANEOUS CANDIDOSIS

Topical antifungal therapy is usually of no benefit in this condition. Since these patients may have serious underlying disorders, referral to a physician for further investigation is advised.

References and further reading

- Budtz-Jorgensen E. *Candida* associated denture stomatitis and angular cheilitis. In: Samaranyake LP, MacFarlane TW (eds) *Oral Candidosis*. Bristol, Wright, 1990: 156-183.
- Dias AP, Samaranyake LP. Clinical, microbiological and ultrastructural features of angular cheilitis lesions. In *Southern Chinese Oral Diseases* 1995; 1: 43-48.
- Holmstrup P, Bessermann M. Clinical, therapeutic and pathogenic aspects of chronic oral multifocal candidosis. *Oral Sur. Oral Med. Oral Pathol.* 1983; 56: 388-395.
- Jorrizo JL. Chronic mucocutaneous candidosis: an update. *Arch. Dermatol* 1982; 118: 963-965.
- Lamey PJ, Samaranyake LP. Oral candidosis: 2. Diagnosis and management. *Dental Update*

1988; 15: 328-331.

MacFarlane TW, Samaranayake LP. *Clinical oral microbiology*. Bristol, Wright. 1990, 122-139.

Samaranayake LP, MacFarlane TW (eds) *Oral Candidosis*, Bristol, Wright 1990.

Samaranayake LP. Nutritional factors and oral candidosis: A review. *J. Oral Pathol.* 1986; 15: 61-65.

Samaranayake LP, Lamey PJ. Oral candidosis: 1. Clinicopathological aspects. *Dental Update* 1988; 15: 227-231.

Samaranayake LP. Host factors and oral candidosis. In: Samaranayake LP, MacFarlane TW (eds) *Oral Candidosis*, Bristol, Wright 1990; 66-104.

Samaranayake LP. Superficial oral fungal infec-

tions. *Current Opinion in Dentistry* 1991; 1: 415-422.

Samaranayake LP. Oral mycoses in immuno deficiency virus infection: a review. *Oral Sur. Oral Med. Oral Pathol.* 1992; 73: 171-180.

Scully C, Samaranayake LP. *Clinical virology in oral medicine and dentistry*. Cambridge, Cambridge University Press 1992, 260-314.

Silverman S, Migliorati D, Epstein JB, Samaranayake LP. laboratory diagnosis of oral candidosis. In: Samaranayake LP, MacFarlane TW (eds) *Oral Candidosis*. Bristol, Wright, 1990, 213-237.

Waranakulasuriya KAAS, Samaranayake LP, Peiris JSM. Angular cheilitis in a group of Sri Lankan adults. *J. Oral Pathol. and Med.* 1991; 20: 17-19.