



Title	p21(WAF1/CIP1) expression in gestational trophoblastic disease: correlation with clinicopathological parameters, and Ki67 and p53 gene expression
Author(s)	Cheung, ANY; Shen, DH; Khoo, US; Wong, LC; Ngan, HYS
Citation	Journal Of Clinical Pathology, 1998, v. 51 n. 2, p. 159-162
Issued Date	1998
URL	http://hdl.handle.net/10722/43590
Rights	Journal of Clinical Pathology. Copyright © B M J Publishing Group.

p21^{WAF1/CIP1} expression in gestational trophoblastic disease: correlation with clinicopathological parameters, and Ki67 and p53 gene expression

A N Y Cheung, D H Shen, U S Khoo, L C Wong, H Y S Ngan

Abstract

Background—The p21^{WAF1/CIP1} gene mediates growth arrest by inhibiting G₁ cyclin dependent kinases and has been considered as a downstream effector of the tumour suppressor gene p53.

Aim—To analyse the role of p21^{WAF1/CIP1} in gestational trophoblastic disease.

Methods—The immunohistochemical expression of p21^{WAF1/CIP1} gene was measured in 33 placentas, 28 partial hydatidiform moles, 54 complete hydatidiform moles, and 13 choriocarcinomas in paraffin wax embedded tissue. The results were correlated with p53 (DO7) and Ki67 (MIB1) immunoreactivity as well as clinical progress.

Results—p21^{WAF1/CIP1} immunoreactivity was found predominantly in the nuclei of the syncytiotrophoblasts. p21^{WAF1/CIP1} protein expression correlated with gestational age in normal placentas ($p = 0.0001$) but not in hydatidiform moles ($p = 0.89$). Complete hydatidiform moles and choriocarcinomas had a significantly higher p21^{WAF1/CIP1} expression compared with normal placentas and partial hydatidiform moles ($p < 0.001$); there was no difference between placentas and partial hydatidiform moles. No correlation between p21^{WAF1/CIP1} expression and either the proliferation (Ki67) index ($p = 0.34$) or p53 protein accumulation ($p = 0.68$) was demonstrated. There was no significant difference ($p > 0.05$) in p21^{WAF1/CIP1} expression between the 17 patients who developed persistent gestational trophoblastic disease and those who did not.

Conclusions—This study suggests that p21^{WAF1/CIP1} expression in trophoblastic disease may be induced by a p53 independent pathway. The proliferative activity of gestational trophoblastic diseases might not be determined solely by the control of the cell cycle operated by p21^{WAF1/CIP1}. p21^{WAF1/CIP1} expression is not an accurate prognostic indicator of gestational trophoblastic disease.

(J Clin Pathol 1998;51:159-162)

Keywords: p21^{WAF1/CIP1}; gestational trophoblastic disease; p53; Ki67

The WAF1 growth suppressor gene, also known as CIP1, encodes a 21 kDa protein p21^{WAF1/CIP1}.¹ This protein is an inhibitor of the cyclin dependent kinases (CDKs), the activation of which is important for cell cycle

progression.^{1,2} p21^{WAF1/CIP1} expression is induced by wild-type p53 but not the mutant p53 gene product.²⁻⁴ Thus, it is considered as a downstream effector of p53, responsible for the antiproliferative, apoptotic, and tumour suppressor effects of p53.³⁻⁵

Gestational trophoblastic disease is a heterogeneous group of lesions including complete and partial hydatidiform moles, invasive moles, choriocarcinoma, and placental site trophoblastic tumours. Some of these lesions are true neoplasms, whereas others may be abnormally formed placentas that have a predisposition to neoplastic transformation of the trophoblast. The pathogenesis and factors predicting the progress of these diseases remain uncertain.^{6,7}

In previous studies, we have demonstrated the absence of p53 mutation in hydatidiform moles as well as the overexpression of wild-type p53 RNA and protein in hydatidiform moles and choriocarcinomas compared with normal placentas⁸ (Cheung *et al*, unpublished data). There are no published data concerning the role of p21^{WAF1/CIP1} in the normal placenta and gestational trophoblastic disease. We investigated the immunohistochemical expression of p21^{WAF1/CIP1} in 33 placentas and 95 cases of gestational trophoblastic disease. Our aim was to evaluate p21^{WAF1/CIP1} expression in relation to p53 protein expression, proliferative activity, and other clinicopathological characteristics, especially the clinical progress of the patients, in an attempt to clarify the role of p21^{WAF1/CIP1} in gestational trophoblastic disease.

Methods and materials

The pathology reports of patients with a diagnosis of complete hydatidiform mole, partial hydatidiform mole, and choriocarcinoma treated at the Queen Mary Hospital, University of Hong Kong were reviewed. Thirty three placentas, 28 partial hydatidiform moles, 54 complete hydatidiform moles, and 13 choriocarcinomas with available paraffin wax blocks were selected. The gestational age of the placentas ranged from seven to 42 weeks, while that of hydatidiform moles ranged from eight to 28 weeks. Some of these cases had been investigated previously for p53 gene status as well as p53 (DO7) and Ki67 (MIB1) immunoreactivity^{8,9} (Cheung *et al*, unpublished data). The histological features of these cases were assessed using generally agreed and accepted diagnostic criteria.^{6,7}

The tissues included uterine curettagings and blocks from hysterectomy specimens, all of which were routinely fixed in 10% formalin and embedded in paraffin wax. Paraffin wax

Department of Pathology, Queen Mary Hospital, The University of Hong Kong, Pokfulam Road, Hong Kong
A N Y Cheung
U S Khoo

Department of Obstetrics and Gynaecology, Queen Mary Hospital
L C Wong
H Y S Ngan

Department of Pathology, Second People's Hospital, Beijing Medical University, Beijing, People's Republic of China
D H Shen

Correspondence to:
Dr Cheung.
email: anycheun@hkucc.hku.hk

Accepted for publication
9 December 1997

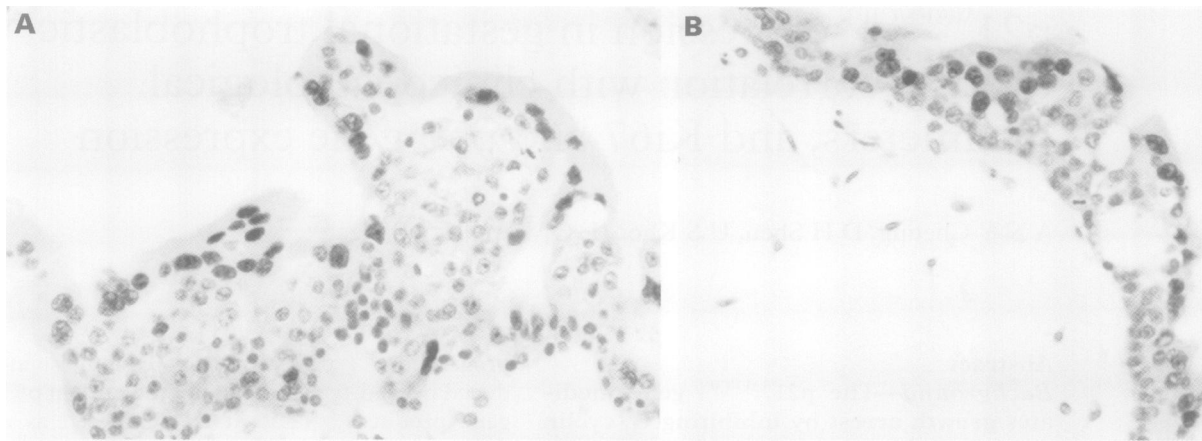


Figure 1 Immunoreactivity for p21^{WAF1/CIP1} is confined to the nuclei of the syncytiotrophoblasts in both (A) complete and (B) partial hydatidiform moles. The positive nuclei are heavily stained.

sections (4 μ m) were dewaxed and rehydrated. Endogenous peroxidase was blocked using 3% H₂O₂ in methanol. After microwave pretreatment for antigen retrieval,⁹ monoclonal mouse antibodies for p21^{WAF1/CIP1} (Calbiochem, Massachusetts, USA) was applied at a 1/30 dilution and incubations were performed overnight at 4°C. Immunohistochemistry was performed using the ABC immunoperoxidase method (Dako, High Wycombe, Bucks, UK). Biotinylated sheep antimouse antibody was used as the linker molecule and diaminobenzidine/hydrogen peroxide was used as chromogen. A light haematoxylin counterstain was used. Sections were dehydrated in alcohol, cleared in xylene, and mounted.

Sections were examined at high power ($\times 400$) and 20 fields were chosen at random for each section. In each case, a quantitative estimate of the nuclear labelling index for p21^{WAF1/CIP1} immunoreactivity was made by scoring positive nuclei/total number of nuclei counted in a minimum of 300 trophoblastic cells. The syncytiotrophoblast and cytotrophoblast were evaluated separately. The p21^{WAF1/CIP1} nuclear labelling index was expressed as a percentage of the total number of nuclei counted. In effect, ~ 2000 syncytiotrophoblasts and cytotrophoblasts were counted in each case. Normal colonic tissue was used as a known positive control and negative controls were included by substituting Tris buffered saline for the primary antibody.

Follow up data were available for 71 patients with partial and complete hydatidiform moles. Persistent gestational trophoblastic disease was diagnosed if there was a plateau in β human chorionic gonadotrophin (hCG) concentrations for four weeks or if there was a further increase in β -hCG for three consecutive weeks when pregnancy was excluded.¹⁰ According to these criteria, four patients with partial hydatidiform moles and 13 patients with complete hydatidiform moles were diagnosed as having persistent gestational trophoblastic disease.

Statistical analysis of p21^{WAF1/CIP1} expression among the four groups of trophoblastic tissues as well as correlation with p53 and Ki67 immunoreactivity was performed with the Mann-Whitney and Pearson tests.

Results

Immunostaining for p21^{WAF1/CIP1} protein product was predominantly found in the nuclei of syncytiotrophoblast cells in the normal placentas, partial hydatidiform moles, complete hydatidiform moles, and choriocarcinomas (fig 1). Mitotic figures were not immunoreactive for p21^{WAF1/CIP1} protein. Occasional stromal cells in the chorionic villi and the decidual glandular cells showed weak immunoreactivity for p21^{WAF1/CIP1}, while the endothelium and decidual stromal cells were negative. Regional variation in staining of trophoblast cells was observed in the same section.

The staining was found to be heterogeneous in the different groups of trophoblastic tissue studied. Table 1 shows the wide range of variation in the p21^{WAF1/CIP1} immunoreactivity for each group of patients. The complete hydatidiform moles and choriocarcinomas had a significantly higher p21^{WAF1/CIP1} expression compared with normal placentas and partial hydatidiform moles ($p < 0.001$), while there was no difference between placentas and partial hydatidiform moles (table 2).

The normal placentas and the hydatidiform moles were divided into two groups based on their gestational age (< 20 weeks and > 20 weeks). The p21^{WAF1/CIP1} indices of each of these groups were compared. p21^{WAF1/CIP1} protein expression correlated with gestational age in normal placentas ($p = 0.0001$), with higher expression in early gestation. No such

Table 1 p21^{WAF1/CIP1} index (% of positively stained nuclei/total number of nuclei counted)

	Number of cases	Mean (SD) (%)
Placentas	33	5.2 (8.7)
Partial hydatidiform moles	28	9.8 (9.3)
Complete moles	54	20.7 (5.0)
Choriocarcinomas	13	23.3 (20.1)

Table 2 Comparison of p21^{WAF1/CIP1} indexes

	Placentas	PM	CM	CCA
Placentas				
PM				
CM	*	*		
CCA	*	*		

*Significant difference.

PM, partial hydatidiform moles; CM, complete moles; CCA, choriocarcinomas.

correlation was observed in partial hydatidiform moles or complete hydatidiform moles ($p = 0.89$).

p21^{WAF1/CIP1} expression was found to be independent of p53 protein accumulation ($p = 0.68$). Cases with a high Ki67 index seemed to show high p21^{WAF1/CIP1} immunoreactivity; however, no significant difference was demonstrated ($p = 0.34$). There was also no statistical correlation ($p > 0.05$) in p21^{WAF1/CIP1} expression between the 17 patients who required chemotherapy and the 54 patients with spontaneous regression of the disease.

Discussion

Deregulation of cell proliferation and differentiation is important in neoplastic transformation. p21^{WAF1/CIP1} is known to be related to the control of proliferation and differentiation of cells. In normal cells, p21^{WAF1/CIP1} exists in quaternary complexes with cyclin, CDK, and proliferating cell nuclear antigen (PCNA). p21^{WAF1/CIP1} can induce G₁ arrest and block entry into the S phase by inactivating CDKs or by inhibiting the activity of PCNA.¹¹ On the other hand, induction of p21^{WAF1/CIP1} expression has been demonstrated during differentiation of various cell types, both during embryological development^{12,13} and in *in vitro* experiments.⁵ Although the expression of p21^{WAF1/CIP1} varies among different human tissues, it occurs mainly in quiescent cells.¹⁴ For example, p21^{WAF1/CIP1} immunoreactivity in colonic normal mucosa and adenomas was seen in the superficial third of the crypts (maturation compartment) and in surface (terminally differentiated) epithelium.¹⁵ Thus, p21^{WAF1/CIP1} may be important in the maintenance of growth arrest in terminally differentiated cells by inhibiting DNA synthesis.^{5,12}

In this study on trophoblastic tissues, p21^{WAF1/CIP1} immunoreactivity in normal placenta and gestational trophoblastic disease, irrespective of gestational age, was demonstrated mainly in the terminally differentiated syncytiotrophoblast, while that for p53 and the proliferation marker Ki67 was found almost exclusively in the germinal layer of cytotrophoblast.^{8,9} These results suggest that p21^{WAF1/CIP1} might be associated with the senescence and terminal differentiation of trophoblastic tissue and is in agreement with the conventional belief that the syncytiotrophoblast is the differentiated zone of the placenta.

There are two issues that we would like to address: what initiates the overexpression of p21^{WAF1/CIP1} in gestational trophoblastic diseases, especially complete hydatidiform moles and choriocarcinomas; and what are the biological consequences of p21^{WAF1/CIP1} overexpression.

Although p21^{WAF1/CIP1} was first established as a negative regulator of the cell cycle through a p53 dependent pathway,^{1,2,16} induction of p21^{WAF1/CIP1} can also be produced by p53 independent mechanisms.¹⁷⁻¹⁹ In trophoblastic tissues, there appears to be a higher expression of p21^{WAF1/CIP1} with increasing expression of wild-type p53. However, the correlation did not reach significance ($p = 0.68$). While these

data do not exclude a component of p53 dependent p21^{WAF1/CIP1} expression, it is likely that other p53 independent mechanisms are operating.

A review of the literature also shows a lack of correlation between p21^{WAF1/CIP1} expression and p53 status in cancers of the lung, stomach, pancreas, breast, and ovary.²⁰⁻²⁵ A finding that is of particular interest is the p53 independent induction of p21^{WAF1/CIP1} expression during terminal differentiation in various cell lineages.^{12,13} In differentiated cells, such as are found in the syncytiotrophoblast, p53 independent p21^{WAF1/CIP1} expression is probably involved in cell cycle withdrawal. p21^{WAF1/CIP1} expression may also be induced by other factors related to differentiation and growth arrest.⁵ Epidermal growth factor (EGF) and fibroblast growth factor (FGF) have been found to induce p21^{WAF1/CIP1} expression.¹⁷

One question that has not been answered by this study is the functional status of the p21^{WAF1/CIP1} protein found to be overexpressed in the trophoblastic tissue. It is known that mutations of the p21^{WAF1/CIP1} gene can abolish its tumour suppressor activity.²⁶ However, no mutations of the p21^{WAF1/CIP1} gene have been detected in various studies on carcinomas of the lung, pancreas,²⁷ oral cavity,²⁸ and colon,²⁹ as well as melanomas³⁰ and the study of Shiohara *et al*, which investigated 351 cases of 14 different types of human malignancy.³¹ Future sequencing studies may be necessary to determine whether p21^{WAF1/CIP1} mutation occurs in gestational trophoblastic disease.

As p21^{WAF1/CIP1} negatively regulates cell cycle progression, an inverse correlation between p21 expression and proliferative activity or malignant behaviour would be expected. In gestational trophoblastic disease, the pattern is complex. At the single cell level, p21^{WAF1/CIP1} and MIB1 immunoreactivity were observed separately in the syncytiotrophoblast and cytotrophoblast, respectively. Such a mutually exclusive pattern involving p21^{WAF1/CIP1} and Ki67 expression has also been observed in colonic¹⁵ and gastric²⁰ tissues. p21^{WAF1/CIP1} expression in early placentas, which display more active trophoblastic proliferation, is higher than in mature placentas, where the proliferative activity is lower.^{9,32,33} Yet, statistically significant direct correlation between p21^{WAF1/CIP1} expression and proliferative activity could not be established in gestational trophoblastic disease.

This lack of correlation between p21^{WAF1/CIP1} expression and the proliferative (Ki67) index has also been reported in cancers of the stomach, colon, breast, and ovary.^{15,20,23-25,34} Yasui *et al* suggested that tumour cells might have escaped terminal differentiation and growth arrest by becoming refractory to the inhibitory signals from p21^{WAF1/CIP1}.²⁰ Moreover, proliferation and progression of trophoblastic tissues may be regulated by factors other than p21^{WAF1/CIP1}.

Association of p21^{WAF1/CIP1} overexpression with tumorigenesis has been well established. In most neoplasms, p21^{WAF1/CIP1} protein and RNA were expressed at higher levels than in the corresponding normal tissues. For example, the levels of p21^{WAF1/CIP1} expression in normal or

reactive brain and lung tissue were much lower than in gliomas or pulmonary carcinoma.²¹⁻³⁵ Complete hydatidiform mole has a higher potential to develop persistent gestational trophoblastic disease compared with partial hydatidiform mole and, according to the beliefs of most gynaecological oncologists, only complete hydatidiform mole will develop into choriocarcinoma.⁶⁻⁷ Our findings that complete hydatidiform mole and choriocarcinoma have a higher level of p21^{WAF1/CIP1} expression concur with the association between p21^{WAF1/CIP1} expression and tumorigenesis.

We were thus interested to see whether p21^{WAF1/CIP1} expression can predict the clinical behaviour of trophoblastic diseases. Our previous studies on PCNA, Ki67, and p53 showed that these indices could not predict the progression of molar pregnancies to persistent trophoblastic disease⁹⁻³³ (Cheung *et al*, unpublished data). In this study, there was no significant difference in the p21^{WAF1/CIP1} index between the patients who developed persistent gestational trophoblastic diseases and those who did not. Thus, the p21^{WAF1/CIP1} index is not useful in predicting the prognosis of molar pregnancies.

To conclude, our study demonstrates a complex relation between p21^{WAF1/CIP1} expression and phenotypes of gestational trophoblastic disease. p21^{WAF1/CIP1} is found to be overexpressed in gestational trophoblastic disease compared with the normal placenta, although p21^{WAF1/CIP1} expression could not predict the clinical progress of the disease. p21^{WAF1/CIP1} expression did not correlate with proliferative activity or p53 expression. This is compatible with the observation that p21^{WAF1/CIP1}, p53, and Ki67 immunoreactivity operate in different populations of trophoblasts. This also suggests that the proliferative activity in trophoblastic tissue may be controlled by factors other than p21^{WAF1/CIP1}. The lack of correlation with p53 expression supports the possibility that p21^{WAF1/CIP1} is being induced at least in part by p53 independent mechanisms.

This study was supported by Research Grant Council Grant (377-030-7863) from the University of Hong Kong.

- 1 Harper JW, Adami GR, Wei N, *et al*. The p21 cdk-interacting protein Cip1 is a potent inhibitor of G1 cyclin-dependent kinases. *Cell* 1993;75:805-16.
- 2 El-Deiry WS, Tokino T, Velculescu VE, *et al*. WAF1, a potential mediator of p53 tumour suppression. *Cell* 1993;75:817-25.
- 3 El-Deiry WS, Harper JW, O'Connor PM, *et al*. WAF1/CIP1 is induced in p53-mediated G1 arrest and apoptosis. *Cancer Res* 1994;54:1169-74.
- 4 Guillot C, Falette N, Paperin MP, *et al*. p21(WAF1/CIP1) response to genotoxic agents in wild-type TP53 expressing breast primary tumours. *Oncogene* 1997;14:45-52.
- 5 Steinman RA, Hoffman B, Iro A, *et al*. Induction of p21 (WAF-1/CIP1) during differentiation. *Oncogene* 1994;9:3389-96.
- 6 Mazur MT, Kurman RJ. Gestational trophoblastic disease. In: Kurman RJ, ed. *Blaustein's pathology of female genital tract*. New York: Springer-Verlag, 1994:1049-93.
- 7 Elston CW. Gestational trophoblastic disease. In: Fox H, ed. *Haines and Taylor: obstetrical and gynaecological pathology*. Edinburgh: Churchill Livingstone, 1997:1597-640.
- 8 Cheung ANY, Srivastava G, Chung LP, *et al*. Expression of the p53 gene in trophoblastic cells in hydatidiform moles and normal human placentas. *J Reprod Med* 1994;39:223-7.
- 9 Cheung ANY, HYS Ngan, Collins RJ, *et al*. Assessment of cell proliferation in hydatidiform mole using monoclonal antibody MIB1 to Ki-67 antigen. *J Clin Pathol* 1994;47:601-4.
- 10 Ma HK, Wong LC, Ngan HYS. The modern management of trophoblastic disease. In: Nonnar J, ed. *Recent advances in obstetrics and gynaecology*. Edinburgh: Churchill Livingstone, 1990:1-23.
- 11 Waga S, Hannon GJ, Beach D, *et al*. The p21 inhibitor of cyclin-dependent kinases controls DNA replication by interaction with PCNA. *Nature* 1994;369:574-8.
- 12 Parker SB, Eichele G, Zhang P, *et al*. p53 independent expression of p21^{Cip1} in muscle and other terminally differentiating cells. *Science* 1995;267:1024-7.
- 13 Halevy O, Novitch BG, Spicer DB, *et al*. Correlation of terminal cell cycle arrest of skeletal muscle with induction of p21 by MyoD. *Science* 1995;267:1018-21.
- 14 Fredersdorf S, Milne AW, Hall PA, *et al*. Characterization of a panel of novel anti-p21Waf1/Cip1 monoclonal antibodies and immunochemical analysis of p21Waf1/Cip1 expression in normal human tissues. *Am J Pathol* 1996;148:825-35.
- 15 Doglioni C, Pelosio P, Laurino L, *et al*. p21/WAF1/CIP1 expression in normal mucosa and in adenomas and adenocarcinomas of the colon: its relationship with differentiation. *J Pathol* 1996;179:248-53.
- 16 Xiong Y, Hannon GJ, Zhang H, *et al*. p21 is a universal inhibitor of cyclin kinases. *Nature* 1993;366:701-4.
- 17 Michieli P, Cheddidi M, Lin D, *et al*. Induction of WAF1/CIP1 by a p53-independent pathway. *Cancer Res* 1994;54:3391-5.
- 18 Zhang W, Grasso L, McClain CD, *et al*. p53 independent G₁ arrest and apoptosis induced by a novel retinoid in human breast cancer cells. *Oncogene* 1995;11:493-504.
- 19 Johnson M, Dimitrov D, Vojta PJ, *et al*. Evidence for a p53-independent pathway for upregulation of SDI1/CIP1/WAF1 p21 RNA in human cells. *Mol Carcinog* 1994;11:59-64.
- 20 Yasui W, Akama Y, Kuniyasu H, *et al*. Expression of cyclin-dependent kinase inhibitor p21WAF1/CIP1 in non-neoplastic mucosa and neoplasia of the stomach: relationship with p53 status and proliferative activity. *J Pathol* 1996;180:122-8.
- 21 Marchetti A, Doglioni C, Barbareschi M, *et al*. p21 RNA and protein expression in non-small cell lung carcinomas: evidence of p53-independent expression and association with tumoral differentiation. *Oncogene* 1996;12:1319-24.
- 22 DiGiuseppe JA, Redston MS, Yeo CJ, *et al*. p53-independent expression of the cyclin-dependent kinase inhibitor p21 in pancreatic carcinoma. *Am J Pathol* 1995;147:884-8.
- 23 Barbareschi M, Caffo O, Doglioni C, *et al*. p21WAF1 immunohistochemical expression in breast carcinoma: correlations with clinicopathological data, oestrogen receptor status, MIB1 expression, p53 gene and protein alterations and relapse-free survival. *Br J Cancer* 1996;74:208-15.
- 24 Barboule N, Mazars P, Baldin V, *et al*. Expression of p21WAF1/CIP1 is heterogeneous and unrelated to proliferation index in human ovarian carcinoma. *Int J Cancer* 1995;63:611-15.
- 25 Werness BA, Jobe JS, DiCioccio RA, *et al*. Expression of the p53 induced tumour suppressor p21^{waf1/cip1} in ovarian carcinomas: correlation with p53 and Ki67 immunohistochemistry. *Int J Gynecol Pathol* 1997;16:149-55.
- 26 Lin J, Reichner C, Wu X, *et al*. Analysis of wild-type and mutant p21WAF-1 gene activities. *Mol Cell Biol* 1996;16:1786-93.
- 27 Shimizu T, Miwa W, Nakamori S, *et al*. Absence of a mutation of the p21/WAF1 gene in human lung and pancreatic cancers. *Jpn J Cancer Res* 1996;87:275-8.
- 28 Heinzl PA, Balaran P, Bernard HU. Mutations and polymorphisms in the p53, p21 and p16 genes in oral carcinomas of Indian betel quid chewers. *Int J Cancer* 1996;68:420-3.
- 29 Li YJ, Laurent-Puig P, Salmon RJ, *et al*. Polymorphism and probable lack of mutation in the WAF1-CIP1 in colorectal cancer. *Oncogene* 1995;10:599-601.
- 30 Vidal MJ, Loganzo F Jr, de Oliveira AR, *et al*. Mutations and defective expression of the WAF1 p21 tumour-suppressor gene in malignant melanomas. *Melanoma Res* 1995;5:243-50.
- 31 Shiohara M, el Deiry WS, Wada M, *et al*. Absence of WAF1 mutations in a variety of human malignancies. *Blood* 1994;84:3781-4.
- 32 Boyd PA. Quantitative studies of the normal human placenta from 10 weeks of gestation to term. *Early Hum Dev* 1984;9:297-307.
- 33 Cheung ANY, Ngan HYS, Chen WZ, *et al*. The significance of proliferating cell nuclear antigen in human trophoblastic disease: an immunohistochemical study. *Histopathology* 1993;22:565-8.
- 34 El-Deiry WS, Tokino T, Waldman T, *et al*. Topological control of p21WAF1/CIP1 expression in normal and neoplastic tissues. *Cancer Res* 1995;55:2910-19.
- 35 Jung JM, Bruner JM, Ruan S, *et al*. Increased levels of p21WAF1/Cip1 in human brain tumors. *Oncogene* 1995;11:2021-8.