



Title	A cluster of cases of severe acute respiratory syndrome in Hong Kong
Author(s)	Tsang, KW; Ho, PL; Ooi, GC; Yee, WK; Wang, T; ChanYeung, M; Lam, WK; Seto, WH; Yam, LY; Cheung, TM; Wong, PC; Lam, B; Ip, MS; Chan, J; Yuen, KY; Lai, KN
Citation	New England Journal Of Medicine, 2003, v. 348 n. 20, p. 1977-1985
Issued Date	2003
URL	http://hdl.handle.net/10722/43134
Rights	Creative Commons: Attribution 3.0 Hong Kong License

ORIGINAL ARTICLE

A Cluster of Cases of Severe Acute Respiratory Syndrome in Hong Kong

Kenneth W. Tsang, M.D., Pak L. Ho, M.D., Gaik C. Ooi, M.D., Wilson K. Yee, M.D.,
Teresa Wang, M.D., Moira Chan-Yeung, M.D., Wah K. Lam, M.D.,
Wing H. Seto, M.D., Loretta Y. Yam, M.D., Thomas M. Cheung, M.D.,
Poon C. Wong, M.D., Bing Lam, M.D., Mary S. Ip, M.D., Jane Chan, M.D.,
Kwok Y. Yuen, M.D., and Kar N. Lai, M.D., D.Sc.

ABSTRACT

BACKGROUND

Information on the clinical features of the severe acute respiratory syndrome (SARS) will be of value to physicians caring for patients suspected of having this disorder.

METHODS

We abstracted data on the clinical presentation and course of disease in 10 epidemiologically linked Chinese patients (5 men and 5 women 38 to 72 years old) in whom SARS was diagnosed between February 22, 2003, and March 22, 2003, at our hospitals in Hong Kong, China.

RESULTS

Exposure between the source patient and subsequent patients ranged from minimal to that between patient and health care provider. The incubation period ranged from 2 to 11 days. All patients presented with fever (temperature, $>38^{\circ}\text{C}$ for over 24 hours), and most presented with rigor, dry cough, dyspnea, malaise, headache, and hypoxemia. Physical examination of the chest revealed crackles and percussion dullness. Lymphopenia was observed in nine patients, and most patients had mildly elevated aminotransferase levels but normal serum creatinine levels. Serial chest radiographs showed progressive air-space disease. Two patients died of progressive respiratory failure; histologic analysis of their lungs showed diffuse alveolar damage. There was no evidence of infection by *Mycoplasma pneumoniae*, *Chlamydia pneumoniae*, or *Legionella pneumophila*. All patients received corticosteroid and ribavirin therapy a mean (\pm SD) of 9.6 ± 5.42 days after the onset of symptoms, and eight were treated earlier with a combination of beta-lactams and macrolide for 4 ± 1.9 days, with no clinical or radiologic efficacy.

CONCLUSIONS

SARS appears to be infectious in origin. Fever followed by rapidly progressive respiratory compromise is the key complex of signs and symptoms from which the syndrome derives its name. The microbiologic origins of SARS remain unclear.

From the University Departments of Medicine (K.W.T., M.C.-Y., W.K.L., P.C.W., B.L., M.S.I., J.C., K.N.L.), Clinical Microbiology (P.L.H., T.W., W.H.S., K.Y.Y.), and Diagnostic Radiology (G.C.O.), University of Hong Kong; the Department of Medicine, Kwong Wah Hospital (W.K.Y.); and the Department of Medicine, Pamela Youde Nethersole Eastern Hospital (L.Y.Y., T.M.C.) — all in Hong Kong, China. Address reprint requests to Dr. Lai at the University Department of Medicine, University of Hong Kong, Queen Mary Hospital, Pokfulam, Hong Kong, China.

This article was published at www.nejm.org on March 31, 2003.

N Engl J Med 2003;348:1977-85.

Copyright © 2003 Massachusetts Medical Society.

IN THE FALL OF 2002, THERE WERE REPORTS from Guangdong Province in southern China of 305 cases of highly contagious and very severe atypical pneumonia of unknown cause. The condition appeared to be particularly prevalent among health care workers and their household members; many cases were rapidly fatal.¹ On March 13, 2003, as the condition began to spread from China, the World Health Organization (WHO) issued a global alert about the outbreak and instituted worldwide surveillance. In March the U.S. Centers for Disease Control and Prevention (CDC) termed this condition the severe acute respiratory syndrome (SARS) and provided a clinical case definition.² Herein we report the clinical, radiologic, and laboratory features of 10 of our patients with SARS whose cases were epidemiologically linked. Since the microbiology of these cases remains unresolved, we provide the clinical and epidemiologic information for use in case recognition and management.

METHODS

PATIENTS

Between February 22 and March 22, 2003, we identified 10 epidemiologically linked patients (all southern Chinese) whose disease met the CDC case definition of March 17, 2003, of SARS at our hospital cluster (Queen Mary Hospital, Kwong Wah Hospital, and Pamela Youde Nethersole Eastern Hospital) in Hong Kong (Table 1).² Patients were interviewed to ascertain their possible contacts with each other, as noted in Figure 1.

RADIOLOGIC ASSESSMENT

The chest radiographs of 10 patients were evaluated without reference to clinical details. Volumetric contrast-enhanced computed tomography (CT) with high-resolution CT scanning of the thorax was available in three patients (Patients 3, 4, and 10), and these were also reviewed. The pattern of opacification was categorized as air space (ground-glass opacification, focal consolidation, lobar consolidation, or patchy consolidation), interstitial (reticular), or diffuse (affecting all lung zones). The presence of pleural effusions was also noted.

MICROBIOLOGIC EVALUATION

Respiratory secretions (sputum in all patients and tracheal aspirate and bronchoalveolar-lavage fluid in Patients 1, 2, and 3) were analyzed for convention-

al bacteria (with blood, chocolate, and MacConkey agars), *Legionella pneumophila* (with BCYE α medium), and mycobacteria (with LJ medium). Gram-stained and auramine-rhodamine-stained smears were examined to search for bacterial or acid-fast morphotypes.

Single or, when available, paired serum samples were tested for *Mycoplasma pneumoniae* (Serodia-Myco-II, Fujirebio) and *Chlamydia pneumoniae* and *C. psittaci* (MRL microimmunofluorescence kit). Urinary antigen detection (Binax Now test kits, Binax) was performed for *L. pneumophila* and pneumococcus. Immunofluorescence techniques were used to detect antigens in nasopharyngeal aspirates (and bronchoalveolar-lavage fluid in Patient 1) with commercially available reagents from Dako Diagnostics and Chemicon International.

RESULTS

PATIENTS AND CONTACT HISTORY

The mean (\pm SD) age of the 10 patients (5 men and 5 women) was 52.5 \pm 11.0 years (median, 49.5; range, 35 to 72). Except as noted below, all of the patients had unremarkable medical histories. Patient 2 had stable hypertension and benign prostatic hypertrophy, Patient 4 had ischemic heart disease and non-insulin-dependent diabetes mellitus, and Patient 10 had non-insulin-dependent diabetes and resected renal-cell carcinoma of the right kidney. Patient 2 was taking metoprolol and nifedipine; Patient 4 was taking aspirin, diltiazem, and metformin; and Patient 10 was taking gliclazide and metformin. Eight of the 10 patients had never smoked, 1 was a current smoker (25 cigarettes per day), and 1 was a former smoker (20 cigarettes per day) who had stopped five years earlier.

The contact history among the patients in this cluster is shown in Figure 1A. Patient 1, who had the first known case of SARS in Hong Kong, was a nephrologist working in a hospital in southern China who had traveled to Hong Kong on February 21, 2003, having first had symptoms five days earlier. On arrival in Hong Kong he felt well enough to sightsee and shop with his brother-in-law, but the next day he sought urgent care and was directly admitted to the intensive care unit (ICU) of Hospital A with respiratory failure. Patient 2, a Hong Kong resident, was the brother-in-law of Patient 1 and had had social contact with Patient 1 for 10 hours while sightseeing and shopping. Patient 3 was a nurse in the accident and emergency department

Table 1. Characteristics of the Patients on Presentation.*											
	Patient No.										Summary
	1	2	3	4	5	6	7	8	9	10	
Sex	M	M	F	M	F	F	F	F	M	M	—
Age (yr)	64	53	35	72	56	38	47	54	50	56	52.5±11.0
Smoking history	Never	Never	Never	Never	Never	Never	Never	Never	Current	Former	
Symptoms											
Cough	+	-	+	+	+	+	+	+	+	-	8+
Sputum production	-	-	-	-	-	+	-	-	-	-	1+
Dyspnea	+	+	-	+	-	+	+	+	-	-	6+
Pleurisy	+	-	+	-	-	+	-	-	-	-	3+
Sore throat	-	-	-	-	-	-	-	-	-	-	—
Rhinorrhea	-	-	-	-	-	+	-	-	-	-	1+
Malaise	+	+	-	-	-	+	+	+	+	+	7+
Myalgia	+	+	-	-	-	+	+	-	+	-	5+
Rigor	+	+	+	+	+	+	+	+	+	-	9+
Fever (temperature >38°C for 24 hr)	+	+	+	+	+	+	+	+	+	+	10+
Headache	+	+	+	-	-	+	+	+	+	-	7+
Physical signs											
Crackles	+	+	+	+	+	+	-	+	+	+	9+
Percussion dullness	+	+	+	+	+	-	-	-	+	+	7+
Hemoglobin (g/dl)	13.7	13.7	11.4	13.5	14.3	11.6	13.3	11.4	14.2	11.6	12.9±1.22
Leukocyte count (×10 ⁹ /liter)	12.2	11.4	3.6	8.6	9.3	5.6	6.1	5.2	3.2	5.9	7.1±3.1
Lymphocyte count (×10 ⁹ /liter)	1.2	1.6	0.8	0.6	1.4	0.4	0.9	0.6	1.3	0.6	0.9±0.4
Platelet count (×10 ⁹ /liter)	239	160	134	245	309	170	235	115	161	354	212.2±77.8
ALT (U/liter)	62	48	16	21	63	20	198	14	58	78	57.8±54.4
AST (U/liter)	84	67	35	51	62	—	—	—	96	103	71.1±24.5†
Creatinine (μmol/liter)	77	84	80	115	81	69	57	66	103	148	88.0±27.1
PaCO ₂ on room air (kPa)	3.51	4.4	NA	4.8	3.4	NA	NA	NA	3.8	NA	4.0±0.6
PaO ₂ on room air (kPa)	6.7	8.3	NA	7.0	10.2	NA	NA	NA	11.9	NA	8.8±2.2‡
Oxygen saturation on room air (%)	60	91	97	80	94	94	96	93	96	99	90±11.8‡

* Plus-minus values are means ±SD. A plus sign indicates that the sign or symptom was present, and a minus sign that it was absent. Normal ranges are as follows: for hemoglobin, 13 to 18 g per deciliter; for the leukocyte count, 4×10⁹ to 11×10⁹ per liter; for the lymphocyte count, 1.5×10⁹ to 4×10⁹ per liter; for the platelet count, 150×10⁹ to 400×10⁹ per liter; for alanine aminotransferase (ALT), 6 to 53 U per liter; for aspartate aminotransferase (AST), 13 to 33 U per liter; for creatinine, 82 to 106 μmol per liter; for the partial pressure of carbon dioxide (PaCO₂), 4.7 to 6.0 kPa; and for the partial pressure of oxygen (PaO₂), 12 to 17 kPa. To convert values for creatinine to milligrams per deciliter, divide by 88.4. NA denotes not available.

† Data were available for seven patients.

‡ Data were available for five patients.

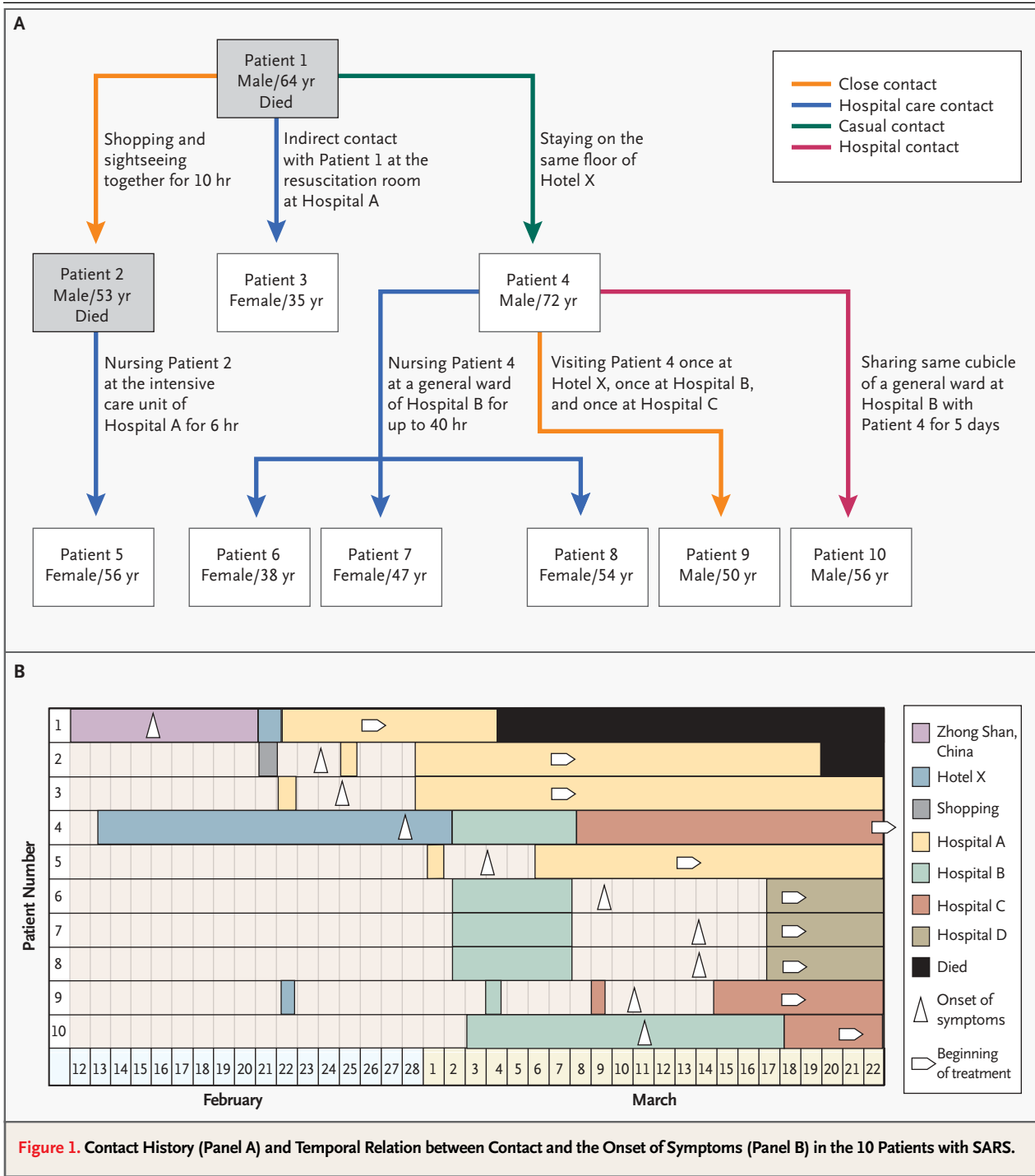


Figure 1. Contact History (Panel A) and Temporal Relation between Contact and the Onset of Symptoms (Panel B) in the 10 Patients with SARS.

of Hospital A who was present in the same resuscitation room but at least 1 m away from Patient 1, who was being treated by another team of physicians and nurses. Patient 3 had no direct contact with Patient 1 and was wearing a surgical mask at

the time. Patient 5 was a health care assistant who worked in the ICU of Hospital A and had unprotected hospital contact (without a mask or gown) with Patient 2 for six hours.

Patient 4 was a Chinese-Canadian businessman

who had returned to Hong Kong for a family reunion on February 13, 2003. He had not traveled outside Toronto for more than 12 months before his return to Hong Kong. His stay at Hotel X overlapped with that of Patient 1 for one day. There was no known direct contact between Patient 1 and Patient 4. Patient 4 could not recollect whether he had seen Patient 1 in the common areas of the hotel. Patients 6, 7, and 8 were nurses who worked at Hospital B, where Patient 4 was admitted and remained for six days for treatment of pneumonia before he was transferred to Hospital C. During this period, the nurses spent five eight-hour shifts stationed on the general ward on which Patient 4 was hospitalized. The three nurses recalled a close encounter with Patient 4 during which they cleaned him when he had fecal incontinence after an episode of diarrhea on March 3, 2003. The nurses did not wear masks or gowns during their routine nursing care of any patients on the ward. Patient 9 was the nephew of Patient 4 and visited him once at Hotel X, once at Hospital B, and once in the ICU of Hospital C, each time for 10 minutes. At the last of these visits, Patient 4 was receiving noninvasive positive-pressure ventilation. Patient 10 stayed in the same cubicle (with six beds) on the same ward of Hospital B as Patient 4 for a total of five days while recovering uneventfully from a total nephrectomy for a resectable right renal-cell carcinoma. Another bed separated them from one another. There was no social or other contact between the two patients, who were both largely bedridden. Apart from these contacts, and with the exception of Patient 1, none of the patients had any known contacts with anyone with respiratory illness or had traveled to southern China, Vietnam, or Singapore for at least three months.

Figure 1B shows the temporal relation between contact and the onset of symptoms in the 10 patients. The incubation period, calculated as the number of days between likely exposure and the onset of symptoms,³ could be precisely determined only for Patients 2, 3, 4, and 5 (two, two, six, and two days, respectively), since the other patients had multiple contacts with the source patients. The ranges of possible incubation periods were 1 to 6, 5 to 11, 5 to 11, 1 to 5, and 2 to 7 days for Patients 6, 7, 8, 9, and 10, respectively.

CLINICAL AND OTHER FEATURES

All 10 patients presented with fever (temperature, >38°C for more than 24 hours), and all but 1 also had rigor (Table 1). There was a median interval of

five days (range, three to seven) from the onset of fever to the occurrence of dyspnea. All patients remained febrile until the initiation of empirical treatment with corticosteroids and ribavirin. Over half the patients also reported a nonproductive cough, dyspnea, malaise, and headache on presentation. On physical examination of the chest, crackles and dullness on percussion were detected in most patients. The results of cardiovascular, abdominal, and neurologic examination were normal in all patients given their known preexisting conditions. Mild leukocytosis and leukopenia were each observed in two patients at initial presentation. Lymphopenia (less than 1500 cells per cubic millimeter) was observed in nine patients; clinically significant thrombocytopenia (less than 50,000 platelets per cubic millimeter) was not observed. The aspartate aminotransferase level, alanine aminotransferase level, or both were elevated slightly (to less than four times the upper limit of the reference range in seven patients); serum creatinine levels were normal in eight patients. Five patients presented with hypoxemia, and three (Patients 4, 6, and 8) had infrequent diarrhea in the first three days after the onset of fever. The onset of diarrhea could not be attributed to antibiotic therapy in Patients 6 and 8, since they had not received such treatment before its onset.

MICROBIOLOGIC ASSESSMENT

The sputum culture yielded only commensal species (Table 2). Acid-fast staining of all respiratory secretions was negative in each patient. Examination of nasopharyngeal aspirates for rapid viral antigen detection of influenza virus A and B, parainfluenza virus 1, 2, and 3, respiratory syncytial virus, and adenovirus was negative. The serologic titers of *C. pneumoniae*, *C. psittaci*, and *M. pneumoniae* showed no significant increase over a period of 7 to 10 days in the entire cohort. Urinary antigen detection for *L. pneumophila* and pneumococcus was negative in all cases. At this time, the microbiologic origin of SARS was unknown.

RADIOLOGIC ASSESSMENT

All patients except Patient 2 had abnormal chest radiographs on presentation. The primary abnormality on the initial chest radiograph was air-space shadowing: ground-glass opacities (in Patients 4, 5, and 10), focal consolidation (in Patients 3 and 9), or patchy consolidation (Patients 6, 7, and 8) (Fig. 2A). No interstitial pattern was found on the chest radiographs. Opacities were predominantly in the lower lung zones in eight patients (Patients 2, 3,

Table 2. Results of Microbiologic Assessment in 10 Patients with SARS.*

Patient No.	Sputum Culture	Sputum AFB Smear	NPA	Serologic Analysis			Urinary Antigen Detection	
				<i>C. pneumoniae</i>	<i>C. psittaci</i>	<i>M. pneumoniae</i>	<i>S. pneumoniae</i>	<i>L. pneumophila</i>
1	C	—	—	<1:32	<1:32	<1:40	ND	ND
2	C	—	—	<1:32	<1:32	<1:40	ND	ND
3	C	—	—	<1:32	<1:32	<1:40	ND	ND
4	C	NA	NA	<1:32	<1:32	<1:40	—	—
5	C	—	—	<1:32	<1:32	<1:40	ND	ND
6	C	—	—	1:32	<1:32	<1:40	—	—
7	C	—	—	<1:32	<1:32	<1:40	—	—
8	C	—	—	<1:32	1:32	<1:40	—	—
9	C	—	—	1:32	<1:32	<1:40	—	—
10	C	NA	NA	1:128	<1:32	<1:40	—	—

* C denotes commensals, AFB acid-fast bacilli, NPA nasopharyngeal aspirate for rapid viral antigen detection, NA not available, and ND not done.

5, 6, 7, 8, 9, and 10) and in upper zones in one (Patient 4). None of the patients had pleural effusions.

The air-space opacities increased in size, extent, and severity in seven patients (Patients 3, 4, 5, 6, 7, 9, and 10) within the first 10 days after admission. The chest radiograph of Patient 1 did not show clinically significant changes from presentation to death; a diffuse miliary nodulation was noted throughout. In Patient 2, the chest radiograph remained unremarkable for more than a week, after which diffuse opacification appeared (Fig. 2B); a similar course was observed in Patient 5. Among the survivors, six patients (Patients 3, 4, 6, 8, 9, and 10) had some improvement of the air-space opacities, with variable residual reticular opacities, within two weeks after presentation.

Predominant abnormalities found on initial CT scans were subpleural focal consolidation with air bronchograms and ground-glass opacities. These occurred mostly, but not exclusively, in the posterior aspects of the lower lobes (Fig. 2C). No pleural effusions, mediastinal nodes, or central pulmonary emboli were found.

TREATMENT AND OUTCOME

All of the patients were treated empirically with corticosteroids and ribavirin, as noted below. Before this combination was administered, all patients except Patients 7 and 8 received a combination of

a beta-lactam (Augmentin, Rocephin, or Maxipime) and a macrolide (clarithromycin or azithromycin) for a mean (and median) of four days (range, two to six), which had no effect on the overall clinical course, fever, or radiographically evident profusion of disease (Table 2 and Fig. 2 and 3). Empirical treatment consisted of a combination of intravenous ribavirin (8 mg per kilogram of body weight every eight hours) or oral ribavirin (1.2 g every eight hours, in Patient 4 only) and intravenous corticosteroids (hydrocortisone at a dose of 4 mg per kilogram every eight hours tapered to 200 mg every eight hours or methylprednisolone at a dose of 240 to 320 mg daily) in all patients (Fig. 3). There was a mean of 9.6 ± 5.42 days (median, 12.5; range, 3 to 22) between the onset of symptoms and treatment with the combination of corticosteroids and ribavirin. Figure 3 shows the response in temperature, heart rate, oxygen saturation, and total leukocyte, lymphocyte, and platelet counts after the beginning of therapy. There was resolution of fever and improvement in heart rate within the first two days of starting treatment. There was also an increasing trend toward improved lymphocyte and platelet counts after eight days of treatment.

In Patients 1 and 2 there was a steady deterioration in gas exchange despite an increase in ventilatory support from noninvasive support to intubation and mechanical pressure-controlled ventilation with

high positive end-expiratory pressures and a fraction of inspired oxygen of 1.0. Despite intensive physiological support, both patients died. Postmortem examination of the lungs of Patient 1 revealed marked alveolar edema with foci of hemorrhage and hyaline membrane formation. There was desquamation of pneumocytes, but there were few free inflammatory cells, either polymorphonuclear or mononuclear cells in the alveolar spaces. There were scattered foci of alveolar myxoid fibroblastic tissue, a finding consistent with the early organization phase of progressive pneumonia. Inter-alveolar septa were mildly thickened, with a mild mononuclear infiltrate. There was no tissue necrosis, viral inclusions, fungi, or bacteria on the sections. These features were considered to reflect severe diffuse alveolar damage. Patient 2 underwent a biopsy by video-assisted thoracoscopy on day 5 that showed only mild diffuse alveolar damage.

From the onset of disease to the time of this writing, only Patient 3 has had a complete clinical recovery (no supplementary oxygen as of day 12) and radiographic recovery (resolution of right-lower-lobe consolidation on day 18), leading to her discharge on day 20. This patient has continued to have nonspecific malaise, even on day 26. From the onset of symptoms, Patients 4 through 10 have been unwell for 23.1 ± 5.5 days (median, 25.5; range, 18 to 33) and have had a partial radiologic and clinical recovery. Only Patients 4, 7, and 9 are still oxygen-dependent; the mean oxygen saturation was 95.1 ± 2.6 percent (median, 96; range, 90 to 99) in the eight survivors. Patient 3 recovered completely and had no exercise restriction, whereas Patients 4, 7, and 9 were able to walk only three to five steps on the level, and Patients 5, 6, 8, and 10 were able to walk on the level without apparent restriction, within the confines of the isolation wards. Patients 4, 6, 7, 8, and 9 still reported dry cough, which was considered subjectively to be milder than that experienced at the onset of disease. None of the surviving patients reported any of the other symptoms listed in Table 2.

DISCUSSION

Our experience with these 10 epidemiologically linked patients confirms that SARS is a contagious and rapidly progressive infectious disease that can affect otherwise healthy persons, sometimes after even trivial contacts. It is not known why some persons (such as the wife of Patient 4, who stayed in

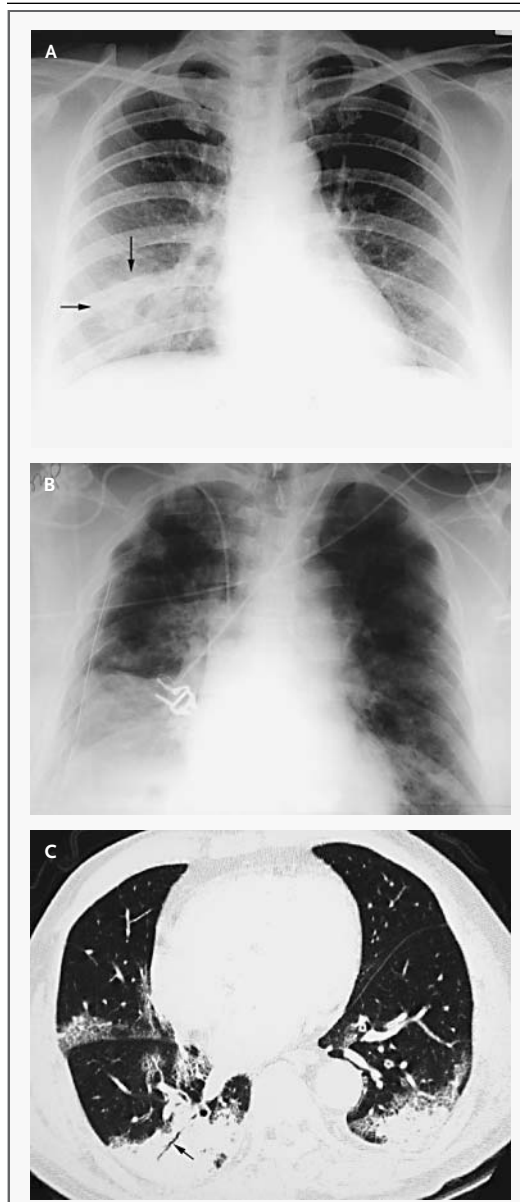


Figure 2. Chest Radiographs of Patient 6 (Panel A), Showing Patchy Consolidation in the Right Lower Zone (Arrows), and Patient 2 (Panel B), Showing Diffuse Involvement of All Lung Zones in Both Lungs, and a High-Resolution CT Scan of Patient 4 (Panel C), Showing Subpleural Areas of Consolidation and Ground-Glass Opacification with Air Bronchogram (Arrow) Affecting the Posterior Aspects of the Lungs, Particularly the Lower Lobes.

the same hotel room with him throughout) remain asymptomatic despite substantial exposure.

SARS presents predominantly with high fever (temperature, $>38^{\circ}\text{C}$ for more than 24 hours) and

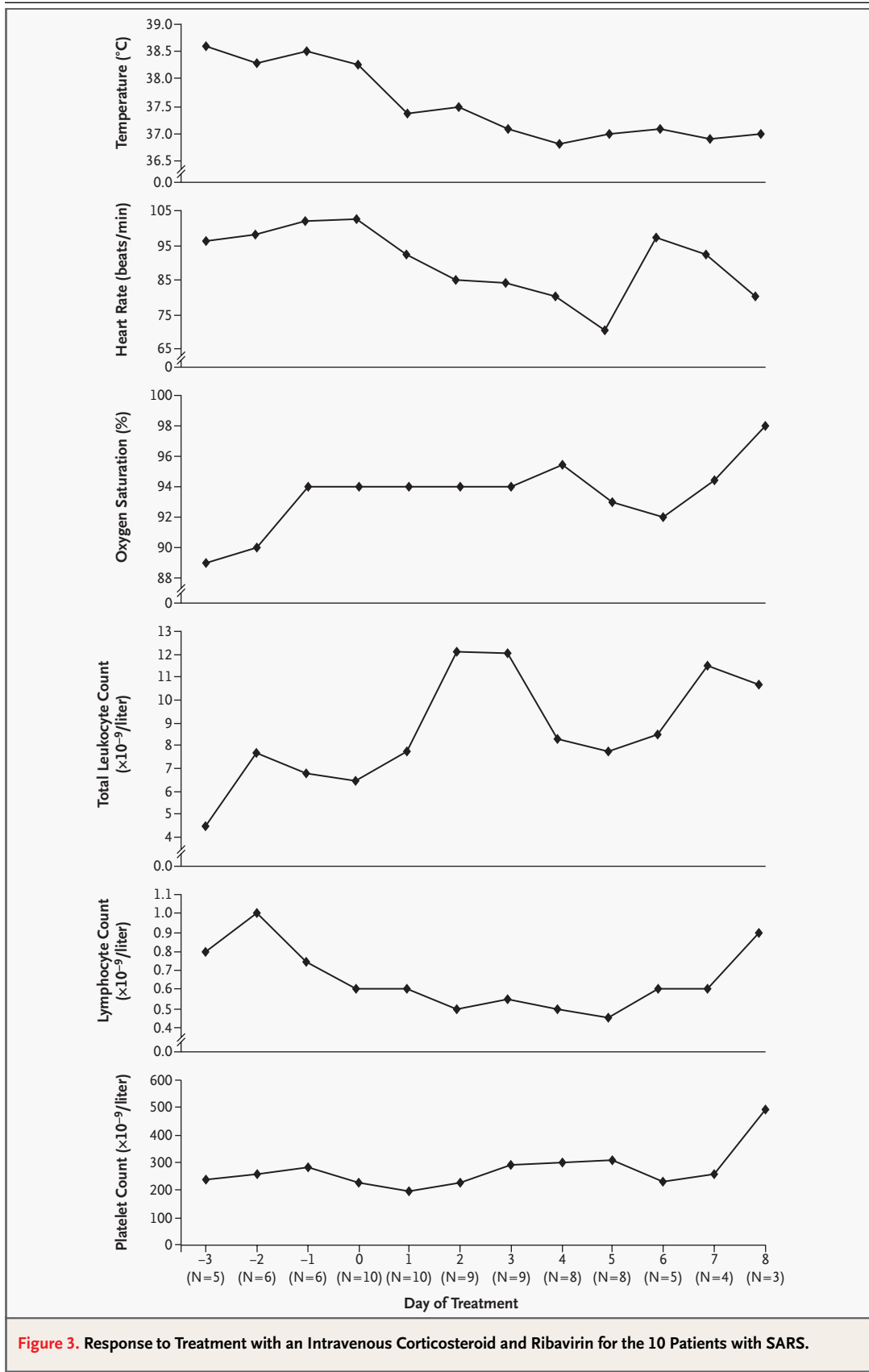


Figure 3. Response to Treatment with an Intravenous Corticosteroid and Ribavirin for the 10 Patients with SARS.

rigor, followed by dry cough, which may in some cases proceed rapidly to respiratory failure, accompanied by radiographic evidence of air-space disease. The incubation period in our patients was between 1 and 11 days, and in most of our clear-cut cases, the patients presented 2 days after exposure. Our experience therefore singles out at-risk exposure (however trivial) to source patients and fever as the most important pointers to the diagnosis of SARS. Indeed, the finding that many people whose condition meets the CDC case definition² of SARS do not have respiratory failure.⁴ Although there was no clinical response to combined therapy with a beta-lactam and a macrolide, empirical treatment with a combination of a high-dose corticosteroid and ribavirin coincided with clinical improvement. Most patients appeared to have clinical and radiographic improvement, although the full time course of the illness is not known. It is also of note that the two patients who died did not have multiorgan failure, as is often the case with patients with the acute respiratory distress syndrome.

The primary radiologic appearance of SARS is air-space shadowing determined on CT to be subpleural focal consolidation with air bronchograms and ground-glass opacities predominantly affecting the lower lobes. The initial radiographic appearance, however, may be normal. Air-space opacification progresses within a few days of presentation, increasing in size, extent, and severity. In some cases, there is further progression to diffuse opacification suggestive of the acute respiratory distress syndrome. Resolution of air-space shadowing occurs with features suggesting that the disease is entering a fibrotic phase. Radiographically, SARS may be indistinguishable from bacterial bronchopneumonia or viral infections, and more important, it shares CT features with other conditions that result in subpleural air-space disease, such as bronchiolitis obliterans with organizing pneumonia and acute

interstitial pneumonia.⁵⁻⁷ In the later stages, particularly with diffuse involvement of the lungs, the radiographic appearance is similar to that of the acute respiratory distress syndrome.

The clinical and radiographic features of the disease in our patients and, in particular, its highly contagious nature strongly point to a viral cause of SARS. Most patients with SARS had the onset of symptoms two to five days after exposure to the respective source patients. Such a short incubation period argues against infection with *M. pneumoniae* or *C. pneumoniae*. For *M. pneumoniae*, the reported incubation period ranges from 6 to 32 days, with a median of 14 days.³ The incubation period for *C. pneumoniae* is unclear but appears to be long, with estimates ranging from 10 to 30 days.⁸ *L. pneumophila* is not known to be transmitted from human to human and is thus most unlikely to be the causative agent. Our microbiologic tests also showed no evidence of infection by these agents. Research to identify potential viral infective agents in SARS is ongoing.

Given the information we present on case transmission, it is important to take appropriate isolation precautions with patients suspected to have SARS. Information on current recommendations can be found at <http://www.who.int/csr/sars/guidelines> and <http://www.cdc.gov/ncidod/sars/ic.htm>. Because the disease has appeared in many health care workers, they should have a high index of suspicion when fever and features suggestive of SARS develop in them or their family members. In such cases, we believe that health care workers should present themselves for evaluation, to avoid putting others at risk. When the microbiology of SARS is more fully understood, better methods of case identification should follow.

We are indebted to Ms. Christina Yan, June Sun, and Christine So for technical assistance and to all the medical and nursing staff members who assisted in the care of these patients.

REFERENCES

1. Acute respiratory syndrome in China — update 3: disease outbreak reported. Geneva: World Health Organization, 2003. (Accessed April 22, 2003, at http://www.who.int/csr/don/2003_2_20/en.)
2. Severe acute respiratory syndrome (SARS). Atlanta: Centers for Disease Control and Prevention, 2003. (Accessed March 31, 2003, at <http://www.cdc.gov/ncidod/sars/>.)
3. *Mycoplasma*. In: Hawker J, Begg N, Blair I, Reintjes R, Weinberg J. Communicable disease control handbook. London: Blackwell Science, 2001:152-3.
4. Case definitions for surveillance of severe acute respiratory syndrome (SARS). Geneva: World Health Organization, 2003. (Accessed April 22, 2003, at <http://www.who.int/csr/sars/casedefinition>.)
5. Muller NL, Staples CA, Miller RR. Bronchiolitis obliterans organizing pneumonia: CT features in 14 patients. *AJR Am J Roentgenol* 1990;154:983-7.
6. Lee KS, Kullnig P, Hartman TE, Muller NL. Cryptogenic organizing pneumonia: CT findings in 43 patients. *AJR Am J Roentgenol* 1994;162:543-6.
7. Primack SL, Hartman TE, Ikezoe J, Akira M, Sakatani M, Muller NL. Acute interstitial pneumonia: radiographic and CT findings in nine patients. *Radiology* 1993;188:817-20.
8. Jackson LA, Grayston JT. *Chlamydia pneumoniae*. In: Mandell GL, Bennett JE, Dolin R, eds. *Mandell, Douglas, and Bennett's principles and practices of infectious diseases*. 5th ed. Vol. 2. Philadelphia: Churchill Livingstone, 2000:2007-14.

Copyright © 2003 Massachusetts Medical Society.