



Title	Acupuncture mycobacteriosis [6]
Author(s)	Woo, PCY; Li, JHC; Tang, WM; Yuen, KY
Citation	New England Journal Of Medicine, 2001, v. 345 n. 11, p. 842-843
Issued Date	2001
URL	http://hdl.handle.net/10722/43132
Rights	New England Journal of Medicine. Copyright © Massachusetts Medical Society.

sition espoused in the coeditors' letter. The idea of applying social, political, and economic analysis to the understanding of medical illness is excellent, as is much of the material in the book. However, the use of expressions such as "social construction of illness" implies something more: that society creates illness as such, rather than modifies the meaning and impact of biologic events.

Regarding the relative roles of treatment and prevention, the coeditors state in the book, "Indeed, taken together, the chapters make clear the need for fundamental social change. Such change would include reframing how scientific research is conducted, making prevention rather than cure the goal of both research and clinical practice." I agree, as I state in my review, that prevention is always preferable, whenever possible. The benefits of primary prevention can be enormous, but detecting them always requires a theoretical inference — the identification of a decrease in the incidence of new cases in the population — rather than a more obvious and immediately rewarding scenario, the cure of an identified patient of a specific disease and its consequences. This necessary abstraction — the detection of the absence of a disease rather than the treatment of it — is one impediment to the implementation of prevention programs in medicine.

I welcome the coeditors' current emphasis on the relations among social and biomedical analysis, prevention, and treatment. Such broad mobilization of all available resources in collaboration rather than in competition is the surest path toward our common goal of eliminating the suffering caused by breast cancer.

DAVID SPIEGEL, M.D.

Stanford University School of Medicine
Stanford, CA 94305-5718
dspiegel@leland.stanford.edu

Acupuncture Mycobacteriosis

To the Editor: A 79-year-old woman presented with induration of the right leg three months after undergoing acupuncture for osteoarthritis of the knees. The induration was centered around the acupuncture point that lies along the gallbladder meridian (site GB 38, or *Yangfu*) (Fig. 1A). Radiographs of the right leg showed focal dystrophic calcification below this point. The underlying fibula was intact except for periosteal bone formation along the lower half (Fig. 1B and 1C). The findings were consistent with the presence of a chronic soft-tissue infection that extended along the muscle compartments over the fibula. There were no other signs of trauma or foci of infection, and the findings on chest radiography were normal. Histologic studies of the biopsy specimen showed suppurative granulomatous inflammation with microabscesses, caseous necrosis, and acid-fast bacilli. The isolate was identified as *Mycobacterium chelonae*. The infection responded to three weeks of treatment with imipenem, clarithromycin, and amikacin, followed by a six-month regimen of clarithromycin and minocycline.

This woman had acupuncture-induced mycobacteriosis. The acupuncture procedure required insertion of the needle 4 in. above the lateral malleolus, at the anterior margin of the fibula (the point at which the induration developed), which overlaid the focus of dystrophic calcification. The needle had to penetrate the skin, subcutaneous tissue, extensor

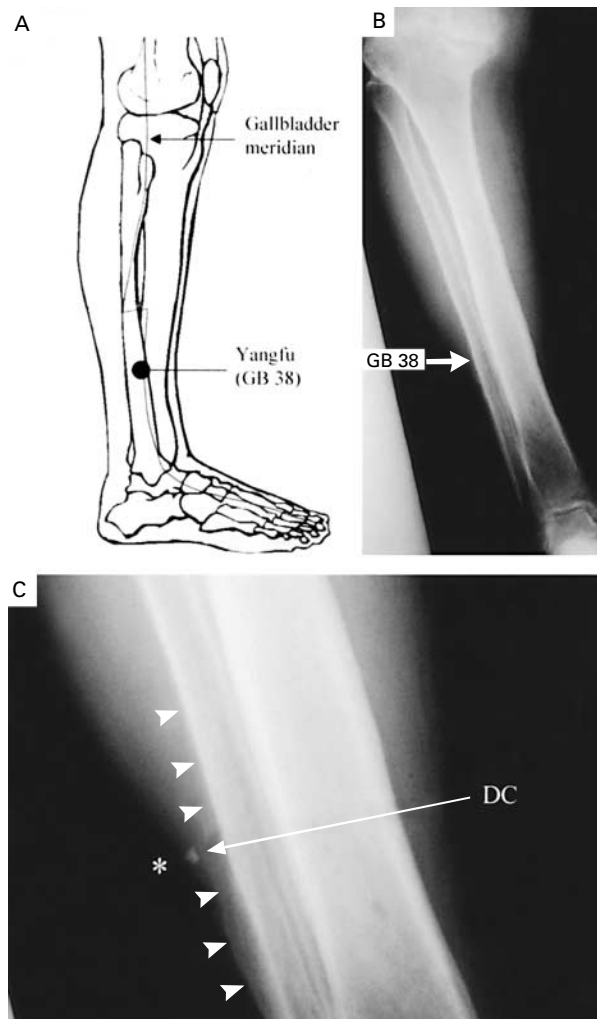


Figure 1. Site of Acupuncture along the Gallbladder Meridian (Panel A) and Anteroposterior Radiographs of the Patient's Right Leg (Panels B and C).

The acupuncture site is referred to as GB 38, or *Yangfu* (Panel A). The radiographs (Panels B and C) show osteoarthritis of the right knee joint, focal dystrophic calcification (DC) in soft tissues deep to GB 38 (denoted by the asterisk), and a periosteal reaction (arrowheads) in the underlying fibula.

digitorum longus and extensor hallucis longus muscles, and interosseous membrane, to a depth of 7.5 to 12.5 mm (0.3 to 0.5 in.).¹ This depth is similar to the depth of the chronic infectious process, as suggested by the finding of periosteal bone formation.

There was a long delay in establishing the diagnosis of acupuncture mycobacteriosis. The patient delayed seeking medical advice because the symptoms were relatively mild and indolent. Furthermore, she failed to associate the acupuncture procedure with the clinical illness because the infection had a relatively long incubation period.²⁻⁴ The attending clinicians also did not recognize the source of the mycobacteriosis. The diagnosis was made by the infectious-disease consultant, after the patient recalled having undergone acupuncture when she was asked whether a sharp

object had penetrated the involved site in the preceding months.

PATRICK C.Y. WOO, M.B., B.S.
JIMMY H.C. LI, M.B., B.S.
WAI-MAN TANG, M.B., B.S.
KWOK-YUNG YUEN, M.D.
University of Hong Kong
Hong Kong, China
hkumicro@hkucc.hku.hk

1. Chen E. Cross-sectional anatomy of acupoints. London: Churchill Livingstone, 1995.
2. Safranek TJ, Jarvis WR, Carson LA, et al. *Mycobacterium chelonae* wound infections after plastic surgery employing contaminated gentian violet skin-marking solution. N Engl J Med 1987;317:197-201.
3. Camargo D, Saad C, Ruiz F, et al. Iatrogenic outbreak of *M. chelonae* skin abscesses. Epidemiol Infect 1996;117:113-9.
4. Clegg HW, Foster MT, Sanders WE Jr, Baine WB. Infection due to organisms of the *Mycobacterium fortuitum* complex after augmentation mammoplasty: clinical and epidemiologic features. J Infect Dis 1983;147:427-33.

Correspondence Copyright © 2001 Massachusetts Medical Society.