



Title	Biliary tract infection due to bile-soluble bacteria: An intriguing paradox
Author(s)	Luk, WK; Liu, CL; Yuen, KY; Wong, SSY; Woo, PCY; Fan, ST
Citation	Clinical Infectious Diseases, 1998, v. 26 n. 4, p. 1010-1012
Issued Date	1998
URL	http://hdl.handle.net/10722/43121
Rights	Creative Commons: Attribution 3.0 Hong Kong License

had no history of allergy or asthma, and she was not taking any medication. She lived in Zamora, in northeastern Spain, an area where fascioliasis is endemic and she often ate uncooked wild watercress. Physical examination did not disclose any skin lesions or polyadenopathy, abdominal tenderness, or hepatosplenomegaly. A complete blood count revealed the following values: 8,400 WBCs/mm³ (2,830 neutrophils/mm³, 2,440 lymphocytes/mm³, 670 monocytes/mm³, and 2,860 eosinophils/mm³) and a hemoglobin level of 15.2 g/dL. Biochemical analysis revealed the following values: aspartate aminotransferase, 53 U/L; alanine aminotransferase, 76 U/L; lactate dehydrogenase, 390 U/L; alkaline phosphatase, 776 U/L; γ -glutamyl transpeptidase, 152 U/L; total bilirubin, 0.8 mg/dL; cholesterol, 235 mg/dL; and triglycerides, 93 mg/dL. The prothrombin time was normal. A determination of immunoglobulin levels showed hypergammaglobulinemia, with an IgG level of 1,420 mg/dL, an IgA level of 245 mg/dL, an IgM level of 209 mg/dL, and an IgE level of 969 U/mL.

The results of immunologic studies for antinuclear antibodies, rheumatoid factor, and antimitochondrial antibodies were normal. Serological studies were all negative. Four stool specimens were analyzed, but no eggs or adult forms of the parasite were found. Abdominal ultrasonography showed a normal-sized liver with multiple hyperechogenic lesions <1 cm in diameter and posterior acoustic shadowing. An abdominal CT scan showed multiple solid, hypodense lesions, most of which were located in the posterior segment of the right hepatic lobe; these lesions were better delineated after injection of contrast medium.

The diagnosis of hepatobiliary fascioliasis was suspected. Therefore, after informed consent was obtained, duodenal and biliary aspirates, collected by endoscopy after stimulation with rapid intravenous infusion of cholecystokinin (1 mL/kg), were analyzed. The results of microscopic examination of the duodenal fluid were normal, while examination of bile samples showed *Fasciola* eggs. We were informed that the indirect immunofluorescence test for *Fasciola* was positive at a 1:2,560 dilution 2 weeks after the procedure. Treatment with bithionol (800 mg q8h once every 2 days for 1 month) was prescribed. One month later the patient's cholestasis and eosinophilia had resolved, and the immunofluorescence assay titer was a quarter of the previous value.

Direct microscopic evaluation of stool specimens may fail to identify *Fasciola* eggs. During the acute stage of infection, the ova are not excreted in the feces. Furthermore, during the chronic stage, repeated analysis may be required for visualization of the

parasite eggs. Falcon assay screening test-ELISA and indirect hemagglutination studies have a high sensitivity (>90%) and good specificity in the acute stage of fasciola infection [1]. However, these studies are not widely available. Histological studies of the liver usually reveal the presence of granulomas with central necrosis surrounded by an inflammatory infiltrate with eosinophils, but *Fasciola* eggs are rarely encountered [2]. Endoscopic retrograde cholangiography allows the diagnosis to be made by visualization or collection of the parasite from the biliary duct after sphincterotomy has been performed, when large flukes are present in the chronic stage of infection [3]. However, this technique is time-consuming and is associated with the risk of cholangiopancreatic complications. Microscopic study of duodenal fluid has not proved reliable for the diagnosis of hepatobiliary fascioliasis.

Based on the findings of the present case, the microscopic examination of biliary aspirate obtained through upper endoscopy after intravenous infusion of cholecystokinin, with the identification of either eggs or adult parasites, could be a new method for the diagnosis of hepatobiliary fascioliasis. This technique has been used previously for the microscopic study of bile from patients with acute idiopathic pancreatitis [4]. As canalization of the papilla of Vater is not necessary, adverse events seldom occur, and this technique may be performed quickly. We believe that this method is promising for the diagnosis of fascioliasis as well as other hepatobiliary parasitoses.

**Jorge Gómez Cerezo, Juan José Ríos Blanco,
Carmen Ladrón de Guevara, F. Javier Barbedo Hernández,
and Juan José Vázquez Rodríguez**

*Departments of Internal Medicine and Microbiology, La Paz Hospital,
Universidad Autónoma de Madrid, Madrid, Spain*

References

1. Arjona R, Riancho JA, Aguado JM, Salesa R, González-Macías J. Fascioliasis in developed countries: a review of classic and aberrant forms of the disease. *Medicine (Baltimore)* 1995;74:13-21.
2. Noya M, Lema M, Castillo J, Rodríguez-Cameselle L, Ali Al-Shaban WM. Parasitación por *Fasciola hepática*. Claves diagnósticas. *Rev Clin Esp* 1982;166:177-9.
3. Hussein E, Imam W, Anastasios M. Biliary complications of *Fasciola hepática*: the role of endoscopic retrograde cholangiography in management. *J Clin Gastroenterol* 1995;21:309-11.
4. Lee S, Nicholls J, Park H. Biliary sludge as a cause of acute pancreatitis. *N Engl J Med* 1992;326:589-93.

Biliary Tract Infection Due to Bile-Soluble Bacteria: An Intriguing Paradox

Streptococcus pneumoniae and *Haemophilus parainfluenzae* exhibit autolysis in bile; thus, their isolation from bile is unexpected.

Reprints or correspondence: Dr. W. K. Luk, Department of Microbiology, Queen Mary Hospital, Pokfulam, Hong Kong.

Clinical Infectious Diseases 1998;26:1010-2
© 1998 by The University of Chicago. All rights reserved.
1058-4838/98/2604-0046\$03.00

Nevertheless, both organisms have been linked to biliary infections [1-3]. In addition, *Haemophilus parahaemolyticus* has been implicated in empyema of the gallbladder [4]. In this report, we present five cases of biliary tract infection due to bile-soluble bacteria and review the literature.

Patient 1. A 1-year-old female with congenital biliary atresia managed by portoenterostomy and subsequent living-related-donor liver transplantation developed repeated episodes of fever and chills and had impaired liver function 2 months after transplantation. Serial ultrasonograms showed progressive dilation of intrahepatic bile ducts, which required repeated percutaneous transhepatic cholangiography with balloon dilation, percutaneous transhepatic biliary drainage (PTBD), and iv antibiotics. Micro-

Table 1. Summary of features of patients with biliary tract infection due to bile-soluble bacteria.

Reference	Gender/age (y)	Condition	Procedure	Organism
[4]	M/40	Empyema of gallbladder	Elective cholecystectomy	<i>Haemophilus parahaemolyticus</i>
[3]	F/65	Chronic cholelithiasis	NA	<i>Haemophilus parainfluenzae</i> , <i>Streptococcus sanguis</i>
[2]	F/56	Acute on chronic cholecystitis, liver biopsy showed PBC	Cholecystectomy	<i>H. parainfluenzae</i>
[5]	F/87	Acute cholecystitis	Cholecystectomy	<i>H. parainfluenzae</i>
[5]	F/74	Acute cholecystitis	Cholecystectomy	<i>H. parainfluenzae</i>
[5]	F/58	Chronic cholecystitis	Cholecystectomy	<i>H. parainfluenzae</i> , <i>Streptococcus anginosus</i> , <i>Candida</i> species
[1]	M/53	Acute cholangitis after operation for hilar cholangiocarcinoma	None	<i>Streptococcus pneumoniae</i> , <i>Enterobacter cloacae</i>
[1]	M/48	Stricture at common hepatic duct, hilar cholangiocarcinoma	PTC, right hepatic lobectomy with excision of left hepatic duct and extrahepatic biliary system	<i>S. pneumoniae</i>
[PR]	F/1	Post-liver-transplantation biliary stricture and cholangitis	PTBD drainage	<i>H. parahaemolyticus</i> , <i>Enterococcus</i> species, coagulase-negative staphylococcus
[PR]	M/68	Cholangitis with underlying Klatskin's tumor	PTBD drainage	<i>S. pneumoniae</i> , <i>Pseudomonas aeruginosa</i> , <i>Escherichia coli</i> , <i>Bacteroides</i> species
[PR]	M/59	Empyema of gallbladder	Emergency laparoscopic cholecystectomy	<i>H. parainfluenzae</i>
[PR]	M/62	Empyema of gallbladder	Emergency cholecystectomy	<i>H. parainfluenzae</i> , <i>Streptococcus mitis</i>
[PR]	F/58	Acute cholecystitis	Elective cholecystectomy	<i>H. parainfluenzae</i>

NOTE: NA = not available; PBC = primary biliary cirrhosis; PR = present report; PTBD = percutaneous transhepatic biliary drainage; PTC = percutaneous transhepatic cholangiography.

scopic evaluation of a bile specimen revealed gram-negative bacilli, gram-positive cocci in clusters, and WBCs. Her condition responded favorably to iv cefuroxime treatment.

Patient 2. A 68-year-old man with diabetes mellitus who had a history of cholangiocarcinoma of the common bile duct, which was diagnosed 7 years previously and managed by stenting, presented with fever and abdominal pain. Microscopic evaluation of a bile specimen obtained from the PTBD tube revealed gram-positive cocci in chains, gram-negative bacilli, and WBCs. The patient's condition responded favorably to treatment with iv piperacillin/tazobactam.

Patient 3. A 59-year-old man presented with fever and right-upper-quadrant abdominal pain of 6 days' duration. Empyema of the gallbladder was diagnosed by use of emergency laparoscopy. Microscopic evaluation of a bile specimen showed gram-negative bacilli and WBCs.

Other features of cases 1–3 are summarized in table 1, together with cases 4 and 5. The implicated isolates included *H. parahaemolyticus*, *H. parainfluenzae*, and *S. pneumoniae*.

None of the bile specimens were bile stained, and the specimens were found to be negative for bilirubin by use of the Ames Multistix 10 SG test (Bayer Diagnostics, Sydney, New South Wales, Australia). Bile solubility testing on a strain of *S. pneumoniae*, performed by using samples of the patients' bile and 10% sodium deoxycholate as a control, yielded negative results. Conversely, bile solubility tests on the patients' isolates, performed by using 10% sodium deoxycholate, were positive.

A MEDLINE search (1966–1997) was conducted using the terms *bile*, *biliary*, *cholangitis*, *Haemophilus*, and *Streptococcus pneumoniae*. Altogether, eight cases of biliary-tract infection due to bile-soluble bacteria were found; these are presented in table 1.

Normal human bile contains 12% bile salts [6] and is theoretically inhibitory to microorganisms, since a 10% solution is already sufficient in routine laboratory testing for bile solubility. In all of our patients, the bile salt concentration was well below 10%, as demonstrated by the negative bile solubility test results obtained with a standard strain of *S. pneumoniae*. These findings imply that low concentrations or absence of bile salts allows microorganisms to proliferate in the biliary system. All patients had either acute or chronic cholecystitis with obstruction at the cystic or common bile duct. Cholestasis has been shown to reduce secretion of bile acids, producing white bile [7]; in addition, there may be passive absorption of bile salts from the gallbladder [8].

The usual source of pathogens in cholecystitis or cholangitis is the lower gastrointestinal tract. However, the three organisms studied in this report are known upper respiratory tract commensals, although *Haemophilus* species have been found to be members of the fecal flora as well [9]. Among the eight cases for which gram-stain results were available, microscopic and culture findings were concordant in six cases, indicating that these upper respiratory tract inhabitants were of etiologic significance.

The bile specimens were obtained either during operation or percutaneously. Contamination by upper respiratory or lower gastrointestinal flora was thus unlikely. In the absence of a concurrent

positive blood culture, an ascending route of infection from the intestinal tract was the most probable mechanism, as previously suggested [2].

**W. K. Luk, C. L. Liu, K. Y. Yuen, S. S. Y. Wong,
P. C. Y. Woo, and S. T. Fan**

*Division of Infectious Diseases, Department of Microbiology, and
Department of Surgery, Queen Mary Hospital, The University of Hong
Kong, Pokfulam, Hong Kong*

References

1. Blenkham JI, Blumgart LH. The isolation of *Streptococcus pneumoniae* from bile. *J Infect* 1986;12:175-8.
2. Bottone EJ, Zhang DY. *Haemophilus parainfluenzae* biliary tract infection: rationale for an ascending route of infection from the gastrointestinal tract. *J Clin Microbiol* 1995;33:3042-3.
3. Cattier B, Caillon J, Quentin R. A case of biliary tract infection caused by *Haemophilus parainfluenzae*. *Eur J Clin Microbiol Infect Dis* 1992;11:197-9.
4. Parsons M, Faris I. Empyema of the gallbladder due to *Haemophilus parahaemolyticus*, with a brief review of its role as a pathogen. *J Clin Pathol* 1973;26:604-5.
5. Pierard D, De Waele B, Covens L, Van Zeebroeck A, Rosseel P, Lauwers S. *Haemophilus parainfluenzae* biliary tract infections. *J Clin Microbiol* 1996;34:1866-7.
6. Greenberger NJ, Isselbacher KJ. Diseases of the gallbladder and bile ducts. In: Isselbacher KJ, Braunwald E, Wilson JD, Martin JB, Fauci AS, Kasper DL, eds. *Harrison's principles of internal medicine*. 13th ed. New York: McGraw-Hill, 1994:1504-16.
7. Sherlock S, Dooley J. Diseases of the liver and biliary system. 10th ed. Oxford: Blackwell Science, 1997:220.
8. Ostrow JD. Absorption by the gallbladder of bile salts, sulfobromophthalein and iodipamide. *J Lab Clin Med* 1969;17:572-7.
9. Megraud F, Bebear C, Dabernat H, Delmas C. *Haemophilus* species in the human gastrointestinal tract. *Eur J Clin Microbiol Infect Dis* 1988;7:437-8.

Acute Respiratory Failure Associated with the Human Immunodeficiency Virus (HIV) Protease Inhibitor Indinavir in an HIV-Infected Patient

The HIV protease inhibitor indinavir has been marketed recently in several countries after a relatively short period of clinical research; during this period the drug was shown to be safe and effective in the treatment of HIV infection [1-3]. Indinavir is now widely used in HIV-infected patients. The most common adverse effects include elevated serum levels of indirect bilirubin as well as nausea, headache, abdominal pain, and nephrolithiasis [4]. We report a case of acute respiratory distress syndrome probably caused by indinavir.

A 36-year-old transsexual man was admitted to the intensive care unit (ICU) because of shock and acute respiratory failure. He was known to have AIDS, which was classified as Centers for Disease Control and Prevention clinical category C3 on the basis of cervical lymph node tuberculosis, recurrent candida stomatitis, and a low CD4 cell count (15/mm³). He had no history of pulmonary diseases or drug allergies. Nine months before admission, he had started receiving antiretroviral therapy (zidovudine, 200 mg three times daily and zalcitabine, 0.75 mg three times daily) and primary prophylaxis for *Pneumocystis carinii* pneumonia (PCP) (co-trimoxazole, 480 mg daily). The only other medication he was receiving was cyproterone acetate (im, 300 mg biweekly). The antiretroviral treatment was considered ineffective and was switched one day before admission to triple therapy with indinavir (800 mg three times daily), stavudine (30 mg twice daily), and lamivudine (150 mg twice daily).

Two hours after receiving the first 800-mg dose of indinavir, the patient developed high fever, generalized myalgia, and malaise and began vomiting. The next day, after the second dose, he developed shock and cyanosis and was admitted to the ICU. Physical examination revealed a temperature of 40.4°C, a blood pressure of 70/0 mm Hg, a pulse of 158/min, and respiratory failure. Supportive treatment with mechanical ventilation and inotropic agents was instituted.

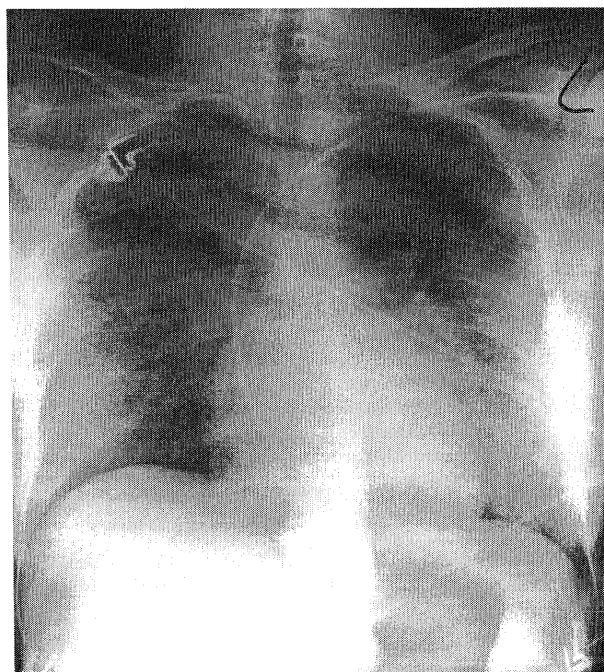


Figure 1. Chest radiograph showing diffuse bilateral alveolar infiltrates in a patient with acute respiratory failure associated with indinavir therapy (the radiograph was obtained while the patient was supine).

Reprints or correspondence: J.P. Dieleman, Pharmaco-Epidemiology, Internal Medicine II, University Hospital Dijkzigt, Dr. Molewaterplein 40, 3015 GD Rotterdam, the Netherlands.

Clinical Infectious Diseases 1998;26:1012-3
© 1998 by The University of Chicago. All rights reserved.
1058-4838/98/2604-0047\$03.00