



Title	Immunorestitution disease involving the innate and adaptive response
Author(s)	Cheng, VCC; Yuen, KY; Chan, WM; Wong, SSY; Ma, ESK; Chan, RMT
Citation	Clinical Infectious Diseases, 2000, v. 30 n. 6, p. 882-892
Issued Date	2000
URL	http://hdl.handle.net/10722/43094
Rights	Creative Commons: Attribution 3.0 Hong Kong License

Immuno-restitution Disease Involving the Innate and Adaptive Response

Vincent C. C. Cheng,¹ Kwok-yung Yuen,¹
Wai-ming Chan,³ Samson S. Y. Wong,¹
Edmond S. K. Ma,² and Robert M. T. Chan¹

From the Departments of ¹Microbiology and ²Pathology
and ³Intensive Care Unit, Queen Mary Hospital, Hong Kong

Immuno-restitution disease (IRD) is defined as an acute symptomatic or paradoxical deterioration of a (presumably) preexisting infection that is temporally related to the recovery of the immune system. We report the temporal sequence of events that led to IRD caused by *Pneumocystis carinii* and *Aspergillus terreus* in 2 human immunodeficiency virus (HIV)-negative patients soon after the recovery of adaptive and innate immunity, respectively, and we review episodes noted in the English-language literature that fit the definition of IRD (109 episodes in 107 patients). The median time from the recovery of neutrophil counts or termination of steroid therapy to the development of IRD was 8 days in cases of pulmonary aspergillosis (23 episodes) and hepatosplenic candidiasis (8) and 21 days for viral diseases such as hepatitis B (24) and viral pneumonitis (6). For IRD due to mycobacteriosis (27 episodes) and cryptococcosis (4) in HIV-positive patients, the median interval between the initiation of highly active antiretroviral therapy (HAART) and the onset of IRD was 11 days; for viral infections, including those due to cytomegalovirus (14), hepatitis B virus (1), and hepatitis C virus (2), the median interval was 42 days. As an emerging clinical entity, IRD merits further study to optimize treatment of immunosuppressed patients.

The survival of patients with cancer, AIDS, and congenital immunodeficiency has been improved by the development of better anticancer and antimicrobial therapy and by the development of effective bone marrow transplantation. Regardless of the temporary benefit conferred by suppressing opportunistic infections that are aggravated by the underlying illness or the associated chemoradiotherapy, the ultimate outcome for these patients depends on recovery of the immune system [1]. However, the clearance of preexisting asymptomatic or mildly symptomatic opportunistic infections associated with immune recovery is not necessarily a smooth and painless process.

The local or systemic inflammatory response syndrome triggered during the recovery of the innate and adaptive immune system can result in paradoxical clinical deterioration. The degree of tissue damage would depend on the tissue burden of the preexisting microbes and the restriction or exactness of the immune system being restored. Examples reported recently include the onset of fundoscopic deterioration with cytomegalovirus (CMV) retinitis and the clinical and radiological worsening of pulmonary tuberculosis in patients with AIDS who received antiretroviral therapy [2–7].

We are not aware of any report that documents the chronological changes in CD4⁺ lymphocyte or neutrophil counts, changes in tissue microbial load, and clinical deterioration in HIV-negative individuals during immuno-restitution. We report the clinical, microbiological, and hematologic profiles of 2 patients with paradoxical worsening of their infections during immune recovery and review the relevant English-language literature.

Patients and Methods

The clinical records of the case patients were analyzed and summarized. *Pneumocystis carinii* pneumonitis was diagnosed by methenamine silver staining of 100 μ L of bronchoalveolar lavage (BAL) fluid subjected to cytospinning (Cytospin 2; Shandon, Pittsburgh, PA). The entire smear was examined under 400 \times magnification, and the number of stained cysts was quantified [8]. CMV infection was diagnosed by semiquantitative PCR assay of plasma, monoclonal antibody staining for the CMV pp65 antigen in peripheral blood leukocytes, and shell vial culture of a standardized volume of BAL fluid. The longitudinal collection of plasma or buffy-coat specimens from the case patient were retrieved from storage at -70°C for microbiological and immunological study. Laboratory procedures were followed as reported elsewhere [9, 10]. For semiquantitative nested PCR of CMV, 100 μ L of each serum specimen was extracted by the QIAamp DNA Mini Kit (Qiagen; Chatsworth, CA).

The DNA extract was eluted in 100 μ L of eluant provided by the manufacturer. A serial dilution was performed (1, 1/2, 1/4, 1/10, 1/20, 1/40, and 1/100), and 10 μ L of each dilution was used for PCR. The extracts were amplified by external primers with denaturation at 94°C for 1 min, annealing at 55°C for 1 min, and extension at 72°C for 1.5 min in an automated thermal cycler (Per-

Received 16 June 1999; revised 3 December 1999; electronically published 20 June 2000.

Financial support: Committee for Research and Conference Grants and the Research Grants Council.

Reprints or correspondence: K. Y. Yuen, Division of Infectious Diseases, Dept. of Microbiology, University of Hong Kong, University Pathology Building, Queen Mary Hospital, Pokfulam Road, Hong Kong (kyuen@hkucc.hku.hk).

Clinical Infectious Diseases 2000;30:882–92

© 2000 by the Infectious Diseases Society of America. All rights reserved.
1058-4838/2000/3006-0006\$03.00

kin-Elmer Cetus, Gouda, the Netherlands). The process was repeated for 20 cycles. Ten microliters of the first-round PCR amplicon was amplified by another set of internal primers, which underwent a similar temperature cycle for 30 cycles. The final PCR product of 168 bp was detected by gel electrophoresis.

A CMV pp65 antigenemia assay was performed according to the methods of The et al. [11]. As for the shell vial culture of CMV and detection of early antigen fluorescent foci, 200 μ L of BAL fluid was inoculated into human embryonic fibroblast cells in shell vials incubated at 37°C with 5% CO₂ for 48 h. The cells were stained with fluorescein-conjugated mouse monoclonal antibody to CMV (Chemicon International, Temecula, CA) to detect CMV immediate-early antigens and early antigens.

The CD4⁺ lymphocyte count was determined on a peripheral blood film using the labeled avidin biotin method (LSAB plus alkaline phosphatase kit; Dako, Carpinteria, CA); the CD4 : CD8 ratio was also determined on a peripheral blood film but using monoclonal antibodies to CD4 and CD8 (Dako). In brief, after fixation of the blood film with formalin/acetone/methanol, the primary and secondary antibodies were stained with Meyer's hematoxylin. We calculated the positive cells as a percentage of all lymphocytes present, and the CD4⁺ and CD8⁺ lymphocyte counts, taking into account the absolute lymphocyte count.

Definition of immunorestitution disease (IRD). For the purpose of this study, IRD is defined as an acute symptomatic or paradoxical deterioration of a (presumably) preexisting infection that is temporally related to recovery of the immune system and is due to immunopathological damage associated with the reversal of immunosuppressive processes, such as withdrawal of corticosteroids, recovery of the neutrophil count from chemotherapy, engraftment after bone marrow transplantation, or highly active antiretroviral therapy (HAART) for AIDS. The preexisting microbial infection could be either asymptomatic or mildly symptomatic.

Time to development of IRD in HIV-negative patients. For patients with preexisting viral infections due to hepatitis B virus (HBV), parainfluenza virus, and respiratory syncytial virus, the time to development of IRD is defined as the interval between the withdrawal of immunosuppressive agents or the day of bone marrow engraftment and the onset of clinical symptoms or signs of IRD. For patients with fungal infections due to *Aspergillus* or *Candida* species, it is defined as the interval between the recovery of the absolute neutrophil count (ANC) to 500 cells/ μ L and the onset of IRD.

Definition of engraftment in bone marrow transplant recipients. Engraftment is defined as a peripheral absolute neutrophil count of 500/L.

Time to development of IRD in HIV-positive patients. For patients with preexisting viral infections due to CMV, HBV, or hepatitis C virus (HCV) or mycobacterial infections due to *Mycobacterium tuberculosis*, *Mycobacterium avium* complex, *Mycobacterium xenopi*, or *Cryptococcus* species, the time to development of IRD is defined as the interval between the initiation of HAART and the onset of signs or symptoms of IRD.

Literature review. We searched the English-language literature using the MEDLINE databases of the National Library of Medicine. To search for the cases in HIV-negative patients listed in tables 1 and 2, we used the keywords "immunosuppressive withdrawal," "chemotherapy withdrawal," "bone marrow transplan-

tation," "hepatitis B," "liver failure," "neutrophil recovery," "candidiasis," and "aspergillosis." To search for the cases in the HIV-positive patients listed in tables 3 and 4, we used the keywords "HIV," "highly active antiretroviral therapy," "immune reconstitution," "immune restitution," "immune recovery," "paradoxical," "opportunistic infection," "CMV," and "tuberculosis." We included all case reports and clinical studies in this study that fit our definition of IRD. When appropriate, the cited bibliographies were also retrieved for further analysis.

Case Reports

Case one. A 31-year-old woman was admitted to our institution (Queen Mary Hospital, Hong Kong) for investigation of Cushing's syndrome. She had a morning cortisol level of 3300 nmol/L (normal range, 150–720 nmol/L). Endocrine function tests confirmed the diagnosis of pituitary-dependent Cushing's disease. Therapy was started with metyrapone (11- β hydroxylase inhibitor) on day 0 to block the adrenal corticosteroid synthesis, and transphenoidal resection of the functional pituitary tumor was planned (figure 1).

On admission her WBC count was normal, but the differential count revealed lymphopenia (300 cells/ μ L) and a CD4⁺ lymphocyte count of 120 cells/ μ L. Liver function tests showed the following values: alkaline phosphatase, 175 IU/L; alanine aminotransferase (ALT), 67 IU/L; and aspartate aminotransferase, 38 IU/L. The liver enzyme levels continued subsequently to increase (shown by ALT values in figure 1). CT of the hepatobiliary system yielded normal findings. Serology for hepatitis A, B, and C infections was negative.

Four days after treatment with metyrapone, the patient developed persistent low-grade fever, with temperatures ranging from 37.3°C to 37.8°C. Her ALT level increased to a maximum of 416 IU/L on day 3 of metyrapone treatment but subsequently decreased and spontaneously returned to normal without specific treatment on day 12. On the same day, she developed a fever (temperature, 39.5°C), which was associated with increasing respiratory distress and arterial hypoxemia. Chest radiography on that day showed bilateral hilar infiltration with diffuse alveolar shadows in the lower zones, which were not visible on the chest radiograph obtained 2 days earlier. The CD4⁺ lymphocyte count was 1092 cells/ μ L on the day her condition began to deteriorate.

She was transferred to the intensive care unit for ventilatory support with 100% oxygen. Emergency bronchoscopy did not reveal any endobronchial lesions. BAL specimens were sent for microbiological and cytological examination. Fifty milliliters of saline was injected in the right middle and lingular bronchi, and 35 mL of BAL fluid was recovered. *P. carinii* was detected: ~250 cysts/mL of BAL. Cytological examination revealed abundant lymphocytes, neutrophils, and bronchial epithelial cells. CMV was detected by shell vial culture, with 13 fluorescent foci per 200 μ L of BAL fluid. CMV pp65 antigen testing was positive at 3 cells/10⁵ neutrophils.

Table 1. Summary of published cases of immunorestitution disease due to viruses in HIV-negative patients, after withdrawal of immunosuppressive therapy (IS) or bone marrow transplantation.

Case, [ref]	Sex, age in y of patient	Virus	Underlying condition	IS agent(s) or BMT	Time to onset of IRD	IRD manifestation(s)	Remarks
1 [12]	M, 40	HBV	CML	Prd, CYT	2 w	Anorexia; nausea; jaundice; HE; Bil, 240 μ mol/L; AST, 700 IU/L	Died despite steroid treatment; liver biopsy: massive hepatic necrosis
2 [12]	F, 28	HBV	Choriocarcinoma	CYT	4 w	Anorexia; jaundice; HE; Bil, 410 μ mol/L; AST, 600 IU/L	Died; liver biopsy: massive hepatic necrosis
3 [12]	M, 32	HBV	CLL	Prd, CYT	6 w	Malaise; anorexia; jaundice; Bil, 550 μ mol/L; AST, 1270 IU/L	Died; liver biopsy: massive hepatic necrosis
4 [13]	F, 35	HBV	Renal transplant	Aza (100 mg/d), Prd (10 mg/d)	2 w	Jaundice; abnormal liver function test findings	Withdrawal of IS due to peritonitis; died; 1st liver biopsy: centrilobular necrosis; 2d liver biopsy: massive hepatic necrosis
5 [14]	M, 49	HBV	Malignant lymphoma	Prd, CYT	3 w	Progressive anorexia; fever; arthralgia; myalgia; increasing ascites; Bil, 11.9 mg/dL; ALT, 4495 IU/L	Died despite steroid treatment; liver biopsy: massive hepatic necrosis
6 [15]	M, 15	HBV	Nephrotic syndrome	Prd (50 mg/d), tapered over 2 w	16 d	Malaise; anorexia; nausea; jaundice; tender hepatomegaly; Bil, 85 μ mol/L; ALT, 1350 IU/L	Died; liver biopsy: massive hepatic necrosis
7 [15]	M, 60	HBV	Nephrotic syndrome	CTX (150 mg/d)	2 w	Lassitude; anorexia; ascites; jaundice; Bil, 92 μ mol/L; ALT, 1800 IU/L	Died; liver biopsy: massive hepatic necrosis
8 [16]	M, 43	HBV	Behcet's disease	CTX (160 mg/d), MP (250 mg/mo)	2 w	Grade I HE; jaundice; Bil, 46 μ mol/L; ALT, 520 IU/L	Died despite steroid treatment; liver biopsy: cirrhotic liver with advanced necrosis
9 [16]	M, 39	HBV	Follicular lymphoma	Prd, CYT	3 w	Jaundice; HS; Bil, 315 μ mol/L; ALT, 2180 IU/L	Died despite steroid treatment; liver biopsy: extensive area of confluent necrosis
10 [16]	M, 40	HBV	Renal transplant	Prd (25 mg/d), CysA (200 mg/d), Aza (100 mg/d)	2 w	Confusion; Bil, 67 μ mol/L; AST, 2103 IU/L	Withdrawal of IS due to uncontrolled hypertension; died despite steroid treatment; no liver biopsy
11 [16]	F, 55	HBV	Hodgkin's disease	Prd, CYT	2 w	Jaundice; upper abdominal pain; ascites; Bil, 258 μ mol/L; AST, 1782 IU/L	Died despite steroid treatment; liver biopsy: cirrhosis, mixed inflammatory infiltrate in portal tract
12 [16]	F, 52	HBV	Ca cervix	CYT	6 w	Jaundice; HE; Bil, 135 μ mol/L; ALT, 3585 IU/L	Died; liver biopsy: massive hepatic necrosis
13 [17]	F, 59	HBV	Hodgkin's disease	Prd, CYT	3 w	Symptoms of hepatitis; ALT peak, 2600 IU/L	Died; liver biopsy: massive hepatic necrosis
14 [17]	F, 32	HBV	Hodgkin's disease	Prd, CYT	4 w	NM	Died; liver biopsy: massive hepatic necrosis
15 [17]	M, 36	HBV	Hodgkin's disease	Prd, CYT	4 w	NM	Died; liver biopsy: massive hepatic necrosis
16 [17]	M, 52	HBV	Hodgkin's disease	Prd, CYT	3 w	NM	Died of liver failure
17 [18]	F, 57	HBV	Rheumatoid arthritis	Mtx (7.5–10 mg/w orally)	41 d	Fulminant hepatic failure	Survived; liver transplantation on d 53
18 [19]	M, 63	HBV	Malignant lymphoma	Prd, CYT	28 d	Jaundice; abdominal pain; ascites; Bil, 25.5 mg/dL; ALT, 540 IU/L	Died despite steroid treatment; liver biopsy: bridging necrosis and portal fibrosis
19 [19]	F, 60	HBV	CLL	Prd, CYT	38 d	Fever; jaundice; HS; ascites; Bil, 18.8 mg/dL; ALT, 760 IU/L	Died of hepatic failure; no postmortem
20 [19]	M, 34	HBV	Malignant lymphoma	Prd, CYT	10 d	Anorexia; fatigue; jaundice; abdominal pain; Bil, 4.9 mg/dL; ALT, 1100 IU/L	Died despite steroid treatment; liver biopsy: submassive hepatic necrosis and mild portal fibrosis
21 [19]	M, 56	HBV	Malignant lymphoma	Prd, CYT	2 w	Nausea; Bil, 9.9 mg/dL; ALT, 1710 IU/L	Survived with steroid treatment; liver biopsy: severe degree of multifocal necrosis
22 [19]	F, 28	HBV	Malignant lymphoma	Prd, CYT	17 d	Fatigue; nausea; jaundice; Bil, 9.1 mg/dL; ALT, 397 IU/L	Died of hepatic failure; no postmortem
23 [20]	NM	PIF1	SCID	BMT	NM	Postengraftment pneumonitis	Died of pneumonitis
24 [20]	NM	PIF2	SCID	BMT	NM	Postengraftment pneumonitis	Survived after treatment with inhaled budesonide
25 [20]	NM	PIF3	SCID	BMT	NM	Postengraftment pneumonitis	Died of pneumonitis
26 [20]	NM	PIF3	SCID	BMT	NM	Postengraftment pneumonitis	Died of pneumonitis
27 [20]	NM	PIF4	SCID	BMT	NM	Postengraftment pneumonitis	Died of pneumonitis despite inhaled budesonide
28 [20]	NM	RSV	SCID	BMT	NM	Postengraftment pneumonitis	Died of pneumonitis
29 [21]	M, 27	HBV	CML	BMT	59 d	Ascites; HE; increasing ALT	Engrafted on d 17; liver biopsy on d 44 showed active lobular hepatitis with necrosis; died d 130; no postmortem
30 [22]	F, 19	HBV	CML	BMT	74 d	Jaundice; hepatomegaly; worsening of liver function test findings	Engrafted on d 18; died despite steroid treatment; liver biopsy: submassive necrosis and large area of balloon degeneration

NOTE. ALT, alanine aminotransferase level; AST, aspartate aminotransferase level; Aza, azathioprine; Bil, bilirubin level; BMT, allogeneic bone marrow transplantation; Ca, carcinoma; CLL, chronic lymphocytic leukemia; CML, chronic myeloid leukemia; CTX, cyclophosphamide; CysA, cyclosporin A; CYT, cytotoxic agents; HBV, hepatitis B virus; HE, hepatic encephalopathy; HS, hepatosplenomegaly; IRD, immunorestitution disease; MP, methylprednisolone; Mtx, methotrexate; NM, not mentioned; ref, reference; PIF1, parainfluenza virus serotype 1; PIF2, parainfluenza virus serotype 2; PIF3, parainfluenza virus serotype 3; PIF4, parainfluenza virus serotype 4; Prd, prednisone; ref, reference; RSV, respiratory syncytial virus; SCID, severe combined immunodeficiency disease.

Table 2. Summary of published cases of immunorestitution disease in HIV-negative patients with aspergillosis and hepatosplenic candidiasis after recovery of the absolute neutrophil count (ANC).

Case(s) [ref]	Sex (n), age in y of patient(s)	Preexisting infection	Disease	ANC, cells/ μ L		Time to onset of IRD, d	IRD manifestation(s)	Remarks
				Before IRD	During IRD			
31–38 [23]	NM	Asp	Hemic mal ^a	<500	>500	NM	Pulmonary cavitation, followed by hemoptysis	1 patient died of massive hemoptysis
39–45 [24]	M (4) F (3), median, 42 [rng, 36–69]	Asp	AML, 5; ALL, 2	<500	Mean, 7200	Mean, 7	Cough, pain, bronchospasm worsening of CXR lesion; massive hemoptysis	6 patients died; diagnosis confirmed by autopsy; 1 case diagnosed by serology and sputum smear
46–53 [25]	NM	Asp	Hemic mal ^b	<500	Mean, 6577	Mean, 5–11	Massive hemoptysis in 4 patients; 3 had pneumothorax, 1 had both	5 patients died of pulmonary complications
54 [26]	M, 20	HSC	RMS	<50	25,000	10	Recurrent fever, RUQ abdominal pain	Died; autopsy showed numerous granulomas in liver, spleen, kidney
55 [26]	M, 12	HSC	ALL	<500	15,400	5	Recurrent fever, severe nausea, vomiting; CT showed lesion in liver, spleen, kidney, pulmonary nodules	Liver biopsy finding consistent with candidal infection; autopsy showed single granulomatous area with necrosis and residual hyphae in spleen
56 [26]	F, 22	HSC	ALL	<500	>500	2	Abdominal pain	Laparotomy and histology showed multiple hepatic abscesses with budding yeast and pseudohyphae; culture confirmed <i>C. albicans</i> ; survived after receipt of AmB (total, 7.5 g); repeated liver biopsy showed no residual disease
57–61 [27]	M (1) F (4), median, 41 [rng, 18–47]	HSC	ALL, 2; AML, 3	<500	>500	Median, 20 [rng, 7–46]	Reappearance or increase in hepatosplenic lesions on CT	CT used to follow evolution of lesions during and after neutropenia

NOTE. ALL, acute lymphoblastic leukemia; AmB, amphotericin B; AML, acute myeloid leukemia; Asp, aspergillosis; CXR, chest radiographic; Hemic mal, hemic malignancy; HSC, hepatosplenic candidiasis; IRD, immunorestitution disease; ref, reference; RMS, rhabdomyosarcoma of left maxillary sinus; rng, range; RUQ, right upper quadrant;

^a Acute leukemia.

^b Including acute leukemia or high-grade lymphoma.

After metyrapone treatment, the morning cortisol level progressively decreased from 2270 nmol/L (day 0) to 575 nmol/L (day 12) (figure 1). The drop in cortisol level was associated with normalization of the absolute lymphocyte count, from 300 cells/ μ L to 2600 cells/ μ L, whereas the CD4⁺ lymphocyte count increased to 1092 cells/ μ L. Concurrent semiquantitative PCR of stored plasma taken on day 0 and day 12 showed a 10-fold decrease in CMV DNA titer after treatment with metyrapone.

The tentative diagnosis was that during recovery of the CD4⁺ lymphocyte count, asymptomatic clearance of CMV hepatitis had occurred but pneumonitis developed as a result of a severe inflammatory response to *P. carinii* and possibly CMV. The patient was treated for *P. carinii* pneumonitis with high-dose trimethoprim (20 mg/kg/d) and sulfamethoxazole (100 mg/kg/d) in 4 divided doses for 21 days. Tapering doses of adjunct corticosteroid were given as recommended [34]. For treatment and prevention of possible concomitant CMV pneumonitis and systemic CMV disease, ganciclovir (250 mg iv every 12 h) was given along with tapering doses of methylprednisolone. The patient recovered completely and was discharged on day 30. Her serum was negative for HIV antibody.

Case two. A 51-year-old woman at our hospital who had acute myeloid leukemia was noted to have fever and an asymp-

tomatic radiographic pulmonary consolidation over the left-mid-zone before induction chemotherapy. Blood and sputum culture for bacteria, fungi, and acid-fast bacilli were negative, and induction chemotherapy with cytosine arabinoside (100 mg/m²) and daunorubicin (50 mg/m²) was started under coverage with iv ceftazidime (2 g every 8 h). Because of the persistence of fever, neutropenia (ANC, 30/ μ L), and radiographic pulmonary changes, bronchoscopy and BAL were performed on day 7 of chemotherapy. Culture of the BAL fluid yielded *Aspergillus terreus*, but the concentrated smear was negative [35].

The patient was given ceftazidime and amphotericin B (1 mg/kg/d) for prolonged neutropenic fever and pulmonary aspergillosis. The WBC count started to recover on day 36, at which time ANC was 530 cells/ μ L. Ten days later the ANC had increased to 1500 cells/ μ L, but there was a progressive increase in blood-streaked sputum, pleuritic chest pain, and fever. Repeated chest radiography showed an enlarging left-mid-zone shadow with evidence of cavitation and abscess formation. Bronchoscopy was performed on day 54 and revealed mucosal swelling at the apical segment of the left lower lobe. Examination of a direct smear of the BAL fluid showed the presence of fungal elements and numerous neutrophils. The concomitant

Table 3. Summary of published cases of immunorestitution disease (IRD) in HIV-positive patients due to viruses after highly active antiretroviral therapy (HAART).

Case [ref]	Sex, age in y of patient	Virus	CD4 cells/ μ L		HIV RNA, copies/mL		Time to onset of IRD	IRD manifestation (treatment)
			Before HAART	After HAART, during IRD	Before HAART	After HAART		
62 [2]	M, 34	CMV	82	266	NM	NM	7 w	Retinitis
63 [2]	M, 43	CMV	70	213	NM	NM	5 w	Retinitis, vitritis
64 [2]	M, 35	CMV	14	205	NM	NM	4 w	Retinitis, vitritis
65 [2]	M, 47	CMV	18	197	NM	NM	5 w	Retinitis
66 [2]	M, 45	CMV	40	270	NM	NM	6 w	Retinitis
67 [3]	M, 33	CMV	4	70	80,000	6000	NM	Retinitis
68 [3]	M, 39	CMV	33	144	374,000	83,584	NM	Retinitis
69 [3]	M, 30	CMV	5	190	341,000	<400	NM	Retinitis
70 [3]	M, 54	CMV	88	200	600,000	42,210	6 w	Retinitis
71 [4]	M, 43	CMV	17	300	NM	UD	5 mo	Decreased visual acuity and floaters; vitritis and papillitis
72 [4]	M, 32	CMV	47	234	NM	UD	2 mo	Decreased visual acuity and floaters; vitritis and papillitis; cystoid macular edema
73 [4]	M, 44	CMV	22	63	NM	UD	2 mo	Decreased visual acuity and floaters; vitritis and papillitis; macular edema (oral steroid)
74 [4]	NM	CMV	18	104	NM	UD	2 mo	Decreased visual acuity and floaters; vitritis and papillitis; cystoid macular edema (repository steroid injection)
75 [4]	NM	CMV	28	79	NM	UD	3 mo	Decreased visual acuity and floaters; vitritis and papillitis
76 [28]	M, 34	HBV	130	NM	NM	100-fold reduced	6 w	Vomiting, tender hepatomegaly with increased ALT; liver biopsy at week 10 showed acute lobular hepatitis; by week 24, 10,000-fold reduction of HBV DNA and clearance of HBeAg
77 [29]	M, 36	HCV	32	138	545,000	<260	4 w	Anorexia, jaundice, tender hepatomegaly; serum ALT, 301 IU/L (peaked at 24 w); liver biopsy showed chronic hepatitis
81 [29]	M, 30	HCV	14	154	579,000	<260	2 mo	Vomiting, tender hepatomegaly; pruritic blistering eruption of cutaneous porphyria noted on hands; ALT, 460 IU/L

NOTE. ALT, alanine aminotransferase level; CMV, cytomegalovirus; HAART, highly active antiretroviral therapy; HBeAg, hepatitis B e antigen; HBV, hepatitis B virus; HCV, hepatitis C virus; NM, not mentioned; ref, reference; UD, undetectable.

peripheral blood ANC was 2400 cells/ μ L. *A. terreus* was again cultured from the BAL fluid. She recovered after 102 days of therapy with iv amphotericin B (total dose, 4 g), and consolidation chemotherapy was continued.

Literature Review

Our review of the literature in English found a total of 109 disease episodes (cases) in 107 patients that fit the definition of IRD. The patients' ages ranged from 12 to 69 years, with a median of 38 years. Forty cases were in males and 23 in females; for 46 cases, the age and sex of the patient were not mentioned.

Sixty-one patients (tables 1 and 2) were HIV-negative patients with hematologic malignancies (46), solid tumors (3), nephrotic syndrome (2), autoimmune diseases (2), severe combined immunodeficiency (6), or renal transplants (2). Among these HIV-negative patients, the source of immunosuppression was steroid therapy alone (1.6%), cytotoxic therapy alone (55.8%), steroid and cytotoxic therapy (29.5%), or bone marrow transplantation (13.1%). Preexisting infections were those due to *Aspergillus* species (37.7%), *Candida* species (13.1%), HBV (39.3%), parainfluenza virus (8.2%), and respiratory syncytial virus (1.7%).

The median time from recovery of neutrophil counts or the end of steroid therapy to the development of IRD was 8 days

for pulmonary aspergillosis and hepatosplenic candidiasis and 21 days for viral diseases, such as hepatitis B and viral pneumonitis. In 14 cases, this time interval was not mentioned. The outcome was not mentioned in 6 cases, but 41 of (67.2%) 61 patients died. Eleven patients were treated with inhaled or systemic steroids for IRD, but only 2 of them survived.

Clinical features of pulmonary aspergillosis included hemoptysis, cough, pleuritic chest pain, pneumothorax, and radiographic worsening in terms of enlargement of lesions, cavitation, or effusion. Manifestations of hepatosplenic candidiasis included abdominal pain, increasing ductal enzyme levels, and ultrasonographic evidence of enlarging abscess with the typical bull's eye lesion. Viral pneumonitis was predominantly manifested by respiratory failure and diffuse interstitial radiographic changes typical of pneumonitis. Deterioration due to hepatitis B presented as jaundice, upper abdominal pain, ascites, and features of hepatic failure.

Forty-six HIV-positive patients (tables 3 and 4) who had 48 episodes of IRD were reviewed. All episodes were related to the institution of HAART. Before the initiation of therapy, the CD4⁺ lymphocyte count ranged from 2 cells/ μ L to 220 cells/ μ L, with a median of 26 cells/ μ L. After HAART, the CD4⁺ lymphocyte count increased to a median of 149 cells/ μ L and ranged from 5 cells/ μ L to 420 cells/ μ L. In 4 reported episodes

Table 4. Summary of published cases of immunorestitution disease (IRD) in HIV-positive patients due to *Mycobacterium tuberculosis*, *Mycobacterium avium* complex, (MAC) *Mycobacterium xenopi*, and *Cryptococcus* species after highly active antiretroviral therapy (HAART).

Cases(s) [ref]	Sex (n), age in y of patient(s)	Organism	CD4 cells/ μ L		HIV RNA, copies/mL		Time to onset of IRD	IRD manifestation (treatment)
			Before HAART	After HAART, during IRD	Before HAART	After HAART		
79 [5]	NM	<i>M. tuberculosis</i>	25	NM	>750,000	NM	1-2 w	Fever, abdominal pain, HS; CT scan showed enlargement of mesenteric and retroperitoneal lymph nodes (oral steroid)
80 [5]	NM	<i>M. tuberculosis</i>	37	NM	74,000	NM	1-2 w	Fever, abdominal pain, pleural effusion, ascites, weight loss, HS (oral steroid)
81 [5]	NM	<i>M. tuberculosis</i>	26	NM	290,000	NM	1-2 w	Fever; chills, scrotal swelling; USG showed hyperemic enlargement of testicles, epididymis (oral steroid)
82 [6]	M, 44	<i>M. tuberculosis</i>	220	420	>750,000	NM	6 w	Fever; left cervical lymph nodes; CXR showed new mediastinal, hilar adenopathy with infiltrates (oral steroid)
83a [7]	NM	<i>M. tuberculosis</i>	12	5	134,615	5843	15 d	Fever; intrathoracic adenopathies; worsening perihilar infiltrate
83b [7]	NM	<i>M. tuberculosis</i>	5	37	104,882	583	11 d	Fever
84 [7]	NM	<i>M. tuberculosis</i>	80	67	3,420,595	4719	2 d	Fever; intrathoracic and cervical adenopathies
85 [7]	NM	<i>M. tuberculosis</i>	27	33	907,585	914	10 d	Fever
86 [7]	NM	<i>M. tuberculosis</i>	91	116	581,694	4032	4 d	Fever
87 [7]	NM	<i>M. tuberculosis</i>	2	32	1,319,555	4516	17 d	Intrathoracic and cervical adenopathies
88 [7]	NM	<i>M. tuberculosis</i>	35	169	750,000	6527	5 d	Fever; ascites; worsening LLL infiltrates with pleural effusion
89 [7]	NM	<i>M. tuberculosis</i>	75	30	31,987	<400	5 d	Cutaneous tuberculosis, pleural effusion (oral steroid)
90 [7]	NM	<i>M. tuberculosis</i>	133	110	4,275,175	2735	19 d	Fever; intrathoracic and cervical adenopathies
91 [7]	NM	<i>M. tuberculosis</i>	87	194	NM	7890	16 d	Fever; intrathoracic adenopathies
92 [7]	NM	<i>M. tuberculosis</i>	20	65	271,921	2061	12 d	Fever; hilar and cervical adenopathies, miliary infiltrates
93 [7]	NM	<i>M. tuberculosis</i>	73	283	62,727	3914	40 d	Cervical adenopathies
94 [7]	NM	<i>M. tuberculosis</i>	17	62	1,831,622	6072	32 d	Increased paratracheal adenopathy with new RUL infiltrates
95-99 [30]	M(3) F(2), median, 33 [rng, 23-42]	MAC	Median, 25 [rng, 5-39]	Median, 178 [rng, 56-205]	>100,000	NM	Median, 11 d [rng, 6-20 d]	High fever (39.4°C-41.1°C), abdominal pain, leukocytosis; excisional lymph node biopsy for 4 patients revealed well-formed granulomatous inflammation
100a [31]	F, 37	MAC	<10	160	NM	NM	10 d	Fever (39.4°C), weight loss, nausea, hepatomegaly; liver biopsy revealed granuloma containing acid-fast bacilli; cultures of blood, bone marrow, and hepatic tissue showed MAC
100b [31]	F, 37	MAC	10	120	NM	NM	21 d	Mediastinal lymphadenopathy and ulceration of a supraclavicular lymph node; culture revealed MAC
101 [31]	M, 38	MAC	20	100	NM	NM	12 w	Cough, abdominal discomfort; CXR showed a dense infiltrate in the right lung, CT of abdomen revealed enlarged para-aortic lymph node
102 [31]	F, 30	MAC	<10	NM	>100,000	<1000	8 d	Fever; cough dyspnea; CXR showed patchy lesions in right lower lung and mediastinal lymphadenopathy; culture of the lymph node yielded MAC
103 [31]	M, 38	<i>M. xenopi</i>	19	>400	>10,000	<1000	1 mo	Fever; watery diarrhea; CXR and CT showed multiple bilateral nodules and left-sided pleural effusion; culture of sputum and stool revealed <i>M. xenopi</i>
104 [32]	NM	<i>Cryptococcus</i> sp.	5	70	2,600,000	<200	7 d	Fever; pain, bilateral eye pain, frontal headache, neck stiffness, nausea vomiting
105 [32]	NM	<i>Cryptococcus</i> sp.	40	240	480,000	1300	11 d	Fever; neck stiffness
106 [33]	M, 28	<i>Cryptococcus</i> sp.	6	63	560,000	3700	8 mo	Recurrence of enlarged lymph nodes; aspiration showed numerous yeast cells compatible with cryptococci; lymphadenitis resolved in ≤ 2 w when naproxen was added
107 [33]	M, 30	<i>Cryptococcus</i> sp.	28	251	560,000	3830	NM	Fever; retropharyngeal abscess, cervical lymphadenitis; aspirate of abscess showed acute inflammation and many yeast cells compatible with cryptococci; persistent lymphadenitis for 9 mo (prednisone, 60 mg/d, produced dramatic improvement after a few days)

NOTE. CXR, chest radiography; HS, hepatosplenomegaly; LLL, left lower lobe; NM, not mentioned; ref, reference; rng, range; RUL, right upper lobe; USG, ultrasonography.

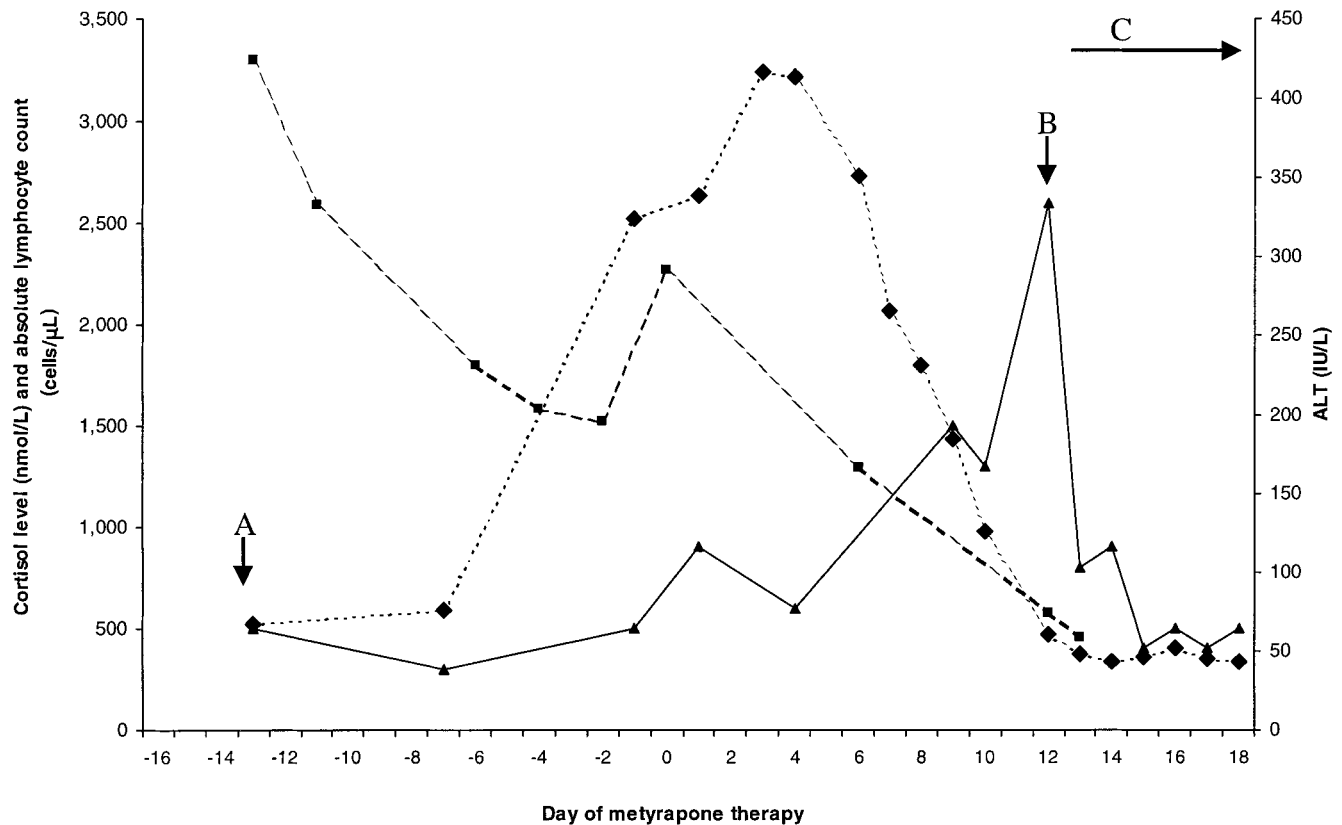


Figure 1. Profile of cortisol levels (■), lymphocyte counts (▲), and liver function values (◆) before and after metyrapone therapy for patient 1. A, CD4⁺ lymphocyte count, 120×10^9 cells/ μ L. B, CD4⁺ lymphocyte count, 1092×10^9 cells/ μ L. C, Commencement of 21 days of methylprednisolone treatment. ALT, alanine aminotransferase level.

(cases 83a, 84, 89, and 90), there was a decrease in CD4⁺ lymphocyte counts after initiation of HAART. The organisms that caused IRD included *M. tuberculosis* (35.4%), *M. avium* complex (18.7%), *M. xenopi* (2.1%), *Cryptococcus* species (8.4%), CMV (29.1%), HBV (2.1%), and HCV (4.2%).

For mycobacterial and fungal infections, the median interval between initiation of HAART and the onset of IRD was 11 days, whereas the interval for viral infections was 42 days. The interval was not mentioned for 4 cases. Fever was reported to occur in 20 (74%) of 27 cases of mycobacterial disease and in 3 of 4 cases of cryptococcal infection but not in those of viral disease. Ocular manifestations of CMV disease included visual loss and fundoscopic changes of inflammatory retinitis, vitritis, papillitis, and macular edema. Abdominal pain, ascites, pleural effusion, hepatosplenomegaly, testicular enlargement, tender cervical lymphadenopathy, and skin lesions were reported to occur in the cases of mycobacterial disease.

Chest radiography and CT scanning revealed effusions, mediastinal and retroperitoneal lymph node enlargement, and worsening pulmonary parenchymal or miliary shadows. Focal necrotizing lymphadenitis with well-formed granulomas was noted in patients with *M. avium* complex infection. The man-

ifestations of HBV and HCV infection were similar to those in HIV-negative patients. No deaths caused by IRD were reported to occur among HIV-positive patients. Good response was obtained with the use of systemic steroids (8 cases), repository steroids (1), and a nonsteroidal anti-inflammatory agent (1).

Discussion

The immune system has been demonstrated to play a critical role in host defense against opportunistic infections in neutropenic patients recovering from chemoradiotherapy, patients with AIDS who are receiving HAART, and congenitally immunodeficient patients who are undergoing immunoglobulin replacement or have undergone bone marrow transplantation. However, there are also anecdotal reports on the deleterious and occasionally fatal effects of inflammatory or immunopathological damage that comes with restitution of the immune system [12–18].

Many terms have been used to describe this disease entity, including immune recovery disease [4], immune reconstitution disease [36], immune restoration disease [29, 37], immune rebound illness [38, 39], and steroid-withdrawal disease [19]. The

term “immunorestitution disease” is used here to express the concept of immunosuppression followed by a “bouncing back” of the immune system. Attention to this disease entity was recently raised by a series of reports concerning HIV-positive patients presenting with a paradoxical inflammatory response to preexisting viral and mycobacterial infections after HAART [2–7]. However, little attention has been devoted to the existence of a similar entity in HIV-negative patients, and a clear and encompassing concept of IRD related to innate and adaptive immunity has not yet been formulated.

IRD related to adaptive immunity is illustrated in our first case. The onset of severe *P. carinii* pneumonitis and possibly CMV pneumonitis occurred while the CD4⁺ lymphocyte count was 1092 cells/ μ L, on day 12 of metyrapone therapy for Cushing’s disease. Though low-grade fever started on day 4 of metyrapone therapy, there were no clinical and radiographic features suggestive of inflammatory damage of the lungs until recovery of the CD4⁺ lymphocyte count. It is interesting that the liver function improved as the CD4⁺ lymphocyte count increased, a circumstance suggesting that the patient might have had CMV hepatitis during immunosuppression with high levels of endogenous steroid.

Systemic CMV infection was also evidenced by a 10-fold reduction in CMV DNA in the blood after recovery of the CD4⁺ lymphocyte count. It is presumed that both CMV and *P. carinii* were present in the lungs subclinically before the CD4⁺ lymphocyte count increased. However, we concede that there is an extremely low possibility that the *P. carinii* pneumonia was incidentally acquired when the CD4⁺ lymphocyte count was normal and at the highest point in the course of the patient’s illness. The CD4⁺ lymphocyte count decreased rapidly to 600 cells/ μ L on the day of clinical deterioration before initiation of therapy with methylprednisolone, presumably because of CD4⁺ lymphocyte migration into the lungs, as evidenced by the numerous lymphocytes detected in the BAL specimen. This may also explain the decrease in CD4⁺ lymphocyte count during IRD in the 4 patients receiving HAART (cases 83a, 84, 89, and 90; 4).

IRD related to innate immunity is illustrated by the second case. Similar cases have been reported in the literature but not from the perspective of paradoxical inflammatory damage due to recovery of the innate immune system [23, 24]. Unlike previously reported cases, our patient had preexisting *A. terreus* infection; presence of the organism in BAL during neutropenia was documented. Clinical symptoms and radiographic changes worsened while the neutrophil count increased to 2400 cells/ μ L. The release of proteolytic enzymes from neutrophils, causing lung-tissue destruction, probably facilitated the release of the hyphae into the bronchial lumen and pulmonary vasculature [23]. This may explain why only the second BAL specimen revealed typical findings of septated branching hyphae with dichotomous branching and numerous neutrophils, as well as the subsequent hemoptysis and radiological deterioration.

Preexisting asymptomatic or mildly symptomatic infections were documented clinically, serologically, or microbiologically in 86 (78.9%) of 109 episodes of IRD reported in the literature. In some cases, the preexistence of the microbes was presumed because the pathogen was much more likely to have been acquired during the intense immunosuppression than when the relevant laboratory markers of the immune system were already within normal limits. As expected, the infecting organisms in IRD were either slow growers, such as *M. tuberculosis* and *Cryptococcus* species, or opportunistic pathogens of relatively low virulence, such as *M. avium* complex, *Aspergillus*, and *Candida*. Similarly, the damage caused by latent viruses such as HBV is mainly immunopathological and may appear only after immunorestitution.

No pyogenic bacterial infection in cases of IRD was reported, probably because of the almost universal usage of potent and effective antimicrobials or because the fulminant course of severe pyogenic infections during immunosuppression would have resulted in early death.

Immune recovery was well documented in most of the HIV-positive patients by an increase in CD4⁺ lymphocyte counts, even though the interval between the onset of symptoms and the determination of CD4⁺ lymphocyte counts was not mentioned in many reports. In some HIV-negative cases, immune recovery after the administration of steroids or cytotoxic agents ended was only inferred since the exact dates of cell count determinations were not mentioned. The number of circulating neutrophils or CD4⁺ lymphocytes does not always reflect their number in the involved tissues or their in vivo functional status. Even less is known about the relationship of IRD to pathogen-specific CD4⁺ and CD8⁺ lymphocytes and antibody subsets. Thus, in cases 83a, 84, 89, and 90, the CD4⁺ lymphocyte count apparently decreased despite HAART and does not necessarily exclude IRD.

Though a clear temporal sequence was apparent, the interval between the onset of immune recovery and IRD was variable. It appeared that in both HIV-positive and HIV-negative patients, the period was 21–42 days for viruses and only 8–11 days for fungal and mycobacterial diseases. The latter pathogens are nonobligatory intracellular or extracellular organisms, in contrast to viruses, which are obligatory intracellular pathogens. This phenomenon raised the possibility that the pathogen-specific adaptive CD8⁺ cytotoxic T cell response may recover later than does innate neutrophil-mediated or adaptive CD4⁺ cell-mediated immunity. This postulation was confounded by the difference in the definition of this interval and the fact that the CD8⁺ lymphocyte count may not correlate with the degree of virus-specific lymphocytic cytotoxicity.

Clinical manifestations of opportunistic infections during immunosuppression are characterized by a high microbial tissue burden and systemic dissemination. In contrast, the manifestations of IRD are characterized by severe inflammatory and typical host responses to preexisting microbes. In patients with

prolonged neutropenia and disseminated fungal infections due to *Aspergillus* and *Candida* species, fever was the only initial symptom, and subsequent dissemination to skin, brain, and viscera often occurred concomitantly with shock. In patients with pulmonary aspergillosis, radiographic lesions during immunosuppression that were shown by chest radiography or CT scanning were due to the presence of mold or infarcted tissue.

During immunorestitution, pulmonary cavitation with central necrosis and massive hemoptysis might become clinically and radiologically overt [23, 24]. As for hepatosplenic candidiasis during immunorestitution, severe nausea, vomiting, upper abdominal pain, elevated alkaline phosphatase levels, ultrasonographic evidence of multiple well-formed abscesses with bull's eye lesions, and histologic findings of granulomatous inflammation with microabscesses and hyphae or pseudohyphae have been reported [40–44].

Primary or reactivated *M. tuberculosis* infection in immunosuppressed hosts may be rapidly progressive and be manifested by persistent fever, wasting, and extrapulmonary spread with high mycobacterial load [45, 46]. Chest radiography may yield normal findings or show miliary lesions. Skin tests with purified protein derivative (PPD) were always negative in our study. During immunorestitution, a severe inflammatory response to both pulmonary and extrapulmonary foci loaded with acid-fast bacilli resulted in worsening of pulmonary lesions, hypertrophy, and hyperplasia of the reticuloendothelial tissues of the liver, spleen, and lymph nodes. Histologic evidence of granulomatous inflammation would appear and the PPD skin test would turn positive [5–7].

In patients with AIDS whose CD4⁺ lymphocyte counts were <200 cells/ μ L, CMV retinitis was characterized by noninflammatory necrotizing lesions even in the presence of extensive retinal involvement, distinct from the fundoscopic changes of inflammatory retinitis, vitritis, papillitis, and macular edema that occurred after treatment with HAART [2–4]. In patients with severe combined immunodeficiency, respiratory viral infections due to parainfluenza virus and respiratory syncytial virus could present with mild upper or lower respiratory symptoms, with high levels of viral shedding. At the time of engraftment after bone marrow transplantation, there could be rapid deterioration, with fulminant pneumonitis and respiratory failure [20].

Diagnosis of IRD is never simple or straightforward since there are no clinical or laboratory tests that are specific for IRD. Indeed, IRD is a diagnosis of exclusion. During immunorestitution, paradoxical worsening of clinical symptoms and signs of a preexisting infection should be carefully investigated. Such presentations may be a result of inadequate antimicrobial therapy, development of drug resistance, superinfection by other organisms, or development of noninfectious complications. A diagnosis of IRD can be made after all these possibilities are excluded.

Development of IRD probably requires an interaction be-

tween the tissue burden of preexisting microbes, virulence of the organism, and exactness or restriction of the immune system. Three combinations can be envisaged. First, patients with a high microbial load or infected with more virulent microbes may die of overwhelming sepsis even before recovery of the immune system. This is exemplified by the absence of pyogenic bacterial infections reported in IRD. Second, patients with a low microbial burden and orderly recovery of the immune system may have only subclinical IRD, so the diagnosis may be missed. Thus only the third group of patients, those with an appropriately significant microbial burden and relative “overshooting” of immune recovery, may have a clinically significant systemic or local inflammatory response during immunorestitution. Factors affecting the onset and severity of IRD during immune recovery still await further study.

Morbidity was clearly documented for IRD, as systemic or local inflammatory response and loss of function. However, mortality attributed to IRD was not as certain. No mortality was reported for AIDS patients receiving HAART, but a high mortality was noted among HIV-negative patients. This phenomenon is primarily confounded by the lack of highly effective antifungal or antiviral therapy against *Aspergillus*, *Candida*, and hepatitis and respiratory viruses.

The therapeutic intervention for IRD is not well established. The use of appropriate antimicrobial agents is the prerequisite for success in most cases. Anti-inflammatory agents such as nonsteroidal drugs and local or systemic steroids seem to give promising results in terms of arrest of the acute inflammatory damage during IRD after initiation of HAART in HIV-positive patients. However, the results of steroid use for hepatitis flares induced by chemotherapy withdrawal were disappointing in patients with chronic hepatitis B.

The ideal situation in the treatment of IRD is to attain exact control of the overwhelming immune system by immunomodulation. For example, iv infusion of immunoglobulin combined with ganciclovir has been proven to reduce the mortality associated with postengraftment CMV pneumonitis in bone marrow transplant recipients [47]. It should also be investigated for use against IRD related to respiratory syncytial virus and parainfluenza virus infection. Recently, a combination of thalidomide plus antibiotics was shown to protect rabbits in an experimental model from death due to tuberculous meningitis, via the inhibition of tumor necrosis factor [48]. Although the role of interleukins and cytokines in IRD is still uncertain, immunotherapy should be the future direction of treatment. IRD may be prevented if asymptomatic infection is screened for and appropriate prophylaxis is given before and throughout the period of immunosuppression. However, it seems imprudent to treat all such asymptomatic patients, since it appears that only a minority will develop immunopathological damage. Prophylaxis should be considered for certain high-risk patients such as bone marrow transplant recipients. Antimicrobial therapy plus short-term immunosuppression with gradual dose reduc-

tion may decrease morbidity and prevent permanent functional loss [5, 6].

Preemptive immunosuppression with steroids, without simultaneous effective antimicrobial coverage, is probably counterproductive in the treatment of IRD. Adoptive transfer of pathogen-specific immune function may also be effective in preventing the onset of symptomatic disease when the tissue burden of the pathogen is still low. This was illustrated by the prophylactic use of CMV-specific cytotoxic T lymphocytes in allogeneic bone marrow transplant recipients [49]. This therapeutic modality is especially important if no effective antimicrobial is available or resistance to prophylaxis develops rapidly. IRD is an emerging clinical entity that merits further study.

Acknowledgments

We are most grateful to the staff of the Department of Microbiology, Queen Mary Hospital, Hong Kong, for their technical support and to Dr. J. Lo for critical review of the manuscript.

References

- Powderly WG, Landay A, Lederman MM. Recovery of the immune system with antiretroviral therapy: the end of opportunism? *JAMA* **1998**;280:72-7.
- Jacobson MA, Zegans M, Pavan PR, et al. Cytomegalovirus retinitis after initiation of highly active antiretroviral therapy. *Lancet* **1997**;349:1443-5.
- Reed JB, Schwab IR, Gordon J, Morse LS. Regression of cytomegalovirus retinitis associated with protease-inhibitor treatment in patients with AIDS. *Am J Ophthalmol* **1997**;124:199-205.
- Karavellas MP, Lowder CY, Macdonald C, Avila CP Jr, Freeman WR. Immune recovery vitritis associated with inactive cytomegalovirus retinitis: a new syndrome. *Arch Ophthalmol* **1998**;116:169-75.
- Furrer H, Malinverni R. Systemic inflammatory reaction after starting highly active antiretroviral therapy in AIDS patients treated for extrapulmonary tuberculosis. *Am J Med* **1999**;106:371-2.
- Chien JW, Johnson JL. Paradoxical reactions in HIV and pulmonary TB. *Chest* **1998**;114:933-6.
- Narita M, Ashkin D, Hollender ES, Pitchenik AE. Paradoxical worsening of tuberculosis following antiretroviral therapy in patients with AIDS. *Am J Respir Crit Care Med* **1998**;158:157-61.
- Limper AH, Offord KP, Smith TF, Martin WJ II. *Pneumocystis carinii* pneumonia. Differences in lung parasite number and inflammation in patients with and without AIDS. *Am Rev Respir Dis* **1989**;140:1204-9.
- Yuen KY, Lo SK, Chiu EK, et al. Monitoring of leukocyte cytomegalovirus DNA in bone marrow transplant recipients by nested PCR. *J Clin Microbiol* **1995**;33:2530-4.
- Woo PC, Lo SK, Yuen KY, et al. Detection of CMV DNA in bone marrow transplant recipients: plasma versus leucocyte polymerase chain reaction. *J Clin Pathol* **1997**;50:231-5.
- The TH, van der Ploeg M, van den Berg AP, Vlieger AM, van der Giessen M, van Son WJ. Direct detection of cytomegalovirus in peripheral blood leukocytes: a review of the antigenemia assay and polymerase chain reaction. *Transplantation* **1992**;54:193-8.
- Galbraith RM, Eddleston AL, Williams R, Zuckerman AJ. Fulminant hepatic failure in leukaemia and choriocarcinoma related to withdrawal of cytotoxic drug therapy. *Lancet* **1975**;2:528-30.
- Hanson CA, Sutherland DE, Snover DC. Fulminant hepatic failure in an HBsAg carrier renal transplant patient following cessation of immunosuppressive therapy. *Transplantation* **1985**;39:311-2.
- Thung SN, Gerber MA, Klion F, Gilbert H. Massive hepatic necrosis after chemotherapy withdrawal in a hepatitis B virus carrier. *Arch Intern Med* **1985**;145:1313-4.
- Onwubalili JK. Fulminant hepatic failure in nephrotic syndrome related to withdrawal of immunosuppressive therapy. *Postgrad Med J* **1988**;64:325-7.
- Bird GL, Smith H, Portmann B, Alexander GJ, Williams R. Acute liver decompensation on withdrawal of cytotoxic chemotherapy and immunosuppressive therapy in hepatitis B carriers. *Q J Med* **1989**;73:895-902.
- Lau JY, Lai CL, Lin HJ, et al. Fatal reactivation of chronic hepatitis B virus infection following withdrawal of chemotherapy in lymphoma patients. *Q J Med* **1989**;73:911-7.
- Flowers MA, Heathcote J, Wanless IR, et al. Fulminant hepatitis as a consequence of reactivation of hepatitis B virus infection after discontinuation of low-dose methotrexate therapy. *Ann Intern Med* **1990**;112:381-2.
- Pinto PC, Hu E, Bernstein-Singer M, Pinter-Brown L, Govindarajan S. Acute hepatic injury after the withdrawal of immunosuppressive chemotherapy in patients with hepatitis B. *Cancer* **1990**;65:878-84.
- Taylor CE, Osman HKE, Turner AJL, et al. Parainfluenza virus and respiratory syncytial virus infection in infants undergoing bone marrow transplantation for severe combined immunodeficiency. *Communicable Disease and Public Health* **1998**;1:202-3.
- Caselitz M, Link H, Hein R, et al. Hepatitis B associated liver failure following bone marrow transplantation. *J Hepatol* **1997**;27:572-7.
- Pariente EA, Goudeau A, Dubois F, et al. Fulminant hepatitis due to reactivation of chronic hepatitis B virus infection after allogeneic bone marrow transplantation. *Dig Dis Sci* **1988**;33:1185-91.
- Albelda SM, Talbot GH, Gerson SL, Miller WT, Cassileth PA. Pulmonary cavitation and massive hemoptysis in invasive pulmonary aspergillosis: influence of bone marrow recovery in patients with acute leukemia. *Am Rev Respir Dis* **1985**;131:115-20.
- Pagano L, Ricci P, Nosari A, et al. Fatal haemoptysis in pulmonary filamentous mycosis: an undervalued cause of death in patients with acute leukaemia in haematological complete remission: a retrospective study and review of the literature. *Gimema Infection Program. Br J Haematol* **1995**;89:500-5.
- Todeschini G, Murari C, Bonesi R, et al. Invasive aspergillosis in neutropenic patients: rapid neutrophil recovery is a risk factor for severe pulmonary complications. *Eur J Clin Invest* **1999**;29:453-7.
- Thaler M, Pastakia B, Shawker TH, O'Leary T, Pizzo PA. Hepatic candidiasis in cancer patients: the evolving picture of the syndrome. *Ann Intern Med* **1988**;108:88-100.
- Pestalozzi BC, Krestin GP, Schanz U, Jacky E, Gmur J. Hepatic lesions of chronic disseminated candidiasis may become invisible during neutropenia. *Blood* **1997**;90:3858-64.
- Carr A, Cooper DA. Restoration of immunity to chronic hepatitis B infection in HIV-infected patient on protease inhibitor. *Lancet* **1997**;349:995-6.
- John M, Flexman J, French MA. Hepatitis C virus-associated hepatitis following treatment of HIV-infected patients with HIV protease inhibitors: an immune restoration disease? *AIDS* **1998**;12:2289-93.
- Race EM, Adelson-Mitty J, Krieger GR, et al. Focal mycobacterial lymphadenitis following initiation of protease-inhibitor therapy in patients with advanced HIV-1 disease. *Lancet* **1998**;351:252-5.
- Foudraire NA, Hovenkamp E, Notermans DW, et al. Immunopathology as a result of highly active antiretroviral therapy in HIV-1-infected patients. *AIDS* **1999**;13:177-84.
- Woods ML II, MacGinley R, Eisen DP, Allworth AM. HIV combination therapy: partial immune restitution unmasking latent cryptococcal infection. *AIDS* **1998**;12:1491-4.

33. Blanche P, Gombert B, Ginsburg C, et al. HIV combination therapy: immune restitution causing cryptococcal lymphadenitis dramatically improved by anti-inflammatory therapy. *Scand J Infect Dis* **1998**; 30:615–6.
34. National Institutes of Health–University of California Expert Panel for Corticosteroids as Adjunctive Therapy for Pneumocystis Pneumonia. Consensus statement on the use of corticosteroids as adjunctive therapy for pneumocystis pneumonia in the acquired immunodeficiency syndrome. *N Engl J Med* **1990**; 323:1500–4.
35. Yuen KY, Woo PC, Ip MS, et al. Stage-specific manifestation of mold infections in bone marrow transplant recipients: risk factors and clinical significance of positive concentrated smears. *Clin Infect Dis* **1997**; 25: 37–42.
36. Emery S, Lane HC. Immune reconstitution in HIV infection. *Curr Opin Immunol* **1997**; 9:568–72.
37. Nussenblatt RB, Lane HC. Human immunodeficiency virus disease: changing patterns of intraocular inflammation. *Am J Ophthalmol* **1998**; 125:374–82.
38. Harris J, Sengar D, Stewart T, Hyslop D. The effect of immunosuppressive chemotherapy on immune function in patients with malignant disease. *Cancer* **1976**; 37(2 Suppl):1058–69.
39. Nair PV, Tong MJ, Stevenson D, Roskamp D, Boone C. A pilot study on the effects of prednisone withdrawal on serum hepatitis B virus DNA and HBeAg in chronic active hepatitis B. *Hepatology* **1986**; 6: 1319–24.
40. Lewis JH, Patel HR, Zimmerman HJ. The spectrum of hepatic candidiasis. *Hepatology* **1982**; 2:479–87.
41. Bodey GP, Anaissie EJ. Chronic systemic candidiasis. *Eur J Clin Microbiol Infect Dis* **1989**; 8:855–7.
42. Pizzo PA, Walsh TJ. Fungal infections in the pediatric cancer patient. *Semin Oncol* **1990**; 17(3 Suppl 6):6–9.
43. Anaissie E, Bodey GP, Kantarjian H, et al. Fluconazole therapy for chronic disseminated candidiasis in patients with leukemia and prior amphotericin B therapy. *Am J Med* **1991**; 91:142–50.
44. Swerdloff JN, Filler SG, Edwards JE Jr. Severe candidal infections in neutropenic patients. *Clin Infect Dis* **1993**; 17(Suppl 2):S457–67.
45. Shafer RW, Edlin BR. Tuberculosis in patients infected with human immunodeficiency virus: perspective on the past decade. *Clin Infect Dis* **1996**; 22:683–704.
46. Gallant JE, Ko AH. Cavitory pulmonary lesions in patients infected with human immunodeficiency virus. *Clin Infect Dis* **1996**; 22:671–82.
47. Ljungman P, Engelhard D, Link H, et al. Treatment of interstitial pneumonitis due to cytomegalovirus with ganciclovir and intravenous immune globulin: experience of European Bone Marrow Transplant Group. *Clin Infect Dis* **1992**; 14:831–5.
48. Tsenova L, Sokol K, Freedman VH, Kaplan G. A combination of thalidomide plus antibiotics protects rabbits from mycobacterial meningitis-associated death. *J Infect Dis* **1998**; 177:1563–72.
49. Walter EA, Greenberg PD, Gilbert MJ, et al. Reconstitution of cellular immunity against cytomegalovirus in recipients of allogeneic bone marrow by transfer of T cell clones from the donor. *N Engl J Med* **1995**; 333: 1038–44.