

Glucosamine and chondroitin sulfate association increases tibial epiphyseal growth plate proliferation and bone formation in ovariectomized rats

Roberta Bastos Wolff

Federal University of São Paulo, Department of Gynecology and Climaterium, São Paulo/SP, Brazil.

OBJECTIVE: The growth plate consists of organized hyaline cartilage and serves as a scaffold for endochondral ossification, a process that mediates longitudinal bone growth. Based on evidence showing that the oral administration of glucosamine sulfate (GS) and/or chondroitin sulfate (CS) is clinically valuable for the treatment of compromised articular cartilage, the current study evaluated the effects of these molecules on the tibial epiphyseal growth plate in female rats.

METHOD: The animals were divided into two control groups, including vehicle treatment for 45 days (GC45) and 60 days (GC60) and six ovariectomized (OVX) groups, including vehicle treatment for 45 days (GV45), GS for 45 days (GE45GS), GS+CS for 45 days (GE45GS+CS), vehicle for 60 days (GV60), GS for 60 days (GE60GS) and GS+CS for 60 days (GE60GS+CS). At the end of treatment, the tibias were dissected, decalcified and processed for paraffin embedding. Morphological and morphometric methods were employed for analyzing the distal tibial growth plates using picosirius red staining and the samples were processed for histochemical hyaluronan detection. Morphometric analyses were performed using the 6.0ProPlus® Image system.

RESULTS: Notably, after 60 days of treatment, the number of proliferative chondrocytes increased two-fold, the percentage of remaining cartilage increased four-fold and the percentage of trabecular bone increased three-fold in comparison to the control animals.

CONCLUSION: GS and CS treatment drugs led to marked cellular proliferation of the growth plate and bone formation, showing that drug targeting of the tibial epiphyseal growth plate promoted longitudinal bone growth.

KEYWORDS: Growth Plate; Ovariectomy; Rat; Glucosamine Sulfate; Chondroitin Sulfate.

Wolff RB. Glucosamine and chondroitin sulfate association increases tibial epiphyseal growth plate proliferation and bone formation in ovariectomized rats. *Clinics*. 2014;69(12):847-853.

Received for publication on July 1, 2014; First review completed on August 11, 2014; Accepted for publication on September 10, 2014

E-mail: robertawolff@uol.com.br

Tel.: 55 11 98696-9693

INTRODUCTION

Bone formation through endochondral ossification is a process initiated by mesenchymal cell condensation that forms a cartilaginous scaffold that is later replaced by bone (1). However, in diarthroid joints, not all cartilage of the scaffold is substituted by bone and the growth plate remains responsible for further endochondral ossification (2-3).

The outcome of this process is chondrocyte differentiation, which leads to subsequent proliferation and hypertrophy and the concomitant expression of specific genes in cartilaginous tissue (4). Terminal differentiation of the

cartilage induces the mineralization of cartilaginous extracellular matrix (ECM) and death of chondrocytes by means of programmed cellular death (PCD) (5). During the longitudinal growth period, the rate of cartilage formation is balanced by substitution with bone tissue, which makes the growth plate size remain constant. For this reason, hypertrophic chondrocytes must be eliminated (4-7). At the end of ossification, the growth plate decreases in thickness, although the articular cartilage remains (8-9). However, both types of tissue undergo age-related changes, which increase the risk of articular cartilage degeneration because of decreased bone formation and may reduce or hinder movement through the joint. Thus, the discovery of new agents able to protect this tissue is needed (10).

The growth plate articular cartilage is known for its low capacity to self repair, which is likely associated with the lack of blood supply, reduced mobility and a limited number of progenitor cells (1). Therefore, some authors have suggested that supplementation with glucosamine sulfate (GS), alone or in combination with chondroitin

Copyright © 2014 CLINICS – This is an Open Access article distributed under the terms of the Creative Commons Attribution Non-Commercial License (<http://creativecommons.org/licenses/by-nc/3.0/>) which permits unrestricted non-commercial use, distribution, and reproduction in any medium, provided the original work is properly cited.

No potential conflict of interest was reported.

DOI: 10.6061/clinics/2014(12)10



sulfate (CS+GS), can stimulate regeneration of this cartilage through chondrogenesis of mesenchymal cells and reduce the risk of cartilage damage via proteoglycan synthesis. Additionally, these compounds may alleviate pain in cases of osteoarthritis and may possess anti-inflammatory activity that can alter the progression of the disease (11). In addition, cartilage degeneration is a serious problem for post-menopausal and elderly women and some studies suggest that estrogen deficiency plays a role in its development (12).

Surgical bilateral ovariectomy is used to induce hypogonadism in rats, which results in the degeneration of cartilage and bone (13) and studies using this experimental animal model are important for evaluating the effects of various substances on cartilage damage. However, the effects of GS alone or in combination with CS on the growth plate are not well known, although their chondroprotective effects for the treatment of osteoarthritis have been advocated by some authors (14-16). To test the hypothesis that GS and CS can influence the growth plate, ovariectomized (OVX) adult female rats were studied.

METHODS

All experimental protocols were approved by the Research Ethics Committee on Animal Experimentation of São Paulo Federal University (UNIFESP-EPM/project 1179/05) and the animals were maintained in accordance with the National Institutes of Health guidelines for the Care and Use of Laboratory Animals (17).

Animals

A total of 80, four-month-old virgin rats (*Rattus norvegicus albinus*) weighing 250–300 g were used. The animals were provided by the Center for the Development of Experimental Models (CEDEME) of the Federal University of São Paulo (UNIFESP - EPM) and were kept in plastic cages with controlled light and temperature, and fed a soy-free diet and water *ad libitum*.

The rats were submitted to colpocitological examination for 21 consecutive days for the evaluation of normal estrous cycles, after which time 60 animals were subjected to bilateral OVX. A post-surgical period of 28 days was observed in order to obtain significant depletion of the estrogen levels (18). The rats were randomly divided into the following six experimental groups, each consisting of ten animals: GV45 – treatment with vehicle (NaCl 0.9%) for 45 days; GE45GS – treatment with GS (9 mg/kg) for 45 days; GE45GS+CS – treatment with GS (9 mg/kg) + CS (9 mg/kg) for 45 days; GV60 – treatment with NaCl 0.9% for 60 days; GE60GS – treatment with GS (9 mg/kg) for 60 days and GE60GS+CS – treatment with GS (9 mg/kg) + CS (9 mg/kg) for 60 days. The remaining intact animals in the proestrous phase (n=20) were used as controls, which comprised the two following groups of ten animals each: GC45 – treatment with NaCl 0.9% for 45 days and GC60 – treatment with NaCl 0.9% for 60 days. Treatments were given by gavage (0.5 mL per day), always at 04:00 p.m. and the drug dosing protocols were selected based on previous experimental data.

At the end of the treatment, all animals were euthanized with an excess of anesthesia (xylazine 20 mg/kg plus ketamine 100 mg/kg, administered intraperitoneally (i.p.)). The tibias were dissected and fixed in 10% phosphate-buffered

formaldehyde for 24 h and then decalcified in 10% buffered formic acid for 7 days (19). The fragments were then dehydrated and processed for paraffin embedding. Eight 4- μ m-thick sections were prepared for each sample, with two used for hematoxylin-eosin (H.E.) staining and two used for sirius red-hematoxylin staining. The remaining four slices were processed for immunohistochemical analyses. The slices were used for histological and morphometrical evaluations.

Immunoexpression of hyaluronan

The sections were rehydrated in a graded series of ethanol and water. They were then incubated for 30 min in 3% hydrogen peroxidase in PBS (Amersham Life Sciences Buckinghamshire, England, UK), followed by b-HABP (1:150; Seikagaku Corporation, Chiyoda-ku, Japan) in 1% BSA/PBS for 1 h at 40°C. Then, the sections were pre-digested with 50 ng of *Streptomyces* hyaluronidase in PBS (Sigma-Aldrich Co., St Louis, Missouri, USA), which specifically degrades hyaluronan acid (HA), for 1 h at 37°C. This step was followed by incubation in horseradish peroxidase-labeled streptavidin solution (NOVOCastra Super Novostain Reacting ABC Kit, Leica Microsystem Inc, Buffalo Grove, USA) for 1 h at room temperature, 0.05% 3,3'-diaminobenzidine (NOVOCastra Liquid DAB Substrate Kit NCL-L-DAB, Leica Microsystem Inc., Buffalo Grove, USA) and 0.03% hydrogen peroxide in PBS and counterstaining with methyl green (Sigma-Aldrich Co Diagnostics, St. Louis, Missouri, USA) for 30 min. The prepared specimens were examined by light microscopy (Nikon E800 Eclipse, Nikon Imaging Japan Inc, Japan) and digital images of growth plate area were obtained. Quantification was obtained by evaluating the brownish color density resulting from the binding of endogenous HA to the biotinylated probe (20-21).

Histomorphometric analysis

The central two-thirds of the growth plate sections (sagittal area) of the distal epiphyseal growth plate and the subjacent newly formed bone were used in the histomorphometric analysis. Images were captured with a digital system (light microscope connected to Nikon DXM1200F[®] digital camera) using Nikon software (ACT-1 2.62 version 2000[®]). The histomorphometric measures were analyzed using Image Pro Plus 6.0 software (Media Cybernetics). Ten microscope fields per histological section (total of five slices per animal) were analyzed using a 36-point intersection grid (Weibel's reticulum to measure the newly formed bone (remaining cartilage, trabecular bone and the bone marrow) and the growth plate cartilage activity (thickness of the resting zone (RZ), proliferative zone (PZ) and hypertrophic zone (HZ), along with total zone estimates)). To prevent overcounting due to the reticular extremity effect, which has been reported, two lines of the grid extremities were not considered. In addition, five different slices from each animal were analyzed with the Image Pro Plus 6.0 digital system to determine the chondrocyte number and the thickness of the RZ, HZ and PZ of the growth plate. Ten areas of five different slices from each animal were analyzed under 400 \times magnification and the intensity of hyaluronan staining and the quantitation by optical density (O.D.) of positively marked cells were determined (22).



Statistical analysis

The data from histomorphometric analyses are given as the mean \pm SD. The statistics software GraphPad Prism version 4.02 for Windows (San Diego, California) was used to calculate the means and mean deviations and differences were evaluated by analysis of variance (ANOVA), parametric tests (testing differences between two or more variables), Bonferroni test and nonparametric tests (testing independent samples). Statistical significance was set at $p < 0.05$ (23).

RESULTS

Morphology

The cellular arrangement of the epiphyseal disk in the GV45 and GV60 groups was disorganized and the remaining cartilage and trabecular bone area were decreased. Significant reductions in the number of resting and proliferative chondrocytes and PZ thickness were also noticed. Moreover, these groups showed increases in RZ and HZ thickness as well as the bone marrow area (Figure 1). Compared to GV45 and GV60, the GE45GS, GE45GS+CS, GE60GS and GE60GS+CS groups presented an organized cellular arrangement and increases in the number of resting and proliferative chondrocytes, PZ thickness, remaining cartilage and the trabecular bone area. In addition, these groups showed a decrease in the number of hypertrophic chondrocytes in the bone marrow area, as well as a decrease in RZ and HZ thickness. In all cases, the most significant alterations of these histomorphological parameters occurred 60 days after treatment. Figure 2 shows that in all groups, evident hyaluronan staining was only present in the HZ.

Histomorphometric assessment

The histomorphometric data regarding the effect of GS and GS+CS treatments for 45 or 60 days on the growth plate are shown in Table 1. The percentages of resting and proliferative chondrocytes in the GE45GS, GE45GS+CS, GE60GS and GE60GS+CS groups were higher than those observed in the GV45 and GV60 groups ($p < 0.001$). The percentages of hypertrophic chondrocytes in groups GE45GS, GE60GS and GE60GS+CS were significantly lower than those in groups GV45 and GV60 ($p < 0.01$). The resting and hypertrophic cartilage thickness in groups GE45GS, GE45GS+CS, GE60GS and GE60GS+CS was lower than that observed in groups GV45 and GV60 ($p < 0.01$). Moreover, the thickness of the proliferative cartilage in groups GE45GS, GE45GS+CS, GE60GS and GE60GS+CS was significantly increased when compared to that in groups GV45 and GV60 ($p < 0.001$). No difference was found among the groups with respect to the total cartilage thickness of the growth plate. Regarding the bone formation area, the percentages of remaining cartilage and trabecular bone in groups GE45GS, GE45GS+CS, GE60GS and GE60GS+CS were all consistently higher than those found in groups GV45 and GV60 ($p < 0.001$). The percentages of bone marrow area in groups GE45GS, GE45GS+CS, GE60GS and GE60GS+CS were significantly lower than those in groups GV45 and GV60 ($p < 0.001$). Hyaluronan content in the growth plate, obtained through optical density (O.D.) measurements, revealed that only the GE60GS and GE60GS+CS groups showed significant differences, with an increased O.D. value for hypertrophic chondrocytes.

DISCUSSION

GS and CS are found naturally in connective tissues and as constituents of glycosaminoglycans, the building blocks of the large aggregating proteoglycans of the cartilage that are important for cartilage health. CS is a major component of glycosaminoglycan, while GS is a constituent of the disaccharide building blocks of CS. These structures play a role in the cartilage matrix and may improve the strength of this tissue (11,23). Our data suggest that GS may act to improve the cartilage in OVX rats, particularly after 60 days of treatment.

It is important to emphasize that our histological analysis of the epiphyseal growth plate in the control groups showed similar findings as those described by Roach et al. (9) for adult rats, with three distinct hyaline cartilage zones (5,9). Therefore, the control animals in our study were similar to those previously described in the literature.

The rate at which chondrocytes carry out these events is called "turnover", and this process varies from species to species (24-25). The ossification process occurs in functionally active growth plates and requires the correct spatial and temporal regulation of a series of events. During the differentiation of growth plate chondrocytes, a complex interaction exists among systemic, paracrine, autocrine and intrinsic factors, which can change with aging (senescence) (26-27). In some mammals, including humans, the growth plate gradually gets thinner, ossifies and ceases longitudinal growth during adulthood. However, in some small rodents, such as rats, the growth plate is maintained, showing continued longitudinal growth throughout the lifespan of the animal. In older rats, the growth plate structure and thickness is maintained but is not functional and longitudinal growth ceases at a certain point (28-31). For this reason, the rat model may be helpful in evaluating the effects of GS on the cartilage.

Some studies have suggested that estrogen helps to regulate chondrocyte maturation but does not directly stimulate ossification. Instead, this sexual hormone speeds up the normal process of senescence and the cessation of longitudinal growth via the exhaustion of the proliferative potential of chondrocytes (32-34). To accelerate the senescence process in adult animals, OVX was performed in our study. After this procedure, which was followed by a decrease in estrogen, some histological structures similar to those found in older animals were observed.

The difference of 15 treatment days between the groups was significant, showing that the senescence process was more accentuated in the 60-day OVX group treated with vehicle. In fact, these animals presented morphological and structural changes on the growth plate, with an increase in hypertrophic chondrocytes and a decrease in proliferative chondrocytes (3,5,9). This effect was similar to data reported by Tivesten et al. (12). Additionally, an acellular region was observed in the RZ, along with disorganization in the PZ and HZ arrangement and loss of synchrony of the cartilage zones of growth plate. All of these events increase with senescence, as previously reported by Helmtrud et al. (10) in their study of rat growth plates after the cessation of longitudinal growth.

GS and CS have been used separately or in association in the treatment of degenerative joint processes (11,14-15,24) and they have been shown to participate in component reconstitution of the ECM of the hyaline cartilage in some

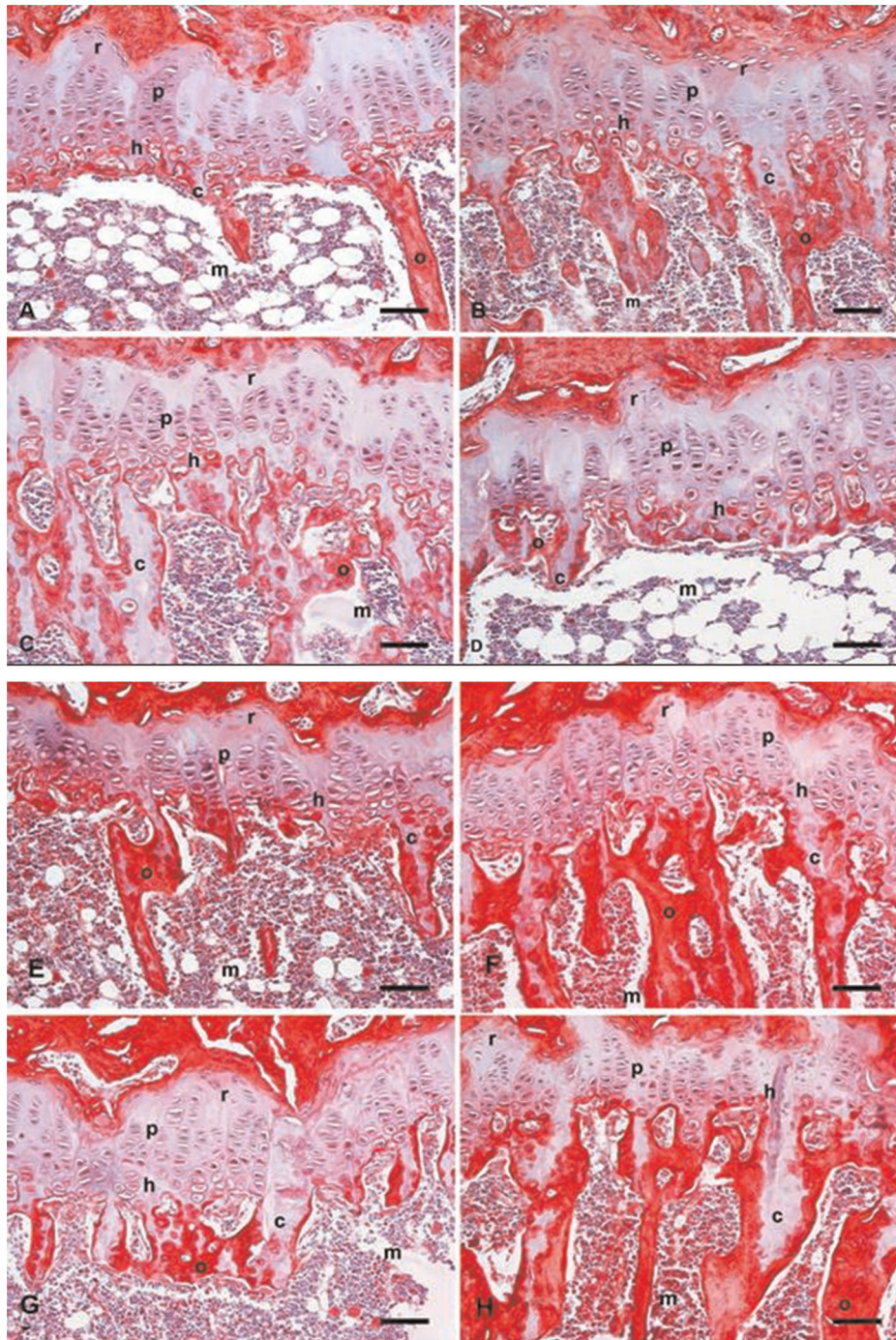


Figure 1 - Growth plate photomicrographs of the following: A – non-OVX rats treated for 45 days with vehicle (GC45); B – OVX rats treated for 45 days with vehicle (GV45); C – non-OVX rats treated for 60 days with vehicle (GC60); D – OVX rats treated for 60 days with vehicle (GV60); E – OVX rats treated for 45 days with GS (GE45GS); F – OVX rats treated for 45 days with GS+CS (GE45GS+CS); G – OVX rats treated for 60 days with GS (GE60GS); and H – OVX rats treated for 60 days with GS+CS (GE60GS+CS). Sirius red-hematoxylin staining. (r: resting cartilage; p: proliferative cartilage; h: hypertrophic cartilage, c: remaining cartilage, o: trabecular bone, m: bone marrow). Scale bar = 75 μm.

joints (14,35). In our study about the effects of these drugs on the growth plate, treatment with GS alone was similar to treatment with GS in association with CS. As evidenced by Morelli et al. (16), these drugs have a delayed action on the cartilage of the joint and they need to be applied for at least one month prior to the manifestation of improvements in the degenerated cartilage.

The action of GS may be explained by the acceleration of the longitudinal growth of the plate (14). In rats, this process is independent of the influence of estrogen. This effect on bone longitudinal growth is referred to as “catch-up growth” and is intrinsic to the growth plate. Van der Eerden et al. (36) suggested that this action may occur after retardation in longitudinal growth of the plate, which is

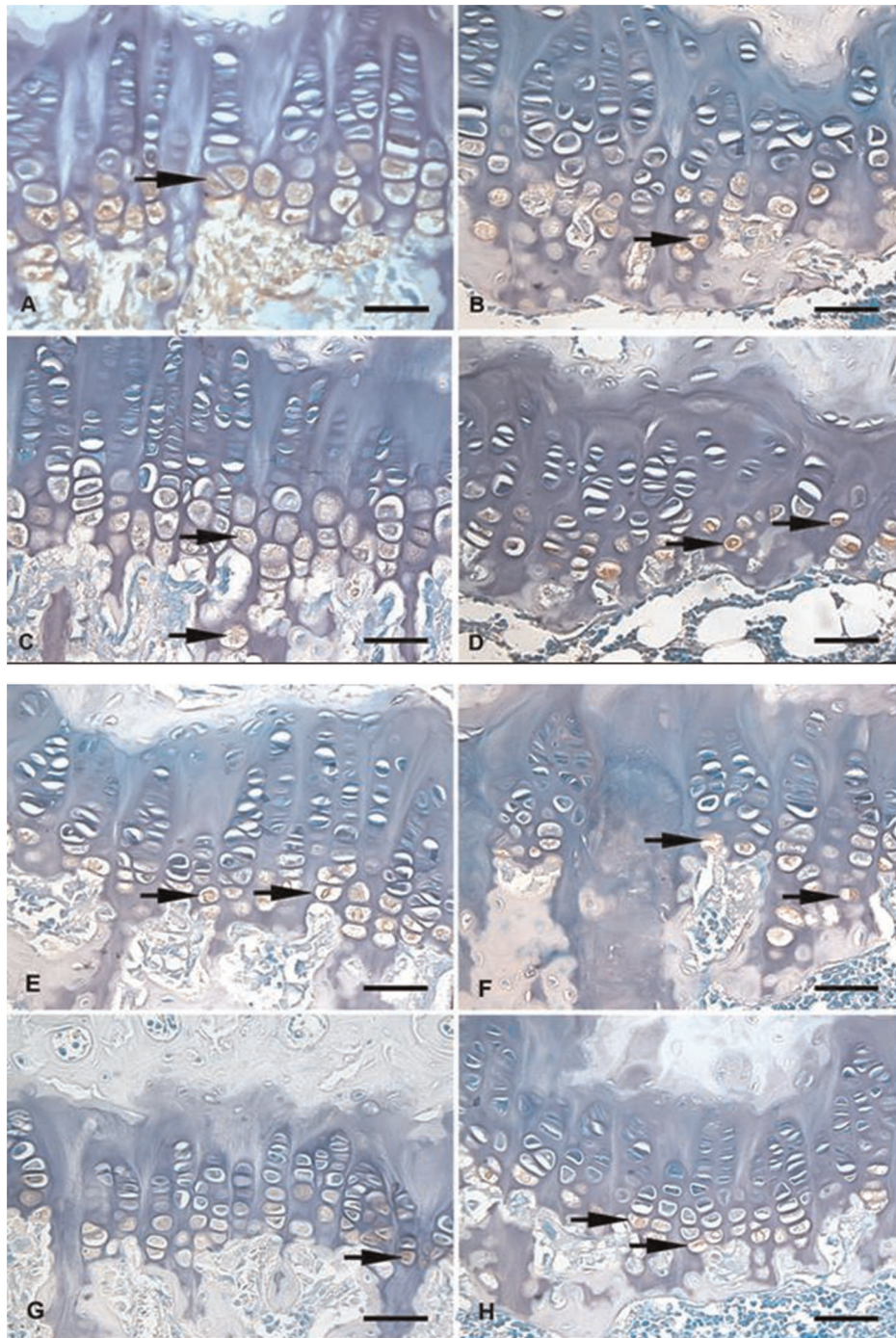


Figure 2 - Growth plate photomicrographs of the following: A: non-OVX rats treated for 45 days with vehicle (GC45); B: OVX rats treated for 45 days with vehicle (GV45); C: non-OVX rats treated for 60 days with vehicle (GC60); D: OVX rats treated for 60 days with vehicle (GV60); E: OVX rats treated for 45 days with GS (GE45GS); F: OVX rats treated for 45 days with GS+CS (GE45GS+CS); G: OVX rats treated for 60 days with GS (GE60GS); and H: OVX rats treated for 60 days with GS+CS (GE60GS+CS). Histochemical staining of hyaluronan counterstained with methyl green (arrows). Scale bar=50 µm.

associated with the loss of mitotic activity of proliferative chondrocytes. After this process, the proliferative capacity of the chondrocytes returns, but is much accentuated to compensate for the previous lack of longitudinal growth. Therefore, if animals show increased ingestion of important components of the matrix during this phase, the cartilage damage may be lessened.

The quantitation of hyaluronan in hypertrophic chondrocytes in our study should be emphasized. Pavasant et al. (20) and Suzuki et al. (22) showed that the expression of hyaluronan in hypertrophic chondrocytes was evidenced in the pericellular region, between the chondrocyte and its territorial matrix. These chondrocytes synthesize a great amount of hyaluronan, which, together with aggrecan, is



Table 1 - Morphometrical data of tibial histological analyses after the treatment of OVX rats with GS (9 mg/kg) and/or CS (9 mg/kg) for 45 or 60 days, as indicated (for further details, see materials and methods section). Each group consisted of 10 rats and the values correspond to the mean ± SD.

NUMBER OF CHONDROCYTES (%)								
CARTILAGE ZONES	GE45GS	GE60GS	GE45GS+CS	GE60GS+CS	GV45	GV60	GC45	GC60
Resting	16.0±0.4a	19.5±0.5a	15.0±3.0a	17.5±3.4a	10.0±0.8	8.0±1.2	14.0±2.3	15.0±0.4
Proliferative	55.0±3.7a	58.5±0.6a	51.5±5.4b	57.0±8.7a	47.5±3.9	43.0±3.0	49.5±1.4	47.5±3.7
Hypertrophic	29.0±3.0b	22.0±0.8a	33.5±2.1	25.5±1.1a	42.5±4.1	49.0±2.2	36.5±2.1	37.5±0.1
CARTILAGE THICKNESS (µm)								
CARTILAGE ZONES	GE45GS	GE60GS	GE45GS+CS	GE60GS+CS	GV45	GV60	GC45	GC60
Resting	36.0±1.5	31.5±5.5a	35.0±0.6c	32.5±1.0a	44.0±1.4	47.5±0.7	38.5±0.7	39.5±0.7
Proliferative	74.5±0.6a	81.5±1.5a	70.0±1.5b	77.0±3.5a	58.0±0.0	48.0±1.4	70.0±0.0	66.5±0.0
Hypertrophic	47.5±2.3b	43.5±0.6a	51.0±3.1	47.0±1.5a	56.0±1.4	63.0±1.4	48.5±1.4	50.5±0.7
Total	158.0±0.0	156.5±5.0	156.0±2.1	156.5±3.6	158.0±2.1	158.5±1.4	157.0±3.5	156.5±1.4
BONE FORMATION AREA (%)								
AREA	GE45GS	GE60GS	GE45GS+CS	GE60GS+CS	GV45	GV60	GC45	GC60
Remaining Cartilage	11.5±0.5a	13.5±0.5a	10.5±0.1a	13.0±0.1a	6.0±0.5	3.5±0.1	9.0±1.7	6.5±0.0
Trabecular Bone	13.5±0.2a	15.0±0.1a	10.5±0.1	14.5±0.3a	9.0±1.4	5.0±1.0	11.5±0.4	11.5±1.1
Bone Marrow	11.0±0.4a	8.0±0.6a	13.0±0.5a	9.0±0.6a	21.5±1.4	27.5±1.1	15.5±2.0	18.0±1.1
HYALURONAN QUANTIFICATION (O.D. units)								
CARTILAGE ZONE	GE45GS	GE60GS	GE45GS+CS	GE60GS+CS	GV45	GV60	GC45	GC60
Hypertrophic	36.4±1.9	41.8±1.1b	34.3±0.4	41.3±2.0b	33.0±2.3	31.20±1.9	41.0±1.1	38.8±0.8

Statistically significant values: a $p < 0.001$; b $p < 0.01$; c $p < 0.05$; µm - micrometers; %: percentage; O.D.: optical density.

able to absorb large amounts of water, thus increasing the osmotic pressure and expanding the lacunae. The hyaluronan content found in this region is directly proportional to the chondrocyte lacunae size, but its presence is not necessary to keep the lacunae expanded. This expansion during maturation of the growth plate is therefore essential for its longitudinal growth. Nilsson & Baron (25) showed that the histochemical hyaluronan localization is directly correlated with the chondrocyte total area and that GS treatment may stimulate hypertrophic chondrocytes to synthesize additional hyaluronan.

When GS and CS were administered as combination treatment for 60 days, female rats showed more effective maintenance and improvement of the proliferation of the epiphyseal growth plate as well as increased longitudinal bone growth. While our results were obtained in rat models, Provenza et al. (37), Sawitzke et al. (38) and Gregory et al. (39) have shown that the treatment of post menopausal women with GS and CS for more than 4 months can also be effective for improving articular function and reducing pain. Therefore, long-term administration of GS and CS in postmenopausal women with osteoarthritis caused by hypogonadism should be evaluated for its effects on bone maintenance.

ACKNOWLEDGMENTS

This study was supported by FAPESP (Fundação de Apoio à Pesquisa do Estado de São Paulo - 05/57914-8, scholarship).

REFERENCES

- Schrier L, Ferns SP, Barnes KM, Emons JAM, Newman EI, Nilsson O. Depletion of resting zone chondrocytes during growth plate senescence. *J Endocr.* 2006;189(1):27-36, <http://dx.doi.org/10.1677/joe.1.06489>.

- Chrysis D, Nilsson O, Ritzen EM, Savendahl M. Apoptosis is developmentally regulated in rat growth plate. *Endocrine.* 2002;18(3):271-8, <http://dx.doi.org/10.1385/ENDO:18:3:271>.
- Wuelling M, Vortkamp A. Chondrocyte proliferation and differentiation. *Endocr Dev.* 2011;21(3):1-11, <http://dx.doi.org/10.1159/000328081>.
- Mackie EJ, Tatarczuch L, Mirams M. 2. The skeleton: a multi-functional complex organ. The growth plate chondrocyte and endochondral ossification. *J Endocrinol.* 2011;211(2):109-21, <http://dx.doi.org/10.1530/JOE-11-0048>.
- Mackie EJ, Ahmed YA, Tatarczuch L, Chen KS, Mirams M. Endochondral ossification: how is converted into bone in the developing skeleton. *Int J Biochem Cell Biol.* 2008;40(1):46-62.
- Farnum CE, Wilsman NJ. Morphologic stages of the terminal hypertrophic chondrocyte of growth plate cartilage. *Anat Rec.* 1987;219(3):221-32, <http://dx.doi.org/10.1002/ar.1092190303>.
- Anderson HC. Matrix vesicles and calcification. *Curr Rheumatol Rep.* 2003;5(3):222-6, <http://dx.doi.org/10.1007/s11926-003-0071-z>.
- Garimella R, Bi X, Camacho N, Sipe J, Anderson HC. Primary culture of rat growth plate chondrocytes: an in vitro model growth plate histotype, matrix vesicle biogenesis and mineralization. *Bone.* 2004;34(6):961-70, <http://dx.doi.org/10.1016/j.bone.2004.02.010>.
- Roach HI, Mentha G, Oreffo ROC, Clarke NMP, Cooper C. Temporal analysis of rat growth plates: cessation of growth with age despite presence of a physis. *J Histochem Cytochem.* 2003;51(3):373-83, <http://dx.doi.org/10.1177/002215540305100312>.
- Felson DT. Osteoarthritis: New Insights Part 2, NIH Conference: Treatment Approaches. *Ann Intern Med.* 2000;133(9):726-36, <http://dx.doi.org/10.7326/0003-4819-133-9-200011070-00015>.
- Henrotin Y, Marty M, Mobasher A. What is the current status of chondroitin sulfate and glucosamine for the treatment of knee osteoarthritis? *Maturitas.* 2014;78(3):184-87, <http://dx.doi.org/10.1016/j.maturitas.2014.04.015>.
- Tivesten A, Moverare-Skrtec S, Chagin A, Veken K, Salmon P, et al. Additive protective effects of estrogen and androgen treatment on trabecular bone in ovariectomized rats. *J Bone Min Res.* 2004;19(11):1833-44, <http://dx.doi.org/10.1359/JBMR.040819>.
- Pernille HA, Tanko LB, Andersen TL, Lundberg CV, Mo JA, et al. Ovariectomized rats as a model of postmenopausal osteoarthritis: validation and application. *Arthritis Res Ther.* 2004;6(2):169-80.
- Hua J, Suguro S, Hirano S, Sakamoto K, Nagaoka I. Preventive actions of a high dose of glucosamine on adjuvant arthritis in rats. *Inflamm Res.* 2005;54(3):127-32, <http://dx.doi.org/10.1007/s00011-004-1333-6>.
- Hungerford DS, Jones LC. Glucosamine and Chondroitin Sulfate are effective in the management of osteoarthritis. *J Arthroplasty.* 2003;18(1):5-9, <http://dx.doi.org/10.1054/arth.2003.50067>.



16. Morelli V, Naquin C, Weaver V. Alternative therapies for traditional disease states: osteoarthritis. *Ame Fam Phys*. 2003;67(2):339-44.
17. Andersen ML, D'Almeida V, Ko GM, Kawakami R, Martins PJF, Magalhães LE, et al. Ethical principles and practical use of experimental animals. Dept Psychobiology, Federal University of São Paulo School of Medicine. 2009.
18. Allen E. The estrous cycle in the mouse. *Am J Anat*. 1992;30(3):297-348.
19. Kiernan JA. Histological and histochemical methods. Theory and practice. Arnold Editor. Third edition. 2001.
20. Pavasant P, Shirazi T, Underhill CB. Hyaluronan contributes to the enlargement of hypertrophic lacunae in the growth plate. *J Cell Sci*. 1996;109(Pt2):327-34.
21. Suzuki A, Tanimoto K, Ohno S, Nakatani Y, Honda K, et al. The metabolism of hyaluronan in cultured rabbit growth plate chondrocytes during differentiation. *Biochem Biophys Acta*. 2005;1743(1-2):57-63, <http://dx.doi.org/10.1016/j.bbamcr.2004.08.007>.
22. Lacerda CAM. Stereological tools in biomedical research. *An Acad Bras Cienc*. 2003;75(4):469-86.
23. Fowler J, Cohen L. Practical statistics for field biology. Open University Press, Buckingham, Inglaterra 1990.
24. Blitterswijk W, Van de Nes J, Wuisman P. Glucosamine and chondroitin sulfate supplementation to treat symptomatic disc degeneration: Biochemical rationale and case report. *BMC Complementary and alternative Medicine*. 2003;3(2):1-8.
25. Nilsson O, Baron J. Impact of growth plate senescence on catch-up growth and epiphyseal fusion Review. *Pediatr Nephrol*. 2005;20(3):319-22, <http://dx.doi.org/10.1007/s00467-004-1689-4>.
26. Lui JC, Nilsson O, Baron J. Growth Plate Senescence and Catch-Up Growth. *Endocr Dev*. Basel. 2011;21:23-9, <http://dx.doi.org/10.1159/000328117>.
27. Stevens DA, Williams GR. Hormonal regulation of chondrocyte differentiation and endochondral bone formation. *Mol Cell Endocrinol*. 1999;151(1-2):195-204, [http://dx.doi.org/10.1016/S0303-7207\(99\)00037-4](http://dx.doi.org/10.1016/S0303-7207(99)00037-4).
28. Nilsson O, Marino R, De Luca F, Phillip M, Baron J. Endocrine Regulation of the Growth Plate. *Horm Res*. 2005;64(4):157-65, <http://dx.doi.org/10.1159/000088791>.
29. Provot S, Schipani E. Molecular mechanisms of endochondral bone development. *Bioch Bioph Res Com*. 2008;328(3):658-65.
30. Irie T, Aizawa T, Kokubun S. The role of sex hormones in the kinetics of chondrocytes in the growth plate. A study in the rabbit. *J Bone Joint Sur*. 2005;87(9):1278-84.
31. Wolff RB, Gomes RC, Verna C, Maioral GC, Rampazo TC, et al. Molecular features of sexual steroids on cartilage and bone. *Rev Assoc med Bras*. 2012;58(4):493-7, <http://dx.doi.org/10.1590/S0104-42302012000400023>.
32. Frenkel B, Hong A, Banival SK, Coetzee GA, Ohlsson C, Khalid O. Regulation of adult bone turnover by sex steroids. *J Cel Physiol*. 2010;224(2):305-310, <http://dx.doi.org/10.1002/jcp.22159>.
33. Karimian E, Sävendahl L. Estrogen signaling in growth plate cartilage. *Endocr Dev*. 2011;21:42-51, <http://dx.doi.org/10.1159/000328126>.
34. Van der Eerden BCJ, Karperien M, Wit JM. Systemic and local regulation of the growth plate. *Endocr Rev*. 2003;24(6):782-801, <http://dx.doi.org/10.1210/er.2002-0033>.
35. Bruyere O, Pavelka K, Rovati LC, Deroisy R, Olejarova M, et al. Glucosamine sulfate reduces osteoarthritis progression in postmenopausal women with knee osteoarthritis: evidence from two 3-year studies. *Menopause*. 2004;11(2):134-5.
36. Van der Eerden BCJ, Van de Ven J, Lowik CWGM, Wit JM, Karperien M. Sex steroid metabolism in the tibial growth plate of the rat. *Endocrinology*. 2002;143(10):4048-55, <http://dx.doi.org/10.1210/en.2002-220093>.
37. Provenza JR, Shinjo SK, Silva JM, Peron CR, Rocha FA. Combined glucosamine and chondroitin sulfate, once or three times daily, provides clinically relevant analgesia in knee osteoarthritis. *Clin Rheumatol*. 2014 Aug 3. [Epub ahead of print].
38. Sawitzke AD, Shi H, Finco MF, Dunlop DD, Harris CL, et al. Clinical efficacy and safety of glucosamine, chondroitin sulphate, their combination, celecoxib or placebo taken to treat osteoarthritis of the knee: 2-year results from GAIT. *Ann Rheum Dis*. 2010;69(8):1459-64, <http://dx.doi.org/10.1136/ard.2009.120469>.
39. Gregory PJ, Sperry M, Friedman A. Dietary supplements for osteoarthritis. *Am Fam Physician*. 2008;77(2):177-84.