



Single scrotal incision orchiopexy - a systematic review

Hugo Fabiano Fernandes Novaes, José Abraão Carneiro Neto, Antonio Macedo Jr, Ubirajara Barroso Júnior

Section of Pediatric Urology, Division of Urology Bahiana School of Medicine and Federal University of Bahia and Federal University of São Paulo

ABSTRACT

Objective: To conduct a systematic review on single scrotal incision orchiopexy.

Materials and Methods: A search was performed using Pubmed, through which 16 articles were selected out of a total of 133. The following conditions were considered exclusion criteria: other surgical methods such as an inguinal procedure or a laparoscopic approach, retractile testes, or patients with previous testicular or inguinal surgery.

Results: A total of 1558 orchiopexy surgeries initiated with a transcrotal incision were analyzed. Patients' ages ranged between 5 months and 21 years. Thirteen studies used high scrotal incisions, and low scrotal incisions were performed in the remainder of the studies. In 55 cases (3.53%), there was a need for inguinal incision. Recurrence was observed in 9 cases, testicular atrophy in 3, testicular hypotrophy in 2, and surgical site infections in 13 cases. High efficacy rates were observed, varying between 88% and 100%.

Conclusions: Single scrotal incision orchiopexy proved to be an effective technique and is associated with low rates of complications.

ARTICLE INFO

Key words:

Cryptorchidism; Orchiopexy; Scrotum; Surgical Procedures, Operative

Int Braz J Urol. 2013; 39: 305-11

Submitted for publication:
December 18, 2012

Accepted after revision:
May 27, 2013

INTRODUCTION

Cryptorchidism is the most common pathology during childhood (1), affecting 2-4% of children at birth and decreasing to 1% in the first year of life (2,3). The majority of cryptorchidic testes are in the superficial inguinal pouch of Denis Browne, making inguinal exploration the traditional surgical correction procedure (4).

The inguinal procedure requires two incisions: one in the groin to release the testicle, and another scrotal incision to make a pocket to accommodate the testicle. In order to reduce the potential morbidity of this treatment, in 1989 Bianchi and Squire introduced a technique utilizing a single scrotal incision (5). It is suggested that this technique adds the advantages of a single incision, shorter operation time, ease

of dissection, accelerated healing, less pain, good maintenance of testicular position and an excellent cosmetic result (6).

Despite the good results of transcrotal orchiopexy found in the literature, its use is not widespread. The objective of this study is to perform a systematic review on the subject.

MATERIALS AND METHODS

Our Experience

We retrospectively evaluated 18 patients (22 testes) who underwent scrotal orchiopexy between August 2007 and August 2009. We reviewed the charts concerning laterality of the surgery, age of the patients, inguinal conduit persistence and whether the patients had undergone a previous surgery for undescended testis.

All patients were examined under anesthesia and the decision of whether or not to perform a transcrotal approach was based on the ability to push the testis to the level of external inguinal ring. The incision was horizontal at the lowest part of the hemiscrotum for unilateral cases (Figures 1a and 1b), and longitudinal at the scrotal raphe for bilateral undescended testes (Figure-2).

In the technique of scrotal orchiopexy we first manipulate the testis down toward the external inguinal ring. The testis is grasped with the thumb and the index finger. With the surgeon keeping traction on the testis the scrotal incision is performed and the testis and spermatic chord are freed from the cremasteric fascia (Figure-1a). When present, the inguinal conduit persistence is closed. Because the inguinal canal is short in children, the conduit can be closed at the level of the internal inguinal ring. The dissection of the inguinal conduit elongates enough the spermatic chord, making it possible for the testes to reach the scrotum easily. The testes are fixated in the scrotum by means of a Dartos pouch. The patients are discharged the same day of the surgery.

The patients were followed up regularly. They were directed to return to the office one week, one month and six months after surgery and then on a yearly basis.

Systematic review

A systematic review was performed through an electronic search on the Pubmed database using the following key words and combinations thereof: scrotal incision, cryptorchidism, orchiopexy and undescended testis. The search yielded 133 articles. Prospective and retrospective articles were selected which evaluated children with primary cryptorchidism who were treated surgically through single scrotal incision orchiopexy. Articles were excluded if they: evaluated secondary cryptorchidism from previous procedures or any other pathology; evaluated patients who underwent orchiopexy via another procedure (inguinal or laparoscopic). The effectiveness of the technique was evaluated, defined as the presence of the testis in the scrotum after the procedure, without subsequent hypotrophy or atrophy, and without the need for an inguinal incision.

Figure 1a - The testis mobilized and delivered through the incision.

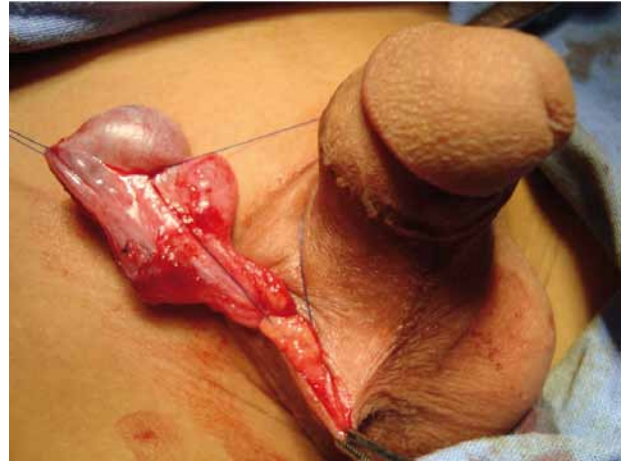


Figure 1b - Final appearance for unilateral undescended testis.

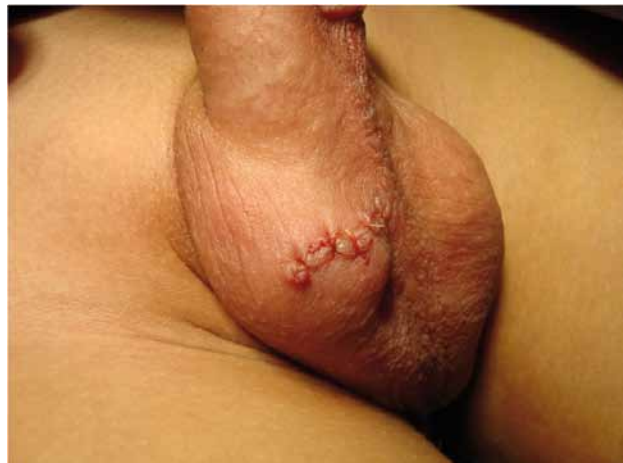
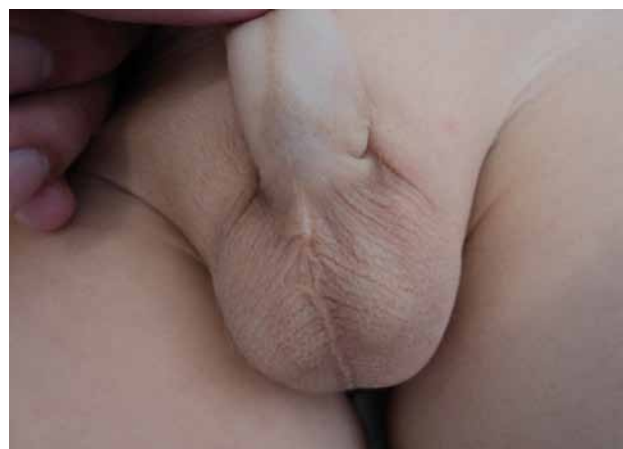
Figure 2 - Final appearance for bilateral undescended testes.



After evaluating the abstracts, 88 articles were excluded that dealt with other issues, 23 that used laparoscopy as a means of access, and 4 which were review articles; 18 articles remained to be reviewed. After verifying the references of the selected articles, we included two articles (7,8), giving a total of 20 articles. After analyzing the full articles, one study was excluded which studied the same group of patients as another study published later (9), one article which evaluated the technique in patients with retractile and reoperated testicles (10), another which only evaluated patients with secondary or relapsed cryptorchidism and another article which did not evaluate the surgical results of the orchiopexy separately from other inguinal procedures (8). In the end, 16 articles were selected for review. The present study was completed in March 2011.

RESULTS

Our results

Eighteen patients (22 testes) underwent scrotal orchiopexy. The surgery could be performed via scrotal approach in all cases and the testes could be brought down to the scrotum with no tension. No inguinal incision was necessary.

Persistence of inguinal conduit was found in 16 (72%) cases. In all, the conduit could be closed at the level of inguinal internal ring. There were no intraoperative or postoperative complications.

Two patients had unsuccessfully undergone previous inguinal surgery for undescended testis. The testes remained in the superficial inguinal pouch of Denis Browne and could be approached via scrotal approach with no complication.

In a mean follow up of 18 months (ranging from 3 to 37 months), no complication such as infection, testicular atrophy, hydrocele or hernia was observed.

Systematic review

Results are shown in Table-1. A total of 1558 orchiopexy surgeries initiated with a transscrotal incision were analyzed. The patients were examined in standing positions and un-

der anesthesia, excluding cases of retractile testis. The age range varied between 5 months and 21 years. All patients studied underwent single scrotal incision orchiopexy; 13 studies used high scrotal incisions, and low scrotal incisions were performed in the remainder. Eleven studies recorded the incidence of patent processus vaginalis, which was present in 324 of the 1090 cases evaluated (29.7%).

In 55 cases (3.53%) an inguinal incision was necessary. These patients had high testes (1,2,11-14) requiring retroperitoneal dissection (4,13,15) or the presence of the vaginal process or hernia (1,11,16).

Only one case presented intraoperative complications (injury to the vas deferens). Study 3 did not evaluate intraoperative complications. In one article, the authors reported no intraoperative or postoperative complications and 100% efficacy. In this study, the follow-up was only 3 months (17).

The post-operative follow-up was heterogeneous, ranging from 3 months to 5 years, with a lack of follow-up in some studies. Recurrence was observed in 9 cases (2-4,16,18), testicular atrophy in 3 (2,16), testicular hypotrophy in 2 patients (11) and surgical site infections in 13 (2,11,12,16,19-21). Hematomas occurred in 22 cases (2,3,12,15,16); in Study 2 alone 16 cases of hematoma were observed (15.09% of the patients in the study). Study 2 also showed the highest rates of testicular atrophy (2 cases) and recurrence (5 cases), out of a total of 106 orchiopexies.

Given the concept of efficacy that was pre-established (the post-operative result after single scrotal incision orchiopexy, with no subsequent atrophy, hypotrophy or any other complication that may result in orchiectomy), rates of success were found to be between 88 and 100%, as shown in Table-1.

DISCUSSION

Orchiopexy is a necessary procedure for the treatment of a common problem in the pediatric population. It is traditionally performed through an inguinal procedure, with a second incision made in the scrotum to set the testicle.

Table 1 - Review of the published literature about transscrotal orchidopexy.

Authors	Year	Design	No. of patients	No. of Orchiopexies	Incision	Patent Processus Vaginalis	Inguinal incision	Age	Intraoperative complications	Postoperative complications	Follow-up	Efficacy (%)	Reference
Lais A et al	1996	Prospective	50	50	High scrotal	13	3	5 months to 14 years (mean 5 years)	0	Hematoma: 3; Recurrence: 1; Hipotrophy: 2	3 to 5 years	88	15
Misra D et al	1997	Prospective	NE	67	High scrotal	0	9	1 to 12 years (mean: 6.8 years)	0	0	1 to 5 years	86.5	14
Jawad AJ	1997	Prospective	96	106	High scrotal	NE	14	14 months to 11 years (mean: 41 months)	0	Recurrence: 5; Atrophy: 2; Hematoma: 16; Infection: 2	8 to 36 months (mean: 16 months)	93.3	2
Caruso A et al	2000	Prospective	34	42	High scrotal	3	1	media: 03 years (mean: 14 months)	0	Recurrence: 1	6 months to 2 years (mean: 1 year)	96.6	4
Parsons JK et al	2003	Prospective	52	66	Low scrotal	13	0	Below 2 years-old: 16 patients; 2 to 6 years: 19 patients; 6 years: 17 patients	0	0	3 months	100	17
Russinko PJ et al	2003	Retrospective	78	85	High scrotal	58	1	4.5 years (0.5 a 24 years)	0	Recurrence: 2; Hematoma: 1; Atrophy: 1; Infection: 1	1 to 36 months (mean: 6 months)	95.2	16
Handa R et al	2006	Prospective	28	35	High scrotal	NE	0	10 months to 9 years	0	Infection: 1; Hernia: 1	2 to 6 months	100	19
Dayanc M et al	2007	Prospective	166	204	High scrotal	72	12	10 months to 12 years (mean 2.2 years; median 3.2 years)	NE	Hydrocele: 1; Hernia: 01;	16 to 68 months	92.7	1

Bassel YS et al	2007	Retrospective	103	121	High scrotal	75	0	6 months a 13 years (mean: 4.5 years)	0	0	Infection: 4	6 months to 1 year	100	21
Samuel DG et al	2008	Prospective	156	206	High scrotal	NE	1	1 a 21 years (mean: 4.26 years)	0	0	Infection: 2	2 years	99.95	11
Takahashi M et al	2009	Prospective	32	49	Low scrotal	14	0	11.5 a 114.0 months (mean: 39.3 months)	0	0	Recurrence: 1	12.1 to 68.8 months (mean: 39.1 months)	97.95%	18
Al-Mandil M et al	2008	Retrospective	56	63	Low scrotal	NE	0	4.6 years	0	0	Recurrence: 1; Hydrocele: 1; Hernias: 2; Infection: 1	6 to 42 months	98.41	20
Callewaert PR et al	2009	Prospective	154	194	High scrotal	11	2	4 a 229 months (mean: 71 months)	0	0	Hematoma: 1; Infection: 2	3 to 22 months (mean: 10 months)	100	12
Gordon M et al	2010	Retrospective	118	122	Low scrotal	NE	3	10 months to 8 years	0	0	Recurrence: 12	6 months to 1 year	89.3	6
Cloutier J et al	2011	Retrospective	44	60	High scrotal	NE	1	53 (± 23) months	0	0	Recurrence: 1; Hematoma: 1	3 months to 2 years	99.3	3
Yucel S et al	2011	Retrospective	74	88	High scrotal	65	8	6 months to 11 years (mean: 4.9 years)	0	0	0	3 to 12 months (mean: 7.1 months)	90.9	13
Authors	2007 - 2009	Prospective	16 (more 2 patients was re-do)	20 (more 2 cases was re-do)	Low scrotal	16	0	3 to 108 months (mean 42.5 months)	0	0	0	3 to 17 months (mean: 18 months)	100	-

NE: not evaluated

After introduction of the single incision transcrotal technique by Bianchi and Squire in 1989, it became possible to treat these patients with high rates of effectiveness and lower postoperative morbidity.

After analyzing the selected articles, a high level of efficacy was observed in scrotal surgery, which was able to be performed in 85% of cases. Unfortunately, the location of the testis and the criteria for surgery are not well established in the studies, making it difficult to compare them in terms of efficacy.

The rate of relapse was small (1.43%), as was the rate of testicular atrophy/hypotrophy (0.3%). However, the follow-up times presented in the studies are short and many do not provide follow-ups. In 1995, Docimo et al. (22) conducted a systematic review, analyzing 8425 inguinal orchiopexies. Among these studies, the position of the testicles was identified in only 2491 of them. It was observed that the success rate of the surgery after 6 months of follow-up was 83.9% for the cases of intracanalicular testes and 92.3% for the cases with testes in the external inguinal ring. When the authors analyzed the literature that has been published since 1985, the success rates rose to 95.7% with intracanalicular testes and 100% with the testes located below the external inguinal ring. Finally, when analyzing a subgroup of patients who only underwent the inguinal procedure (1556 orchiopexies), the rate of success after 6 months was 86.4%. When analyzing the data after 1985 (677 orchiopexies), the success rate was 85.2%.

The incidence of patent processus vaginalis varied among the studies. In cryptorchidism, the processus vaginalis was patent in 20 to 73% of cases (13,17), and was lower in cases of retractile testes. Therefore, we can infer that the surgery was indicated for many gliding testis. The lack of surgical reports regarding the presence of this finding may interfere with the result.

The fact that only four hernias occurred postoperatively may reflect the lack of follow-up, but may also reflect the effectiveness of treating patent processus vaginalis through the scrotum. In children, the inguinal portion of the processus vaginalis is short (median 1 cm in children under 2 years and median 1.1 cm in children over 4 years) (23) and by using traction, it is possible to perform

the tubal ligation at practically the same level as the internal inguinal ring.

Only 11 articles report the location of the testis; in 8 of the studies the authors indicated scrotal orchiopexy for all the cases and in 8 studies the surgery was only indicated when it was possible to bring the testicles to the scrotum with the patient anesthetized (1,3,11,14,16,18,19,21). In 5 studies the rate of success was higher than 95% and two reported 100% of success. In our experience using this method, we were able to adequately position the testicles in the scrotum in all cases. In our department, low scrotal incision orchiopexy is indicated for cases where traction and relocation of the testis to the upper third of the scrotum is possible with the patient anesthetized. We have operated on 22 consecutive orchiopexies through low scrotal incisions (data not published) and found persistent processus vaginalis in 16 cases (72%). In all cases, it was possible to dissect and correct the patency of the processus vaginalis through the same incision. After a mean follow-up of 18 months, we did not find a single recurrence or any complication such as surgical site infection, hematomas, or atrophy.

This systematic review demonstrates the poor methodological quality of the articles which are available for the comparison of data. There was a significant lack of follow-up, some studies are retrospective, there is no randomization, and a great heterogeneity of techniques was used (high and low incisions); there was also a heterogeneity of cases selected (there are cases in which impalpable testes were treated by single scrotal incision). Given this heterogeneity, it is impossible to conduct a meta-analysis of the success rate.

Based on the evidence presented in the literature, we believe that in the cases in which the testicles are found in a low position, making it possible to move them to the scrotum, scrotal orchiopexy is the procedure of choice. However, for those testicles that are located in a higher position, comparative studies with inguinal orchiopexy should be performed.

CONCLUSIONS

Single scrotal incision orchiopexy is an effective technique associated with low complica-

tion rates. We believe that this technique is preferable in cases where the testicles are displaced up to the level of the external inguinal ring, even in reoperations and cases of previous inguinal surgery. Randomized, prospective, and multicenter studies are necessary to obtain better scientific evidence, specially for those testicles that are located in a higher position.

CONFLICT OF INTEREST

None declared.

REFERENCES

- Dayanc M, Kibar Y, Irkilata HC, Demir E, Tahmaz L, Peker AF: Long-term outcome of scrotal incision orchiopexy for undescended testis. *Urology*. 2007; 70: 786-8; discussion 788-9.
- Jawad AJ: High scrotal orchidopexy for palpable maldescended testes. *Br J Urol*. 1997; 80: 331-3.
- Cloutier J, Moore K, Nadeau G, Bolduc S: Modified scrotal (Bianchi) mid raphe single incision orchiopexy for low palpable undescended testis: early outcomes. *J Urol*. 2011; 185: 1088-92.
- Caruso AP, Walsh RA, Wolach JW, Koyle MA: Single scrotal incision orchiopexy for the palpable undescended testicle. *J Urol*. 2000; 164: 156-8; discussion 158-9.
- Bianchi A, Squire BR. Transcrotal orchidopexy : orchidopexy revised. *Pediatric Surgery International*. 1989; 4: 189-92.
- Gordon M, Cervellione RM, Morabito A, Bianchi A: 20 years of transcrotal orchidopexy for undescended testis: results and outcomes. *J Pediatr Urol*. 2010; 6: 506-12.
- Karaman I, Karaman A, Erdoğan D, Çavuşoğlu YH: The transcrotal approach for recurrent and iatrogenic undescended testes. *Eur J Pediatr Surg*. 2010;20: 267-9. Erratum in: *Eur J Pediatr Surg*. 2010; 20: e2. Cavuşoğlu, Y H [corrected to Çavuşoğlu, Y H].
- Gökçora IH, Yagmurlu A: A longitudinal follow-up using the high trans-scrotal approach for inguinal and scrotal abnormalities in boys. *Hernia*. 2003; 7: 181-4.
- Dayanç M, Kibar Y, Tahmaz L, Yildirim I, Peker AF: Scrotal incision orchiopexy for undescended testis. *Urology*. 2004; 64: 1216-8; discussion 1219.
- Rajimwale A, Brant WO, Koyle MA: High scrotal (Bianchi) single-incision orchidopexy: a "tailored" approach to the palpable undescended testis. *Pediatr Surg Int*. 2004; 20: 618-22.
- Samuel DG, Izzidien AY: Bianchi high scrotal approach revisited. *Pediatr Surg Int*. 2008; 24: 741-4.
- Callewaert PR, Rahnama'i MS, Biallostowski BT, van Kerrebroeck PE: Scrotal approach to both palpable and impalpable undescended testes: should it become our first choice? *Urology*. 2010; 76: 73-6.
- Yucel S, Celik O, Kol A, Baykara M, Guntekin E: Initial pre-scrotal approach for palpable cryptorchid testis: results during a 3-year period. *J Urol*. 2011; 185: 669-72.
- Misra D, Dias R, Kapila L: Scrotal fixation: a different surgical approach in the management of the low undescended testes. *Urology*. 1997; 49: 762-5.
- Lais A, Ferro F: Trans-scrotal approach for surgical correction of cryptorchidism and congenital anomalies of the processus vaginalis. *Eur Urol*. 1996; 29: 235-8; discussion 238-9.
- Russinko PJ, Siddiq FM, Tackett LD, Caldamone AA: Prescrotal orchiopexy: an alternative surgical approach for the palpable undescended testis. *J Urol*. 2003; 170: 2436-8.
- Parsons JK, Ferrer F, Docimo SG: The low scrotal approach to the ectopic or ascended testicle: prevalence of a patent processus vaginalis. *J Urol*. 2003; 169: 1832-3; discussion 1833.
- Takahashi M, Kurokawa Y, Nakanishi R, Koizumi T, Yamaguchi K, Taue R, et al.: Low transscrotal orchidopexy is a safe and effective approach for undescended testes distal to the external inguinal ring. *Urol Int*. 2009; 82: 92-6.
- Handa R, Kale R, Harjai M, Minocha A: Single scrotal incision orchiopexy for palpable undescended testis. *Asian J Surg*. 2006; 29: 25-7.
- Al-Mandil M, Khoury AE, El-Hout Y, Kogon M, Dave S, Farhat WA: Potential complications with the prescrotal approach for the palpable undescended testis? comparison of single prescrotalincision to the traditional inguinal approach. *J Urol*. 2008; 180: 686-9.
- Bassel YS, Scherz HC, Kirsch AJ: Scrotal incision orchiopexy for undescended testes with or without a patent processus vaginalis. *J Urol*. 2007; 177: 1516-8.
- Docimo SG: The results of surgical therapy for cryptorchidism: a literature review and analysis. *J Urol*. 1995; 154: 1148-52.
- Parnis SJ, Roberts JP, Hutson JM: Anatomical landmarks of the inguinal canal in prepubescent children. *Aust N Z J Surg*. 1997; 67: 335-7.

Correspondence address:

Dr. Ubirajara Barroso Jr.
Rua Sócrates Guanaes Gomes, 73 / 2004
Cidade Jardim
Salvador, Bahia, 40296-720, Brazil
E-mail: ubarroso@uol.com.br