

- 4 Scott I, Flynn H, Feuer W, Pflugfelder S, Alfonso E, Forster R *et al.* Endophthalmitis associated with microbial keratitis. *Ophthalmology* 1996; **103**: 1864–1870.
- 5 Chen PP, Gedde SJ, Budenz DL, Parrish RK. Outpatient treatment of bleb infection. *Arch Ophthalmol* 1997; **115**: 1124–1128.
- 6 Waheed S, Ritterband DC, Greenfield DS, Liebmann JM, Seedor JA, Ritch R. New patterns of infecting organisms in late bleb-related endophthalmitis: a ten year review. *Eye* 1998; **12**: 910–915.
- 7 Wallin O. Comparison of different implants for deep sclerectomy. *Acta Ophthalmologica Scandinavia* 2004; **82**: 345 (XXXVI Nordic Congress of Ophthalmology, Abstracts. Poster available by e-mail to [orjan.wallin@sankterik.se](mailto:orjan.wallin@sankterik.se)).
- 8 Krukowski ZH, Cusick EL, Engeset J, Matheson NA. Polydioxanone or polypropylene for closure of midline abdominal incisions: a prospective comparative clinical trial. *Br J Surg* 1987; **74**: 828–830.
- 9 Paterson-Brown S, Cheslyn-Curtis S, Biglin J, Dye J, Easmon CS, Dudley HA *et al.* Suture materials in contaminated wounds: a detailed comparison of a new suture with those currently in use. *Br J Surg* 1987; **74**: 734–735.

OJ Wallin and PG Montan

Department of Anterior Segment Surgery, St Erik Eye Hospital, Polhemsgatan 50, SE-11282, Stockholm, Sweden

Correspondence: O Wallin, St Erik Eye Hospital, Polhemsgatan 50, SE-112 82 Stockholm, Sweden  
Tel: +46 8672 3000;  
Fax: +46 8651 0785.  
E-mail: [orjan.wallin@sankterik.se](mailto:orjan.wallin@sankterik.se)

*Eye* (2007) **21**, 258–260. doi:10.1038/sj.eye.6702494; published online 23 June 2006

---

Sir,  
**Regarding Newton's laws (Editorial, *Eye*, May 2006)**

I read the Editorial about pathways for macular disease with interest.<sup>1</sup> Can I correct one point?

The misquoted law should have read Newton's Third Law of Motion. No thermodynamic laws are attributed to him. For completeness, Newton's Laws of Motion and the Laws of Thermodynamics are as follows:

Newton's First Law: An object at rest tends to stay at rest and an object in uniform motion tends to stay in uniform motion unless acted upon by a net external force.

Newton's Second Law: An applied force equals the rate of change of momentum.

Newton's Third Law: For every action there is an equal and opposite reaction.

Zeroth Law of Thermodynamics: If A and B are in thermal equilibrium, and B and C are also in thermal equilibrium, then A and C are in thermal equilibrium.

First Law of Thermodynamics: The increase in the energy of a closed system is equal to the amount of energy added to the system by heating, minus the amount lost in the form of work done by the system on its surroundings.

Second Law of Thermodynamics: The total entropy of any isolated thermodynamic system tends to increase over time, approaching a maximum value.

Third Law of Thermodynamics: As a system approaches absolute zero of temperature, all processes cease and the entropy of the system approaches a minimum value or zero for the case of a perfect crystalline substance.

## Reference

- 1 Ellis J, Cole A, Roxburgh STD. Patient pathways for macular disease: what will the new optometrist with special interest achieve? *Eye* 2006; **20**: 521–522.

N Davies

Department of Ophthalmology, Chelsea & Westminster Hospital, 369 Fulham Road, London SW10 9NH, UK

Correspondence: N Davies,  
Tel: +44 02087 468345;  
Fax: +44 02082 375040.  
E-mail: [nigel@npdavies.wanadoo.co.uk](mailto:nigel@npdavies.wanadoo.co.uk)

*Eye* (2007) **21**, 260. doi:10.1038/sj.eye.6702497; published online 23 June 2006

---

Sir,  
**Xanthogranuloma of the lacrimal sac as a manifestation of Wegener's granulomatosis**

Wegener's granulomatosis (WG) is a multisystemic disease that affects small vessels. The necrotizing granulomatous inflammation commonly involves the upper airways, lung, and kidney, although any organ can be affected.<sup>1</sup> Xanthogranuloma formation is a rare manifestation of the disease.<sup>1</sup>

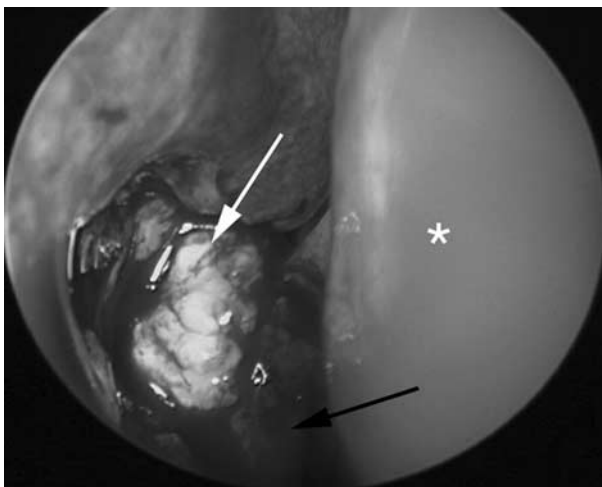Ocular manifestations occurs in approximately 30–50% of cases.<sup>2</sup> The lacrimal drainage system is usually affected by direct spread of the inflammatory process from the upper airways.<sup>3</sup> Focal vasculitis of the lacrimal

sac wall is extremely rare in WG. Ghanem *et al.*,<sup>3</sup> described the first case in 2004.

### Case report

A 21-year-old man presented with acute right dacryocystitis. He was successfully treated with intravenous antibiotics for a week, and then oral antibiotics for another 2 weeks. Incision and drainage of the localized abscess was also performed. However, the patient persisted with epiphora in the affected side. A firm, nontender swelling of the right lacrimal sac could be palpated. Lacrimal probing and irrigation demonstrated right lower lacrimal obstruction. The patient was being treated for WG with methotrexate and oral prednisolone since the previous year.

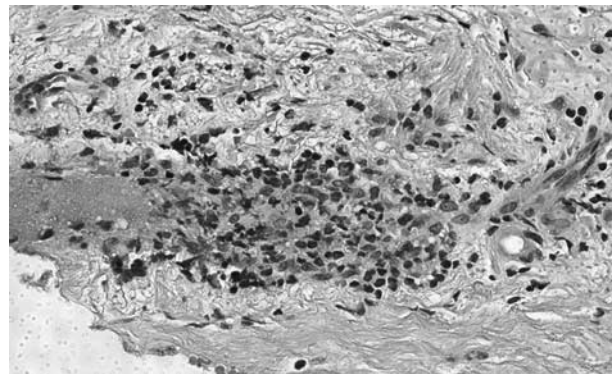
Dacryocystorhinostomy has been an effective therapy for lacrimal duct obstruction in patients with WG.<sup>4</sup> In this patient, endonasal dacryocystorhinostomy was performed. During the procedure, a yellowish mass could be seen at the lacrimal sac wall (Figure 1). The lesion was excised and sent for histopathological evaluation. The rest of the surgery was uneventful. In addition to the small cell vasculitis (Figure 2), a proliferation of xanthomized histiocytes (Figures 3 and 4) could be seen. Touton or Langerhans multinucleated giant cells were not observed. Special stains for microorganisms failed to reveal any infectious aetiology. The histiocytes did not stain for PAS, thus excluding Whipple's disease. Given the history of WG and no other finding that could suggest a different cause for the xanthogranuloma, the relationship was established. At follow-up, the lacrimal drainage system is patent 8 months after the procedure.



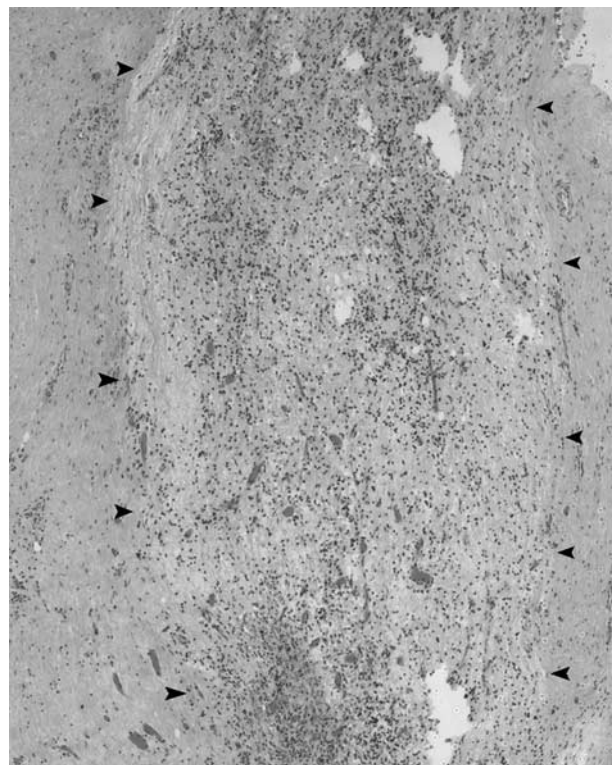
**Figure 1** Endonasal dacryocystorhinostomy. A yellowish mass is seen in the lacrimal sac wall (white arrow). Nasal septum (white asterisk) and middle turbinate (black arrow).

### Comment

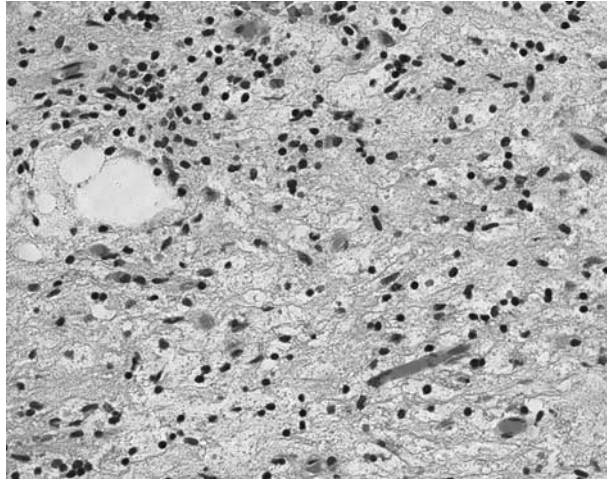
The xanthomatous transformation in WG is considered to be a focal accumulation of lipid-rich histiocytes secondary to the necrotizing vasculitis, and corresponds to the xanthoma of the skin, described by Frances *et al.*<sup>1</sup> To the best of our knowledge, a xanthogranuloma of the



**Figure 2** Photomicrography. Chronic inflammatory infiltrate destroying the wall of a small vessel of the lacrimal sac (H&E, original magnification,  $\times 400$ ).



**Figure 3** Photomicrography. A well-delimited aggregate of xanthomized histiocytes (arrowheads) is seen at the lacrimal sac wall. Immunohistochemistry was positive for CD68 (H&E, original magnification,  $\times 200$ ).



**Figure 4** Photomicrography. Higher magnification of the same area showed in Figure 3. The xanthomized histiocytes appear pale with small nuclei and vacuolated cytoplasm (H&E, original magnification,  $\times 400$ ).

lacrimal sac as a manifestation of WG has never been described before.

#### References

- 1 Frances C, Du LT, Piette JC, Saada V, Boisnic S, Wechsler B *et al.* Wegener's granulomatosis. Dermatological manifestations in 75 cases with clinicopathologic correlation. *Arch Dermatol* 1994; **130**(7): 861–867.
- 2 Bullen CL, Liesegang TJ, McDonald TJ, DeRemee RA. Ocular complications of Wegener's granulomatosis. *Ophthalmology* 1983; **90**(3): 279–290.
- 3 Ghanem RC, Chang N, Aoki L, Santo RM, Matayoshi S. Vasculitis of the lacrimal sac wall in Wegener granulomatosis. *Ophthal Plast Reconstr Surg* 2004; **20**(3): 254–257.
- 4 Hardwig PW, Bartley GB, Garrity JA. Surgical management of nasolacrimal duct obstruction in patients with Wegener's granulomatosis. *Ophthalmology* 1992; **99**(1): 133–139.

BF Fernandes<sup>1,2</sup>, A Al-Kandari<sup>1</sup>, A Al-Mujaini<sup>3</sup>, F Codère<sup>3</sup> and MN Burnier Jr<sup>1,2</sup>

<sup>1</sup>Department of Ophthalmology and Pathology, The McGill University Health Center & Henry C Witelson Ocular Pathology Laboratory, Montreal, Quebec, Canada

<sup>2</sup>Department of Ophthalmology, Federal University of Sao Paulo—UNIFESP/EPM, São Paulo, Brazil

<sup>3</sup>Department of Ophthalmology, McGill University Health Center, Montreal, Quebec, Canada

Correspondence: BF Fernandes,  
Department of Ophthalmology and Pathology,  
The McGill University Health Center & Henry C  
Witelson Ocular Pathology Laboratory,  
3775 University Street,  
Room 216,  
Montreal, Quebec,  
Canada H3A-2B4  
Tel: +1 514 392 7192 ext. 00384;  
Fax: +1 514 398 5728.  
E-mail: brunonet@centroin.com.br

The authors have no financial conflict of interest regarding this manuscript

*Eye* (2007) **21**, 260–262. doi:10.1038/sj.eye.6702500;  
published online 23 June 2006

Sir,

#### Management of paecilomyces keratitis

Paecilomyces is a rare cause of fungal keratitis, presenting a significant challenge for diagnosis and successful treatment.

#### Case report

A 44-year-old immunocompetent female school teacher was referred by another ophthalmologist for the management of left keratitis. She first presented 4 months previously, with symptoms of irritation, photophobia, and reduced vision. Treatment with topical steroids and pupil dilation was unsuccessful. No history of known trauma, contact-lens wearing, or herpes simplex keratitis was evident.

On examination, visual acuity in her right eye was 6/5 and in her left eye 6/240, pinholing to 6/120. The left cornea (Figure 1) demonstrated a  $2 \times 2$  mm central corneal posterior plaque with a clear anterior stroma and no epithelial defect. There was an associated 1 mm hypopyon. The B scan of her vitreous showed no vitreous cells. Owing to the posterior position of the infiltrate, no anterior scraping was performed. A clinical decision was made to undertake an excisional biopsy to remove the infected tissue. The patient was commenced on oral itraconazole 100 mg b.d. as well as topical dexamethasone 0.1% q.i.d. in preparation to minimize inflammation before surgery. A left penetrating keratoplasty was performed with a 9 mm trephination of the host centred around the infiltrate with insertion of a 10 mm diameter corneal graft. Histopathology reported septate hyphae extension through Descemet's