

## CASE REPORT

# Peripheral arterial emboli due to bullet projectile: diagnosis confirmed by vascular ultrasound

## *Embolia arterial periférica por projétil de arma de fogo em civis: diagnóstico confirmado pelo ultrassom vascular*

Domingos de Moraes Filho<sup>1</sup>, Gustavo Teixeira Fulton Schimit<sup>2</sup>, Guilon Otávio Santos Tenório<sup>2</sup>, Wander Eduardo Sardinha<sup>3</sup>, José Manuel Silva Silvestre<sup>3</sup>, Eduardo Durante Ramires<sup>3</sup>

### Abstract

We describe a case of acute arterial occlusion caused by a firearm bullet. Since the case is rare (23 cases in 20 years), and due to the importance of early diagnosis, a bibliographic review was performed. Aspects of the clinical picture, differential diagnosis and treatment were approached. In this case, diagnosis by a vascular ultrasound was published for the first time.

**Keywords:** ultrasonography, Doppler; wounds and injuries; ischemia.

### Resumo

Descrevemos um caso de oclusão arterial aguda por projétil de arma de fogo. Devido à raridade do caso (23 relatos em 20 anos) e a importância do diagnóstico diferencial precoce, uma revisão bibliográfica foi realizada. Foram abordados aspectos do quadro clínico, diagnóstico diferencial e tratamento. Neste caso, o diagnóstico por meio de ultrassom vascular da complicação foi publicado pela primeira vez.

**Palavras-chave:** ultrassonografia Doppler; ferimentos e lesões; isquemia.

### Introduction

Peripheral arterial embolism caused by firearm bullets (cardio arterial or arterio-arterial) is very rare<sup>1</sup>. To become an embolus, the bullet must penetrate the vessel lumen or the heart with only enough energy to cross one of the walls into the vessel, atrium or ventricle. For peripheral arterial embolism to occur, it should be transported in the blood stream from the entrance wound into the pulmonary circulation or from the left side of the heart or the aorta until the arterial point of occlusion<sup>2-21</sup>. Despite the existence of some cases in the literature of arterial and venous embolism due to trauma, cases in which the bullet becomes the arterial embolus itself are rare. We present

such a case and a review of other similar situations that have been published since 1990 (Table 1).

### Case report

A 16-year-old male patient was admitted to *Hospital Universitário Regional*, to the North of Paraná, with history of being shot, which resulted in multiple injuries (five shots). The injuries were located on the posterior trunk (three), one to the side of the trunk, and one on the right arm. The patient was conscious, with blood pressure of 120/80 mmHg and regular pulse. All peripheral pulses were palpable and symmetric. Considering the multiple thoracic (without hemothorax) and abdominal injuries, x-rays were performed.

Study carried out at the Universidade Estadual de Londrina (UEL) – Londrina (PR), Brazil.

<sup>1</sup> Doctor by Universidade Federal de São Paulo (Unifesp) – São Paulo (SP), Brazil. Assistant Professor of the Surgical Clinical Department in the Sector of Vascular Surgery and Angiology of UEL – Londrina (PR), Brazil; member of the Brazilian Society of Angiology and Vascular Surgery (SBACV).

<sup>2</sup> Resident of the Surgical Clinical Department in the Sector of Vascular Surgery and Angiology of UEL – Londrina (PR), Brazil.

<sup>3</sup> Assistant Professor of the Surgical Clinical Department in the Sector of Vascular Surgery and Angiology of UEL – Londrina (PR), Brazil

Financial support: none.

Conflict of interest: nothing to declare.

Submitted on: 08.29.11. Accepted on: 02.06.12.

J Vasc Bras. 2012;11(1):67-72.

The patient was then submitted to the placement of bilateral thoracic drainage tubes and to exploratory laparotomy. The drainage by the thoracic ducts was minimum, and laparotomy showed no intra-abdominal lesions. Peripheral pulses in the lower limbs were present and symmetric.

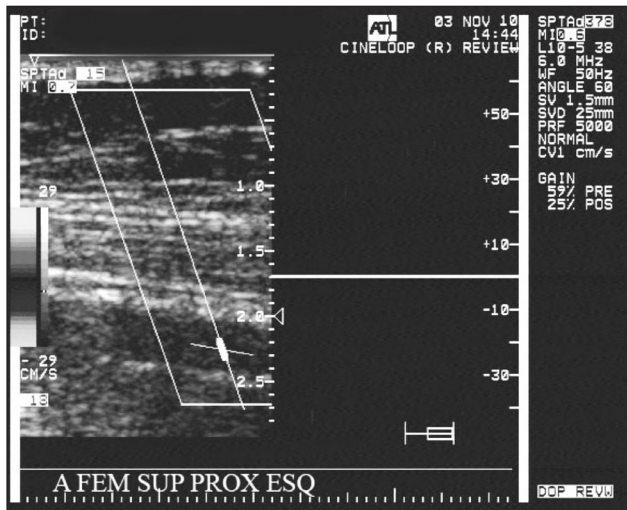
The patient was admitted, and approximately after 8 hours he began to present signs of cooling and absence of all pulses in the left lower limb (femoral, popliteal

and tibial). The Vascular Surgery Service was consulted and raised the diagnostic hypothesis of acute arterial occlusion, which was confirmed by a vascular ultrasound that showed the absence of arterial flow and intraluminal hypoechogenic image in the left superficial femoral artery (Figure 1). Associated with the absence of local arterial flow, the image was interpreted as early thrombosis, which caused the acute arterial occlusion.

**Table 1.** Arterio-arterial embolisms since 1990.

Reference	Entrance vessel	Location of embolism (occluded arteries)	Time for diagnosis	Arterial ischemia	Diagnosis of embolism	Removing the embolism	Result
Keele (2010) <sup>2</sup>	Proximal aorta	Descending thoracic aorta	4 days	No	Simple x-rays, angio	Pressure catheter	Full recovery
Sandler (2009) <sup>3</sup>	Infrarenal abdominal aortic transection	Fibular and right PT	1 day	Yes	Physical examination, x-rays, angio	Embolectomy	Transtibial bilateral amputation
Ntlhe (2008) <sup>4</sup>	Pulmonary vein (?)	Right internal carotid	2 months	Yes	Stroke, angio	Excision and ligature of the internal carotid D	Improvement stroke
Olsun (2008) <sup>5</sup>	Ascending aorta	Right renal interlobar	Hours	Yes	X-ray	Non-removed embolism	Full recovery
Nguyen (2006) <sup>6</sup>	Left ventricle	Right external carotid	Immediate	No	CT, X-ray	Arteriotomy	Full recovery
Ronsivalle (2005) <sup>7</sup>	Pulmonary vein	Right axillary vein	Immediate	Yes	Physical examination, CT, angio	Arteriotomy	Full recovery
Schwoerer (2004) <sup>8</sup>	Abdominal aorta	Right popliteal	Immediate	Yes	Computed tomography	Arteriotomy	Full recovery
Harirchi (2004) <sup>9</sup>	Right ventricle (interventricular septum?)	Right axillary	Immediate	Yes	Physical examination	Arteriotomy	Full recovery
Duncan (2002) <sup>10</sup>	Heart	Internal carotid	Immediate	Yes	Left paresis Angio	Non-removed embolism	Partial recovery
Kurt (2001) <sup>11</sup>	Left atrium	Right external iliac	Immediate	No	Laparotomy	Arteriotomy	Death (stroke?)
Shen (1998) <sup>12</sup>	Distal thoracic aorta	Right external iliac	Immediate	Yes	Physical examination	Arteriotomy	Death
Rajamani (1998) <sup>13</sup>	Pulmonary vein	Right internal carotid	16 hours	Yes	Angio	Arteriotomy	Death
Adegboyega (1996) <sup>14</sup>	Abdominal aorta	Left popliteal	14 months	No	Not performed at initial care. Angio	Non-removed embolism	Amputation (thigh)
Bilsker (1996) <sup>15</sup>	Left ventricle	Right subclavian	2 weeks	No	Angio	Arteriotomy	Full recovery
Yoshioka (1995) <sup>16</sup>	Right external iliac	Right deep femoral	Immediate	Yes	Embolectomy catheter	Non-removed embolism	Full recovery
Nikolic (1994) <sup>17</sup>	Descending aorta	Right common iliac	Hours	Yes	Angio	Arteriotomy	Not reported
Khalifeh (1993) <sup>18</sup>	Left ventricle	Right superficial femoral	Immediate	No	Simple x-ray	Arteriotomy	Full recovery
Kerr (1993) <sup>19</sup>	Right pulmonary vein	Right axillary	Immediate	Yes	Physical examination, angio	Arteriotomy	Full recovery
Bradham (1991) <sup>20</sup>	Pulmonary vein (?)	Aortic valve	3 days	No	Angio	Local aortotomy	Full recovery
Bongard (1991) <sup>21</sup>	Right superficial femoral	AT, PT and right fib	Immediate	Yes	Physical examination	Arteriotomy	Revascularization
	Left superficial femoral	Left pop trifurcation	Immediate	Yes	Physical examination	Embolectomy	Full recovery
	Left superficial femoral	Right ulnar	Immediate	Yes	Physical examination	Non-removed embolism	Amputation
	Right brachial	Left pop trifurcation	Immediate	No	Intraoperative angio	Arteriotomy	neurologic lesion
	Left external iliac						Full recovery

CT—computed tomography; AT—anterior tibial; PT—posterior tibial; FIB—fibular; POP—popliteal.



**Figure 1.** Examination of the left proximal superficial femoral artery (A FEM SUP PROX ESQ) showing the absence of flow in the spectral analysis.

The presence of early thrombosis in the superficial femoral artery and the clinical picture of acute arterial occlusion in the left lower limb led to the hypothesis of the occlusion of iliac arteries (common and external), which were previously normal. Since this acute occlusion could possibly affect the left aortoiliac segment, an acute arterial occlusion caused by trauma was considered, thus leading to a new laparotomy.

At laparotomy, a bullet was noticed when examining the left iliac bifurcation (Figure 2). The bullet was removed by an arteriotomy of the left iliac bifurcation, which did not show local lesions in the intima. The Fogarty catheters were introduced by the arteriotomy and the early thrombus (about 20 cm long) was removed. Circulation was restored by arteriorrhaphy.

The patient did not receive systemic anticoagulation, only local. In the postoperative period, the patient had symmetric peripheral pulses, with ankle-brachial index of 0.98 and normal vascular ultrasound. The entrance point of the bullet in the artery was not defined. The patient was discharged without sequelae.

## Discussion

“The occurrence of bullets in the blood flow, even if rare, has become more than a surgical curiosity, and its presence must be taken into account when unexpected symptoms are observed after injuries caused by a firearm, especially when the bullet cannot be visualized”<sup>22</sup>. Right after the First World War, in 1917,



**Figure 2.** Projectile (arrow) after arteriotomy of the external iliac artery.

this editorial in Lancet was already concerned about the arterial embolism caused by projectiles. Currently, with the increased urban violence, this notice is more than adequate.

Firearm bullets penetrating the pulmonary veins, left heart, aorta or large-caliber arteries of the thorax, abdomen and limbs may have enough energy to penetrate, but not to transect the vessel, thus becoming an embolism. So, they travel through the blood flow until occluding a peripheral artery in a site that is distant from the initial perforation<sup>2-21</sup>. As in all emergencies, an accurate diagnosis should be made as soon as possible in order to minimize complications. In case of acute arterial occlusion, when the arterial embolism consists of a firearm bullet, diagnosis is rarely taken into account, especially because the acute arterial occlusion is far from the trauma site. Therefore, knowing this type of arterial embolism is important for those who work in trauma centers.

The migration of a firearm bullet through the circulatory tree can cause symptoms that mislead assistant doctors<sup>10,12</sup>, thus causing doubts as to diagnosis and treatment. Complications of such injuries also include: infection, pseudoaneurysm, and hemorrhage in the place where the projectile entered the circulation<sup>14</sup>. In case of proximal arterial lesions<sup>9</sup>, the distal emboli are not treated and can lead to ischemia in places that are distant from the injury site (proximal); unless there is clinical suspicion or the diagnosis is made with the consequent removal of the emboli, the limb can suffer an

irreversible ischemia, despite the success of a proximal arterial reconstruction<sup>10,13,15</sup>.

Even though it has been described since 1834 by Thomas Davis<sup>1</sup>, arterial embolism caused by a projectile is rare in cases of trauma, especially in combat situations. The frequency of these cases during the Vietnam war is usually described as 0.3% of the arterial trauma cases<sup>1</sup>. However, the reports were referred to arterial embolism caused by explosive debris, (0.25% of arterial trauma cases), and these were caused by a projectile, which results in the frequency of 0.04% when it comes to arterial trauma. A possible explanation for the low frequency of embolism caused by projectiles during wars is the use of high energy bullets (and high speed), which tend to destroy the vessel instead of penetrating it. In order for a projectile to enter the systemic circulation, its energy must be only sufficient to penetrate the vessels or the heart, and not to transfix the structure<sup>1,5,8</sup>.

One of the causes that can determine the rarity of arterial embolism caused by projectile in the emergency rooms is that injuries involving the heart and major vessels are usually lethal, so patients die before the emergency care<sup>11</sup>. The mortality rate of patients with peripheral arterial embolism increases from 21%, when the bullet comes into the circulation by the heart, to 47%, when it enters by the thoracic aorta. This rate can increase to 70% when the bullets come in by the abdominal aorta<sup>1</sup>, maybe because of excessive bleeding.

Since it is rare, most reports consist of single cases, or with a small number of patients<sup>2-21,23-26</sup>. In civil trauma, 80% of the causes are caused by low-caliber bullets, with low speed<sup>2-21</sup>.

In case of acute arterial ischemia in a patient with trauma caused by firearm, the possibility of embolism caused by a projectile should be taken into account when it is not possible to visualize an exit hole, when the signs and symptoms are different from those expected due to lesions in organs that are in the supposed path of the projectile, and when the projectile is not visualized in imaging examinations<sup>8,9,15</sup> – considering that most arterial injuries caused by firearm are owed to lesions in the arterial wall, directly or indirectly. The possibility of arterial embolism caused by a projectile should also be considered when signs of ischemia cannot be explained by the entrance wound, or when the patient presents signals of arterial ischemia in a limb that had not been previously involved<sup>3,4,7</sup>.

When the projectile enters the blood flow, its path depends on the anatomy and on arterial hemodynamics, as

well as on the effects of gravity<sup>7-12</sup>. Most bullets causes embolism in the arteries of the lower limbs<sup>1,3,8,12,14,16</sup>, especially when the projectile enters through the descending or abdominal aorta due to anatomy and position of the patient at the time of the trauma, as well as respiratory and muscular movements made by the patient<sup>12</sup>. When the projectile enters through the descending aorta, the tendency is for it to be transported to the brachiocephalic trunk due to its diameter and anatomic location<sup>9</sup>.

In young patients, the penetration in the aorta may be tamponade, which makes the diagnosis more difficult<sup>7,9</sup>. The fact that the entrance wound is located in the right ventricle does not rule out the possibility of an arterial embolization being originated in this site<sup>10</sup>, probably due to the presence of patent foramen ovale.

As to symptomatology, in 66.7% of the cases, patients presented with signs and symptoms of arterial ischemia; 13.3% presented only with neurological symptoms, and 20% of the patients were asymptomatic (Table 1)<sup>9</sup>. In another review, there were signs of arterial ischemia in only 40.7% of the cases<sup>3,4,12,16</sup>, possibly due to collateral circulation.

The recommended treatment is to remove the bullet, preferably by local arteriotomy, with visual inspection of the intima in the site<sup>6-9,11-13,15,17-21</sup>, instead of catheter embolectomy due to the risk of intimal lesions. In one of the cited cases, the projectile was removed with a pressure catheter<sup>2</sup>. The indication to remove the asymptomatic arterial embolism includes the risk of a new distal embolism, clotting and potential arterial occlusion<sup>5,14,16,21</sup>.

Embolism caused by a projectile in a paradoxical way, in which the entrance point is the venous part of the circulation (systemic veins, pulmonary artery, right atrium and right ventricle) (Table 2) is even rarer<sup>6,23-26</sup>. The embolism should pass to the blood flow through interventricular communication (IVC) and interatrial communication (IAC), or even by an arteriovenous fistula<sup>6,23-26</sup>. Since only 6% of the population presents IAC (most common anatomic malformation), whose diameter is sufficient to enable the passage of a bullet, paradoxical embolism is unusual<sup>6,23-26</sup>.

### **Review of case reports**

The bibliographic review was based on cases indexed in PubMed (www.PubMed.gov), from the review by Michellassi, in 1990<sup>1-21,23-36</sup>, and includes only cases of embolism that impacted peripheral arteries caused by firearm

**Table 2.** Paradoxical embolisms.

Reference	Entrance vessel	Location of embolism (occluded arteries)	Time for diagnosis	Diagnosis of embolism	Type of arteriovenous communication	Removing the embolism	Result
Nguyen (2006) <sup>6</sup>	Left pulmonary artery	Left internal iliac	Days	Angio	Traumatic fistula pulmonary artery and ascending aorta	Non-removed embolism	Full recovery
Miroslav (2005) <sup>23</sup>	Left subclavian vein	Right common femoral	7 days	Physical examination, angio	IAC	Arteriotomy	Full recovery
Meeks (2004) <sup>24</sup>	Hepatic vein	Right superficial femoral	Immediate	Physical examination, angio	IAC	Embolectomy	Full recovery
Corbett (2003) <sup>25</sup>	Inferior vena cava (?)	Left common femoral	Immediate	Physical examination, duplex	IAC	Arteriotomy	Medullary lesion Full arterial recovery
Schurr (1996) <sup>26</sup>	Left external iliac vein	Left common iliac	Immediate	Physical examination	IAC	Arteriotomy	Full recovery

IAC=interatrial communication.

bullets (single bullets or pellets) in patients who went to the emergency room. Autopsy reports, embolism caused by debris and venous embolism were excluded.

In this review, “embolism projectiles” were only considered when the embolism consisted of the projectiles themselves, and lead pellets (Table 1). In cases of civil trauma, embolism is usually caused by low caliber<sup>2-21,23-26</sup> or low speed bullets, so kinetic energy enables vascular penetration, but not the transfixing of heart chambers of blood vessels.

One of the broadest bibliographic reviews showed 153 cases of arterial and venous embolism caused by bullets up to 1990<sup>1</sup>, and demonstrated the entrance site in the arterial tree was defined in less than 50% of the cases (71 out of 153; 46.4%). Among the 58 cited cases, the entrance site was the aorta for 22 patients (37.9%), the left ventricle for 10 (17.2%), the abdominal aorta for 9 (15.5%), the heart for 5 (8.6%), the left atrium and the pulmonary vein for 3 (5.2%), and each of the following sites for 1 patient (1.7%): right atrium, right ventricle, left common iliac, right common femoral and left common carotid arteries. From the bullets that entered the systemic circulation, 10 out of 26 (38.47%) migrated to the brachiocephalic trunk (BCT) (7 to the right subclavian, 2 to the common carotid and 1 for the distal BCT). Out of the 16 left, 1 migrated to the left common carotid, and 15 (93.75%) went to the descending aorta. To these 15 were added 29, which perforated the descending aorta. Out of the 44 embolisms present in the descending aorta, 10 (22.27%) moved to the right external iliac artery, and 15 (34.1%) to the left external iliac<sup>1</sup>.

Since 1990, we have found a total of 20 case reports of arterial embolism, with 23 arteries occluded by arterio-arterial embolism (Table 1)<sup>2-21,23-26</sup>. In this period, other

five cases of paradoxical embolism were published, that is, venous-arterial (Table 2). The arteries that suffered embolism were more commonly in the lower limb (11 out of 22 cases, 50%). In nine cases (82%), the arteries of the right side were also occluded. In the lower limbs, the most affected arteries were the popliteal (three cases) and the external iliac artery (two cases).

Even though the authors in the 1990s have mentioned that diagnosis took a long time<sup>1</sup>, in most of the cases analyzed in our review, diagnosis was immediate (14 cases out of 23; 60.86%) (Table 2), possibly due to the easy access to angiography, which was used for diagnosis of 11 (47.8% out of the 23 cases). Physical examination was used for the early diagnosis of 7 (30.43%) out of the 23 cases. There were signs of arterial ischemia in 16 (69.56%) out of the 23 cases. The embolisms were removed by direct arteriotomy in 14 (60.86%) cases, and there was full recovery in 13 (56.52%) cases (Table 2).

## References

1. Michelassi F, Pietrabissa A, Ferrari M, et al. Bullet emboli to the systemic and venous circulation, *Surgery*. 1990;107:239-45.
2. Keele KL, Gilbert PM, Aquisto TM, et al. Bullet embolus to the thoracic aorta with successful endovascular snare retrieval. *J Vasc Interv Radiol*. 2010;21(1):157-8.
3. Sandler G, Merrett N, Buchan C, et al. Abdominal shotgun wound with pellet embolization leading to bilateral lower limb amputation: case report and review of the literature of missile emboli over the past 10 years. *J Trauma*. 2009;67(6):E202-8.
4. Ntlhe LM, Komati SM, Fourie PA, et al. Missile embolism--pulmonary vein to systemic bullet embolism: a case report and review of the literature. *S Afr J Surg*. 2008;46(2):58-60.
5. Olsun A, Duzyol C, Gur AK, et al. Bullet embolism after gunshot injury: a case report. *Heart Surg Forum*. 2008;11(3):E193-4.



6. Nguyen R, Ouedraogo A, Deneuille M. Gunshot wounds to the chest with arterial bullet embolization. *Ann Vasc Surg.* 2006;20(6):780-3.
7. Ronsivalle J, Statler J, Venbrux AC, et al. Intravascular bullet migration: a report of two cases. *Mil Med.* 2005;170(12):1044-7.
8. Schwoerer AP, Omshoro-Jones JAO, Jones; Zellweger R. A bullet embolism to the right popliteal artery following an abdominal gunshot wound. *European J Trauma.* 2004;30(5):319-22.
9. Harirchi I, Salehi M, Ghazisoltani M, et al. Gunshot wound of the heart with embolism to the right axillary artery. *Int Surg.* 2004;89(3):176-80.
10. Duncan IC, Fourie PA. Embolization of a bullet in the internal carotid artery. *AJR Am J Roentgenol.* 2002;178(6):1572-3.
11. Kurt N, Küçük HF, Celik G, et al. Bullet embolism of the right external iliac artery following cardiac gunshot wound (a case report). *Ulus Travma Derg.* 2001;7(2):131-3.
12. Shen P, Mirzayan R, Jain T, et al. Gunshot wound to the thoracic aorta with peripheral arterial bullet embolization: case report and literature review. *J Trauma.* 1998;44(2):394-7.
13. Rajamani K, Fisher M. Bullet embolism. *NEJM.* 1998;339(12):812.
14. Adegboyega PA, Sustento-Reodica N, Adesokan A. Arterial bullet embolism resulting in delayed vascular insufficiency: a rationale for mandatory extraction. *J Trauma.* 1996;41(3):539-41.
15. Bilsker MS, Bauerlein EJ, Kamerman ML. Bullet embolus from the heart to the right subclavian artery after gunshot wound to the right chest. *Am Heart J.* 1996;132(5):1093-4.
16. Yoshioka H, Seibel RW, Pillai K, et al. Shotgun wounds and pellet emboli: case reports and review of the literature. *J Trauma.* 1995;39:596-601.
17. Nikolic G, Todoric M, Simić A. Embolization of the iliac artery by a bullet. *AJR Am J Roentgenol.* 1994;163(1):229-30.
18. Khalifeh M, Khoury G, Hajj H, et al. Penetrating missile embolisation. *Eur J Vasc Surg.* 1993;7(4):467-9.
19. Kerr A, Louie W. Bullet embolus from a pulmonary vein to the right axillary artery. *Cardiovasc Intervent Radiol.* 1993;16(3):178-9.
20. Bradham WG, Lewis JV, Sewell DH, et al. Bullet embolus to the ascending aorta following a gunshot wound to the chest. *J Tenn Med Assoc.* 1991;84(12):592-3.
21. Bongard F, Johs SM, Leighton TA, et al. Peripheral arterial shotgun missile emboli: diagnostic and therapeutic management--case reports. *J Trauma.* 1991;31(10):1426-31.
22. Migration of projectiles in the blood stream. *Lancet.* 1917[4906]:190:395.
23. Miroslav M, Lazar D, Aleksandar M, et al. Rare forms of peripheral arterial embolism: review of 11 cases. *Vascular.* 2005;13(4):222-9.
24. Meeks T, Nwomeh B, Abdessalam S, et al. Paradoxical missile embolus to the right superficial femoral artery following gunshot wound to the liver: a case report. *J Trauma.* 2004;57(6):1338-40.
25. Corbett H, Paulsen EK, Smith RS, et al. Paradoxical bullet embolus from the vena cava: a case report. *J Trauma.* 2003;55(5):979-81.
26. Schurr M, McCord S, Croce M. Paradoxical bullet embolism: case report and literature review. *J Trauma.* 1996;40(6):1034-6.

---

**Correspondence**

Domingos de Morais Filho  
 Avenida Bandeirantes, 403 – Ipiranga  
 CEP 86010-020 – Londrina (PR), Brazil  
 E-mail: domingos.morais@sercomtel.com.br

**Authors' contributions**

Study conception and design: DMF  
 Data analysis and interpretation: DMF  
 Data collection: DMF, GTFS  
 Writing: DMF  
 Critical review: WES  
 Final approval\*: GTFS, GOST, WES, JMSS, EDR, DMF  
 Statistical analysis: DMF  
 Overall responsibility: DMF

\*All authors have read and approved the final version submitted to J Vasc Bras.