

Comparison of the effects of low-level laser therapy and low-intensity pulsed ultrasound on the process of bone repair in the rat tibia

Comparação dos efeitos do laser de baixa potência e do ultrassom de baixa intensidade no processo de reparo ósseo em tíbia de rato

Poliani Oliveira¹, Evandro Sperandio², Kelly R. Fernandes², Fabio A. C. Pastor³, Keico O. Nonaka⁴, Ana C. M. Renno⁵

Abstract

Background: Electrophysical agents such as Ultrasound (US) and low-level laser therapy (LLLT) have been increasingly used in physical therapy practice. Studies suggest that these devices are able to stimulate osteoblast proliferation and osteogenesis at the fracture site, resulting in a greater deposition of bone mass and speeding up the consolidation process. **Objective:** The aim of this study was to analyze the effects of US and LLLT on the bone healing process, through biomechanical and histological analysis of the bone callus. **Methods:** A total of 30 rats were randomly allocated into three groups: control group fracture without treatment (GC); fracture group treated with pulsed US, *burst* 1.5 MHz, 200us, 1KHz, 30 mW/cm² (GUS) and fracture group treated with laser 830nm, 100mW, 120J/cm² (GL). Bone defects were performed with a circular drill of 2mm in diameter in the animal's tibias. The treatments were carried out after surgery consisting of 7 applications every 48 hours. After 14 days the animals were sacrificed and the tibias were removed to perform the analysis, being the right tibia designated for biomechanical analysis, while the left tibia for histological analysis. **Results:** The biomechanical analysis showed no statistically significant difference between biomechanical properties of the CG, CL and GUS. In morphometric analysis, both GUS and GL showed a significantly higher woven bone tissue area compared to the control group. However, when the two treatment modalities were compared, there were no statistical differences between them. **Conclusion:** Both devices used in this study were able to accelerate the bone healing process in rats.

Keywords: laser; ultrasound; bone; rat.

Resumo

Contextualização: Recursos eletrofísicos, como o ultrassom (US) e a terapia laser de baixa potência (LLLT), vêm sendo cada vez mais utilizados na prática fisioterapêutica. Estudos sugerem que esses recursos são capazes de estimular a proliferação de osteoblastos e a osteogênese no local da fratura, promovendo maior deposição de massa óssea e acelerando o processo de consolidação. **Objetivo:** Analisar os efeitos do US e da LLLT no processo de consolidação óssea por meio das análises biomecânica e histológica do calo ósseo. **Métodos:** Foram utilizados 30 ratos machos, distribuídos aleatoriamente em três grupos: grupo controle fratura, sem tratamento (GC); grupo fratura tratado com US pulsado com *burst* de 1,5 MHz, 200us, 1KHz, 30 mW/cm² (GUS) e grupo fratura tratado com laser 830nm, 100mW, 120J/cm² (GL). Foram realizados defeitos ósseos circulares com broca de 2 mm de diâmetro nas tíbias dos animais. Os tratamentos foram realizados a cada 48 horas, totalizando sete aplicações e, no 14^o dia, os animais foram sacrificados. A tibia direita foi designada para análise biomecânica, enquanto a esquerda, para análise histológica. **Resultados:** A análise biomecânica não mostrou diferença estatisticamente significativa entre as propriedades biomecânicas do GC, GL e GUS. Na análise morfométrica, tanto GUS quanto GL apresentaram área de osso neoformado estatisticamente maior em relação ao GC. No entanto, quando as duas modalidades de tratamento foram comparadas, não foram encontradas diferenças estatísticas entre elas. **Conclusão:** Ambos os recursos utilizados neste estudo foram capazes de acelerar o processo de reparo ósseo em ratos.

Palavras-chave: laser; ultrassom; tecido ósseo; rato.

Received: 03/12/2009 – **Revised:** 05/08/2010 – **Accepted:** 14/02/2011

¹Postgraduate Program in Biotechnology, Universidade Federal de São Carlos (UFSCar), São Carlos, SP, Brazil

²Physical Therapist

³Postgraduate Program in Physiological Sciences, UFSCar

⁴Department of Physiological Sciences, UFSCar

⁵Department of Biosciences, Universidade Federal de São Paulo (UNIFESP), Santos, SP, Brazil

Correspondence to: Ana Claudia Muniz Renno, Av. Ana Costa, 95, Vila Mathias, CEP 11050-240, Santos, SP, Brasil, e-mail: a.renno@unifesp.br

Introduction

The bone repair is a highly complex regenerative process, which includes the interaction of a series of biological events, such as the active synthesis of genes and the action of a large number of cells and proteins, which will determine the restoration of the integrity of the bone tissue¹. However, during this process it is possible to occur alteration that will culminate in the impairment of the bone regeneration and, consequently, the delay in consolidation and, even in non-bone union. It is estimated that, in the USA from the 6.2 million of fractures that occur annually, nearly 10% will progress to non-consolidation and pseudoarthrosis¹.

Within this context, several biophysical and biochemical advances have been investigated in an attempt to minimize the time to bone consolidation and to decrease the chance of possible complications originated from abnormal regeneration process². Among them, the effects of treatments such as the administration of bone morphogenetic proteins, bioactive materials and the use of electromagnetic fields can be cited. More recently, the use of low-intensity pulsed ultrasound (US) and of the low-level laser therapy (LLLT) have been suggested as a possible treatment for this condition³.

Due to the positive effects on bone metabolism and on fracture consolidation the use of LLLT has been encouraged in clinical practice. Renno et al.⁴ and Stein et al.⁷ showed a significant increase in the proliferation of osteoblasts after 830 nm laser irradiation at 20 J/cm². In addition, the laser seems to accelerate the process of fracture repair and cause an increase on the callus volume and bone mineral density^{8,9}. Pinheiro et al.¹⁰ showed that the laser (830 nm, 40 mW, 4,8 J/cm²) was able to increase the amount of mineralized bone tissue in induced fractures in rats' femurs.

The low intensity pulsed US is also a device that has been gained high attention due to its great osteogenic potential¹¹. Several authors have demonstrated the effectiveness of the US in the acceleration of bone consolidation after a fracture as well as improving the biomechanical properties of the bone callus in rats and rabbits^{12,13}. Takikawa et al.¹² observed in an experimental study, that after six weeks of treatment, the US has significantly increased the level of fracture consolidation in non-union fractures in comparison with a control group. Similar results were reported by Sun et al.¹⁴ and Lirani-Galvão et al.⁹.

According to the points discussed above, the US and the LLLT have been emerging as promising alternatives in the treatment of bone fractures. Such devices, present a great osteogenic potential, as well as they consist of a non-invasive treatment methods and have a relatively low cost. However, controversy exists with regards to the best parameters to be used to obtain an effective outcome on the bone tissue after the administration of US and LLLT. In addition, studies that

have compared the effects of these two devices on the fracture consolidation process are scarce. Therefore, this study has the purpose to verify the effects of the US and of the LLLT on the bone consolidation process in rats, based on biomechanical and histological analysis.

Methods

Thirty male Wistar rats weighting between 280 and 320g were selected for inclusion in this study. The animals remained under controlled environmental conditions (light/dark cycle of 12/12 hours, sanitized environment, temperature of 24±2°C and adequate ventilation), where they received common ration and water freely. This study had been approved by the Ethics Committee in Animal Experimentation of the Universidade Federal de São Carlos (UFSCar), São Carlos, SP, Brazil (Protocol 023/2006).

The animals were randomly allocated into three groups (n=10): control group with fracture (CG) in which the rats were submitted to the bone defect, however they did not receive treatment; laser group (GL) in which the rats were submitted to the bone defect and there were treated with laser of 120 J/cm², and US group (GUS) in which the rats were submitted to bone defect and they were treated with US. To perform the bone defects, the rats were anesthetized according to their body weight with a mixture of Ketamine (National Pharmaceutical Chemical Union S/A, Brazil) and Xylazine (Calier Laboratories S.A, Brazil) (80/10 mg/Kg). Both the right and left tibia were submitted to the surgical procedure. After anesthesia, trichotomy and disinfecting of the area to be operated, a skin incision was performed in the medial region to expose the tibia. A standardized 2 mm diameter bone defect, irrigated with saline solution, was created in the middle third of the tibia (10 mm below knee joint) using a motorized drill (Figure 1). Finally, muscle and skin were sutured with a 4.0 monofilament nylon

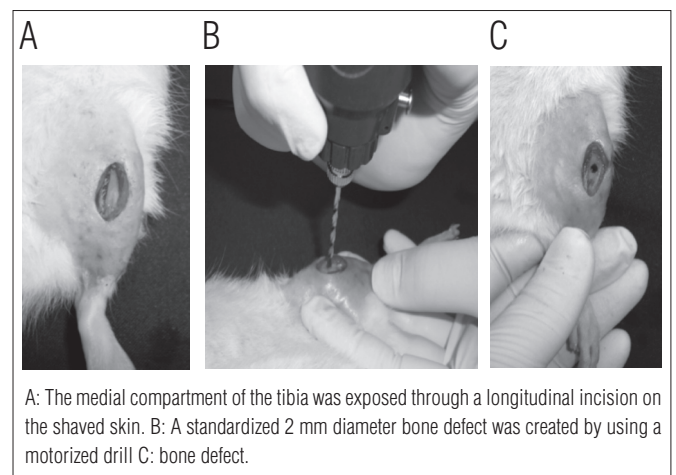


Figure 1. Pictures of surgery.

with 1 cm distance between points, and then the site was cleaned. The animals had free access to water and food until they were sacrificed.

Treatments

Low intensity laser

The device used was a portable Laser model DMC, THE-RALASE, version 24, class 3B, Ga-Al-As diode, with wavelengths of 830 nm, continuous emission, output power of 100 mW, power density of 3.57 W/cm², beam area of 0,028 cm² and divergence of 1.5°. The laser application was performed in both tibias, using the punctual contact technique in just one point over the fracture, being the pen device positioned perpendicularly to the tissue. The fluency used was 120 J/cm², for 34 seconds, 3.4J of energy.

Low intensity pulsed ultrasound

A portable model of US (Exogen, United States), pulsed mode with a burst of 1.5 MHz, with pulse width of 200us, pulse repetition frequency of 1 KHz and intensity of 30 mW/cm², for 20 minutes.

Both treatments have been initiated immediately after the surgical procedure and in the second, fourth, sixth, eighth, tenth and twelfth post-surgery day, with a total of seven applications in 14 days. The application was performed on both tibias.

Euthanasia

On the fourteenth day after the experimental procedure, the animals were euthanized by a lethal dose of anesthetics, injected intraperitoneally. The tibias and the soft tissue were removed for further analysis. The right tibia was chosen for biomechanical analysis, while the left tibia was used for the histological analysis. The analyses were performed with ten samples of each group.

Biomechanical analysis

For biomechanical analysis, a three point bending test was performed, which was carried out on the right tibia of the animals of all groups. The biomechanical tests were performed in a universal testing machine (Instron, model 4444) at room temperature. To perform the test, a load cell with maximal capacity of 1 KN and preload of 5 N was used. A metallic frame of 3.8 cm length was used, exposing only 1.8 cm of the specimen. The tibias were positioned with the defect area facing down in order to place this segment under traction according to the

model used in the Lirani-Galvão et al.⁹ study. From this test, the following variables were obtained: maximal load (KN), resilience (J) and tenacity (J).

Histological analysis

The tibias were decalcified in a decalcification solution described by MORSE (Sodium Citrate at 20% and Formic Acid at 50% in equal parts) and, subsequently processed in paraffin. The paraffin blocks were sectioned longitudinally with standardized thickness of 5.0 µm, and histological sections were prepared. The sections were then stained with Hematoxylin and Eosin (HE) for qualitative analyses and with Masson Trichrome for morphometry. Each animal was represented by two histological sections, each one with a series of at least three consecutive sections.

The qualitative histological analysis was performed using a light microscope (Olympus, Optical Co. Ltd, Tokyo, Japan). Modifications such as the presence of new bone formation, bone marrow tissue, presence of inflammatory infiltration and granulation tissue, were considered.

The morphometry of the area of the new bone formation in the defect region of each animal was measured with the sections stained with TM using an image analysis system Motican 5.0. Two areas of the cortical region of the bone defect were selected and named C1 and C2, corresponding to the regions adjacent to the wall defect, located above and below the cortical region of the of the bone defect (Figure 2). In this staining, the woven bone tissue stains in blue, being therefore possible to measure the entire area of new bone formation. The areas were registered using a 10X objective Lents. After being registered, they were combined, resulting in the total area of woven bone tissue in the defect.

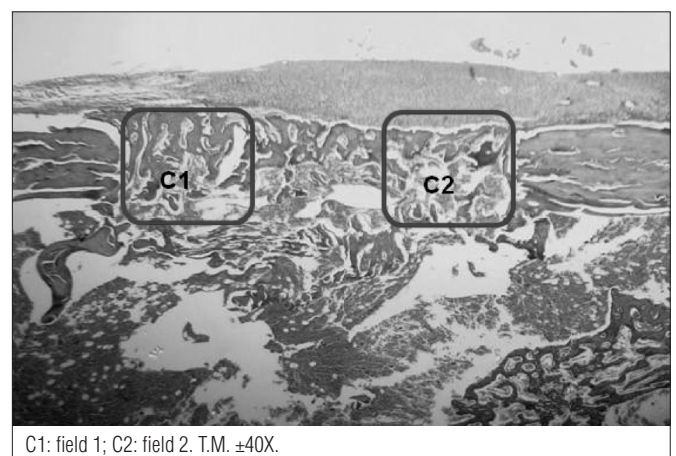


Figure 2. Standardization of selected areas in histological sections for morphometry.

Statistical analysis

Descriptive analyses, such as graphs and tables, as means and standard deviations were used to analyze statistically the data. The Shapiro-Wilk normality test was used for all the variables and the Kruskal Wallis test was used for comparisons between groups. The analyses were performed with the STATISTICA software, version 7.0. The level of significance was of $p \leq 0.05$.

Results

Biomechanical analysis

Table 1 presents the means and the standard deviations of the biomechanical properties of all experimental groups. The statistical analysis showed that there was no significant difference among the three groups after the period of 14 days.

Qualitative histological analysis

A moderate presence of woven bone tissue inside the defects was observed in the control group. The presence of inflammatory process (Figure 3A) was not observed. In the groups treated with LLLT and US, similar results were found. In both groups there was a large amount of woven bone tissue and also the presence of extensive union of thick and well-defined trabeculae bone in most parts of the affected area (Figure 3B and 3C). The presence of inflammatory process was not observed. Moreover, the treated groups presented a higher tissue organization compared to the CG.

Morphometric analysis

It can be observed in Figure 4 that the GL and GUS presented statistically significant values of the area of woven bone tissue when compared to the GC that was not treated. However, there was no difference in the comparison between the GL and GUS groups.

Table 1. Biomechanical Properties (Mean±SD).

Group	Maximal load (KN)	Energy absorption (J)	Tenacity (J)
GC	0.064±0.020	0.029±0.012	0.057±0.011
GUS	0.056±0.012	0.022±0.010	0.034±0.013
GL	0.056±0.009	0.018±0.007	0.055±0.019

GC: fracture control group; GUS: ultrasound group; GL: laser group. (n=10/grupo).

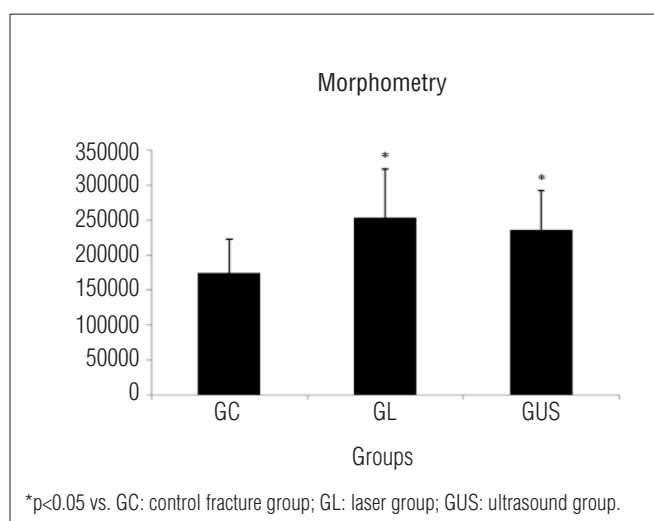


Figure 4. Mean and standard deviation of the area of woven bone tissue of the different experimental groups.

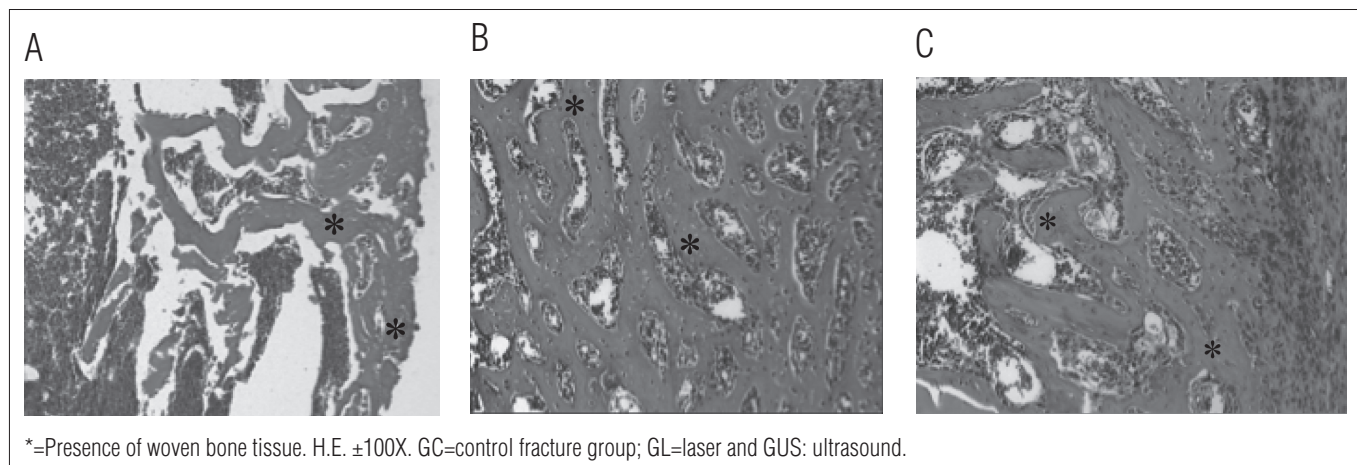


Figure 3. Bone defect from GC (A); GL (B) and GUS (C).

Discussion

The present study demonstrated, through histological analyses, that both the therapeutic laser and the low intensity pulsed US were able to stimulate the bone healing process after the induction of defects in the rat tibias. However, no significant differences were observed between these two devices; in addition, no modifications in the mechanical properties of bone callus of the animals treated were found.

Several studies have reported that laser is able to contribute to the acceleration of the bone healing process. Merli et al.¹⁵ found positive results after the administration of laser (Ga-As-Al 670 nm, 15 mW) in bone defects. After 14 days, the authors found an increase of the area of the woven bone tissue in the group treated with laser when compared to the control group. The acceleration of the bone healing process was also reported in other studies, such as the study by Pretel et al.¹⁶ and by Pinheiro et al.¹⁰, that have used the laser As-Ga-Al (830 nm, continuous, 40 mW, 57.6 J/cm²).

A similar result was observed by Matsumoto et al.¹⁷, whom used the laser Ga-As-Al, 735 nm, continuous, 16 J/cm², for repairing the bone defect in rats tibias, being the treatment carried out every 48h for 7, 14 and 21 days. As a result, they found that the laser was able to increase the area of the woven bone tissue in the area of bone defect after 14 days from surgery.

The effects of US in bone healing process have also been widely investigated and, according to several authors, this device seems to stimulate bone metabolism. Freeman et al.¹⁸ have used computerized tomography to investigate the effects of the US on the bone remodeling during the repair of bone fracture in rat's femurs. As a result, they found that there was a significant increase in woven bone tissue in the fracture site in the US group. Moreover, Gebauer et al.¹⁹ showed that the US at 30 mW/cm², 1.5 MHz was effective to increase bone strength in diabetic rats.

Despite the positive effects of the US and the laser therapies, such as the stimulation of the bone healing process, no biomechanical changes was found in the histological analysis.

It can be suggest that the time after surgery has not been sufficient to result biomechanical properties changes. Shakouri et al.²⁰ have also not found an increase in the biomechanical properties after using low intensity pulsed US, 30 mW / cm², in the bone healing process of rabbits tibia fractures. In the study, osteotomies were performed in 30 rabbits tibias treated with US for a period of eight weeks. The computerized tomography showed that there was an increase in bone mineral density in the US group compared with the control group. However, no significant statistical differences in the biomechanical properties were found. Similarly, Otremski et al.²¹ have not found evidence of increased stiffness and maximum torque after irradiation with 632 nm HeNe laser.

Studies comparing these two treatment modalities are scarce in the literature. In a comparative study, which evaluated the effects of the laser and the US in cultured fibroblasts, it was observed that both devices have promoted cellular changes²². However, in a similar study conducted by De Oliveira et al.²³ it was observed a higher cell proliferation in cultured fibroblasts irradiated with laser, which it seems to be more effective.

Therefore, there is a need for further studies *in vivo* examining the effects of these two modalities of treatment on bone tissue. Thus, the present study can be considered of great importance, as well as the study performed by Liran-Galvão et al.⁹, whom compared the effects of LLLT (Ga-Al-As laser, 780 nm, 30 mW, 112.5 J / cm²) with of low intensity pulsed US (LIPUS) (1.5 MHz, 30 mW / cm²). In this study, the authors have found that both physical agents promoted changes in bone repair, but at different stages of healing process. The LIPUS increased the bone healing process by promoting bone reabsorption in the fractured area, while LLLT accelerated this process through bone formation and by the increase of the maximum bone strength when compared to control groups and LIPUS.

Based on the results of this study, it is possible to conclude that both the therapeutic laser and the low intensity pulsed US were able to increase the area of woven bone tissue, accelerating the bone healing process after the induction of defect in the rat tibias.

References

- Sena K, Leven RM, Mazhar K, Sumner DR, Viridi AS. Early gene response to low-intensity pulsed ultrasound in rat osteoblastic cells. *Ultrasound Med Biol.* 2005;31(5):703-8.
- Hadjiargyrou M, McLeod K, Ryaby JP, Rubin C. Enhancement of fracture healing by low intensity ultrasound. *Clin Orthop Relat Res.* 1998;(355 Suppl):S216-29.
- Brighton CT, McCluskey WP. Response of cultured bone cells to a capacitively coupled electric field: inhibition of cAMP response to parathyroid hormone. *J Orthop Res.* 1988;6(4):567-71.
- Renno ACM, McDonnell PA, Parizotto NA, Laakso EL. The effects of laser irradiation on osteoblast and osteosarcoma cell proliferation and differentiation *in vitro*. *Photomed Laser Surg.* 2007;25(4):275-80.
- Luger EJ, Rochkind S, Wollman Y, Kogan G, Dekel S. Effect of low-power laser irradiation on the mechanical properties of bone fracture healing in rats. *Lasers Surg Med.* 1998;22(2):97-102.
- Ozawa Y, Shimizu N, Kariya G, Abiko Y. Low-energy laser irradiation stimulates bone nodule formation at early stages of cell culture in rat calvarial cells. *Bone.* 1998;22(4):347-354.
- Stein A, Benayahu D, Maltz L, Oron U. Low-level laser irradiation promotes proliferation and differentiation of human osteoblasts *in vitro*. *Photomed Laser Surg.* 2005;23(2):161-6.
- Liu X, Lyon R, Meier HT, Thometz J, Haworth ST. Effect of lower-level laser therapy on rabbit tibial fracture. *Photomed Laser Surg.* 2007;25(6):487-94.

9. Lirani-Galvão AP, Jorgetti V, da Silva OL. Comparative study of how low-level laser therapy and low-intensity pulsed ultrasound affect bone repair in rats. *Photomed Laser Surg.* 2006;24(6):735-40.
10. Pinheiro ALB, Oliveira MG, Martins PPM, Ramalho LMP, Oliveira MAM, Novaes Junior A, et al. Biomodulatory effects of LLLT on bone regeneration. *Laser Therapy.* 2001;13:73-9.
11. Gam AN, Johannsen F. Ultrasound therapy in musculoskeletal disorders: a meta-analysis. *Pain.* 1995;63(1):85-91.
12. Takikawa S, Matsui N, Kokubu T, Tsunoda M, Fujioka H, Mizuno K, et al. Low-intensity pulsed ultrasound initiates bone healing in rat nonunion fracture model. *J Ultrasound Med.* 2001;20:197-205.
13. Lia JK, Chang WH, Lin JC, Ruaan RC, Liu HC, Sun JS. Cytokine release from osteoblasts in response to ultrasound stimulation. *Biomaterials.* 2003;24(13):2379-85.
14. Sun JS, Tsuang YH, Lin FH, Liu HC, Tsai CZ, Chang WH. Bone defect healing enhanced by ultrasound stimulation: an *in vitro* tissue culture model. *J Biomed Mater Res.* 1999;46(2):253-61.
15. Merli LA, Santos MT, Genovese WJ, Faloppa F. Effect of low-intensity laser irradiation on the processo of bone repair. *Photomed Laser Surg.* 2005;23(2):212-5.
16. Pretel H, Lizarelli RF, Ramalho LT. Effect of low-level laser therapy on bone repair: histological study in rats. *Lasers Surg Med.* 2007;39(10):788-96.
17. Matsumoto MA, Ferino RV, Monteleone GF, Ribeiro DA. Low-level laser therapy modulates cyclooxygenase-2 expression during bone repair in rats. *Lasers Med Sci.* 2009;24(2):195-201.
18. Freeman TA, Patel P, Parvizi J, Antoci V Jr, Shapiro IM. Micro-CT analysis with multiple thresholds allows detection of bone formation and resorption during ultrasound-treated fracture healing. *J Orthop Res.* 2009;27(5):673-9.
19. Gebauer GP, Lin SS, Beam HA, Vieira P, Parsons JR. Low-intensity pulsed ultrasound increases the fracture callus strength in diabetic BB wistar rats but does not affect cellular proliferation. *J Orthop Res.* 2002;20(3):587-92.
20. Shakouri K, Eftekharsadat B, Oskuie MR, Soleimanpour J, Tarzami MK, Salekzamani Y, et al. Effect of low-intensity pulsed ultrasound on fracture callus mineral density and flexural strength in rabbit tibial fresh fracture. *J Orthop Sci.* 2010;15(2):240-4.
21. Otremski I, Iriga D, Edelstein S, Ornoy A, Newman R. Does laser irradiation effect fracture healing? *Med. Laser Appl.* 2004;19(3):146-9.
22. Oliveira DA, De Oliveira RF, Magini M, Zangaro RA, Soares CP. Assessment of cytoskeleton and endoplasmic reticulum of fibroblast cells subjected to low-level laser therapy and low-intensity pulsed ultrasound. *Photomed Laser Surg.* 2009;27(3):461-6.
23. De Oliveira RF, Oliveira DA, Monteiro W, Zangaro RA, Magini M, Soares CP. Comparison between the effect of low-level laser therapy and low-intensity pulsed ultrasonic irradiation *in vitro*. *Photomed Laser Surg.* 2008;26(1):6-9.