

GENICULATE ARTERY PSEUDOANEURYSM AFTER ARTHROSCOPIC KNEE SURGERY: TWO CASE REPORTS

EDGARD DOS SANTOS PEREIRA JUNIOR¹, LUIZ AURÉLIO MESTRINER¹, EDGARD DOS SANTOS PEREIRA², RICARDO PEREZ DOMINGUES², MARCOS PRADO ALVES CARDOSO²

ABSTRACT

Arthroscopy of the knee is a very safe surgical procedure, with relatively few complications. Here we present the cases of two patients submitted to arthroscopic surgery for partial meniscectomy and reconstruction of the anterior cruciate ligament with femoral transverse screw and tibial interference screw that developed a superior lateral genicular artery pseudoaneurysm. Doppler ultra-

sonography was performed for diagnostic purposes and the patients were treated by direct arterial suture. One patient developed a large haematoma requiring volemic replacement. These cases illustrate a rare, and not always benign vascular complication, in a minimally invasive arthroscopic surgery.

Keywords: Aneurysm, False. Knee. Arteries. Arthroscopy.

Citation: Pereira Junior ES, Mestriner LA, Pereira ES, Domingues RP, Cardoso MPA. Geniculate artery pseudoaneurysm after arthroscopic knee surgery: two case reports. *Acta Ortop Bras.* [online]. 2010; 18(2):104-6. Available from URL: <http://www.scielo.br/aob>

INTRODUCTION

Arthroscopy of the knee is one of the most common orthopedic procedures in the world, considered very safe, with an extremely low rate of general complications. Vascular complications are rare. Knee vascularization is comprised of two arterial systems integrated by anastomoses: The five genicular arteries added to some articular and muscular branches form the intrinsic system while the extrinsic system is formed by the descending genicular artery, a recurrent branch of the anterior tibial and a descending branch of the lateral femoral circumflex artery.

FIRST CASE REPORT

Male patient aged 20 years suffered a sprain of the left knee and underwent arthroscopic surgery for reconstruction of the anterior cruciate ligament (ACL) with autograft of the patellar tendon fixed on the femur and on the tibia with absorbable interference screws in 1999.

After five years he had a medical consultation due to instability during running. He had a positive Lachman test (+++), positive Jerk test (+++), positive anterior drawer (+++), and positive McMurray and Appley medial meniscus lesion. Nuclear magnetic resonance of the knee evidenced lesion to the neo-ligament and bucket-handle lesion of the left medial meniscus.

He underwent review of the anterior cruciate ligament (ACL) reconstruction with flexor tendons (gracile and semitendineous muscles) fixed on the femur with transversal screw and on the tibia with interference screw, both absorbable, associated with a metallic staple in the tibia in May 2005.

Eleven days after surgery the patient was attended with a history of clicking followed by acute pain on the lateral side of the knee close to the incision for passage of the transversal screw. He exhibited cutaneous-mucous paleness (+++) and taut edema on the lateral side of the thigh with hematoma that reached up to the posterior side of the knee. (Figure 1) Ultrasonographic exam with Doppler revealed extensive hematoma (about 1100 ml) on the thigh and superior lateral genicular artery pseudoaneurysm.

Surgical drainage of the hematoma was performed with ligation of the superior lateral genicular artery, which presented partial lesion in fraying. In the postoperative evaluation the hemogram revealed hemoglobin of 8.2 mg/dl (preoperative hemoglobin of 12.2 mg/dl). The patient received one unit of red blood cells and was discharged from hospital on the following day. (Figure 2)

In spite of the complication the patient evolved very well, with soundness in the knee. The patient returned to the same level of physical activity practiced before the knee injury, expressing satisfaction over the surgery.

All the authors declare that there is no potential conflict of interest referring to this article.

1 – Department of Orthopedics and Traumatology of Universidade Federal de São Paulo - UNIFESP

2 – Knee Surgery Group of the Department of Orthopedics and Traumatology of Universidade de Santo Amaro (UNISA).

Study conducted at UNIFESP and UNISA.

Mailing Address: Marcos Prado Alves Cardoso – Rua Rafael de Barros, 174, apartamento 21, Paraíso, São Paulo-SP. Brazil. CEP 04003-906

E-mail: marcos.pradocardoso@gmail.com

Article received on 01/04/09 and approved on 07/17/09

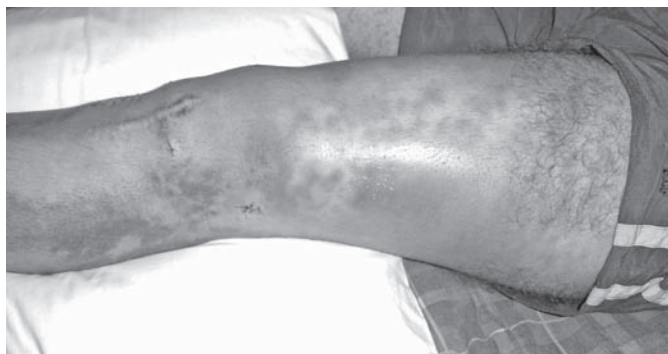


Figure 1 – Right lower limb demonstrating the extensive hematoma on the lateral side of the knee and thigh.

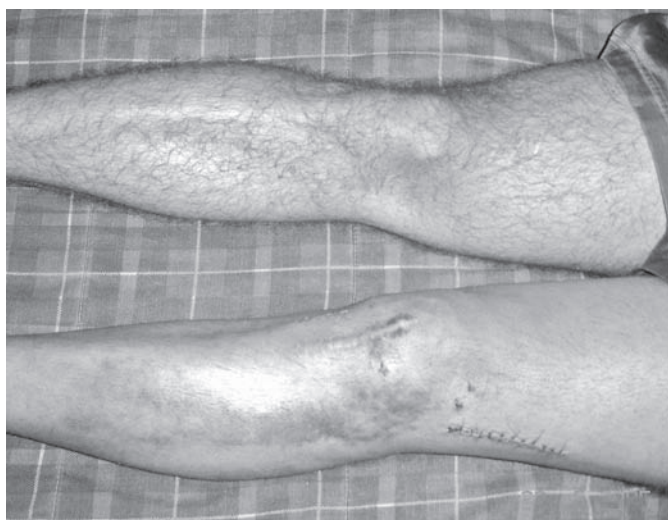

Figure 2 – Photography of the lower limbs demonstrating the surgical scar in the postoperative period of the ligation of the lateral superior genicular artery.

SECOND CASE REPORT

A 38-year-old man presented lesion of the anterior cruciate ligament and of the posterior horn of the medial meniscus six months ago occurring after a sprain of the right knee while playing soccer.

In January 2008 he underwent knee arthroscopy for partial meniscectomy and reconstruction of the anterior cruciate ligament with tendinous autograft of the gracile and semitendinosus muscle. The procedure was carried out under peridural anesthesia, and a tourniquet was applied. The femoral fixation of the graft was performed using a transversal screw introduced laterally and the tibial fixation using an absorbable interference screw. At the end of the procedure the suction drain was introduced, the incision was sutured and the compressive elastic bandaging was made. During the first day of hospitalization there were no complications and the drain was removed after 24 hours of evolution.

On the second day of hospitalization, the patient presented pain of progressive intensity on the lateral side of the knee in spite of cryotherapy and intravenous analgesia. The physician that performed the orthopedic evaluation verified the presence of distal pulse, of good peripheral perfusion and of absence of pain upon palpation

of all the compartments below the knee. The compressive elastic bandage was reviewed without pain improvement. On the same day it proved necessary to perform intravenous administration of powerful morphine-derived analgesics and a localized increase of volume was observed on the lateral side of the knee under the bandage, at the site of the lateral incision used for passage of the transversal screw that fixes the ligament graft at the top.

Arterial ultrasonography with colored Doppler was requested to evaluate vascular integrity, and evidenced a pseudoaneurysm (Figure 3) of the superior lateral genicular artery measuring 1.8 cm along its largest axis and with estimated volume of 0.9 cm³, associated with hematoma of 56 ml, close to the lateral incision used for passage of the femoral transversal screw.

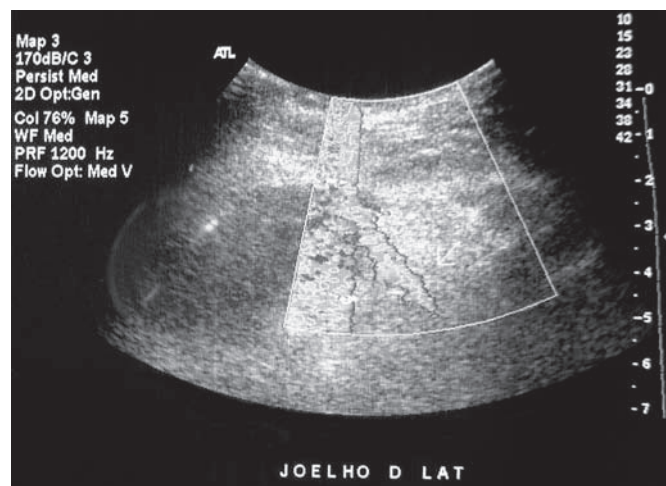


Figure 3 – Arterial ultrasonography of right lower limb with the presence of pseudoaneurysm on the lateral side of the knee.

The patient underwent surgical intervention for ligation of the lateral superior genicular artery. Aneurismatic dilation of the superior lateral genicular artery was observed four centimeters from the lateral side of the patella.

In spite of the complication, today, after two months of follow-up, the knee is painless and the patient has initiated the physiotherapeutic rehabilitation protocol normally without complaints.

DISCUSSION

Arthroscopy of the knee is a surgical procedure performed worldwide, considered extremely safe. Rates of complications range between 0.56% and 8.2%.^{1,2} The most frequent are hemarthroses, ecchymosises, hematomas, superficial infections and thromboembolic phenomena (profound venous thrombosis and pulmonary embolism). Traumatic vascular complications are rare (below 1%)³ and generally related to the popliteal artery.^{1,2,4}

There are many cases in literature reporting vascular complications after surgeries such as knee arthroplasty⁵ and osteosynthesis of fractures⁶ and a much lower number of reports of this type of complication after minimally invasive procedures such as arthroscopy and ligament reconstruction.⁷

Due to the small transversal diameter of the genicular arteries, lesions with complete section are more common than partial le-

sion. Thus the formation of hematomas or ecchymosises is more frequent than the aneurismatic dilation of these vessels.

There are various reports in literature describing pseudoaneurysm in the genicular arteries after arthroscopic procedure. In evaluating these reports we found 4 cases of pseudoaneurysms involving the medial inferior genicular artery (MIGA),⁸⁻¹¹ 1 case of pseudoaneurysm in the medial superior genicular artery (MSGA),¹² 4 cases in the lateral inferior genicular artery (LIGA),¹³⁻¹⁶ 5 cases in the popliteal artery^{16,17}, 1 case in the recurrent tibial artery (RTA),^{1,18} one case in the posterior tibial artery¹⁹ and one case in the sural artery.²⁰ We did not find in literature any case of pseudoaneurysm in the lateral superior genicular artery after arthroscopic procedure.

Pseudoaneurysm can appear clinically as a pulsatile mass^{9,10,12,16} close to the incision or simply as a localized increase of volume²¹ simulating hematoma.

In one of the cases reported the diagnosis occurred on the first days of postoperative evolution with the patient still in hospital,¹¹ but reviewing literature we observed that most times the diagnosis occurred between the first and the third week after surgery.^{8-10,19,20}

The lateral superior genicular artery runs laterally to the knee and does not ascend more than 1 centimeter proximal to the superior pole of the patella, becoming vulnerable in procedures that require

an incision in this region²¹ (release of the lateral retinaculum, osteosynthesis of the distal femur and reconstructions of the ACL with femoral transversal screw).

The treatment performed with surgical exploration and direct ligation of the vessel is considered gold standard,¹¹ but the repair of the arterial wall, compression guided by ultrasonography²⁰ and even selective embolization with catheter^{8,9,20} are described as therapeutic possibilities. When the lesion occurs in vessels of larger caliber, like in the popliteal artery, it is necessary to create an arterial bridge with vascular graft.⁸

Evaluating the reports found in literature we did not find cases of pseudoaneurysm associated with heavy bleeding with acute anemia and the need for volemic replacement or concentrate of red blood cells as occurred in the first case described.

CONCLUSION

We believe that in minimally invasive surgeries, in which the access route does not allow the exploration of the anatomical structures, a certain degree of suspicion permits an earlier diagnosis.

Although extremely infrequent, this pathology should be remembered as a surgical complication with potential risk to the life of the patient when associated with heavy bleeding.

REFERENCES

1. Committee on Complications of the Arthroscopy Association of North America. Complications in arthroscopy-the knee and other joints. *Arthroscopy*. 1986;2:256-8.
2. Small NC. Complications in arthroscopic surgery of the knee and shoulder. *Orthopedics*. 1993;16:985-8.
3. Delee J. Complications of arthroscopy and arthroscopic surgery: results of a national survey. *Arthroscopy*. 1985;1:214-20.
4. Beck DE, Robison JG, Hallett JW Jr. Popliteal artery pseudoaneurysm following arthroscopy. *J Trauma*. 1986;26:87-9.
5. Calligaro KD, Dougherty MJ, Ryan S, Booth RE. Acute arterial complications associated with total hip and knee arthroplasty. *J Vasc Surg*. 2004;39:628.
6. Bennett FS, Born CT, Alexander J, Crincoli M. False aneurysm of the medial inferior genicular artery after intramedullary nailing of the tibia. *J Orthop Trauma*. 1994;8:73-5.
7. Omary R, Stulberg SD, Vogelzang RL. Therapeutic embolization of false aneurysms of the superior medial genicular artery after operations on the knee. *J Bone Joint Surg Am*. 1991;73:1257-9.
8. Puig J, Perendreu J, Fortuño JR, Branera J, Falcó J. Transarterial embolization of an inferior genicular artery pseudoaneurysm with arteriovenous fistula after arthroscopy. *Korean J Radiol*. 2007;8:173-5.
9. Sarrosa EA, Ogilvie-Harris DJ. Pseudoaneurysm as a complication of knee arthroscopy. *Arthroscopy*. 1997;13:644-5.
10. Evans JD, de Boer MT, Mayor P, Rees D, Guy AJ. Pseudoaneurysm of the medial inferior genicular artery following anterior cruciate ligament reconstruction. *Ann R Coll Surg Engl*. 2000;82:182-4.
11. Lafontaine M, Khoury A. False aneurysm of the knee after arthroscopy. *Acta Orthop Belg*. 1997;63:215-7.
12. Carr JB, Jansson KA. An unusual case of vascular dysplasia related to knee arthroscopy. *Arthroscopy*. 2001;17:196-9.
13. Armato DP, Czamecki D. Geniculate artery pseudoaneurysm: a rare complication of arthroscopic surgery. *Am J Roentgenol*. 1990;155:659.
14. Guy RJ, Spalding TJ, Jarvis LJ. Pseudoaneurysm after arthroscopy of the knee: a case report. *Clin Orthop Relat Res*. 1993;(295):214-7.
15. Manning MP, Marshall JH. Aneurysm after arthroscopy. *J Bone Joint Surg Br*. 1987;69:151.
16. Milankov M, Mijlkovic N, Stankovic M. Pseudoaneurysm of the medial inferior genicular artery following anterior cruciate ligament reconstruction with hamstring tendon autograft. *Knee*. 2006;13:170-1.
17. Potter D, Morris-Jones W. Popliteal artery injury complicating arthroscopic meniscectomy. *Arthroscopy*. 1995;11:723-6.
18. Dinh A, Brunet AP, Maatouk M, Diebold S, Favoli P. Arterial complications of arthroscopic meniscectomies. Apropos of three cases. *Ann Chir*. 1993;47:547-52.
19. Aldrich D, Anschuetz R, LoPresti C, Fumich M, Pitluk H, O'Brien W. Pseudoaneurysm complicating knee arthroscopy. *Arthroscopy*. 1995;11:229-30.
20. Audenaert E, Vuylsteke M, Lissens P, Verhelst M, Verdonk R. Pseudoaneurysm complicating knee arthroscopy. A case report. *Acta Orthop Belg*. 2003;69:382-4.
21. Vialle R, Beddouk A, Cronier P, Fournier D, Papon X, Mercier P. Prevention of hemorrhagic complications in the lateral retinacular section of the patella. A study of the lateral arteries of the knee applied to the prevention of knee hemarthrosis. *Rev Chir Orthop Reparatrice Appar Mot*. 1997;83:665-9.