



0021-7557/08/84-02/171

Jornal de Pediatria

Copyright © 2008 by Sociedade Brasileira de Pediatria

ORIGINAL ARTICLE

The relationship between excursion of the diaphragm and curvatures of the spinal column in mouth breathing children

Liu Chiao Yi,¹ José R. Jardim,² Daniel Paganini Inoue,³ Shirley S. N. Pignatari⁴**Abstract**

Objective: To investigate the relationship between excursion of the diaphragm muscle and spinal curvatures in mouth breathing children.

Methods: A total of 52 children of both sexes, aged from 5 to 12 years, were studied. After otorhinolaryngological assessment, the children were divided into two groups: mouth breathers and nose breathers. All of the children underwent videofluoroscopic examination of the diaphragm muscle and postural assessment. Diaphragm excursion was analyzed using Adobe Photoshop[®] software, and postural assessment was recorded using photographs in left lateral view, which were then analyzed using SAPO postural assessment software.

Results: The groups studied exhibited statistically significant differences in terms of spinal curvatures (cervical lordosis: $p = 0.003$; lumbar lordosis: $p = 0.001$; thoracic kyphosis: $p = 0.002$; position of the pelvis: $p = 0.001$) and diaphragm excursion (right side diaphragm: $p = 0.001$; left side diaphragm: $p = 0.001$). The mouth breathing group exhibited reduced cervical lordosis, increased thoracic kyphosis, increased lumbar lordosis and the position of the pelvis was tilted forward. The distance traveled outwards by the diaphragm muscles of mouth breathing children was shorter than that traveled by the muscles of nose breathing children. The relationship between the behavior of spinal curvatures and diaphragm excursion had no statistical significance.

Conclusion: There was no relationship between spinal curvatures and diaphragm excursion in the groups studied here.

J Pediatr (Rio J). 2008;84(2):171-177: Mouth breathing, children, diaphragm muscles, spine.

Introduction

Respiration is the first vital function developed after birth, establishing itself as the organism's primary function. The nasal cavity has a fundamental role in respiratory physiology, filtering, heating and humidifying inspired air, ensuring that it arrives in the lungs at the ideal temperature, favoring correct oxygenation of the organism. The oral cavity only interferes in this process when inspired air is not sufficient, which is generally caused by nasal obstruction.¹

Nevertheless, mouth breathing children frequently present at the offices of pediatricians, allergy specialists and

otorhinolaryngologists. There are many factors which may result in mouth breathing, and allergic rhinitis is possibly the most common cause of chronic airway obstruction, affecting from 15 to 20% of the population, while hypertrophic palatine and pharyngeal tonsils are the second cause of mouth breathing.^{2,3}

Obstruction or narrowing of the pharyngeal air space has been associated with anterior displacement and extension of the position of the head, in order to rectify the airflow trajectory and facilitate influx of air to the lower respiratory tract. In such cases, the craniocervical angle has been observed to increase, with anterior displacement of the center of gravity.⁴

1. Fisioterapeuta. Doutora, Programa de Pós-Graduação em Otorrinolaringologia e Cirurgia de Cabeça e Pescoço, Universidade Federal de São Paulo (UNIFESP), São Paulo, SP, Brazil.

2. Professor livre-docente, UNIFESP, São Paulo, SP, Brazil.

3. Médico otorrinolaringologista, UNIFESP, São Paulo, SP. Fellowship em Otologia, UNIFESP, São Paulo, SP, Brazil.

4. Professora adjunta, chefe, Disciplina de Otorrinolaringologia Pediátrica, UNIFESP, São Paulo, SP, Brazil.

No conflicts of interest declared concerning the publication of this article.

Suggested citation: Liu CY, Jardim JR, Pignatari SS, Inoue DP. The relationship between excursion of the diaphragm and curvatures of the spinal column in mouth breathing children. *J Pediatr (Rio J)*. 2008;84(2):171-177.

Manuscript received Aug 29 2007, accepted for publication Jan 08 2008.

doi:10.2223/JPED.1771

The biomechanical relationship between the craniomandibular regions, cervical spinal, hyoid bone and airways is considered an indivisible unit. Mouth breathing causes both functional and anatomic problems and can lead to problems with the body's posture, as a result of the synergic manner in which muscles work and of the fact that they are organized in chains.⁵

Due to the increased nasal resistance suffered by mouth breathers, respiratory work is increased,^{6,7} the inspiratory accessory muscles are recruited and inspiratory movement becomes predominantly concentrated in the upper thorax. These muscles get their name from the fact that they are activated during exaggerated physical activity or when inspiratory effort is increased.

According to Hruska et al.,^{8,9} when inspiratory movement is predominantly in the upper thorax, it affects thoracoabdominal mechanics, affecting the position of the diaphragm and its zone of contact due to reduced intraabdominal pressure. This situation could then lead to development of thoracic deformities, such as elevation of the last ribs, displacement of the chest upwards and increased lumbar lordosis.

According to Benatti,¹⁰ the effectiveness of the diaphragm is dependent on the stability of the abdominal wall, which is responsible for supporting of the viscera during inspiration, and is also dependent on the stability of the paravertebral lumbar muscles, which is where the diaphragm meets the vertebrae. These muscles impede the whole chest from rising, which is an antagonistic synergic relationship.

Any functional relationship provokes a chain of alterations in the subjacent segments, i.e., throughout the articular and muscular components of the body. Every time that a muscle shortens, it draws together its extremities and, consequently, affects the bones to which it is attached, disorganizing other muscles which originate or are attached to the same bones, and so on, successively. A change at any level of the spine will result in compensation in neighboring curves.¹¹

Given the biomechanical complexity of posture, which make functional integration of many segments possible, it is possible to understand how, in the presence of an alteration to one biomechanical unit, postural control systems are modified and proximal or distal structural systems accommodate themselves to compensate.

To date, there are no studies in the literature that relate the behavior of spinal curvatures to diaphragm excursion in mouth breathing children. Knowledge of the amplitude of this muscle's excursion, associated with the behavior of the spinal curvatures, may be of use to guide the direction of physiotherapeutic rehabilitation.

The objective of this study was to investigate the relationship between diaphragm excursion and spinal curvatures in mouth breathing children.

Methods

A total of 52 children of both sexes, aged from 5 to 12 years, were studied. The nose breathing group (control) was made up of 22 children, 11 girls and 11 boys, from the Escola Paulistinha de Ensino Fundamental; the mouth breathing group was made up of 30 children, 12 females and 18 males, from the Mouth Breathers Center, run by the Pediatric Otorhinolaryngology Department at the Universidade Federal de São Paulo.

All procedures were approved in advance by the Medical Ethics Committee at the Universidade Federal de São Paulo, protocol number 6311/03. Parents received explanations about the procedures involved and the free and informed consent form.

Type of study: prospective; inclusion criteria: age 5 to 12 years, mouth breathing and free and informed consent form signed by guardian. Exclusion criteria: craniofacial malformations, musculoskeletal disease, orthopedic traumas, respiratory diseases and neurological diseases.

The children who comprised the control group underwent a selection process at the Escola Paulistinha de Ensino Fundamental, by means of exclusion of those whose lips did not seal, had a shortened upper lip and protruding lower lip or histories of signs and symptoms that provoke mouth breathing.

Clinical and otorhinolaryngological examination

All participants underwent anamnesis and otorhinolaryngological clinical examination in order to define the nose and mouth breather groups.

The otorhinolaryngological clinical examination consisted of the procedures described below.

- 1) Anterior rhinoscopy.** In order to detect the presence of obstructive factors, such as hypertrophy of inferior nasal turbinates;
- 2) Oroscopy.** To assess oral cavity abnormalities. The degree of palatine tonsil hypertrophy was defined according to criteria published by Brodsky¹²:
 - 0: the tonsils are located within the tonsillar fossa and do not obstruct the airway or oropharynx.
 - +1: the tonsils are located slightly out of the tonsillar fossa, with < 25% of the airway obstructed.
 - +2: the tonsils are immediately visible, causing 25 to 50% of the airway to be obstructed.
 - +3: the tonsils are obstructing 50 to 75% of the airway.
 - +4: the tonsils are obstructing more than 75% of the airway.
- 3) Otoscopy.** Presence of tympanic membrane retraction and/or liquid level in middle ear.

4) Nasofibroscopy. Carried out in order to assess nasal cavities, septal displacement and hypertrophy of turbinates and the nasopharynx, to determine the degree of pharyngeal tonsil hypertrophy in relation to the right and left side choanal space and measurement of palatine tonsils causing pharyngeal constriction.

The criteria for allergic rhinitis was the presence of symptoms such as coryza, nasal obstruction and sneezing with a positive prick test. We included patients with both allergic and non-allergic rhinitis.

The clinical examination was of fundamental importance for identification of the obstructive factor and to make appropriate treatment possible. However, the definition of "mouth breather" was based on clinical assessment.

Therefore, children were defined as mouth breathers if they exhibited mouth breathing during consultation, with confirmation from their guardian that they had been predominantly breathing through the mouth for the previous 6 months,¹³ in addition to at least one of the following findings: skeletal crossbite, high-arched palate, anterior open bite, shortened upper and protruding lower lips or lips that do not seal.¹⁴ Children were defined as nose breathers (controls) if the signs and symptoms described above were absent.

Videofluoroscopy examination

Examinations were carried out using a Medicor 750 B X-ray machine, with image intensification, a standard 525-line television system, at 60 hertz (Hz) and 2:1 interlace, from which images were transferred to video home system (VHS) tapes, using a Philco 7400 video/monitor.

A piece of metal measuring 0.1 cm wide and 2 cm long was attached to each nipple, allowing it to be seen on the recorded image and providing a measurement of the true displacement of the diaphragm for use in formulae.

Images were first recorded of diaphragm excursion on the right-hand side and then on the left-hand side. Four respiratory cycles were recorded at rest in the orthostatic position, in anteroposterior X-ray view; feet were maintained parallel and the arms were aligned with the body. Children were instructed to keep their eyes open, looking at the horizon, and no there was no verbal interference to correct posture. The children's trunks were bare and their abdomens were not compressed.

The respiratory cycle that exhibited the most harmonious movement out of the four recorded was chosen for analysis. Cycles were excluded if they included sudden movements of the trunk, such as coughing, sneezing, laughter, sudden starts or speech.

Analysis of diaphragm excursion

The following apparatus were used to analyze the distance traveled by the diaphragm: 1) a desktop computer with

a Pentium 4 3.6 gigabyte processor, a 200 GB hard disk, 1.0 GB RAM, a video card with 256 megabytes of dedicated memory and a Pinnacle[®] PRO ONE RTDV video capture card; 2) a Sony[®] 5800 SVHS video cassette recorder; 3) a Sony[®] TRINITRON 1351 video monitor; 4) a Sony[®] PVE 500 video controller. Two software packages were employed: 1) Adobe Premiere PRO[®] 6.5, for capturing moving images in digital format, and extracting selected frames; 2) Adobe Photoshop[®] 5.5, for analysis of the still images. The frames containing the highest and lowest points attained by the diaphragmatic cupola within a single respiratory cycle were superimposed, using the right-angle formed by a chosen vertebra as a fixed point of reference. The upper frame was made slightly transparent, allowing both images to be seen simultaneously. Lines were traced from the highest to the lowest point on the diaphragmatic cupola, allowing the distance traveled to be measured. The following formula was then applied in order to identify the true distance: $X = 2b/a$.

	true measurement (cm)	measurement on monitor (cm)
length of metal strip	2	a
displacement of the diaphragm	x	b

This is a simple equation, where the measurement of the piece of metal stuck to the patient's nipple, measuring 2 cm, is to the size of the same piece of metal as measured by Adobe Photoshop[®] as the true distance traveled by the diaphragm (x) is to the same distance measure by the software.

Postural assessment

Photographs

All subjects underwent postural assessment with the aid of a photograph taken in left lateral view, ensuring that the spinal curvatures were visible in sagittal profile.

Small balls of polystyrene were attached to specific anatomical points with double-sided tape at the: acromion, seventh cervical vertebra (C7), the tragus of the ear, seventh thoracic vertebra (T7), first lumbar vertebra (L1), anterior superior iliac spine (ASIS) and greater trochanters (Figure 1).

All participants were photographed wearing swimwear, barefoot, with feet together and parallel and, when necessary, hair was tied back to ensure the cervical region was visible. The volunteers were instructed to keep their eyes open looking at the horizon, and no there was no verbal interference to correct posture.¹⁵ A 1 m plumbline was hung on the left-hand side close to the participant.

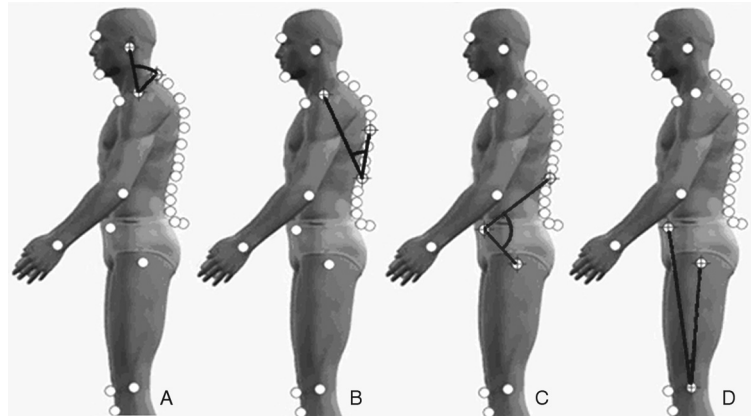


Figure 1 - Angular measurements of spine curvature: A) angular measurement of cervical lordosis; B) angular measurement of thoracic kyphosis; C) angular measurement of lumbar lordosis; D) angular measurement of position of the pelvis

Photographs were taken with the children in orthostatic positions, on a set of two steps, 42 cm high, 15 cm wide and 34 cm long, in front of a white wall as background. A Sony®Cyber Shot 2.0 mega pixel digital camera was fixed at 90° to horizontal in order to focus at the subject lengthways. This camera was positioned 4 m from the wall, on a 1.5 m high tripod and adjusted so that the lower horizontal guideline in the camera viewfinder corresponded with the horizontal line formed by the second step on which the patient was positioned.^{15,16}

Analysis of photographs

Postural analysis was carried out using the SAPO (Software para Análise Postural) postural analysis package.¹⁷ Analysis of photographs consisted of the following steps: open photograph, zoom to 40%, calibrate image based on plumline, mark the anatomic points on photograph.

Cervical lordosis was determined by drawing the angle formed by three anatomic points, the tragus of the ear, the acromion and C7, where the acromion was the apex of the angle. The larger this angle, the further forward the position of the head and the lower the degree of cervical lordosis.

In order to determine thoracic kyphosis, an angle was drawn from the acromion to L1 and from L1 to T7, where L1 was the apex of the angle. The larger this angle, the greater the degree of thoracic kyphosis.

Lumbar lordosis was measured using an angle drawn between three anatomic points: L1, anterior superior iliac spine (ASIS) and the greater trochanters, where ASIS was the apex of the angle. Here, the larger the angle, greater the degree of lumbar lordosis.

To determine the position of the pelvis, an angle was drawn between three anatomic points: the ASIS, the midpoint of the knee joint on the lateral face and the greater trochanters,

where the midpoint of the joint line was the apex of the angle. The greater the angle, the greater the pelvic tilt.

Results

Table 1 shows the relationship of the behavior of spinal curvatures and of the pelvis between the mouth breathing and nose breathing groups. All of the spinal curvatures and position of the pelvis exhibited different behavior in each of the two groups, with p values indicating statistical significance.

Table 2 shows the relationship of the behavior of spinal curvatures and position of the pelvis to diaphragm excursion in the mouth breathing group.

There was no correlation between diaphragm excursion and spinal curvatures or position of the pelvis in the mouth breathing group.

Discussion

Mouth breathers project their heads forwards to facilitate and accelerate airflow. The postural equilibrium of the head is the most important factor in achieving good posture.¹⁸ In our study it was observed that all spinal curvatures and the position of the pelvis behaved differently in the mouth breathing group from in the nose breathing group.

Our findings support to those of Ribeiro et al.,⁷ who evaluated the electrical activity of the upper fibers of the trapezoid and sternocleidomastoid muscles in mouth breathing and nose breathing children and concluded that mouth breathing children exhibit increased muscular activity in order to maintain the head and neck in an adequate position, thereby reducing airway constriction. Also agreeing with that study, Martucci et al.¹⁹ applied resistance to the airways of individuals free from respiratory disease and observed that the time taken for the respiratory act increased, since the musculature involved spends longer contracting due to the increased resistance,

Table 1 - Relationship between the behavior of spinal curvatures and position of the pelvis in the mouth breathing and nose breathing groups, while breathing at rest

Group	n	Mean (degrees)	Standard deviation (degrees)	p
Cervical lordosis				
Mouth breathers	30	60.36	9.54	0.003*
Nose breathers	22	52.27	8.58	
Lumbar lordosis				
Mouth breathers	30	102.52	9.67	0.001*
Nose breathers	22	119.84	5.35	
Thoracic kyphosis				
Mouth breathers	30	45.89	5.26	0.002*
Nose breathers	22	41.33	4.64	
Position of the pelvis				
Mouth breathers	30	9.98	1.49	0.001*
Nose breathers	22	6.93	1.00	

Student *t* test.* $p < 0.05$.**Table 2** - Relationship between the behavior of spinal curvatures and position of the pelvis and diaphragm excursion in the mouth breathing group, while breathing at rest

Variable pairs	Correlation coefficient	p
Cervical lordosis vs. right diaphragm	0.40	0.027*
Cervical lordosis vs. left diaphragm	0.34	0.066
Lumbar lordosis vs. right diaphragm	0.26	0.173
Lumbar lordosis vs. left diaphragm	0.19	0.311
Thoracic kyphosis vs. right diaphragm	0.10	0.594
Thoracic kyphosis vs. left diaphragm	-0.01	0.952
Position of pelvis vs. right diaphragm	-0.36	0.048
Position of pelvis vs. left diaphragm	-0.23	0.232

Spearman test.

* $p < 0.05$.

while the reduction in the expiratory period provides less time for recovery.

The increase in the craniocervical angle observed among the mouth breathing children in our study, which involves an extended head position and reduced cervical lordosis, was also found in studies by Vig et al.⁵ and Woodside & Linder-Aronson.²⁰ In these two studies mean posterior rotation of the cranium in relation to the cervical spine was 4.7 to 6.0 degrees, respectively. It is believed that the musculoskeletal changes generated by chronic nasal obstruction remain after resolution of the obstructing factor, due to the adaptations that have taken place in body segments.

Our results were similar to those reported by Yi et al.,²¹ who used postural assessment according to the method proposed by Kendall et al.²² and demonstrated a reduction in cervical lordosis and increased thoracic kyphosis in 80% of a sample of 176 mouth breathing children aged 5 to 12 years of age, while an increase in lumbar lordosis was observed in 60% of this sample and anterior pelvic tilt in 75% of them. However, in that study no nose breathing control group was employed in order to compare body segments. Furthermore, no tool was used that was capable of quantifying and analyzing in an objective manner the behavior of postural variables, in contrast with our study.

Krakauer²³ assessed body posture in mouth breathing and nose breathing children aged 5 to 12 years of age by means

Table 3 - Relationship between the behavior of spinal curvatures and position of the pelvis and diaphragm excursion in the nose breathing group, while breathing at rest

Variable pairs	Correlation coefficient	p
Cervical lordosis vs. right diaphragm	-0.35	0.113
Cervical lordosis vs. left diaphragm	-0.18	0.412
Lumbar lordosis vs. right diaphragm	0.12	0.59
Lumbar lordosis vs. left diaphragm	0.12	0.601
Thoracic kyphosis vs. right diaphragm	0.08	0.728
Thoracic kyphosis vs. left diaphragm	0.13	0.556
Position of pelvis vs. right diaphragm	0.07	0.751
Position of pelvis vs. left diaphragm	0.03	0.902

Spearman test.

* p < 0.05.

of the visual analysis of photographs. That study demonstrated that postural abnormalities were common in children aged 5 to 8 years of age in both groups. After 8 years of age these postural abnormalities were predominantly observed in the mouth breathing group. From the moment when children first become bipeds, up to approximately their fifth or sixth year of life, they undergo postural adaptations in order to achieve equilibrium under the action of gravity. We suggest that, concurrently with this phase, physiological postural adaptations that are the result of learning to walk are adjusted if mouth breathing continues. The postural imbalance that is triggered by this syndrome leads to musculoskeletal adaptations and may become progressive.

When there is significant nasal obstruction, there is an attempt to overcome this obstruction by conscious force, increasing inspiratory effort by means of the accessory muscles. This results in turbulent airflow, which encourages increased airway resistance and may lead to reduced tidal volume.^{18,24} Corroborating those studies, Song & Pae²⁵ found that contraction of the diaphragm is most efficient in the absence of upper airway obstructions, as in the case of nose breathing.

It was not possible to establish a correlation between diaphragm excursion and the behavior of spinal curvatures or position of the pelvis in the mouth breathing and nose breathing groups, with the exception of the results shown in Table 2, where statistical significance was detected for the pair of variables cervical lordosis vs. right diaphragm excursion; however, it is suggested that this figure was found by chance, since we consider it a peculiarity among the other variables which did not exhibit statistical significance.

We know that spinal curvatures and the position of the pelvis behaved differently in the two groups, however we believe it is impossible not to establish an interrelationship between

body segments in the presence of an isolated abnormality.^{10,11} It is suggested that more time is needed for musculoskeletal adaptations to exhibit a correlation between spinal curvatures and the position of the pelvis and diaphragm excursion; or that the impossibility of detecting a correlation was due to the possible presence of subsets with different behaviors in terms of spinal curvatures, pelvic tilt and diaphragm excursion, and that therefore the mouth breathing and nose breathing groups were not homogeneous.

Based on the results observed in this study, we conclude that there is no relationship between spinal curvatures and diaphragm excursion in the groups studied.

References

- Carvalho GD. Síndrome do respirador bucal ou insuficiente respirador nasal. *Rev Secret Saúde*. 1996;18:22-4.
- Lusvarghi L. Identificando o respirador bucal. *Rev APCD*. 1999; 53:265-73.
- Barros JR, Becker HM, Pinto JA. [Evaluation of atopy among mouth-breathing pediatric patients referred for treatment to a tertiary care center](#). *J Pediatr (Rio J)*. 2006;82:458-64.
- Solow B, Siersbaek-Nielsen S, Greve E. [Airway adequacy, head posture, and craniofacial morphology](#). *Am J Orthod*. 1984;86: 214-23.
- Vig PS, Showfety KJ, Phillips C. [Experimental manipulation of head posture](#). *Am J Orthod*. 1980;77:258-68.
- Ribeiro EC, Soares LM. [Avaliação espirométrica de crianças portadoras de respiração bucal antes e após intervenção fisioterapêutica](#). *Fisioter Brás*. 2003;4:163-7.
- Ribeiro EC, Marchiori SC, Silva AM. [Eletromiografia dos músculos esternocleidomastóideo e trapézio em crianças respiradoras bucais e nasais durante correção postural](#). *Arq Int Otorrinolaringol*. 2003;7:13-9.
- Hruska RJ Jr. [Influences of dysfunctional respiratory mechanics on orofacial pain](#). *Dent Clin North Am*. 1997;41:211-7.

9. Farah EA, Tanaka C. Postura e mobilidade da coluna cervical e do tronco em portadores de alterações miofuncionais orais. *Rev APCD*. 1997;51:171-5.
10. Benatti AT. [Equilíbrio tóraco-abdominal integrada à respiração e à postura](#). *Arq Ciências Saude UNIPAr*. 2001;5:87-92.
11. Souchard PH. *Respiração*. 3ª ed. São Paulo: Summus Editorial, 1989.
12. Brodsky L. [Modern assessment of tonsils and adenoids](#). *Pediatr Clin North Am*. 1989;36:1551-69.
13. Pizarro GU. Análise videofluoroscópica das fases oral e faríngea da deglutição em crianças respiradoras bucais com apnéia do sono [Dissertação]. São Paulo: Universidade Federal de São Paulo; 2003.
14. Liu CY. Relação entre a excursão do músculo diafragma e as curvaturas da coluna vertebral em crianças respiradoras bucais [Tese]. São Paulo: Universidade Federal de São Paulo; 2006.
15. Yi LC, Guedes ZC, Vieira MM. [Relação da postura corporal com a disfunção da articulação temporomandibular: hiperatividade dos músculos da mastigação](#). *Fisioter Bras*. 2003;4:341-7.
16. Watson AW. Procedure for the production of high quality photographs suitable for the recording and evaluation of posture. *Rev Fisioter USP*. 1998;5:20-6.
17. Duarte M, Maldonado EP, Freitas AZ, Ferreira EA, Prado J, Pasqual AP, et al. Software para Avaliação Postural. São Paulo: Universidade de São Paulo, 2006. <http://sapo.incubadora.fapesp.br>. Access: 30.07.2007.
18. Muto T, Yamazaki A, Takeda S, Kawakami J, Tsuji Y, Shibata T, et al. [Relationship between the pharyngeal airway space and craniofacial morphology, taking into account head posture](#). *Int J Oral Maxillofac Surg*. 2006;35:132-6.
19. Martucci RC, Lopes MJ, Jardim JR. Estudo da configuração tóraco-abdominal em indivíduos normais nas posições sentada e supina respirando livremente e através de resistência linear. *J Pneumol*. 1992;18:93-100.
20. Woodside D, Linder-Aronson S. [The channelization of upper and lower anterior face heights compared to population standards in males between ages 6 to 20 years](#). *Eur J Orthod*. 1979;1:25-40.
21. Yi LC, Guedes ZC, Pignatari SS, Weckx LL. Alteração da postura corporal em crianças respiradoras bucais. *Rev Fisioter Mov*. 2003;16:29-33.
22. Kendall FP, McCreary KE, Provence PG. *Músculos: provas e funções*. São Paulo: Manole; 1995.
23. Krakauer LR. Relação entre respiração bucal e alterações posturais em crianças: uma análise descritiva [Dissertação]. São Paulo: Pontifícia Universidade Católica de São Paulo; 1997.
24. Jardim JR. Fisiologia do sistema respiratório. In: Hirschheimer MR, Matsumoto T, Carvalho W, editores. *Terapia intensiva pediátrica*. São Paulo: Atheneu, 1989.
25. Song HG, Pae EK. [Changes in orofacial muscle activity in response to changes in respiratory resistance](#). *Am J Orthod Dentofacial Orthop*. 2001;119:436-42.

Correspondence:

Liu Chiao Yi
Av. Fagundes Filho, 574/141, Vila Monte Alegre
CEP 04304-000 - São Paulo, SP - Brazil
E-mail: liuchiaoyi@yahoo.com.br