

cagA Positive *Helicobacter pylori* in Brazilian Children Related to Chronic Gastritis

Luciano Lobo Gatti^{1,2}, Roger de Lencastre¹, Luiz Carlos da Silva³, Marília de Almeida Cardoso Smith² and Spencer Luiz Marques Payão¹

¹Hemocentro – School of Medicine of Marília, Department of Genetic and Molecular Biology, FAMEMA, Marília, São Paulo,;

²Department of Genetic, UNIFESP/EPM, São Paulo, SP;

³Department of Pathology, FAMEMA, Marília, São Paulo, Brazil

Helicobacter pylori is a spiral-shaped Gram-negative bacterium. It colonizes the gastric mucosa of humans and persists for decades if not treated. *Helicobacter pylori* infection affects more than half of the world's population and invariably results in chronic gastritis. The *cagA* gene is present in about 60 to 70% of *H. pylori* strains; it encodes a high-molecular-weight protein (120 to 140 kDa) and several investigators have noted a correlation between strains that possess *cagA* and the severity of gastric mucosal inflammation. We examined the relation between *cagA* status in *H. pylori* strains and chronic gastritis with inflammatory processes in children from Marília, São Paulo, Brazil. One-hundred-twenty-one children were analyzed histopathologically and by polymerase chain reaction (PCR) to detect *H. pylori* and *cagA*. We then looked for an association between *cagA* presence and inflammatory infiltration. Using histology and PCR, we found 47% *H. pylori* positive infection; 29 children were diagnosed with chronic gastritis, while 28 showed normal mucosa by histopathological analysis. *CagA* presence was genotyped in both groups, and an inflammatory infiltrate was studied in all infected children with chronic gastritis. We found *cagA* strains in 20 of 29 (69%) children with chronic gastritis and 18 of 28 (64%) with normal mucosa, demonstrating a strong relationship between the strains and the inflammatory process. We found a positive association between an inflammatory process associated with *H. pylori* of *cagA*+ strains and chronic gastritis development.

Key Words: *Helicobacter pylori* infection, *cagA*, inflammatory infiltrate.

Helicobacter pylori is a spiral-shaped Gram-negative bacterium. It colonizes the gastric mucosa of humans and persists for decades if not treated [1]. *Helicobacter pylori* infection affects more than half of the world's population and invariably results in chronic gastritis. The clinical results of this infection range from asymptomatic gastritis to peptic ulcers and gastric cancer [2]. The infection is mostly asymptomatic, and most of the infected population never manifests clinically significant conditions. However, some individuals develop diseases, such as peptic ulcers and mucosa-associated lymphoid tissue lymphoma [1,3,4]. Several studies suggest progressive gastric mucosal damage induced by this pathogen [5], since clinical symptoms of gastric disorders appear most frequently in adults, while *H. pylori* acquisition occurs in childhood [6].

However, the role of *H. pylori* in the genesis of gastric disorders in children and in adults is still controversial, since there is no specific clinical manifestation related to *H. pylori* infection and not all infected people develop gastric problems [7]. Host-pathogen interactions involving environmental, host and bacterial factors seem to contribute to the onset and

progression of gastric diseases.

Experience with other bacterial pathogens lead us to believe that *H. pylori* strain-specific factors may influence the pathogenicity of different *H. pylori*, such as vacuolating cytotoxin (VacA) and cytotoxin-associated protein (CagA), which have been identified [8-12].

Only 50% to 65% of *H. pylori* strains produce an 87kDa cytotoxin that induces vacuolation of HeLa or primary gastric epithelial cells *in vitro* [9,11,13]. Specific vacA genotypes were characterized by differences in the signal sequence and the middle region of the gene in isolates obtained from U.S. subjects [14,15]. A vacA signal sequence type s1, but not type s2, was closely associated with *in vitro* cytotoxin activity.

The *cagA* gene is present in about 60% to 70% of *H. pylori* strains; it encodes a high-molecular-weight protein (120 to 140 kDa) [9,16]. The *CagA* gene is a marker for the presence of a transposable element, the chromosome pathogenicity island (Cag PAI) of 40 kb, containing about 30 genes similar to the type IV secretion system acquired by *H. pylori* through horizontal transfer. The Cag PAI gene products have been shown to be involved in the induction of pro-inflammatory chemokines released by host cells [17,18]. Several investigators have noted a correlation between strains that possess *cagA* and the severity of gastric mucosal inflammation [19,20].

We evaluated the relation between *cagA* status and chronic gastritis with inflammatory process in children in Marília, São Paulo, Brazil.

Material and Methods

Patients, endoscopy and biopsies

The subjects included in this study consisted of 121

Received on 24 January 2006; revised 28 July 2006.

Address for correspondence: Dr. Luciano Lobo Gatti. Hemocentro – Faculdade de Medicina de Marília, Disciplina de Genética e Biologia Molecular. Rua Lourival Freire, nº. 240, Zip code: 17519-050 – Bairro Fragata. Marília – São Paulo – Brasil. FAX: (14) 3433-0148 Phone: (14) 3402-1855. E-mail: lobogatti@yahoo.com.br.

The Brazilian Journal of Infectious Diseases 2006;10(4):254-258.

© 2006 by The Brazilian Journal of Infectious Diseases and Contexto Publishing. All rights reserved.

consecutive child patients presenting recurrent abdominal pain (range 1-16 years, mean age 8.6) seen at the Marília School of Medicine Gastroenterology Outpatient Clinic of Pediatrics, in Marília, São Paulo, Brazil. After clinical evaluation, standard laboratory examination, x-ray and ultrasonography, all patients underwent upper-gastrointestinal endoscopy. Four biopsies were obtained from each patient from both the gastric antrum and the corpus. One corpus and one antrum specimen were used for each rapid urease test and DNA extraction, and two specimens of each were used for histological analysis.

Endoscopic forceps were sterilized in 2% glutaraldehyde solution for a minimum of 20 minutes between experiments. This study was approved by the institutional ethics committee, and written informed consent was obtained from the parents of all patients.

Rapid urease test and histology

One corpus and one antrum sample were used for a rapid urease test employing STAT-PAK®, following the manufacturer's instructions, and two corpus and two antrum samples were used for histopathological examination, including *H. pylori* detection using the updated Sydney System [21].

DNA extraction

DNA for PCR was extracted directly from one corpus and one antrum biopsy, using the QIAamp tissue kit provided by Qiagen.

Helicobacter pylori detection

PCR assays were performed with approximately 100µg of total DNA, using two different sets of oligonucleotides; one amplifies a 411 bp fragment, corresponding to the urease gene [22], and the other amplifies a 298bp fragment, corresponding to a gene encoding a 26kDa antigenic protein specific for *H. pylori* [23]. In each experiment, positive and negative controls were included (Figure 1A).

CagA genotyping

For *cagA* detection, primers *cag1/cag2* [31] and *cag3/cag4* [24] amplified fragments of 232 bp and 348 bp respectively (Figure 1B, C and D). Oligonucleotide sequences, and PCR conditions are described in Table 1.

Statistical methods

Statistical analysis was performed by the two-tailed χ^2 test and Fisher's exact test. Significance was set at < 0.05 .

Results

Detection of H. pylori presence in gastric mucosa by histopathological analysis and PCR

Fifty-seven children (47%) of 121 were positive for *H. pylori* presence in gastric mucosa by histopathological

analysis and by PCR. Twenty-nine children were diagnosed to have chronic gastritis and 28 had normal gastric mucosa.

The percentage of *H. pylori*-positive children with chronic gastritis was 51% (29 patients), while 49% of the children (28 patients) displayed normal mucosa.

cagA status and chronic gastritis

Twenty (69%) of 29 children with chronic gastritis and 18 (64%) of 28 children with normal mucosa showed *cagA*-positive strains. A significant association between children with chronic gastritis and *cagA* presence was observed ($P=0.041$). No significant association between *cagA* presence and score differences in mononuclear cell infiltration was observed.

cagA status and neutrophilic inflammatory activity in chronic gastritis

Twenty children were found to be infected with *H. pylori* *cagA*+, and 16 (80%) showed neutrophilic inflammatory activity on histological analysis (four with score 00 and 12 with score 01), while four (20%) did not have this activity ($P=0.032$, Figure 2).

Nine of 29 children with chronic gastritis were infected by *cagA*-negative *H. pylori*. Three of the nine children showed neutrophilic inflammatory activity histologically (two with score 01 and one with score 00) and six of the nine did not show this infiltrate. The difference was not significant.

Discussion

Studies suggest that infection with *cagA* positive *H. pylori* strains induces a marked inflammatory response, with a great density of polymorphonuclear cells in the gastric mucosa and high levels of serum tumor necrosis alpha-factor and gastrin, which are seen as markers of inflammation in *H. pylori* infection, when compared with the *cagA* negative strains [25].

The cytotoxin-associated gene *cagA* was the first gene found to be differentially present in *H. pylori* isolates; it is considered a marker for *cag* pathogenicity. In addition to other putative virulence properties encoded by the *cag* pathogenicity island, several genes of the island encode proteins that enhance the gastric inflammatory response to infection, such as interleukin-8.

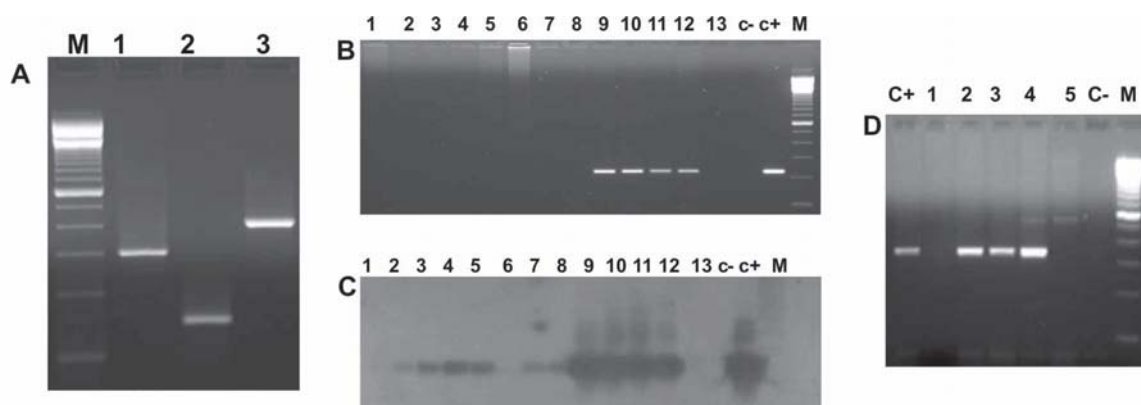
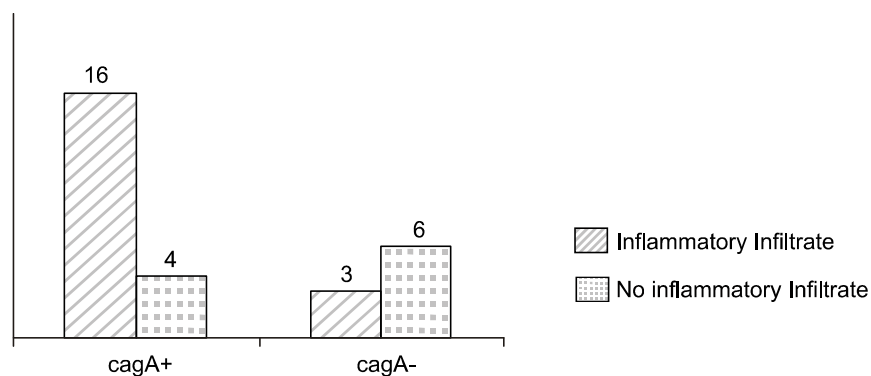
A high degree of polymorphonuclear infiltration for long periods of time may be a risk factor for carcinogenesis, since the oxidative burst produced by the disintegration of cells in the gastric mucosa liberates substances with mutagenic potential [26].

Demirturt et al. studied the association between *cagA* positive strains and histopathological findings in dyspeptic patients and found a significant association between severe inflammation and *cagA*-positive strains [27]. We found a strong association between *cagA* presence and polymorphonuclear infiltration in chronic gastritis ($P=0.032$).

Table 1. Oligonucleotides and PCR conditions

Primer	Sequence (5'-3')	Reference	PCR Condition
Cag1	ATGACTAACGAACTATTGATC	31	94°C 5', 40 cycles 94°C 1'/52°C 1'/72°C, 7'72°C
Cag2	CAGGATTTTTGATCGCTTTATT	31	
Cag3	GATAACAGGCAAGCTTTTGAGG	24	94°C 5', 40 cycles 94°C 1'/56°C 1'/72°C, 7'72°C
Cag4	CTGCAAAAGATTGTTTGCGAGA	24	
H3	TGGCGTGTCTATTGACAGCGAGC	22	94°C 5', 40 cycles 94°C 1'/60°C 1'/72°C, 7'72°C
H4	CCTGCTGGGCATACTTCACCATG	22	
H5	GCCAATGGTAAATTAGTT	23	94°C 5', 40 cycles 94°C 1'/43°C 1'/72°C, 7'72°C
H6	CTCCTTAATTGTTTTTAC	23	
Hp1.1	CTGGAGARACTAAGYCCTCC	32	94°C 5', 40 cycles 94°C 1'/59°C 1'/72°C, 7'72°C
HPX2	GAGGAATACTCATTGCGAAGGCCGA	32	

Figure 1A. 2% agarose gel after PCR amplification of *Helicobacter pylori* DNA detection using H3H4 primers (298 bp) (lane1); HP1.1/HPX2 primers (150 bp) (lane 2) and h5/h6 primers (411 bp) (lane 3); M,100 bp DNA Marker. **B.** 2% agarose gel after PCR amplification of *cagA* detection using cag1/cag2 primers (232 bp). Lanes 1-13. patients; C- negative control, C+ positive control and M = 100 bp DNA Marker. **C.** Autoradiograph after hybridization with a *cagA*-specific chemiluminescent probe. Lanes 2,3,4,5,7,8,9,10,11 and 12, positive strains after hybridization; Lanes 3 and 8, negative strains for *cagA* presence. C+ positive control. **D.** 2% agarose gel after PCR amplification of *H. pylori* DNA using cag3/cagA4 primer. Lanes C+, positive control, 1 and 5 negative strains and 2-4 positive strains for *cagA* presence. C-, negative control and M, 100 bp DNA Marker.

**Figure 2.** Association between *cagA*+ and inflammatory activity.

Frequency of inflammatory activity in children with chronic gastric problems in relation to *cagA*. * Significant difference (P=0.032).

This association was not observed in *cagA*-negative strains. Studies have shown that increased mucosal polymorphonuclear cell infiltration observed in patients infected with *cagA* positive strains is linked to enhanced interleukin-8 (IL-8) secretion by the gastric mucosa [17]. However, *cagA*-negative mutants that do not contain CagA protein are still able to induce enhanced IL-8 secretion, which raises the hypothesis that the *cagA* gene is not uniquely responsible for this ability [28].

Oliveira et al. (2003) found an association between *cagA* presence with more marked antral inflammation in duodenal ulcer and gastric carcinoma in Brazilian adults [29]. Ribeiro et al. (2003) studied Brazilian isolates and suggested that patients colonized with *cagA* positive *H. pylori* strains are at increased risk for developing peptic ulceration [30].

We did not find any association between *cagA*-positive strains and chronic gastritis, but 80% of patients with chronic gastritis were *cagA*-positive, suggesting that other bacterial factors are involved in disease generation. It may be that host factors, such as interleukin-1 polymorphism and *cagA* presence, are important for the development of gastric inflammatory process in *H. pylori* infection in children.

Of the 28 children with normal mucosa by histopathological analysis, 64% revealed a *cagA* positive infection, suggesting that these children had an initial infection by this bacterium. We will be following up on these children, because *H. pylori* is a chronic infection and can eventually develop into chronic gastritis and other gastric complications.

Acknowledgements

This work was supported by the Fundação de Amparo à Pesquisa do Estado de São Paulo (FAPESP, BRAZIL) grant numbers: 1998/15456-8, 2000/13996-7, a graduate student fellowship for LLG (FAPESP no. 2000/05590-0), and by the Faculdade de Medicina de Marília (FAMEMA).

References

- Blaser M.J. Ecology of *Helicobacter pylori* in the human stomach. *J Clin Invest* **1997**;100:759-62.
- Sipponem P., Hyvarinen H. Role of *Helicobacter pylori* in the pathogenesis of gastritis, peptic ulcer and gastric cancer. *Scand J Gastroenterol* **1993**;28:3-6.
- Marshall B.J. Unidentified curved bacilli on gastric epithelium in active chronic gastritis. *Lancet* **1983**;983:1273-5.
- Blaser M.J. Not all *Helicobacter pylori* strains are created equal: Should all be eliminated? *Lancet* **1997**;349:1020-2.
- Ernst P.B., Gold B.D. *Helicobacter pylori* in childhood: new insights for managing infection in children. *J Pediatr Gastroenterol Nutr* **1999**;28:462-73.
- Bonamico M., Mariani P., Magliocca F.M., et al. *Helicobacter pylori* duodenal colonization in children. **1997**;86:356-360.
- Gormally S.M., Prakash N., Durvin M.T., et al. Association of symptoms with *Helicobacter pylori* infection in children. *J Pediatr* **1995**;126:753-6.
- Covacci A.S., Censini M., Bugnoli R., et al. Molecular characterization of the 128-kDa immunodominant antigen of *Helicobacter pylori* associated with cytotoxicity and duodenal ulcer. *Proc Natl Acad Sci* **1993**;90:5791-5.
- Cover T.L., Dooley C.P., Blase M.J. Characterization of and human serologic response to proteins in *Helicobacter pylori* broth culture supernatants with vacuolizing cytotoxin activity. *Infect. Immun* **1990**;58:603-10.
- Crabtree J.E., Figura N., Taylor J.D., et al. Expression of 120 kilodalton protein and cytotoxicity in *Helicobacter pylori*. *J Clin Pathol* **1992**;45:733-4.
- Figura N.P., Guglielmetti A., Rossoline A., et al. Cytotoxin production by *Campylobacter pylori* strains isolated from patients with peptic ulcers and from patients with chronic gastritis only. *J Clin Microbiol* **1989**;27:225-6.
- Leunk R.D., Johnson P.T., David B.C., Kraft W.G., Morgan DR. Cytotoxin activity in broth-culture filtrates of *Campylobacter pylori*. *J Med Microbiol* **1998**;26:93-9.
- Cover T.L., Tummuru M.K.R., Cao P., et al. Divergence of genetic sequences for the vacuolating cytotoxin among *Helicobacter pylori* strains. *J Biol Chem* **1997**;269:10566-73.
- Atherton J.C., Cao P., Peek R.M., et al. Mosaicism in vacuolating cytotoxin alleles of *Helicobacter pylori*. *J Biol Chem* **1995**;270:17771-7.
- Atherton J.C., Peek R.M., Tham K.T., et al. Clinical and Pathological importance of heterogeneity in *vacA*, the vacuolating cytotoxin gene of *Helicobacter pylori*. *Gastroenterol* **1997**;112:92-9.
- Tummuru M.K.R., Cover T.L., Blaser M.J. Cloning and expression of a high-molecular-mass major antigen of *Helicobacter pylori*: evidence of linkage to cytotoxin production. *Infect Immun* **1993**;61:1799-809.
- Crabtree J.E., Covacci A., Farmery S.M., et al. *Helicobacter pylori* induced interleukin-8 expression in gastric epithelial cell is associated with *cagA* positive phenotype. *J Clin Pathol* **1995**;48:41-5.
- Huang J., O'Toole P.W., Doig P., Trust T.J. Stimulation of interleukin-8 in epithelial cell line by *Helicobacter pylori*. *Infect Immun* **1995**;63:1732-8.
- Blecker V., McKeithan T.W., Hant J., Kirchner B.R. Resolution of *Helicobacter pylori* associated gastric lymphoproliferative disease in a child. *Gastroenterology* **1995**;109:973-7.
- Queiroz D.M.M., Mendes E.M., Rocha G.A., et al. *CagA* positive *Helicobacter pylori* and risk for developing gastric carcinoma in Brazil. *Int J Cancer* **1998**;78:135-9.
- Dixon M.F., Genta R.M., Yardley J.H., Correa P. Classification and grading of gastritis: The update Sydney System. *Am J Surg Pathol* **1996**;20:1161-81.
- Clayton C.L., Kleanthoris H., Coates P.J., et al. Sensitive detection of *Helicobacter pylori* by using polymerase chain reaction. *J Clin Microbiol* **1992**;30:192-200.
- Hammar M., Tyszkiewicz T., Wadstrom T., O' Toole PW. Rapid detection of *Helicobacter pylori* in gastric biopsy material by polymerase chain reaction. *J Clin Microbiol* **1992**;30:54-8.
- Peek R.M., Miller G.G., Tham K.T., et al. Detection of *Helicobacter pylori* gene expression in human gastric mucosa. *J Clin Microbiol* **1995**;33:28-32.

25. Saruc M., Demir M.A., Kucukmetin N., et al. Histological and clinical predictive value of determination of tissue CagA status by PCR in *Helicobacter pylori* infected patients; results of the large population based study in western Turkey. *Hepatogastroenterology* **2002**;49:878-81.
26. Correa P. *Helicobacter pylori* and gastric carcinogenesis. *Amer. J Surg Pathol* **1995**;19(suppl.1):S37-S43.
27. Demirtürk L., Özel AM., Yazgan Y., et al. CagA status in dyspeptic patients with and without peptic ulcer disease in Turkey: Association with histopathologic findings. *Helicobacter* **2001**;6:163-8.
28. Sharma A.S., Tummuru M.K., Miller G.G., Blaser M.J. Interleukin-8 response of gastric epithelial cell lines to *Helicobacter pylori* stimulation *in vitro*. *Infect Immunology* **1995**;63:1681-7.
29. Oliveira A.G., Santos A., Guerra J.B., et al. *babA2* and *cagA* positive *Helicobacter pylori* strains are associated with duodenal ulcer and gastric carcinoma in Brazil. *J Clin Microbiol* **2003**;41:3964-6.
30. Ribeiro M.L., Godoy A.P.O., Benvenço Y.H.B., et al. Clinical relevance of the *cagA*, *vacA* and *iceA* genotypes of *Helicobacter pylori* in Brazilian clinical isolates. *FEMS Immunol Med Microbiol* **2003**;36:181-5.
31. Gatti L.L., Agostinho F.J., Labio R.W., et al. *Helicobacter pylori* and *cagA* and *vacA* gene status in children from Brazil with chronic gastritis. *Clin Med Exp Med* **2003**;3:166-72.
32. Scholte G.H.A., van Doorn L.J., Quint W.G.V., Linderman J. Polymerase Chain Reaction for detection of *Helicobacter pylori* in formaldehyde-sublimate fixed, paraffin-embedded gastric biopsies. *Diag Mol Pathol* **1997**;6:238-43.