

Glycine reduces tissue lipid peroxidation in hypoxia-reoxygenation-induced necrotizing enterocolitis in rats¹

Glicina reduz a peroxidação lipídica tecidual em enterocolite necrosante induzida por hipóxia-reoxigenação em ratos

Karine Furtado Meyer², José Luiz Martins³, Luiz Gonzaga de Freitas Filho⁴, Maria Luiza Vilela Oliva⁵, Francly Reis da Silva Patrício⁶, Maurício Macedo², Lina Wang⁷

1. Research developed in Surgery Department of Federal University of São Paulo (UNIFESP). Brazil.
2. MD, Fellow PhD degree Post-graduation Program in Experimental Surgery of UNIFESP. Brazil.
3. Associate Professor, Division of Pediatric Surgery, Surgery Department of UNIFESP. Brazil.
4. Affiliate Professor, Division of Pediatric Surgery, Surgery Department of UNIFESP. Brazil.
5. Associate Professor, Division Molecular Biology of Biochemistry Department of UNIFESP. Brazil.
6. Associate Professor, Division Medical Pathology, Pathology Department of UNIFESP. Brazil.
7. MD, Resident Pediatric Surgery, Public Servant Hospital of São Paulo (HSPE). Brazil.

ABSTRACT

Purpose: To assess the protective effect of glycine in an experimental model of Neonatal Necrotizing Enterocolitis (NEC). **Methods:** Fifty (50) neonatal Wistar rats, from a litter of six female rats and weighing 4 to 6 grams, were used. Five animals were cannibalized and the 45 remaining were distributed into three groups: the G1 normal control group (n=12); the G2 Group (n=16), of animals that underwent hypoxia-reoxygenation (HR); the G3 Group of animals (n=17) that underwent HR following a 5% intraperitoneal glycine infusion. The animals underwent hypoxia in a CO₂ chamber receiving an air flow of 100% CO₂ for 5 minutes and reoxygenation receiving an O₂ flow at 100% for 5 minutes. One centimeter long small bowel and colon segments were prepared for histological analysis. The rest of the bowel was removed in a block and frozen at minus 80°C for homogenization and determination of tissue malondialdehyde (MDA). Tissue lesions were classified as Grade 0 to Grade 5, according to the level of damaged mucosa. **Results:** The animals in Group G1 had levels of small bowel and colon lesion significantly smaller as compared to the animals in Groups G2 and G3. The G2 group had mean MDA values significantly higher than the animals in the G1 (p = .015) and G3 (p=0.021) groups. MDA values did not differ significantly (p = 0.992) for the animals in groups G1 and G3. **Conclusion:** Glycine reduces tissue MDA levels (a measurement of lipid peroxidation) following HR in neonatal rats.

Key words: Enterocolitis, Necrotizing. Glycine. Prevention & Control.

RESUMO

Objetivo: Avaliar o efeito protetor da glicina, num modelo experimental de ECN. **Métodos:** Foram utilizados 50 ratos Wistar recém-nascidos, com peso variando de 4 a 6 gramas, provenientes da ninhada de seis ratas. Cinco animais foram canibalizados e, os 45 restantes, foram distribuídos em três grupos: controle G1(n=12); G2(n=16), animais que foram submetidos à hipóxia-reoxigenação; G3(n=17), animais submetidos à hipóxia-reoxigenação após uma infusão intraperitoneal de glicina 5%. Os animais foram submetidos à hipóxia em uma câmara de CO₂ recebendo um fluxo de ar contendo 100% de CO₂ durante 5 minutos e à reoxigenação recebendo um fluxo de O₂ a 100% por 5 minutos. Segmentos de intestino delgado e cólon de 1 cm de extensão foram preparados para análise histológica. O restante do intestino foi removido em bloco e congelado a menos 80°C para homogeneização e dosagem de malondialdeído tecidual (MDA). Classificou-se as lesões teciduais de Grau 0 a Grau 5, de acordo com a extensão da lesão mucosa. **Resultados:** Os animais do Grupo G1 apresentaram graus de lesão de intestino delgado e cólon significativamente menores do que os animais dos Grupos G2 e G3. O grupo G2 apresentou valores médios de MDA significativamente maiores do que os animais do grupo G1 (p = .015) e G3 (p=0.021). Os animais dos grupos G1 e G3 apresentaram valores de MDA que não diferiram de forma significativa (p = 0.992). **Conclusão:** A glicina diminuiu os níveis de MDA intestinais (um marcador da peroxidação lipídica) em ratos neonatais submetidos à hipóxia-reoxigenação.

Descritores: Enterocolite Necrosante. Glicina. Prevenção & Controle.

Introduction

Despite significant advances in the care provided to high risk newborns, necrotizing enterocolitis (NEC) continues to be the most important cause of mortality and morbidity in low-birth-weight infants. NEC is the most common gastrointestinal emergency in neonatal intensive care units; approximately 5% of low-birth-weight infants end up by developing NEC¹. Most newborns that develop NEC receive parenteral nutrition and extended spectrum antibiotics; surgical indication is restricted to quite frequent complications, aiming in particular to act before intestinal perforations, responsible for the terrible evolution in those children. In such cases, surgical mortality can come to 45%².

The children that survive major resections of large portions of the bowel develop the well known short-bowel syndrome, whose morbidity in the end definitively compromises their weight and height development, with implications also in their neurological, psychic and motor development². Different hypotheses have been formulated to explain the origin of NEC. However it remains as a disease of unknown etiology and uncertain pathogenesis. Management is still based on empirical observations and no prevention method had shown to be fully successful¹. The combination of gastrointestinal ischemia, which is the outcome of a redistribution of the splanchnic blood flow to vital organs such as the heart and the brain, enteral nutrition that possibly predisposes to lesion of the mucosal layer, and the translocation of pathogenic bacteria, associated with immature immunitary mechanisms of the bowel, would be involved in the development of the disease¹.

Many animal models have been used in the assessment of hypoxia effects on the origin of NEC and shown that the reduced intestinal perfusion as well as tissue lesion would be caused by hypoxia-reoxygenation (HR) mechanism³⁻¹². Thus, several agents were used in an attempt to prevent intestinal lesions in NEC such as: mother's milk³, vitamin E⁹, supplementation with bifidobacteria¹¹ and recombinant human interleukin-10¹². Other agents were used seeking to attenuate the injuries caused by ischemia-reperfusion without, however, using NEC as an experimental model. Such was the case of: glucagon¹³, 21-amino-steroids¹⁴, pentoxifylline¹⁵, somatostatin¹⁶ and perfluorocarbons¹⁷. More recently, by using a model of HR in rats, glycine was put to the test as a protective agent of intestinal injuries stemming there from¹⁸⁻²⁰. Glycine is a non-essential simple amino acid formed by a carbon molecule bonded to an amino group and to a carboxyl group. On the plasmatic membrane, it brings into action a chlorine channel that either stabilizes or hyperpolarizes the membrane's potential. As a result, it blocks the additional intracellular calcium triggering the cytokines formation cascade²¹. Thus glycine has an anti-inflammatory, immune-modulator and cytoprotective effect. It protects against the shock caused by both hemorrhage and endotoxins, it prevents ischemia-reperfusion-associated injury in several organs and tissues such as the liver, kidney, heart, bowel and skeletal muscle and it reduces renal and liver injury caused by drugs²¹. Considering the anti-inflammatory, immune-modulator and cytoprotective effects of glycine, we sought to assess its capacity to prevent

intestinal injuries caused by hypoxia-reoxygenation in a previously described experimental model of NEC⁹.

Methods

Experimental design

The animal experiment was approved by the Bioethical Committee in Research from Federal University of São Paulo (UNIFESP) under number 0560/04.

Fifty (50) neonatal OUT B EPM-1 Wistar rats (*Rattus norvegicus albinus, Rodentia mamalia*), from a litter of six female rats and weighing 4 to 6 grams, were used. Five animals were cannibalized and, the forty-five remaining ones were randomized into three groups: the normal control G1 Group (n=12); the G2 Group (n=16), with animals undergoing hypoxia-reoxygenation (HR); the G3 Group (n=17), with animals undergoing HR following a glycine intraperitoneal infusion. The animals underwent hypoxia in a rodents CO₂ kill chamber where they received an air flow containing 100% CO₂ for 5 minutes. Following hypoxia the animals were resuscitated with an air flow containing O₂ at 100% for 5 minutes and then kept close to their respective mothers in a normothermic environment^[9]. All animals were given breast milk before and after the procedure. In Group 3 animals 0.2 ml of 5% glycine solution in saline solution was used.^{19,20} The glycine injection was administered 30 minutes prior to hypoxia-reoxygenation and it was maintained once a day until the animals' euthanasia. All animals underwent euthanasia by decapitation on day four of life.

Intestinal fixation and tissue processing

One centimeter-long small bowel (ileum) and colon samples were prepared for histological analysis. The rest of the bowel was then removed in a block and immediately frozen at minus 80°C for subsequent homogenization and measurement of tissue Malondialdehyde (MDA).

Histopathological examination

The one centimeter specimens were fixed in 10% formalin, dehydrated, embedded in paraffin and stained with hematoxylin and eosin. Six micrometer sections were made in each specimen, analyzed under optical microscopy and graded according to the extent of the tissue lesion, according to Chiu et al²², as: **Grade 0:** mucosa with no alterations (Figure 1). **Grade 1:** well formed villi, with no cell lyses or inflammatory process, however with formation of Grunhagen's subepithelial space (Figure 2). **Grade 2:** presence of cell lyses, formation of Grunhagen subepithelial space and increased spacing between villi (Figure 3). **Grade 3:** destruction of the villi free portion, presence of dilated capillary and inflammatory cells (Figure 4). **Grade 4:** structural destruction of villi, which in some cases appeared only roughly and formed by inflammatory cells and necrotic material, with bleeding and basal glandular ulceration (Figure 5). **Grade 5:** destruction of the entire mucosal tunic, with no glandular structure found, but only amorphous material deposited on the submucosal layer (Figure 6).

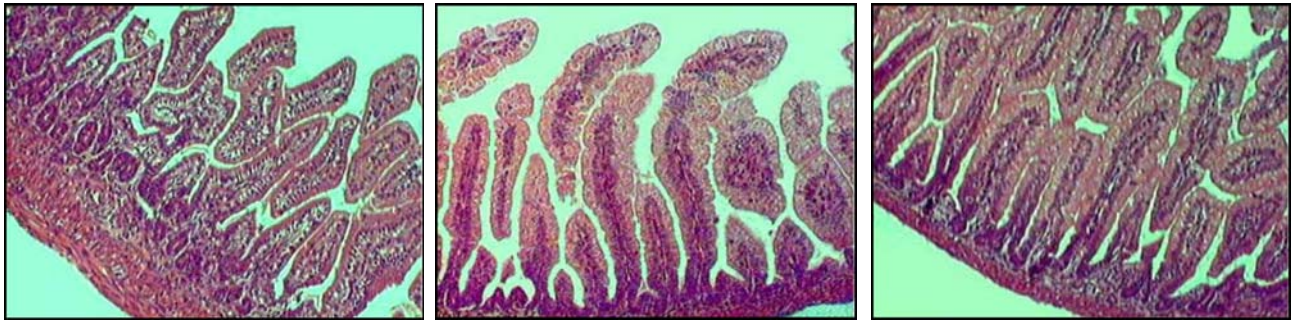

FIGURE 1 - Microscopic appearance of the ileum from a rat showing mucosa with no alterations

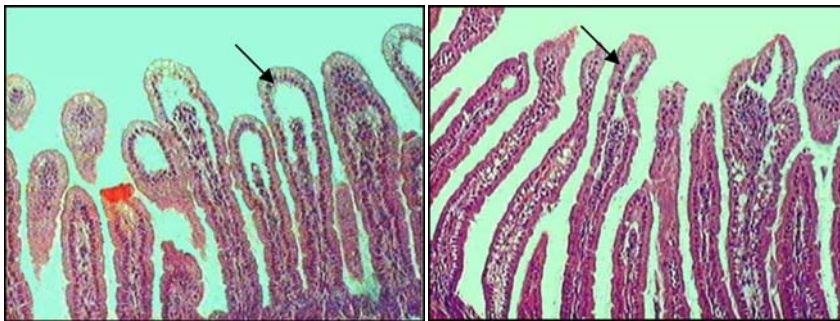


FIGURE 2 - Microscopic appearance of the ileum from a rat showing well formed villi, with no cell lyses or inflammatory process, however with formation of Grunhagen's subepithelial space

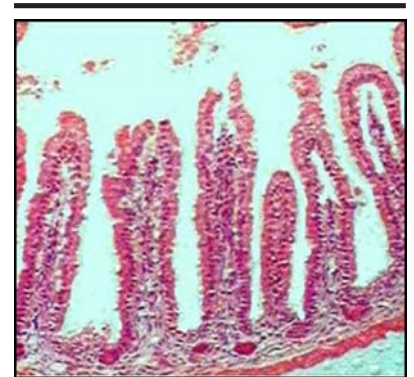


FIGURE 3 - Microscopic appearance of the ileum from a rat showing presence of cell lyses, formation of Grunhagen subepithelial space and increased spacing between villi

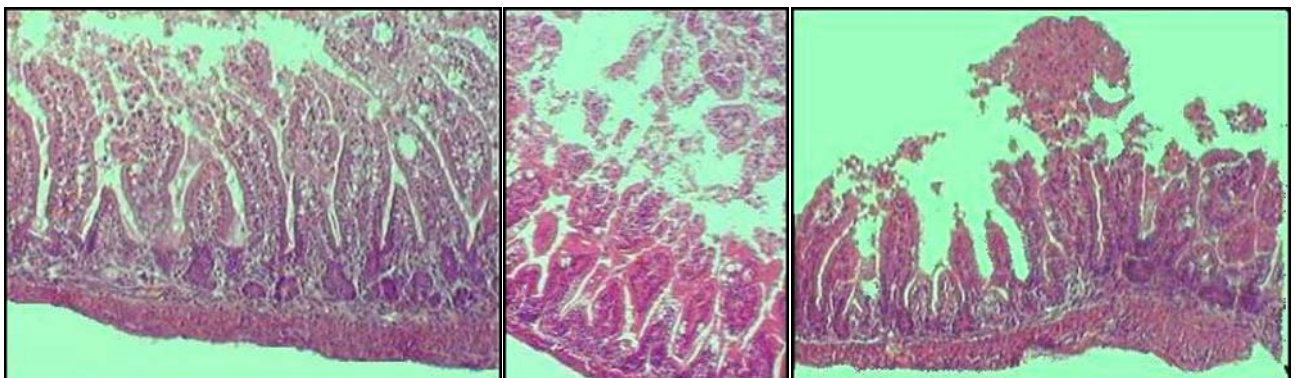


FIGURE 4 - Microscopic appearance of the ileum from a rat showing destruction of the villi free portion, presence of dilated capillary and inflammatory cells

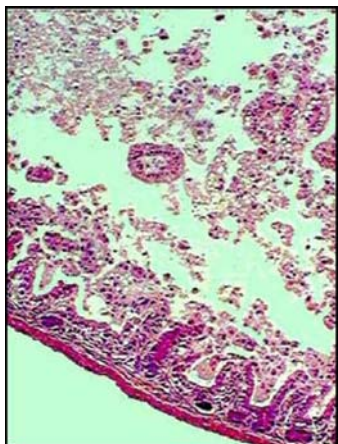


FIGURE 5 - Microscopic appearance of the ileum from a rat showing structural destruction of villi, which in some cases appeared only roughly and formed by inflammatory cells and necrotic material, with bleeding and basal glandular ulceration

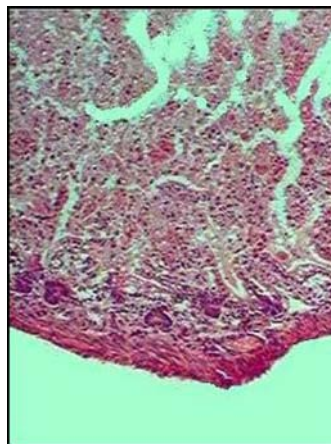


FIGURE 6 - Microscopic appearance of the ileum from a rat showing destruction of the entire mucosal tunic, with no glandular structure found, but only amorphous material deposited on the submucosal layer.

Determination of malondialdehyde

Malondialdehyde (MDA) is a final product of lipid peroxidation and a well established parameter to determine the increase of free radicals in the bowel tissue¹². In order to determine MDA levels the thiobarbituric acid method (TBA), proposed by Kohn and Liversedge²³ was used and the levels were expressed in nmol MDA/mg of protein. The protein content of the homogenate was determined by the "coomassie brilliant blue" (CBB) procedure. Tissue samples were defrosted, duly weighed, and a volume equivalent to 5 times the weight of TRIS 0,01M/pH 7.4 buffer solution was then added. Tissue samples were homogenized in ice bath 4 times, for 30 seconds each and, subsequently, centrifuged for 5 minutes at 10.000 rpm at 4°C.

Protein measurement

The CBB reactant interacts with protein enabling its quantification by using a standard albumin curve with known concentrations.

Preparation of the CBB reactant

CBB 250G, 100 mg, was dissolved in 50 ml of 95% ethanol. 100 ml of 85% phosphoric acid was added and constantly stirred. Distilled water for a final 1 liter volume was added. The reactant was let to rest for 24 hours and then it was filtered and kept in a dark vial. By using a bovine serum albumin (BSA) 10 mg/ml stock solution, we prepared 200 μ l of the following solutions: 0.1 mg/ml, 0.2 mg/ml, 0.4 mg/ml, 0.8 mg/ml and 1 mg/ml (bovine serum albumin/ml of water) to have the bovine serum albumin standard curve (standard curve for protein measurement). Homogenate 25 μ l and 50 μ l was collected, and then diluted in 5 times a TRIS 0,01M/pH 7.4 buffer; 2.5 ml of the CBB was added and readings were taken at 595 nm, 10 min after the CBB reactant was added.

Malondialdehyde measurement

Four hundred (400 μ l) of the centrifuged homogenate supernatant was collected and the following was added to it: 1 ml of 20% trichloroacetic acid and 400 μ l of 1.6% thiobarbituric acid, mixture that was incubated for 30 minutes at 95°C. Lipids were extracted by adding n-butanol (1.6 ml) and stirring vigorously. The sample was again centrifuged for 10 minutes at 3000 rpm. Absorbance of the organic layer was determined through reading at 510, 532, and 560 nm. The following equation proposed to minimize the interference of both heme pigments and hemoglobin in the measurement of MDA²⁵ was used :

$$MDA_{532} = 1,22[(A_{532}) - (0,56)(A_{510}) + (0,44)(A_{560})]$$

The calibration curve was drawn with 1,3,3 tetra-methoxypropane malondialdehyde bis (acetyl-dimethyl).

Statistical analysis

The quantitative variables were represented by mean, standard error (SE), minimum and maximum and the qualitative variables were represented by absolute (n) and relative (%) frequencies. The Kolmogorov-Smirnov test was applied to test the normal distribution of the parameters. One Way Analysis of Variance (ANOVA) was performed to compare the study groups as for nmol/mg of protein and nmol/mg of tissue. The differences were found through the Tukey multiple comparison test. The Kruskal-Wallis test was used in analyzing the extent of tissue injury in the three sites assessed. The differences were found under the Dunn multiple comparison test. We set $p < 0.05$ as the significance level for all the tests, represented by *.

Results

Histopathology

The animals in the G1 Group showed ileum lesion scores significantly lower as compared to the animals in the G2 and G3 Groups that showed no significant differences among one another as can be seen in Table 1. The G1 Group animals had colon lesion scores significantly lower as compared to the G2 and G3 Groups that did not differ significantly among one another as can be seen in Table 1.

TABLE 1 - Scores of tissue lesion of the Ileum and colon

	Ileum	Colon
G1	10,92*	13,17*
G2	31,16	29,19
G3	23,85	24,12

Values represent mean of scores

*p < 0.001

Malondialdehyde

The groups' MDA levels are shown in Table 2.

TABLE 2 - Tissue MDA (nmol/mg of Protein)

Group	N	Mean ± SE
-G1	12	1.0539 ± 0.1419*
-G2	16	2.6007 ± 0.4677*
-G3	17	1.1090 ± 0.1620*

Values represent mean + SE

*p < 0,05

A statistically significant difference was found among the groups studied in regard to Malondialdehyde mean values ($p = .002$)

The G2 Group had malondialdehyde mean values significantly higher in relation to the G1 Group ($p = 0.015$) and also higher than the animals in the G3 Group ($p = 0.021$).

The animals in the G1 and G3 Groups showed levels of no significant difference ($p = 0.992$)

Discussion

Neonatal necrotizing enterocolitis is the most frequent and lethal disease affecting the gastrointestinal tract of preterm infants. Although the etiology of NEC has not been well defined yet, hypoxia definitely plays an important role in its pathogenesis³⁻¹². Several animal models have been proposed to show the relevance of hypoxia in the development of NEC-associated lesions³⁻¹². Barlow and Santulli^{3,5} promoted intestinal lesion in neonatal rats fed on artificial milk, by putting the animals in a plastic bag for 3 to 5 minutes a day. Harrison et al⁴ showed early alterations in the intestinal mucosa and in the endothelial capillary cells under electronic microscopy in neonatal dogs exposed to 7% O₂ hypoxia for two hours. Hansbrough et al⁶, using

neonatal dogs, promoted intestinal ischemic necrosis by producing hypoxia with 10% O₂ for 2 hours. Cohen et al⁷ exposed neonatal pigs to a partial 50% O₂ pressure, achieving microscopic and macroscopic evidence of NEC. Caplan et al⁸ described a NEC model by feeding the animals on an artificial formula and asphyxiating them for 60 seconds with 100% Nitrogen twice a day followed by cold exposure. Other investigators were also able to show ischemic lesion of the intestinal mucosa in a model similar to the one used in this paper^{9,10,12}.

One of the reasons accepted to explain hypoxia-associated lesions would be that neonatal asphyxia would lead to a redistribution of the blood flow by triggering splanchnic vasoconstriction, diverting the flow to vital organs such as the heart and the brain and causing intestinal ischemia⁵. Several mechanisms are involved in the onset and progression of this ischemia-associated lesion, such as: increased production of hyper reactant peroxides, increased synthesis of adhesion molecules with neutrophils infiltration, increased lipid peroxidation and increased production of inflammatory mediators such as cytokines²⁵. Several techniques have been used in an attempt to use NEC attenuating or preventive agents. Mother's milk, unlike artificial milk formulas, could prevent the development of NEC³. Vitamin E, in the 30 IU/Kg/day dose⁹ and recombinant human interleukin, in the 75 µg/Kg dose¹² could reduce lipid peroxidation and histopathological lesion in the intestinal tissue of neonate rats. Supplementation with bifidobacteria could reduce the risk of NEC by reducing the level of plasma endotoxins and intestinal phospholipase A₂¹¹. The use of nitric oxide has already been tested in NEC models also, resulting in reduced intestinal inflammatory reaction²⁶. Agents such as glutamine and dexamethasone also showed some effect by reducing intestinal inflammatory reaction²⁷.

Glycine is a non-essential amino acid that protects the gut against lesions caused by the ischemia-reperfusion phenomenon^{18-20,28}. It is considered an anti-inflammatory, immune modulator agent of direct cytoprotective function²¹. Lee et al¹⁹, in a model of intestinal ischemia and reperfusion, showed that local 20% glycine mesenteric intravenous infusion increased mucosal protein and DNA content, reduced the intestinal myeloperoxidase activity and maintained glutaminase activity in the mucosa. Another two studies^{19,20}, also in an intestinal HR model in rats, showed the protective effect of glycine used in systemic intravenous infusion, by reducing the apoptosis cascade¹⁹ and preserving the integrity and contractility of the intestinal wall²⁰. In the present study, the rats received 1,7 a 2,2 mg glycine per gram body weight. There are reports that recognized the dose to prevent intestinal lesions due ischemia-reperfusion is 0,5-3 mg glycine per gram body weight¹⁸⁻²⁰.

Lipid peroxidation is a complex process that can occur in biological membranes that are made up of molecular oxygen-reactant polyunsaturated fatty acids, leading to the production of lipid hydroperoxides and their metabolites. Most cases involving lipid peroxidation start from a chain reaction that spreads out, mediated by the presence of free

radicals. Lipid hydroperoxides accumulate in the membrane inactivating its receptors and enzymes, affecting its functions, leading it to be unstable and making it permeable to ions. A simple method of high sensitivity, very much used as a lipid peroxidation marker, involves thiobarbituric acid-reactive substances, such as lipid hydroperoxide derivatives. Hence, Malondialdehyde (MDA) is a quite adequate indicator of lipid peroxidation caused by free radicals¹⁰.

By using the NEC model proposed by Okur et al⁹, we sought to assess the protective effect of glycine used through the intraperitoneal route. The model used in the experiment proved to be useful, easily reproduced, requiring the administration of no enteral formulae. An important limitation that had already been previously shown¹⁰, however, was the slight histological alteration found in the different groups. According to Kallakuri et al²⁰ involvement of the lesion beyond the mucosal layer would be necessary for the protective effect of glycine to be possibly assessed. Özkan et al²⁹ proposed, by using the same model, to have the animals undergoing repeated periods of HR, which would cause more marked intestinal lesions. In our experiment the animals undergoing HR, not previously taking glycine infusion, tended to show histological lesions more important than the animals in the other two groups: no injury to very mild injury (grade 0-1) was 12.6% in the HR group but was 41% in glycine-treated group. Moderate injury (grade 2-3) was ~63% in the HR group but was 47% in glycine-treated group. Severe injury (grade 4-5) was 25% in the HR group but was decreased to 12% in glycine-treated group. Similar phenomenon or even more obvious tendency is observed in the colon (severe injury was decreased from 25% to 6%), even though no statistical difference was shown among the groups. Our findings were similar to the ones reported by Lee et al¹⁸, where glycine did not change histological lesions but diminished intestinal myeloperoxidase activity and maintained mucosal glutaminase activity.

Kallakuri et al²⁰ showed that glycine did not prevent the mucosal cover decrease, but kept the full thickness of the wall and the circumference radius of the villi. MDA levels, however, showed that glycine has been able to prevent lipid peroxidation. The group undergoing HR had mean MDA values significantly higher than those in the group undergoing HR despite previously protected by the use of glycine ($p = .021$). The absence of difference between the control group and the group that used glycine ($p = 0.992$) showed that the level of protection provided by glycine was so important that it provided a peroxidation level similar to that of normal control rats. Intestinal lesion in NEC not only causes damage to the organ affected, but also, by triggering the release of inflammatory mediators into the blood stream, but it can also lead to the dysfunction and failure of multiple organs³⁰.

It remains to be known to what extent such findings can actually benefit infants with NEC, and finding the dose capable of changing the history of this disease that still claims for so many lives among low birth weight infants.

Conclusion

Glycine reduces tissue malondialdehyde (MDA) levels (a measurement of lipid peroxidation) following hypoxia-reoxygenation (HR) in neonatal rats.

References

1. Kliegman RM, Walker A, Yolken RH. Necrotizing enterocolitis. Research agenda for a disease of unknown etiology and pathogenesis. *Clin Perinatol*. 1994;21:437-55.
2. Ladd AP, Rescorla FJ, West KW, Scherer LR 3rd, Engum SA, Grosfeld JL. Long-term follow-up after bowel resection for necrotizing enterocolitis: Factors affecting outcome. *J Pediatr Surg*. 1998;33:967-72.
3. Barlow B, Santulli TV, Heird WC, Pitt J, Blanc WA, Schullinger JN. An experimental study of acute neonatal enterocolitis; the importance of breast milk. *J Pediatr Surg*. 1974;9:587-94.
4. Harrison MW, Connell RS, Campbell JR, Webb MC. Microcirculatory changes in gastrointestinal tract of the hypoxic puppy: an electron microscope study. *J Pediatr Surg*. 1975;10:599-608.
5. Barlow B, Santulli TV. Importance of multiples episodes of hypoxia or cold stress on the development of enterocolitis in an animal model. *Surgery*. 1975;77:687-90.
6. Hansbrough F, Priebe CJ Jr, Falterman KW, Bornside GH, Welsh RA. Pathogenesis of early necrotizing enterocolitis in the hypoxic neonatal dog. *Am J Surg*. 1983;145:169-75.
7. Cohen IT, Nelson SD, Moxley RA, Hirsh MP, Couihan TC, Martin RF. Necrotizing enterocolitis in a neonatal piglet model. *J Pediatr Surg*. 1991;26:598-601.
8. Caplan MS, Hedlund E, Adler L, Hsueh W. Role of asphyxia and feeding in a neonatal rat model of necrotizing enterocolitis. *Pediatr Pathol*. 1994;14:1017-28.
9. Okur H, Küçükaydin M, Köse K, Kontas O, Dogan P, Kazez A. Hypoxia-induced necrotizing enterocolitis in the immature rat: the role of lipid peroxidation and management by vitamin E. *J Pediatr Surg*. 1995;30:1416-9.
10. Kazez A, Küçükaydin N, Küçükaydin M, Kontas O, Okur H, Dogan P. A model of nti-in-induced necrotizing enterocolitis: the role of distension. *J Pediatr Surg*. 1997;32:1466-9.
11. Caplan M, Miller-Catchpole R, Kaup S, Russel T, Lickerman M, Amer M, Xiao Y, Thomson R Jr. Bifidobacterial supplementation reduces the incidence of necrotizing enterocolitis in a neonatal rat model. *Gastroenterology*. 1999;117:577-83.
12. Öztürk H, Dokucu AI, Ögün C, Büyükbayram H. Protective effects of recombinant human interleukin-10 on intestines of hypoxia-induced necrotizing enterocolitis in immature rats. *J Pediatr Surg*. 2002;37:1330-3.
13. Gangadharan SP, Wagner RJ, Cronenwett JL. Effect of intravenous nti-infl on intestinal viability after segmental mesenteric ischemia. *J Vasc Surg*. 1995;21:900-8.
14. Park PO, Gerdin B, Haglund U. Effects of a novel 21 aminosteroid or methylprednisolone in experimental total intestinal ischemia. *Arch Surg*. 1994;129:857-60.
15. Mustafa NA, Yandi M, Albayrak L, Yildiz K. Effects of

- pentoxifylline on the ischemia-reperfusion injury of the intestine. *Int Surg*. 1995;80:152-5.
16. Morris JB, Guerrero NH, Furth EE, Stellato TA. Somatostatin attenuates ischemic intestinal injury. *Am J Surg*. 1993;165:676-80.
 17. Ricci JL, Sloviter HA, Ziegler MM. Reduction of mortality utilizing intraluminal perfluorochemicals. *Am J Surg*. 1985;149:84-90.
 18. Lee MA, McCauley RD, Kong SE, Hall JC. Influence of glycine on intestinal ischemia-reperfusion injury. *J Parenter Enteral Nutr*. 2002;26:130-5.
 19. Jacob T, Ascher E, Hingorani A, Kallakuri S. Glycine prevents the induction of apoptosis attributed to mesenteric ischemia/reperfusion injury in a rat model. *Surgery*. 2003;134:457-66.
 20. Kallakuri S, Ascher E, Pagala M, Gade P, Hingorani A, Scheinman M, Mehraein K, Jacob T. Protective effect of glycine in mesenteric ischemia and reperfusion injury in a rat model. *J Vasc Surg*. 2003;38:1113-20.
 21. Zhong Z, Wheeler MD, Li X, Froh M, Schemmer P, Yin M, Bunzendaul H, Bradford B, Lemasters JJ. L-Glycine: a novel nti-inflammatory, immunomodulatory, and cytoprotective agent. *Curr Opin Clin Nutr Metab Care*. 2003;6:229-40.
 22. Chiu CJ, McArdle AH, Brown R, Scott HJ, Gurd FN. Intestinal mucosal lesion in low-flow states. *Arch Surg*. 1970;101:478-83.
 23. Kohn HI, Liversedge M. On a new aerobic metabolite whose production by brain is inhibited by apomorphine, emetine, ergotamine, epinephrine and manadione. *J Pharmacol Exp Ther*. 1944;82:292-300.
 24. Pyles LA, Stejskal EJ, Einzig S. Spectrophotometric measurement of plasma 2-thiobarbituric acid-reactive substances in the presence of hemoglobin and bilirubin interference. *Proc Soc Exp Biol Med*. 1993;202:407-19.
 25. Ikeda H, Suzuki Y, Koike M, Tamura J, Tong J, Nomura M, Itoh G. Apoptosis is a major mode of cell death caused by ischaemia and ischaemia/reperfusion injury to the rat intestinal epithelium. *Gut*. 1998;42:530-537.
 26. Ciftçi I, Dilsiz A, Aktan TM, Gürbilek M, Duman S. Effects of nitric oxide synthase inhibition on intestinal damage in rats with experimental necrotizing enterocolitis. *Eur J Pediatr Surg*. 2004; 14:398-403.
 27. Dilsiz A, Ciftçi I, Aktan TM, Gürbilek M, Karagözoglu E. Enteral glutamine supplementation and dexamethasone attenuate the local intestinal damage in rats with experimental necrotizing enterocolitis. *Pediatr Surg Int*. 2003;19:578-82.
 28. Zhong Z, Arteel GE, Connor HD, Yin M, Frankenberg MV, Stachlewitz RF, Raleigh JA, Mason RP, Thurman RG. Cyclosporin A increases hypoxia and free radical production in rat kidneys: prevention by dietary glycine. *Am J Physiol*. 1998;275:595-604.
 29. Özkan KU, Özokutan BH, Inanç F, Boran Ç, Kiliç M. Does maternal nicotine exposure during gestation increase the injury severity of small intestine in the newborn rats subjected to experimental necrotizing enterocolitis. *J. Pediatr Surg*. 2005;40:484-8.
 30. Pehlivan M, Dalbeler Y, Hazinedaroglu S, Arikan Y, Erkek AB, Gunal O, Turkcapar N, Turkcapar AG. An assessment of the effect of Ginko Biloba EGF 761 on ischemia reperfusion injury of intestine. *Hepato-Gastroenterol*. 2002;49:201-4.

Correspondence:

Karine Furtado Meyer.
 Rua Rio Grande, 551/162 A
 4018-01 - São Paulo – SP Brazil
 Phone/Fax: (55 11)5084-5342
karine_meyer@uol.com.br

Conflict of interest: none
 Financial source: Support Research
 Foundation of the State of São Paulo (FAPESP). Brazil
 Grant 2004/12440-3

Received: December 08, 2005

Review: January 10, 2006

Accepted: February 14, 2006

How to cite this article:

Meyer KF, Martins JL, Freitas Filho LG, Oliva MLV, Patrício FRS, Macedo M, Wang L. Glycine reduces tissue lipid peroxidation in hypoxia-reoxygenation-induced necrotizing enterocolitis in rats. *Acta Cir Bras*. [serial on the Internet] 2006 May-June 21(3). Available from URL: <http://www.scielo.br/acb>.

*Color figures available from www.scielo.br/acb