

# TUBERCULOSIS

## An uncommon cause of cerebral venous thrombosis?

José Antonio Fiorot Júnior<sup>1</sup>, André Carvalho Felício<sup>1</sup>, Márcia Mauimi Fukujima<sup>1</sup>, Celso Arraes Rodrigues<sup>2</sup>, Vânia Maria Morelli<sup>2</sup>, Dayse Maria Lourenço<sup>2</sup>, Gilmar Fernandes do Prado<sup>1</sup>

**ABSTRACT** - Several infectious etiologies are related to cerebral venous thrombosis (CVT), but a review of literature showed only few cases related to tuberculosis (TB), and only one with neurological manifestations. We report an unusual case of CVT related to TB and mutation in prothrombin gene. A 38-year-old black man presented abrupt right hemiparesis, and hemiparesis. Investigations revealed CVT. Cerebral spinal fluid (CSF) examination evidenced an infection by Mycobacterium. He was heterozygous for G20210A prothrombin mutation. Probably, hypercoagulability mechanisms of TB, added to mutation of prothrombin gene increase the risk of CVT.

**KEY WORDS:** cerebral venous thrombosis, tuberculosis, prothrombin gene mutation.

### **Tuberculose: uma causa rara de trombose venosa cerebral?**

**RESUMO** - As mais variadas etiologias infecciosas estão relacionadas a trombose venosa cerebral (TVC), mas revisando-se a literatura há apenas poucos relatos de casos que se devem à tuberculose (TB), sendo que em apenas um deles havia manifestações no sistema nervoso central. Relatamos um caso de TVC associado a TB e a mutação do gene da protrombina. Homem 38 anos, negro, apresentou hemiparestesia de instalação súbita à direita, evoluindo com hemiparesia homolateral. Durante a internação, foi coletado líquido que evidenciou infecção por micobactéria. A pesquisa de trombofilias mostrou positividade somente para mutação do gene da protrombina (G20210A). Provavelmente os mecanismos de hipercoagulabilidade intrínsecos à tuberculose somados à mutação do gene da protrombina, potencializam o risco de TVC.

**PALAVRAS-CHAVE:** trombose venosa cerebral, tuberculose, mutação do gene da protrombina.

Occlusion of the central veins and sinuses occurs owing to thrombus, thrombophlebitis, or tumors. Cerebral venous thrombosis (CVT) is less frequent than arterial thrombosis, but can produce sequelae or may be fatal<sup>1</sup>. Predisposing factors include infections, pregnancy and puerperium, hypercoagulable states, acquired and congenital heart diseases, red blood cells disorders, malignancies, connective tissue disorders, severe dehydration, liver disease, surgery, sex steroid administration, and major traumas<sup>1</sup>. Many infectious causes are related to CVT, but a review of literature showed few cases related to tuberculosis (TB). Only one, with neurological manifestations, could be associated to Mycobacterium tuberculosis found in sputum culture<sup>2</sup>.

We report the case of a man with CVT and systemic TB.

### **CASE**

A 38-year-old black man was admitted to Neurological Emergency Service, and signed informed consent. He reported that he had suddenly presented abrupt right hemiparesis, and hemiparesis. He became better with treatment after one month of hospitalization. On this period, it was also diagnosed pulmonary tuberculosis, by chronic cough, fever, weight loss and acid-fast bacilli on smear of sputum and testicle tuberculosis by a scrotal ultrasound that showed an inflammatory mass of testicle and epididymis, which became better after treatment with isoniazid, rifampicin (7 months), and pyrazinamide (2 months). Corticosteroids were used in usual doses. Imaging tests revealed expansion of superior sagittal sinus, with venous congestion, that enhanced with contrast administration, and increased attenuation area in left parietal lobe. Hypersignal in the left parietal area

<sup>1</sup>Division of Neurology; <sup>2</sup>Division of Haematology and Transfusion, Universidade Federal de São Paulo (UNIFESP), São Paulo SP, Brazil

Received 9 February 2005, received in final form 12 May 2005. Accepted 14 June 2005.

Dr. José Antonio Fiorot Júnior - Disciplina de Neurologia UNIFESP - Rua Botucatu 740 - 04023-900 São Paulo SP - Brasil. E-mail: [fiorotjr@terra.com.br](mailto:fiorotjr@terra.com.br), [maiumi@neuro.epm.br](mailto:maiumi@neuro.epm.br), [dayse@webmail.epm.br](mailto:dayse@webmail.epm.br).

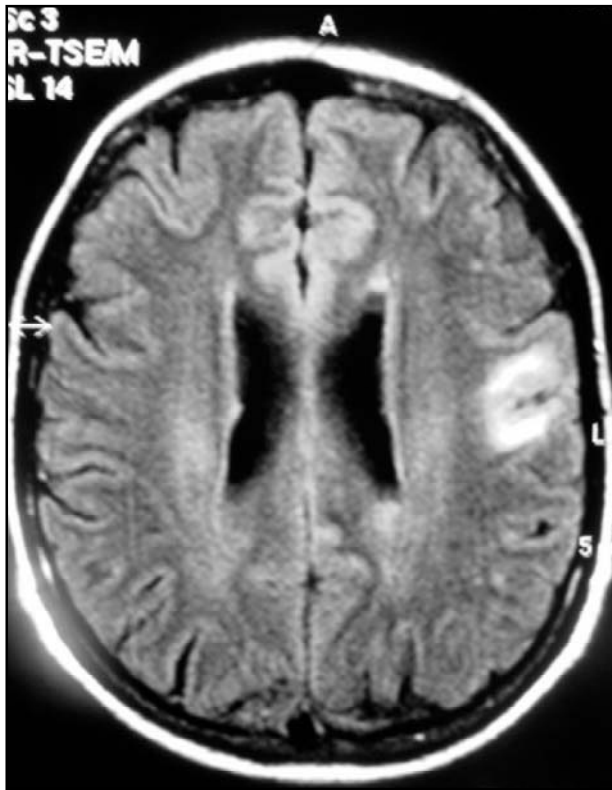


Fig 1. FLAIR axial image with hypersignal in the left parietal area.

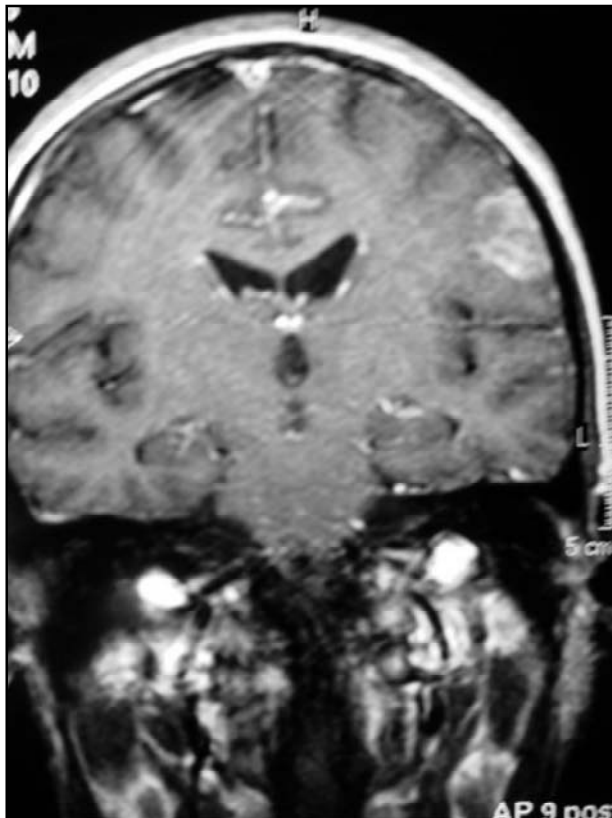


Fig 2. T1- weighted coronal image with enhanced left parietal area after contrast administration.

in FLAIR and sagittal sinus with irregular signals were seen in magnetic resonance imaging (MRI) (Figs 1,2,3,4).

During hospitalization, cerebral spinal fluid (CSF) examination showed: 178 cells (81% lymphocytes, 11% monocytes, 8% neutrophils), protein 132 mg/dl, glucose 30 mg/dl, adenosine deaminase (ADA) 11.1, suggesting tuberculous meningitis. A spinal fluid culture was negative. Rheumatologic tests, including FAN/Hep2/Anti-DNA/ANCA/Crio/Anti-cardio/Anti-ENA were negatives, as well VDRL, Anti-HIV serology and thyroid function tests. Patient was heterozygous for G20210A prothrombin mutation, and factor V Leiden was negative. He has no familiar history of venous thromboembolism. Treatment was successful with 6 months anticoagulation (warfarin), confirmed by an Angio - MRI performed after 6 months, which showed complete resolution of thrombosis in sagittal sinus.

On his last outpatient visit, after 40 months, the patient presented minimal right hemiparesis, and no drug was in use.

## DISCUSSION

CVT can be idiopathic or secondary to infectious and non-infectious etiologies. Infection-related CVT is usually due to bacterial (mainly pneumococcal), fungal or parasitic infections. Tuberculosis was associated to CVT in few patients reported on literature. Two of them have disseminated TB with no involvement of central nervous system<sup>3</sup>, one has only pulmonary disease, and another had chronic granulomatous meningitis<sup>2</sup>.

Finding only 4 cases of CVT related to TB is curious. TB is the main infectious cause of death worldwide. *M. tuberculosis* infects one third of world population and kills almost 3 million people each year<sup>4</sup>. The pathophysiologic process that can explain the relation between TB and CVT includes: (1) injury to endothelium, (2) alterations in normal blood flow, and (3) alterations in the blood coagulability. Blood stasis occurs because intracranial sinus is a low-pressure system without valve. Hypercoagulable state occurs in patients with TB, because they show increased platelet aggregability<sup>5</sup>. Sarode et al. found significant hyper aggregation in 88% patients with intestinal TB<sup>6</sup>. Endothelium injury in intracranial veins may be consequence of the same mechanism, which occurs in arterial vessels by TB. Arteries running through the subarachnoid space may show obliterative endarteritis with inflammatory infiltrates in their walls, and marked intimal thickening.

Despite the continuing description of new causes of CVT, it is very strange that the proportion of

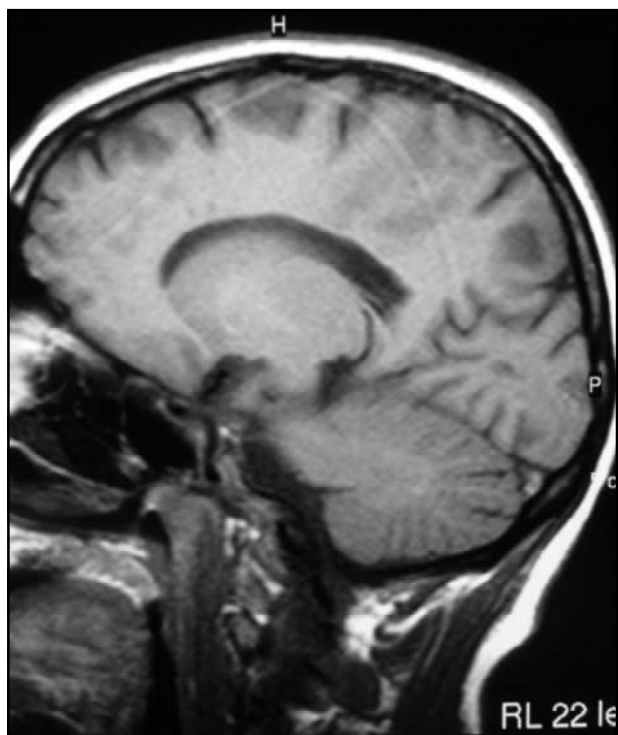


Fig 3. T1-weighted sagittal image with irregular signals in the sagittal sinus.

unknown etiology remains high, in recent series between 20 - 35%. Infections constitute a major cause to CVT and TB prevalence is high. This association may be under diagnosed. The mutation in prothrombin gene found in our patient is very interesting. A transition G→A at position 20210 is associated with elevated prothrombin concentration and thrombosis. People with mutation in this gene and presence of factor V Leiden mutation may increase 5 - 10 fold risk of venous thrombosis. However, both mutations when alone are not high risk factors for venous thrombosis, so lifetime anticoagulation is controversial<sup>7</sup>. Some trials were done to prove that bacterial infection was associated with gene polymorphisms, such as factor V Leiden and factor II (prothrombin), but the result was negative. Prothrombin mutation seems to be more prevalent than factor V Leiden in Brazilian patients with cerebral venous thrombosis<sup>8</sup>.

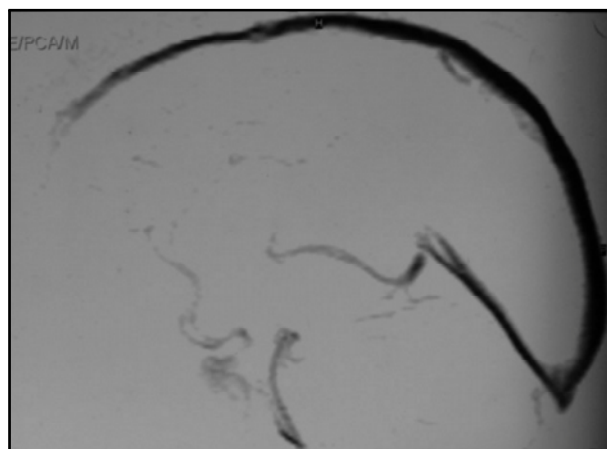


Fig 4. Venous phase of an angiogram shows irregular signals in the sagittal sinus.

Finally, it is still not possible to find a connection between mutation in prothrombin gene and Mycobacterium infection, presented in our patient. Probably, hypercoagulability mechanisms of TB, added to mutation of prothrombin gene increase the risk of CVT.

#### REFERENCES

1. Ferro JM, Canhão P, Stam J, Boussier M-G, Barinagarrementeria F and ISCVT Investigators. Prognosis of cerebral vein and dural sinus thrombosis. Results of the international study on cerebral vein and dural sinus thrombosis. *Stroke* 2004;35:664-670.
2. Finsterer J, Kladosek A, Nagelmeier IE, et al. Chronic granulomatous meningitis with multiple cranial nerve lesions hydrocephalus, stroke, sinus thrombosis, and epilepsy. *South Med J* 2000;93:1108-1111.
3. Kakkar N, Banerjee AK, Vasishtha RK, Marwaha N, Deodhar SD. Aseptic cerebral venous thrombosis associated with abdominal tuberculosis. *Neurol India* 2003;51:128-129.
4. American Thoracic Society Treatment of tuberculosis and tuberculosis infection in adults and children. *Am J Respir Crit Care Med* 1994; 149:1359.
5. Robson SC; White NW; Aronson I; Woolgar R; Goodman H; Jacobs P. Acute-phase response and the hypercoagulable state in pulmonary. *Br J Hematol*, 1996; 93:4943-949.
6. Sarode R, Bhasin D, Marwaha N, et al. Hyperaggregation of platelets in intestinal tuberculosis: role of platelets in chronic inflammation. *Am J Hematol* 1995;48:52-54.
7. Kurkowska-Jastrzebska I, Wicha W, Dowzenko A, et al. Concomitant heterozygous factor V Leiden mutation and homozygous prothrombin gene variant (G20210A) in patient with cerebral venous thrombosis. *Med Sci Monit* 2003;9:41-45.
8. Rodrigues CA, Rocha LKA, Morelli VM, Franco RF, Lourenço DM. Prothrombin G20210A mutation, and not factor V Leiden mutation, is risk factor for cerebral venous thrombosis in Brazilian patients. *J Thromb Haemost* 2004;2:1211-1212