

# ESTHESIONEUROBLASTOMA

## Case report

*Jackson Gondim<sup>1</sup>, Francisco Ramos Jr<sup>2</sup>, Jorge Azevedo<sup>3</sup>,  
Fernando Porto Carrero Jr<sup>3</sup>, Oswaldo Inácio Tella Jr<sup>4</sup>*

**ABSTRACT** - Esthesioneuroblastoma (ENB) is a rare tumor arising from the olfactory epithelium of the nasal vault which frequently invades the cranial base, cranial vault and orbit. ENB has a bimodal age distribution between 11 and 20 years and between 51 and 60 years. ENB accounts for approximately 1 to 5% of intranasal cancers and no consensus has been reached regarding treatment of this tumor. We report on a 66 year old female patient with a Kadish stage C tumor with frontal lobe invasion submitted a total craniofacial resection with a combined head neck and neurosurgeon team. The purpose of this study is to analyze the natural history, treatment and prognosis of this tumor, based on the literature review.

**KEY WORDS:** esthesioneuroblastoma, craniofacial surgery, skull base surgery.

### **Esthesioneuroblastoma: relato de caso**

**RESUMO** - Esthesioneuroblastoma é um tumor raro originado do epitélio olfativo, frequentemente invadindo a base do crânio e a região orbitária. É tumor que pode ser encontrado em qualquer idade mas apresentando dois picos de frequência entre 11 e 21 anos e 51 e 60 anos, raros em criança. A distribuição por sexo é praticamente igual mas com uma pequena predominância masculina. O diagnóstico histopatológico é feito de forma definitiva por métodos imunohistoquímicos. A sintomatologia clínica corresponde ao de uma neoplasia intranasal ou frontobasal. Devido a raridade destes tumores não se chegou ainda a um consenso em relação ao tipo de tratamento. Relatamos o caso de uma paciente 66 anos de idade com um tumor classificado como Kadish tipo C, com invasão dos seios da face e lobo frontal, que foi submetida a ressecção crânio facial por uma equipe multidisciplinar. A historia natural o tratamento e o prognóstico dos pacientes portadores destes tumores serão analisados baseando-se numa revisão da literatura.

**PALAVRAS-CHAVE:** esthesioneuroblastoma, cirurgia crânio facial, cirurgia da base do crânio.

Esthesioneuroblastoma (olfactory neuroblastoma) (ENB) is a rare neuroepithelial tumor that arises from the olfactory epithelium in the cribriform plate or nasal cavity<sup>1</sup>. First described in 1924 by Berger<sup>2</sup> it has a histological pattern similar to that of sympathetic ganglia, retina, and adrenal medulla<sup>2</sup> and only recently<sup>3</sup> became recognized as a distinct pathologic entity probably as a result of immunohistochemistry and by means of electron microscopy techniques. They have helped differentiate ENB from similar undifferentiated nasal cavity tumors<sup>3</sup>. ENB account for 1 to 5% of malignant neoplasm of the nasal cavity. Fewer than 945 cases are reported in the world literature<sup>4</sup>, and most of the reports were in small series. Unlike most other neuroectodermal tumors, which

manifest in childhood, ENB, has a bimodal age distribution between 11-20 years and 51-60 years<sup>5</sup>. The symptoms are related to sites and invasion of the tumor. The staging system based on tumor extension that was presented by Kadish et al.<sup>6</sup> in 1976 has been widely accepted. The treatment of choice is a multidisciplinary craniofacial surgical resection that has improved considerably the prognosis.

The purpose of this study is to analyze the natural history, treatment and prognosis of this tumor, based on the literature review.

### **CASE**

A 66 years old woman with a one year history of constant bifrontal facial headache, nasal obstruction, anosmia

<sup>1</sup>Neurocirurgião do Hospital Geral de Fortaleza, Fortaleza CE, Brazil (HGF) e Mestrando em Neurocirurgia da Escola Paulista de Medicina, Universidade Federal de São Paulo, São Paulo SP, Brazil (UNIFESP-EPM); <sup>2</sup>Neurocirurgião do HGF; <sup>3</sup>Cirurgião do Setor de Cabeça e Pescoço do HGF; <sup>4</sup>Professor Livre-Docente da Disciplina de Neurocirurgia da UNIFESP-EPM.

Received 3 September 2001, received in final form 12 November 2001. Accepted 22 November 2001.

*Dr. Jackson Gondim - Rua Dr. Pedro Sampaio 50 - 60181-560 Fortaleza CE - Brasil. E-mail: jagondim@secrel.com.br*

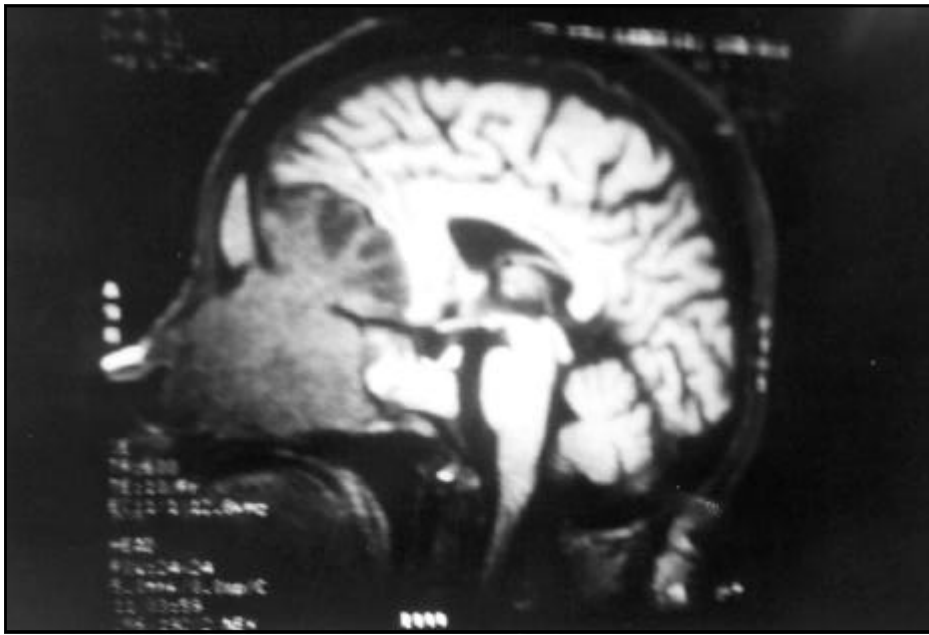


Fig 1. Preoperative sagittal MRI of the tumor, involving the ethmoid sinus, sphenoid sinus, nasal cavity and frontal lobe.

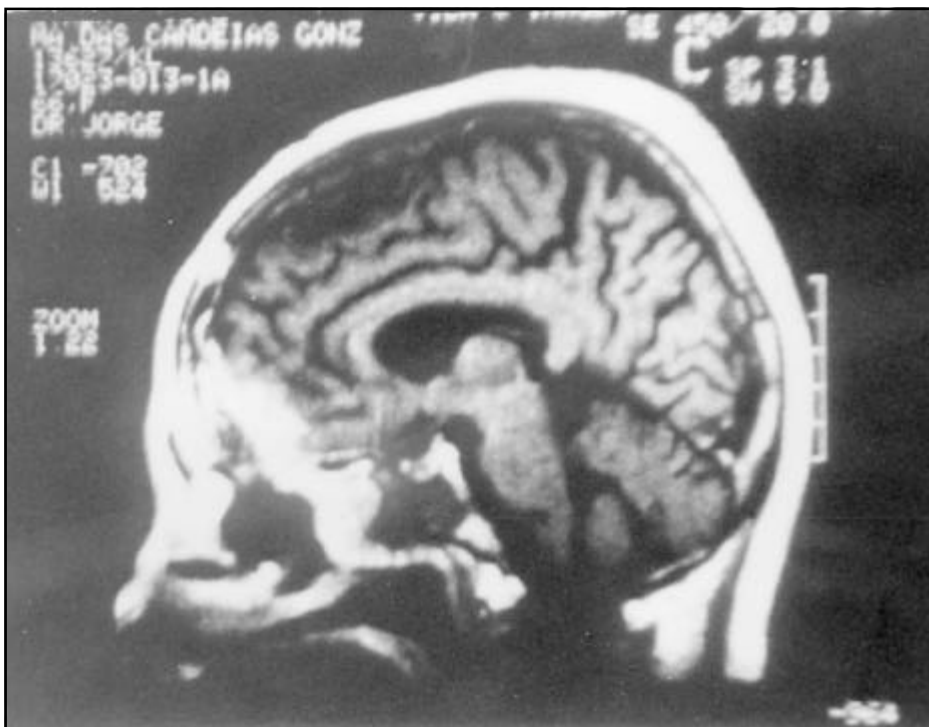

Fig 2. Postoperative one month sagittal MRI, with no more tumor.

has presenting for about two months visual blurring, lacrimation and ocular pain followed one week later by epistaxis. Physical examination revealed a bilateral nasal mass that was endonasal endoscopy biopsy-proven to be an ENB. CT and MRI (Fig 1) demonstrated that the tumor filled the entire nasal cavity, ethmoid sinuses, sphenoid sinus, and left frontal sinus. The tumor invaded the cribriform plate and the left frontal lobe. The patient underwent a craniofacial resection with a combined neurosurgeon and head neck surgeon team. A bicoronal incision

with frontal craniotomy, and in bloc resection of the frontal tumor and frontal base with preservation the pericranial flap, that was placed along the floor of the anterior cranial fossa and sutured to the residual sphenoid bone as well as though the residual dura, combined with an extended lateral rhinotomy, with totally resection of the infra cranial tumor. In the post operatively MRI (Fig 2), no tumor was found. The patient receives 56 Gy of external beam radiotherapy over a 6-week period, and chemotherapy. She showed no recurrence after one year.

## DISCUSSION

Esthesioneuroblastoma is a very rare malignancy of the neuroepithelium. It was first described by Berger et al. in 1924, as "l'esthesioneuroepitheliome olfactif"<sup>2</sup> and was only introduced into the American literature by Schall and Lineback<sup>7</sup> in 1951. Nearly all of the 945 cases have been reported within the last 40 years. Embryologically, the olfactory nerves develop from the olfactory placode present in the fetal olfactory mucosa<sup>8,9</sup>. Histologically, there are a number of criterias that help in its diagnosis: neuroepithelial cells arranged in the classic pseudorosette pattern; fibrillar intracellular background; marked microvasculature; and round or fusiform cells approaching the size of lymphocytes with poorly defined, almost nonexistent cytoplasm<sup>1,10,11</sup>. Correct diagnosis often requires confirmatory examination with electron microscopy for the detection of neurosecretory granules. More recently immunohistochemical methods for detection of neuron-specific enolase (NSE) and S-100 protein with negative epithelial, muscle, and lymphoid antigens allowed further confirmation of ENB<sup>1,12</sup>. This tumor must be differentiated from neoplasm of the nasal cavity and paranasal sinus, such as lymphoma, sarcoma, plasmacytoma, malignant melanoma, anaplastic carcinoma, rhabdomyosarcoma, and transitional cell carcinoma<sup>11,13</sup>.

ENB has a bimodal age distribution with an early peak from 11 to 20 years and a later peak between 51 and 60 years of age<sup>10</sup>. Our patient was a 66 years old woman. There is a slight male predominance<sup>13</sup>. The staging system based on tumor extension that was presented by Kadish et al.<sup>6</sup> in 1976 has been widely accepted. This staging system is predictive of disease-related mortality. The system classifies patients with tumors limited to the nasal cavity as stage A. Patients with tumors involving the nasal cavity and extending into the paranasal sinuses are stage B, and stage C are tumors spreading beyond the nasal cavity and paranasal sinuses, as our patient. This system has been advocated by some, because of its simplicity and acceptable prognostic efficacy. Recently, Morita et al.<sup>14</sup> justified a modified classification with stage D tumors, presenting metastases in cervical lymph nodes distant. Two other staging methods, the Biller method<sup>15</sup> and the Dulguerov method<sup>16</sup>, have also been described and used.

ENB is a slow growing tumor and the patients may have a history of progressive symptomatology for months to years, our patient has a one-year evolution. The presenting symptoms are nonspecific and related to the sites and invasion of the tumor. The

most common finding on physical examination was the presence of a nasal mass as our patient. Recurrent epistaxis is sometimes present. Penetration into the cribriform plate can cause anosmia. Ophthalmological symptoms as ptosis, diplopia, visual blurring, ocular pain, proptosis, and excessive lacrimation may be found. Ear pain and otitis can result from tumor obstructing the Eustachian tube. Frontal headache suggests involvement of the frontal sinus. Cranial nerves may also be affected inducing nerve paralysis<sup>14,17</sup>. Alteration of mental status may be present if frontal lobe is invaded.

The diagnosis and evaluation of staging of ENB can be done by CT, which provides the best information about the tumor invasion into bony structures<sup>12</sup>. The tumor is presented as a homogeneous density mass, equal to or greater than the surrounding soft tissues. There are no tumor cysts or calcifications. Contrast enhancement was usually moderate and homogeneous. Coronal images were of value in evaluating extension to the orbital and through the cribriform plate and the anterior cranial fossa<sup>12</sup>. MRI shows a tumor hypointense to gray matter on T1-weighted images and iso or hyperintense on T2-weighted images. Gadolinium enhancement was observed to some degree in all cases. Fat saturated T1-weighted spin-echo images with and without gadolinium enhancement of particular value in differentiating enhancing tumor from post-obstructive mucous debris and evaluating tumor extension to the non-enhancing orbital fat<sup>12</sup>. MRI is more accurate in depicting the exact margins of intracranial tumor extension because of its multiplanar display and superior tissue contrast<sup>12</sup>.

Metastasis occurs in about 10 to 30% of patients<sup>18,19</sup>. The most common sites for metastasis spread are the cervical lymph nodes, less frequent are lung and pleura, brain, bone, spinal column, breast, and abdominal viscera<sup>20,21</sup>. Metastasis to the central nervous system is infrequent and usually identified only at post-mortem examination<sup>5</sup>. In the spinal cord 80% of metastasis are in the cauda equine<sup>18</sup>.

Our patient underwent a combined craniofacial approach utilizing a bicoronal flap for superior exposure and a lateral rhinotomy for infracranial exposure. Reconstruction varied according to the extent of the surgical resection and resultant defect. We do not use bony reconstruction of the floor of the anterior cranial fossa and supraorbital areas, but the pericranial flap is placed along the floor of the anterior cranial fossa and sutured to the residual sphenoid bone and residual dura matter to obtaining a

watertight dural seal. Fibrin glue is used to assist dural seal and to secure a watertight closure. There are great variations in treatment for ENB. Some series advocate a protocol with surgery<sup>15,19,22</sup>, radiotherapy<sup>6,10,19,23</sup> alone, combined surgery and preoperative radiotherapy<sup>13,24</sup>, and combined surgery and postoperative radiotherapy<sup>22,25</sup>. The optimum management for ENB is probably surgery using the concept first described in 1971 by Doyle and Payton<sup>26</sup>: radical surgery with a combined craniofacial approach<sup>12</sup> taken by craniofacial team, including neurosurgery and head neck surgery. This technique has provided enhanced exposure and the possibility to achieve gross total resection. In patients without extension of tumors to the superior nasal vault or the cribriform plate, an intracranial exploration and removal of the floor of the anterior cranial fossa must be performed. This approach has had a decreased incidence of local recurrence<sup>1</sup>. It is proved that the bone in this area may harbor tumor cells with a potential cause of recurrence. This was done with our patient that had an involvement of cribriform plate and frontal lobe. We also used an adjuvant postoperative radiotherapy with 50-60 Gy resulting in effective local control as indicated by other authors<sup>10,27</sup>. Furthermore the radiotherapy is recommended for palliative treatment<sup>27</sup>. The role of systemic chemotherapy in the treatment of ENB has range from no response<sup>28-32</sup>, palliation<sup>20,33</sup>, partial<sup>14,33-37</sup> and complete response<sup>36,38,39</sup>. In general chemotherapy is usually reserved for tumor spreading beyond the nasal cavity and paranasal sinuses<sup>12</sup>, or in the treatment of distant metastases<sup>40</sup>.

Treatment complications with ENB are high. Visual impairment is the most common adverse effect<sup>13</sup>, because the location of the tumor is difficult to deliver an adequate dose of radiation without exceeding the tolerance of critical structures such as the brain, optic chiasm and orbits.

The prognostic factors in the management of ENB are very controversial because of the small number of patients presented in each series. Morita<sup>1</sup> and Foote<sup>41</sup> advocated that the only reliable survival predictor is the tumor's pathological grade (Hyams' grading system<sup>42</sup>). Polin<sup>31</sup> was unable to find significant difference between survival of patients with low and high-grade tumors. Some authors<sup>16,43</sup> affirm that the negative prognostic include age, metastasis, recurrence, and extensions to the ethmoidal, nasopharyngeal and orbital area. They also noted that the absence of metastasis does not necessarily confer a good prognosis. Goldsweig<sup>34</sup> concluded that the degree of resectability of the tumor on primary surgery is the best

predictor of long-term survival. Irish determined a 100% 2-year survival rates in patients undergoing combined surgical and radiation treatment. Polin<sup>31</sup> informs the 5 and 10 years survival rates of 87 and 54% respectively and a 97% one year survival. Patients with stage C disease have 96% one-year survival, 71% five years and 44% 10 years survival<sup>31</sup>. In the series of Jekunen<sup>40</sup> the median survival time for 11 patients was 27 months, and the median disease-free was 27 months. In the literature the 5-year recurrence free survival is reported to be between 52% and 90%<sup>16,29,40</sup>.

ENB recurs locally in up to 60% of patients who undergo surgery<sup>15</sup>, and its locally aggressive behavior is the most common cause of death<sup>44</sup>. Median survival after recurrences was only 12 months<sup>45,46</sup>. The majority of recurrences occur within the first few years after treatment.

In conclusion, ENB is a very uncommon malignant tumor arising from olfactory epithelium, that have a long natural history characterized by frequent local or regional recurrence. Radical craniofacial resections by a multidisciplinary surgical team combined with adjuvant radiotherapy with 50-60 Gy, is probably the most usual treatment. The role of systemic chemotherapy in the treatment of distant metastasis should be further evaluated.

## REFERENCES

1. Irish J, Dasgupta R, Freeman J, et al. Outcome and analysis of the surgical management of esthesioneuroblastoma. *J Otolaryngol* 1977;26:1-7.
2. Berger L, Luc G, Richard D. L'esthesioneuroepitheliome olfactif. *Bull Assoc Franç Etude* 1924;13:410-421.
3. Stewart F, Frierson H, Levin P, Spaulding C. Esthesioneuroblastoma. In Williams JG, Krikorian MR, Green D (eds.) *Textbook of uncommon cancer*. Oxford: Wiley and Sons, 1988:631-652.
4. Broich G, Pagliari A, Ottaviani F. Esthesioneuroblastoma: a general review of the cases published since the discovery of the tumour in 1924. *Anticancer Res* 1997;17:2383-2406.
5. Becker L, Hinton D. Primitive neuroectodermal tumors of the central nervous system. *Hum Pathol* 1983;14:538-550.
6. Kadish S, Goodman M, Wang C. Olfactory neuroblastoma: a clinical analysis of 17 cases. *Cancer* 1976;37:1571-1576.
7. Schall L, Lineback M. Primary intranasal neuroblastoma. *Ann Otol Rhinol Laryngol* 1951;60:221-229.
8. Moore K. *The developing human*. Philadelphia: Saunders, 1977:174-175.
9. O'Rahilly R, Muller F. *The embryonic human brain*. New York: Wiley-Liss, 1994:91-337.
10. Elkon D, Hightower S, Meng L. Esthesioneuroblastoma. *Cancer* 1979;44:1087-1094.
11. Harrison D. Surgical pathology of olfactory neuroblastoma. *Head Neck Surg* 1984;7:60-64.
12. Pickuth D, Heywang-Kobrunner H, Spielmann R. Computed tomography and magnetic resonance imaging features of olfactory neuroblastoma: an analysis of 22 cases. *Clin Otolaryngol* 1999;24:457-461.
13. Simon J, Zhen W, McCulloch T, et al. Esthesioneuroblastoma: The University of Iowa experience 1978-1998. *Laryngoscope* 2001;111:488-493.
14. Morita A, Ebersold M, Olsen K, Foote R, Lewis J, Quasqst L. Esthesioneuroblastoma: prognosis and management. *Neurosurgery* 1993;32:706-715.
15. Biller H, Lawson W, Sachdev V, Som P. Esthesioneuroblastoma: surgical treatment without radiation. *Laryngoscope* 1990;100:1199-1201.

16. Dulguerov P, Calcaterra T. Esthesioneuroblastoma: the UCLA experience 1970-1990. *Laryngoscope* 1992;102:843-849.
17. Bastin K, Steeves R, Gilchrist K. Esthesioneuroblastoma: diagnosis, prognosis and treatment. *Wis med J* 1993;92:17-19.
18. Shaari C, Catalano P, Sen C, Post K. Central nervous system metastases from esthesioneuroblastoma. *Otolaryngol Head Neck Surg* 1996;114: 808-812.
19. Olsen K, De Santo L. Olfactory neuroblastoma: biologic and clinical behavior. *Arch Otolaryngol* 1983;109:797-802
20. Beitler J, Fass D, Brenner H. Esthesioneuroblastoma: is there a role for elective neck treatment. *Head Neck* 1991;13:321-326.
21. Djalilian M, Zujko R, Weiland D, Devine K. Olfactory neuroblastoma. *Surg Clin N Am* 1977;57:751-762.
22. Skolnik E, Massari F, Tenta L. Olfactory neuroepithelioma: a review of the world literature and presentation of two cases. *Arch Otolaryngol* 1966;84:84-93.
23. Parsons J, Mendenhall W, Mancuso A. Malignant tumors of the nasal cavity and ethmoid sinuses. *J Radiat Oncol Boil Phys* 1988;14:11-22.
24. Cantrell R, Chorayeb B, Fitz-Hugh G. Esthesioneuroblastoma: diagnosis and treatment. *Ann Otol Rhinol Laryngol* 1977;86:760-765.
25. Oberman H, Rice D. Olfactory neuroblastoma: a clinico-pathologic study. *Cancer* 1976;38:2494-2502.
26. Doyle P, Payton H. Combined surgical approach to esthesioneuroepithelioma. *Trans Pa Acad Ophthalmol Otolaryngol* 1971;75:526-531.
27. Eich H, Star S, Mickle O, Eich P, Stutzer H, Muller R. Radiotherapy of esthesioneuroblastoma. *Int J Radiation Boil Phys* 2001;49:155-160.
28. Sheeran JM, Sheeram JP, Jane J, Polin R. Chemotherapy for esthesioneuroblastomas. *Neurosurg Clin N Am* 2000;11:693-701.
29. Levine P, Frierson H, Stewart F. Sinonasal undifferentiated carcinoma: a distinctive and highly aggressive neoplasm. *Laryngoscope* 1987;97: 905-908.
30. Mendeloff J. The olfactory neuroepithelial tumours. *Cancer* 1957;10:944-956.
31. Polin R, Sheeran J, Chenelle A. The role of pre-operative adjuvant treatment in the management of esthesioneuroblastoma: the University of Virginia experience. *Neurosurgery* 1998;42:1029-1037.
32. Polonowshi, Brasnu D, Roux F. Esthesioneuroblastoma: a complete tumor response after induction chemotherapy. *Ear Nose Throat J* 1990; 69:743-746.
33. Tingwald F. Olfactory placode tumors. *Laryngoscope* 1966;76:196-211.
34. Goldweig H, Sundarsean N. Chemotherapy of recurrent esthesioneuroblastoma: case report review of the literature. *Am J Clin Oncol* 1990;13: 139-143.
35. Rodas R, Erkman-Balis B, Cahill D. Late intracranial metastasis from esthesioneuroblastoma: a case report and review of the literature. *Neurosurgery* 1986;9:622-627.
36. Wade P, Smith R, Johns M. Response of esthesioneuroblastoma to chemotherapy. Report of five cases and review of the literature. *Cancer* 1984;53:1036-1041.
37. Weiden P, Yarrington C, Richardson R. Olfactory neuroblastoma: chemotherapy and radiation for extensive disease. *Arch Otolaryngol Head Neck Surg* 1984;11:759-760.
38. Grahne B. Olfactory neuroblastoma. *Acta Otolaryngol (Stockh)* 1965; 59:55-64.
39. Watne K, Hager B. Treatment of recurrence esthesioneuroblastoma with combined intracranial chemotherapy: a case report. *J Neurooncol* 1987; 5:47-50.
40. Jekunen A, Kalevi J, Kairemo J, Lehtonen H, Kajanti M. Treatment of olfactory neuroblastoma. *Am J Clin Oncol* 1966;19:375-378.
41. Foote R, Morita A, Ebersold M, et al. Esthesioneuroblastoma: the role of adjuvant radiation therapy. *Int J Radiat Oncol Biol* 1993;27:835-842.
42. Hyams V, Batsakis J, Michaels L. Olfactory neuroblastoma. In Hyams V, Batsakis J, Michaels L (eds). *Tumors of the upper respiratory tract and ear*. Washington: Armed Forces Institute of Pathology, 1988:240-248.
43. Homzie M, Elkon D. Olfactory esthesioneuroblastoma: variables predictive of tumors control and recurrence. *Cancer* 1980; 46:2509-2513.
44. Ahern V, Pousen M. Olfactory neuroblastoma management of a rare tumor at the Queensland Radium Institute and literature review. *Australas Radiolol* 1991;35:366-369.
45. Eriksen J, Bastholt L, Krogdahi A, Hansen O, Joergesen K. Esthesioneuroblastoma What is the optimal treatment? *Acta Oncologica* 2000;2:231-235.
46. Tatagiba M, Samii M, Dankoweit-Timpe E, et al. Esthesioneuroblastomas with intracranial extension. Proliferative potencial and management. *Arq Neuropsiquiatr* 1995;53:577-586.