

# AGENESIS AND LIPOMA OF CORPUS CALLOSUM

## CASE REPORT

*DÉLRIO FAÇANHA SILVA\**, *MÁRCIA MARQUES LIMA\*\**, *CÉSAR O. OLIVEIRA\*\**,  
*WILLIAM N. OLIVEIRA\*\**, *RENATO ANGHINAH\*\**, *JOSÉ GERALDO CAMARGO LIMA\*\*\**

---

**SUMMARY** - The agenesis and lipoma of the corpus callosum is a very rare association. We report the case of a 18-years old woman with rare epileptic seizures since the age of 6 years, normal neurological examination, as well as normal electroencephalogram. The brain computed tomography scanning and the magnetic resonance showed the lipoma and the agenesis of the corpus callosum.

**KEY WORDS:** corpus callosum, lipoma, agenesis.

### **Agnesia e lipoma de corpo caloso: relato de caso**

**RESUMO** - A agnesia e lipoma do corpo caloso é uma associação muito rara. Relatamos o caso de uma paciente de 18 anos com raras crises epiléticas desde os 6 anos de idade, exame neurológico normal, assim como eletrencefalograma normal. A tomografia computadorizada de crânio e a ressonância magnética mostraram o lipoma e a agnesia de corpo caloso.

**PALAVRAS CHAVES:** corpo caloso, lipoma, agnesia.

---

Corpus callosal lipoma (CCL) is a very rare benign tumor<sup>7,23,32</sup> of questionable etiology. Most of the reported cases have been found at postmortem examination<sup>13</sup>. Its incidence is around 0.06%<sup>5,13</sup> and is often associated with other malformations<sup>24</sup>, most commonly partial or complete callosum agenesis (CA), which occurs in as many as 50% of CCL patients<sup>18,34</sup>. Since the first report in 1856 by Rokitansky<sup>29</sup> an extensive review of the literature revealed a total of less than 85 reported cases of CCL with CA<sup>12</sup>. We describe one case of this unusual association.

### **REPORT OF CASE**

JR, a 18-year-old woman was referred for investigation of epileptic seizures. She had a history of tonic-clonic generalized seizures since 6 years of age. Their seizures lasts no longer than a few minutes, occurred up to 4 per year, mainly during the sleep and complaint of headache as the only postictal change. Pregnancy and delivery were normal, as was the child's early development. The antenatal history had been unremarkable. Physical and neurological examination were normal. Phenobarbital monotherapy was started with 100 mg/day. A conventional EEG performed for 30 min was normal during the awake and sleep state. CT as well as the MR showed the lipoma and the agenesis of CC. The CT scans were characterized by regular low density image filling the place of the CC (lipoma) an bordered on each side by two shell-like calcifications. The MR was carried out with T1 and T2 weighted images and showed the following findings: (a) indirect signs of callosal

---

\*Head of the EEG Sector, Escola Paulista de Medicina (EPM); \*\*Junior Doctor of the EEG Sector; \*\*\* Full Professor and Head of the Discipline of Neurology, EPM. Aceite: 28-abril-1995.

agenesis: dilatation of the trigone of lateral ventricles and ascension of the third ventricle; (b) partial (nearly total) agenesis of the body and splenium of the CC; (c) a slice of adipose tissue over the region of the genu and the rostrum that extended as a voluminous mass (lipoma) into the ventricles with high intensity sign at T1 (Fig 1a, b, and c). During the follow-up of 4 years the EEG remained normal and the CT and MR images showed the same findings without new changes. The patient is still under treatment with phenobarbital 100 mg per day and presents rare epileptic seizures.

## COMMENTS

The rarity of intracranial lipomas is indicated by the fact that in a series occurred only four times in 5000 postmortem examinations<sup>31</sup>. The first case discovered at necropsy occurred after 23813 consecutive necropsies<sup>25</sup>. In a CT department only four lipomas of the CC were found in nearly 13000 patients, a frequency of 0.03%<sup>7</sup>. The commonest associated anomaly is agenesis of the CC, as in our patient, occurring in 48% of cases with this type of tumor<sup>24,34</sup>, and may affect part or all of this structure<sup>25</sup>. Other deviations include agenesis of the cerebellar vermis, cleft lip, funnel chest, cardiac ventricular septal defect<sup>34</sup>, spina bifida and myelomeningocele<sup>25</sup>, and cortical heterotopia<sup>10</sup>. The lipoma of the CC is a congenital<sup>14</sup>, hamartomatous condition<sup>4</sup>, probably due to meningeal maldifferentiation, and the agenesis has been regarded as an example of cerebral dysraphism, the term dysraphism referring to the midline defects caused by imperfect closure of neural tube<sup>1,2,27,28</sup>.

The commonest presentation of the CCL is epilepsy, either partial motor or complex partial seizures<sup>7</sup>. Some of these seizures may evolve to secondary generalization and might terminate in generalized tonic-clonic seizures. In our patient the generalized convulsive seizures could have been secondarily generalized seizure in which the partial beginning was not appreciated. The origin of the epilepsy in this condition is not clear. One theory advanced is that the invasion of cerebral cortex by the collagenous capsule sets up a focus or because of the interhemispheric disconnection<sup>7,34</sup>. Other nonspecific symptoms have been described as headache, paresthesias, vomiting, vertigo and emotional lability<sup>16,18,21,23,30</sup>. On the other hand, approximately 50% of cases are asymptomatic<sup>3,32</sup>.

CT and MR are the diagnostic procedures of choice<sup>1,2,6,9,21,27</sup>. The CT appearance of lipomas of the CC was first described by New and Scott in 1975<sup>22</sup> and the diagnosis depends on the characteristic low attenuation values which are characteristic of fat tissue only. When calcification occurs, it is curvilinear and mural<sup>18</sup>. On contrast-enhanced CT, the tumor does not show any change in density<sup>13</sup>. MR provides highly visible images of the CC and is the procedure of choice in the evaluation of this structure<sup>6,23</sup>. In our patient the diagnosis of partial agenesis (nearly total) of CC was established with the MR images (Fig 1 a, b, and c). The differential diagnosis must be made with

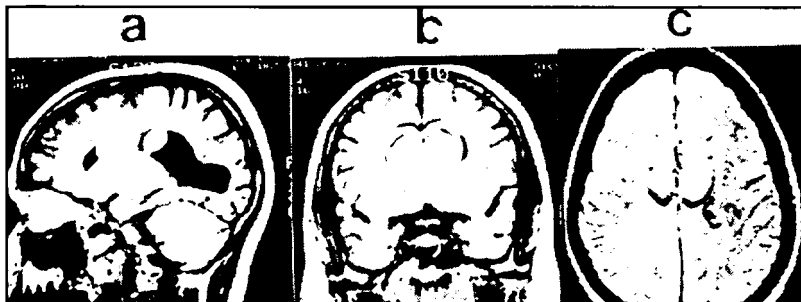


Fig 1. MR evaluation with T1 weighted images demonstrates the agenesis and the lipoma of corpus callosum. Sagittal (a), coronal (b), and axial MR images shows a high-intensity signal (white) of lipoma circumscribing the region of corpus callosum and extending into the ventricles.

dermoid cyst, teratoma, craniopharyngioma, and epidermoid tumors<sup>17,19,20</sup>. The cystic component of craniopharyngiomas may be fat dense but its complex appearance and bizarre calcifications are usually suggestive of this tumor<sup>26</sup>. Teratomas and dermoid cysts are frequently inhomogenous because they contain tissues other than fat<sup>13,33</sup>. Epidermoid tumors are generally located within the cerebellopontine angle, parapituitary region or in the fourth ventricle and have CT appearance that usually fall in the range of cerebrospinal fluid density<sup>20</sup>.

Surgery has little place in the management of this condition<sup>13</sup>. The necessity for removal of the CCL must be seriously questioned, since it is a non-malignant, non-progressive lesion, and some patients live to old age, trouble-free, untreated. Firm adhesion between the collagenous capsule and brain together with the high vascularity of the tumour add to the surgical hazard that may end with death<sup>25,30,34</sup>. Laser techniques may make these lipomas more amendable to surgery<sup>5</sup>. Surgery has been performed in the face of a rapidly growing tumor, signs of increased intracranial pressure, progressive neurologic signs, or severe uncontrolled seizures<sup>11,15</sup>. Even when surgery is performed, a patient's epilepsy will unlikely be resolved<sup>9</sup>. Tahmouresie et al.<sup>30</sup> reported that of 21 surgical patients, 10 (47.6%) died during the postoperative period, 4 were no better, 1 was worse, and 5 (23.7%) improved. Our patient had a history of 12 years of rare seizures, was under control with anticonvulsant, had not progression of their symptoms and the CT and MR images did not change during the follow-up.

## REFERENCES

1. Atlas SW, Zimmerman RA, Bilaniuk LT, Rorke L, Hackney DB, Goldberg HI, Grossman RI. Corpus callosum and limbic system: neuroanatomic MR evaluation of developmental anomalies. *Radiology* 1986, 160:355-362.
2. Bradley WG, Kortman KE. Cranial computed tomography and MRI: current clinical applications. In Lee SH, Rao KCVG (eds). *Cranial computed tomography and MRI*. Ed 2. New York: McGraw-Hill, 1987.
3. Bruyer R, Dupuis M, Ophoven E, Rectem D, Reynaert C. Anatomical and behavioral study of a case of asymptomatic callosal agenesis. *Cortex* 1985, 21:417-430.
4. Budka H. Intracranial lipomatous hamartomas (intracranial "lipomas"): a study of 13 cases including combinations with medulloblastoma, colloid and epidermoid cysts, angiomas and other malformations. *Acta Neuropath (Berlin)* 1974, 28:205-222.
5. Clarici G, Heppner F. The operative approach to lipomas of the corpus callosum. *Neurochirurgia* 1979, 22:77-81.
6. Davidson HD, Abraham R, Steiner RE. Agenesis of the corpus callosum: magnetic resonance imaging. *Radiology* 1985, 155:371-373.
7. Gastaut H, Regis H, Gastaut JL, Yermenos E, Low MD. Lipomas of the corpus callosum and epilepsy. *Neurology* 1980, 30:132-138.
8. Gastaut H, Roger J, Faidherbes J, Ouahchi S, Franck G, Criticos A, Esquivel-Rodon O, Irrigoyen-Arroyo M. Non-jacksonian hemiconvulsive seizures: one side generalized epilepsy. *Epilepsia* 1962, 3:56-68.
9. Gerber SS, Plotkin R. Lipoma of the corpus callosum: case report. *J Neurosurg* 1982, 57:281-285.
10. Gille M, Jacquemin C, Bachy N, Delbecq J, Depré A. Agénésie calleuse, hétérotopie de substance grise et kyste interhémisphérique: diagnostic radiologique tardif chez un adulte asymptomatique. *Rev Neurol (Paris)* 1994, 150:161-163.
11. Halmagyi GM, Evans WA. Lipoma of the quadrigeminal plate causing progressive obstructive hydrocephalus: case report. *J Neurosurg* 1978, 49:453-456.
12. Hughes DS, Osborn RE. Corpus callosal lipoma: report of 2 cases and review of the literature. *J AOA* 1986, 86:564-567.
13. Kazner E, Stochdorph O, Sigurd W, Grumme T. Intracranial lipoma. *J Neurosurg* 1980, 52:234-245.
14. Kolodny EH. Agenesis of the corpus callosum: a marker for inherited metabolic disease? *Neurology* 1989, 39:847-848.
15. Kubota S. Lipoma of the corpus callosum with dysgenesis: a case report. *Neurol Med Chir* 1980, 20:101-106.
16. Larsen JL, Stiris G. Lipoma of the corpus callosum with atypical calcifications. *Br J Radiol* 1970, 43:576-577.
17. Laster DW, Moody DM, Ball MR. Epidermoid tumors with intraventricular and subarachnoid fat: report of two cases. *AJR* 1977, 128:504-507.
18. List CF, Holt JF, Everett M. Lipoma of the corpus callosum: a clinicopathologic study. *AJR* 1946, 55:125-134.

19. Maravilla KR. Intraventricular fat-fluid level secondary to rupture of an intracranial dermoid cyst. *AJR* 1977, 128:500-501.
20. McCormack TJ, Plassche WM Jr, Lin SR. Ruptured teratoid tumor in the pineal region. *J Comput Assist Tomogr* 1978, 2:499-501.
21. Nabawi P, Dobben GD, Mafee M, Espinosa GA. Diagnosis of lipoma of the corpus callosum by CT in five cases. *Neuroradiology* 1981, 21:159-162.
22. New PFJ, Scott WR. *Computed tomography of the brain and orbit (EMI Scanning)*. Baltimore: Williams and Wilkins, 1975, p 397.
23. Olm M, Blesa R, Ribera G, Cardenal C. Lipoma of the corpus callosum: CT and MR for diagnosis. *AJR* 1988, 151:613-614.
24. Parrish ML, Roessmann U, Levinsohn MW. Agenesis of the corpus callosum: a study of the frequency of associated malformations. *Ann Neurol* 1979, 6:349-354.
25. Patel AN. Lipoma of the corpus callosum: a non-surgical entity. *North Carol Med J* 1965, 26:328-338.
26. Peyster RG, Hoover ED. *Computerized tomography in orbital disease and neuro-ophthalmology*. Chicago: Year Book Med Pub 1984, p185-210.
27. Rao KCVG, Harwood-Nash DC. Craniocerebral anomalies. In Lee SH, Rao KCVG (eds). *Cranial computed tomography and MRI*. Ed 2. New York: McGraw-Hill, 1987.
28. Robain O, Dulac O. Malformations cerebrales. In Arthuis M, Pinsard N, Ponsot G. (eds). *Neurologie Pédiatrique*. Paris: Flammarion, Medecine Sciences, 1990.
29. Rokitsansky C. *Lehrbuch der pathologischen Anatomie*. Vienna: Braumuller, 1856, vol 2, p 468-478.
30. Tahmouresie A, Kroll G, Shucart W. Lipoma of the corpus callosum. *Surg Neurol* 1979, 11:31-34.
31. Vonderahe AR, Niemer WT. Intracranial lipoma: a report of four cases. *J Neuropathol Exp Neurol* 1944, 3:344-354.
32. Wallace D. Lipoma of the corpus callosum. *J Neurol Neurosurg Psychiatry* 1976, 39:1179-1185.
33. Zee CS, McComb JG, Segall HD, Tsai FY, Stanley P. Lipomas of the corpus callosum associated with frontal dysraphism. *J Comput Assist Tomogr* 1981, 5:201-205.
34. Zettner A, Netsky M. Lipoma of the corpus callosum. *J Neuropathol Exp Neurol* 1960, 19:305-319.