

Is there a risk to ovarian reserve and fertility from ovarian cystectomy?

Neerujah Balachandren ¹, Ephiah Yasmin ², Dimitrios Mavrelou ³ and Ertan Saridogan ⁴

Abstract

Key Content

- Physiology of benign ovarian cysts, their risk of recurrence, rate of growth and possible impact on fertility
- Management of benign ovarian cysts in children and adolescents
- Impact of ovarian torsion on ovarian reserve
- Impact of ovarian cystectomy on spontaneous conception, ovarian reserve and IVF outcomes.
- Comparison of surgical techniques on the basis of fertility outcomes
- Good practice points when planning a cystectomy for benign ovarian cysts

Learning objectives

- Consider performing ovarian reserve assessments prior to any surgery on the ovary in women who have not completed their family.
- Assess patients who may be at risk for compromised ovarian reserves and discuss fertility preservation options prior to any surgery on the ovaries.
- Children and adolescents presenting with pathological ovarian cysts require a multi-disciplinary team approach and where possible fertility sparing treatment should be offered.
- Laparoscopic detorsion appears to preserve ovarian reserve and this should remain the optimal treatment for ovarian torsion
- Obtain appropriate consent prior to any surgery on the ovary, including the risks of oophorectomy or reduced ovarian reserve.

- Take anatomical considerations into account in order to reduce the risk of bleeding and minimise damage to healthy ovarian tissue

Ethical Issues

- Oocyte freezing is not routinely funded by the NHS for benign conditions.
- Although it would be ideal to do pre-operative ovarian reserve testing on all women of child bearing age who have not yet completed their family, the lack NHS funding and financial constraints present ethical concerns to the clinician and patient.

Key words

Ovarian cysts, ovarian cystectomy, fertility, ovarian reserve assessments, endometriomas, dermoid cysts

Introduction

Ovarian cystectomy is a frequently performed surgical procedure for the management of benign ovarian cysts in pre-menopausal women (1, 2). The procedure is usually performed to prevent cyst complications such as pain, rupture or torsion, or due to concern of malignancy, whilst preserving fertility in those of reproductive age (3). It is not however, easy to determine the impact of the cyst or a cystectomy on a woman's future fertility. This will depend on various factors such as the nature of the cyst, size and number, risk of recurrence, age of the patient, ovarian function, surgical history and the presence of other aetiologies that could be a cause of subfertility in her or her partner (3). The scope of this review article, is to understand how these individual factors can have an impact on the decision to perform a cystectomy as well as determine when and how a cystectomy can be performed in order to reduce the risk of damage to a woman's reproductive potential. We will begin by examining the physiology and natural history of common benign ovarian cysts and whether or not these cysts can have an impact on fertility.

Functional ovarian cysts and their impact on fertility

The ovary has two main functions, folliculogenesis and steroidogenesis. The process of folliculogenesis, i.e. the progression of primordial follicles into large pre-ovulatory follicles, makes the ovary intrinsically prone to developing functional cysts. Functional ovarian cysts have been described as non-pathological follicular cysts which failed to ovulate, a persistent corpus luteum cyst, or other unspecified ovarian cysts measuring more than 20 mm (4). They are the most frequently occurring ovarian cysts in adults and children and account for 46 -53% of all adnexal pathologies (5). They almost always regress spontaneously within 1 to 3 menstrual cycles and therefore should not require any surgical or hormonal interventions (6). Thus, since functional ovarian cysts are simply by-products of

ovulation, in theory, they should not have any impact on fertility. This is with the exclusion of luteal cysts. Luteal cysts are thought to result from failure of the ovulatory follicle to rupture (7). The unruptured follicle undergoes luteinization under the action of luteinizing hormone (LH) and still produces normal levels of progesterone and have the same duration of luteal phase (8). Luteal cysts are observed in 10% of natural menstrual cycles in fertile women, but is thought to occur more frequently in the infertile population (8). Qublan and colleagues found that luteal cysts occurred in 25% of intrauterine insemination (IUI) cycles in couples with unexplained infertility (8).

The second exception, are persistent functional cysts such as those seen in women undergoing controlled ovarian stimulation (COS) as part of IVF treatment, or those with extensive periovarian adhesions. Women with low ovarian reserve and those on a GnRH agonist cycles are at increased risk of developing functional cysts (9). The incidence of these cysts in those undergoing COS is reported to range between 8% and 53% (10). The impact of functional cysts on IVF success remains contentious. Although some studies suggest very poor outcome of cycles where functional cysts were detected, including high cancellation, decreased follicular recruitment and low pregnancy rates (11, 12), others have failed to report a difference in any outcome (13). The first line of treatment in these patients is usually prolonged downregulation with either a progesterone only pill or the combined contraceptive pill and as a last resort, ultrasound or laparoscopy guided drainage of the functional cyst.

Dermoid cysts and their impact on fertility

A dermoid cyst or a mature teratoma is a benign type of germ cell tumour that arises from totipotent ovarian cells which develop into fully differentiated ectodermal, mesodermal, and endodermal tissue and are the most common pathological cysts in pre-menopausal women (14). They are bilateral in 10-20% of cases and grow at a rate of 1.7-1.8mm per year (3). The recurrence rate following cystectomy

is 3-4% (14). There are very few studies that have looked at the impact of dermoid cysts on ovarian function and fertility and have so far not shown any evidence of a negative effect. Kim and colleagues compared anti-mullerian hormone (AMH) levels in women with unilateral and bilateral dermoid cysts to controls and found no significant difference (15). The mean size of the dermoid cysts in their study was 6.3 +/- 0.3cm (15). Schubert and colleagues, performed histological assessments on the ovarian cortex surrounding dermoid cysts, serous cysts and endometriomas taken at cystectomy (16). The follicular density was found to be higher in dermoid cysts compared to endometriotic and serous cysts. Furthermore, there was a clear limit between the dermoid cyst and the ovarian cortex and thus the ovarian cortex only seemed to be stretched but not damaged by the dermoid cyst (16). Maneschi and colleagues also studied the ovarian cortical tissue surrounding benign cysts removed at cystectomy (17). The cortical tissue surrounding dermoid cysts showed normal morphological patterns and regular vascular network similar to those of the normal ovarian cortex in 92% and 84% of the samples respectively (17). One small study also looked at IVF outcomes in 6 patients with dermoid cysts with a mean size of 2.4 cm and showed no difference in the number of eggs collected (18). Overall, it appears that the presence of a dermoid cyst has very little or no impact on fertility. However, dermoid cysts do occur in both ovaries in some women and have a relatively high recurrence rate (1). These factors along with their ability to grow to relatively large sizes can lead to repeated surgery, bilateral procedures and relatively large cystectomies; all of which can have an adverse impact on fertility. Thus, the decision on whether or not to operate and when to operate can be a complex one. Operating early while the cyst is still small may prevent the need for a large cystectomy and thus lower the impact on the ovarian reserve.

Endometriomas and their impact on fertility

Endometriomas or ovarian endometriotic cysts are reported in 17 to 44% of women with endometriosis and is a marker of more severe and deeper disease (19). Furthermore, 28% of endometriomas are bilateral (20). There are several theories on the pathogenesis of endometriomas including invagination and subsequent metaplasia or collection of menstrual debris from endometriotic implants and colonization of functional ovarian cysts by endometriotic cells (19). The risk of recurrence of endometriomas in the same ovary or contralateral ovary following surgery is high, with cumulative rates of 12 to 30% after 2 to 5 years of follow-up (21). Exacoustos and colleagues reported that 81% had recurrence in the treated ovary, 11% on the contralateral untreated ovary and 8% in both the treated and untreated ovaries (22). Overall, the majority of recurrence occurs in the treated ovary, suggesting that the recurring cysts seem to grow from the residual loci (22). The mean monthly rate of growth of endometriomas following post-operative recurrence was about 0.48 cm in those not using any hormonal therapies (21).

The impact of endometriosis and endometriomas on fertility has been extensively studied and overall shows a detrimental effect. Several causes have been implicated including chronic inflammation which can affect the quality of the oocytes and impair ovarian function resulting in defective folliculogenesis and fertilisation; poor oocyte and embryo quality secondary to an altered follicular environment, leading to impaired fertilisation and embryos with reduced implantation capacity; poor ovarian reserve with a significant reduction in the primordial follicle cohort secondary to fibrosis from increased tissue oxidative stress (23) and finally, anatomical distortion and tubal damage or occlusion secondary to pelvic adhesions.

The evidence for poorer oocyte and embryo quality in patients with endometriosis and endometriomas remains patchy and inconclusive as majority of studies have only evaluated this indirectly. An example of indirect assessments of embryo quality are studies looking at miscarriage

rates. Two such studies found higher rates of miscarriages in patients with endometriosis/endometriomas compared to healthy controls following spontaneous conception (24, 25). Sanchez and colleagues performed a systematic review of the literature to evaluate the effect of endometriosis on oocyte quality from a clinical and biological perspective (26). They found that oocytes retrieved from women affected by endometriosis are more likely to fail in vitro maturation and showed altered morphology and a lower cytoplasmic mitochondrial content compared to women with other causes of infertility (26). A meta-analysis of 36 published studies involving women with all stages of endometriosis, found that clinical pregnancy rate was significantly lower for endometriosis patients (odds ratio, 0.78; 95% confidence interval, 0.65–0.94) when compared to women without endometriosis (27). These patients also demonstrated a significant decrease in the number of oocytes retrieved similar miscarriage rates. Another meta-analysis showed that live birth rates were not statistically different in women with and without endometriosis, although those with endometriosis had lower clinical pregnancy rates (28). Similarly, a further meta-analysis looking specifically at the impact of endometriomas on IVF outcomes included 30 retrospective and 3 randomized controlled studies and found similar live birth rates and clinical pregnancy rates but a lower mean number of eggs retrieved and higher cancellation rates in women with endometriomas compared with no endometriomas (29).

With regards to impact on ovarian reserve, two prospective studies demonstrated lower AMH levels and antral follicle counts (AFC) in women with endometriomas compared to age matched controls (30, 31). In a systematic review and meta-analysis looking at the impact of surgery for endometriomas, pooled analysis of preoperative AFC showed that the mean AFC for the ovary with the endometrioma was lower than the contralateral one (mean difference -2.79 , 95% confidence interval [CI] -7.10 to 1.51), but statistical significance was not reached ($p = 0.20$) (32). On histological studies, Schubert et al., showed that endometriotic cysts had lower follicular density compared to dermoid and serous

cysts (16). Furthermore, endometriotic cysts showed invasion of the surrounding cortex resulting in fibrosis and the surrounding cortical tissue had abnormal morphological patterns and irregular vascular network (16, 17). Endometriomas were also thought to negatively affect ovulation with one study showing lower ovulation rates in ovaries containing endometriomas over 10mm in size compared to the healthy contralateral ovary (33). However, more recently Maggiore and colleagues conducted a larger prospective study involving 244 women all of whom had a unilateral endometrioma more than 20mm in size and performed US monitoring for ovulation over 6 cycles (34). They found no difference in the ovulation rates between the affected ovary and healthy ovary (50.3% versus 49.7%, $p=0.919$) (33).

Occasionally, persistent hemorrhagic cysts can be mistaken for endometriomas on ultrasound scan and at laparoscopy. A hemorrhagic cyst is the result of bleeding into a follicular or corpus luteum cyst. Majority will spontaneously resolve like other functional cysts but occasionally they can become trapped by pelvic adhesions which can cause them to persist. These can be difficult to differentiate from endometriomas on ultrasound scan and at laparoscopy and the only way to confirm the diagnosis is by histology. Like other functional cysts, hemorrhagic cysts are unlikely to have any impact on fertility and thus a cystectomy for a hemorrhagic cyst is more likely to have an adverse effect.

Other benign ovarian cysts and their impact on fertility

Ovarian cystadenomas are common benign epithelial neoplasms of which serous and mucinous are two of the most common types seen (35, 36). Serous cystadenomas are more prevalent in menopausal women whilst the mucinous type mainly occurs during the 3rd to sixth decade (37). Mucinous cystadenomas are usually unilateral but they can grow large in

size, on average between 15 - 30cm (38, 39). To the best of our knowledge there is no literature on the impact of a mucinous cystadenoma on fertility. However, owing to the relatively large sizes of these cysts, there is a greater chance of oophorectomy. In addition, surgical spill of mucinous material can lead to pelvic adhesions and subsequent infertility.

Benign ovarian cysts in children and adolescents

Malignant ovarian cysts are uncommon in children and adolescents but despite this, oophorectomy is frequently performed in in this age group when presenting with ovarian cysts. One study found that 75% of oophorectomies in children and adolescents had being carried out for benign ovarian cysts (40). Functional ovarian cysts account for about 45% of all paediatric adnexal abnormalities (5) and usually resolve spontaneously. Teratomas constitute for about half of all ovarian neoplasms in children (41) and 1% of these are malignant immature teratomas (42). Since laparoscopic cystectomy has become the accepted practice for the management of mature cystic teratomas in adults, the same approach should apply to children and adolescents (42). With greater use of pre-operative investigations including pelvic imaging and tumour markers, along with a multidisciplinary team approach and more conservative surgery we should be able to better protect the future fertility of these young girls.

Ovarian torsion and impact on fertility

Ovarian torsion is a rare gynaecological emergency with approximately 3% of all emergency gynaecological surgery being performed for ovarian torsion (43, 44). One study found the cumulative incidence of ovarian torsion in women with ovarian tumours, over a 24-month period was 0.3% (45). Torsion usually involves the ovary and Fallopian tube and is more

commonly seen with benign cysts over 5cm in size (44). It can also occur in normal ovaries, particularly in pre-menarchal girls who have elongated infundibulopelvic ligaments (46).

Conservative management, which involves laparoscopic unwinding of the twisted ovary regardless of the macroscopic appearance has become the mainstay of treatment for ovarian torsion (47). When an ovary undergoes torsion and detorsion, it results in haemorrhage, congestion and apoptosis secondary to ischemia which can affect the ovarian reserve (48). To our knowledge, only one study has assessed ovarian reserve post detorsion and found no difference in the AFC between the affected and contralateral ovary at 3 months post op (48). Similarly, they found no difference in the AMH taken pre-operatively on the day of detorsion and at 1 month and 3 months post-op (48). Thus, laparoscopic detorsion appears to preserve ovarian reserve and this should remain the optimal treatment for ovarian torsion.

Ovarian cystectomy and its impact on ovarian reserve

There are several methods of performing ovarian cystectomy but in principle, it involves incising the ovarian cortex to identify the cyst capsule, removing the cyst wall with or without draining the cyst and finally applying haemostatic measures using monopolar or bipolar coagulation, suturing or intraovarian sealant agents (19). The size and nature of the cyst being removed, bilaterality and/or repeated surgery, method of cystectomy, method of haemostasis and of course the skill and experience of the surgeon are all important factors that will determine how much of an impact, if any, the cystectomy will have on future ovarian reserve.

The stripping and removing of the cyst wall and the thermal damage provoked by coagulation can lead to loss of healthy ovarian tissue and the subsequent reduction in the follicle density. Muzzi et al (2002) performed histological analysis on the excised specimens following laparoscopic excision of ovarian cysts using the stripping technique (49). The primary outcome in this study was to evaluate the presence and nature of ovarian tissue adjacent to the cyst wall. 54% of ovarian tissue was inadvertently excised along with the cyst wall in those with endometriotic cysts compared to 6% in those with non-endometriotic cysts (35). Furthermore, the excised ovarian tissue did not show morphological characteristics seen in normal ovarian tissue (35).

Several other studies have also demonstrated a reduction in the ovarian reserve following cystectomy for endometriomas, including a meta-analysis of 7 published studies showing a 30% decrease in the post-op AMH levels and a systematic review also demonstrating a decline in the ovarian reserve following surgery (3, 50, 51). Furthermore, two prospective longitudinal studies, showed partial recovery of AMH levels 3 months post operatively to about 65% of the preoperative level in both endometriotic and non-endometriotic cysts (52, 53). Similar findings of reduced ovarian reserve were seen in studies assessing ovarian reserve following cystectomy for non-endometriotic cysts, primarily dermoid cysts (52, 54, 55).

In contrast, Muzii et al (2014) analysed data from 13 publications which reported AFC pre- and post-endometrioma surgery and showed that ovarian reserve as assessed by AFC did not change significantly. The differences between the changes of these two surrogate markers (AMH and AFC) can probably be explained by the fact that AFC assessment is likely to be less reliable in the presence of endometriomas and that the preoperative AFC underestimates the value. This may then obscure the postoperative reduction in AFC (56).

The size of the cyst being removed is another important factor when determining the impact on ovarian reserve and future fertility. Using histological measurements of endometrioma cystectomy specimens, Roman et al. found an average loss of 200 μm of ovarian tissue per centimeter increase in endometrioma diameter (57). Several other studies also demonstrated a more significant decline in ovarian reserve following removal of endometriomas over 5 -7 cm in size (31, 58, 59). Additionally, there is a higher risk of oophorectomy when performing cystectomies for larger cysts which can further reduce a woman's reproductive potential. Clinicians frequently advise patients to delay surgery until a cyst reaches a particular size, when there is a significant risk of ovarian torsion. However, knowing that larger cystectomies are more likely to have a greater negative impact on a woman's future fertility, it may be better to proceed with surgery when the cyst is still small; especially in those with mucinous cystadenomas which have a propensity to grow into very large cysts (60).

Bilateral cystectomy can lead to a greater decline in the ovarian reserve compared to those having unilateral surgery (3, 61). In particular, women having surgery for bilateral endometriomas have been shown to have an increased risk of developing premature ovarian failure (20, 62).

Ovarian cystectomy and spontaneous conception

Higher rates of spontaneous conception have been shown in infertile women who had surgical treatment for endometriomas (63). Maggiore and colleagues looked at spontaneous pregnancy rates of women who tried to conceive spontaneously for a year and had known rectovaginal endometriosis with or without endometriomas and treated with expectant or surgical management (33). The crude and cumulative spontaneous pregnancy rate was higher in those with endometriomas and treated surgically than in those managed expectantly (30.4% and 34.5% versus 11.7% and 18.0% respectively)

(33). It has to be emphasized that this data applies to women who have a history of infertility and it would be difficult to recommend routine surgical treatment of endometriomas to improve chances of spontaneous conception in those without proven infertility. Even in the infertile woman with an endometrioma, the potential benefit of improving her chances of spontaneous conception through surgical management must be balanced with the risk of reducing her ovarian reserve and worsening the pelvic anatomy. The ESHRE Guideline Group for the management of women with endometriosis recommends that clinicians counsel women about the risk of a reduction in the ovarian reserve along with the possible loss of the entire ovary, in particular for those who have had previous ovarian surgery (55).

Ovarian cystectomy and IVF outcomes

Cystectomy prior to IVF treatment is not routinely recommended as it has not been shown to improve IVF outcomes. A Cochrane review assessed the effectiveness of surgery versus no treatment for improving reproductive outcomes among women with endometrioma prior to undergoing assisted reproductive technology (ART) (64). They included two trials comparing surgery (aspiration and cystectomy) with expectant management and found no evidence of benefit for clinical pregnancy rates (65, 66). One study in fact, showed a decreased ovarian response to gonadotrophins following cystectomy (65).

However, there are still some clinical circumstances when surgery should be considered. Garcia-Velasco and Somigliana have created the following table to help guide clinicians on the clinical variables that need to be considered when deciding whether to perform surgery or not in women with endometriomas selected for IVF (67).

Table I

Characteristics	Favours surgery	Favours management expectant
Previous interventions for endometriosis	None	≥1
Ovarian reserve ^a	Intact	Damaged
Pain symptoms	Present	Absent
Bilaterality	Monolateral disease	Bilateral disease
Sonographic feature of malignancy ^b	Present	Absent
Growth	Rapid growth	Stable

^aOvarian reserve is estimated based on serum markers or previous hyperstimulation cycles; ^bsonographic feature of malignancy refers to solid components, locularity, echogeniety, regularity of shape, wall, septa, location and presence of peritoneal fluid.

Reprinted from "Management of endometriomas in women requiring IVF: to touch or not to touch; by Garcia-Velasco, J. A. and Somigliana, E, 2009, Hum Reprod, 24, 496-501.

Impact of surgical technique on fertility outcomes

Apart from cyst excision, there are several other surgical techniques available for treating ovarian cysts including drainage and bipolar coagulation or ablation using plasma or laser energy. A systematic review of two RCTs revealed cystectomy to be superior to drainage and bipolar coagulation in terms of spontaneous pregnancy rates, lower risk of recurrence and

pain symptoms amongst sub-fertile patients with endometriomas greater than 3cm (68). However, there have also been several comparative studies that have shown better preservation of ovarian reserve when using laser ablation or plasma energy compared to cystectomy (69-71). On the other hand, higher recurrence rates were seen at 1 year post laser ablation compared to cystectomy (72).

There are also several methods of achieving haemostasis after a cystectomy which may have an impact on the ovarian reserve; these include bipolar diathermy, suturing or haemostatic sealants. A systematic review and meta-analysis of 12 published controlled trials showed that laparoscopic suturing was superior to bipolar coagulation when comparing AMH and AFC even at 12 months post surgery (73). In the comparison between bipolar and hemostatic sealants, the results favored the use of hemostatic agents (73).

Recommendations for ovarian cystectomy

1) Perform ovarian reserve assessments

Ovarian reserve assessments should be carried out prior to any cystectomy in the following situations:

- Women who have not completed their family
- Those requiring repeat surgery on the same or contralateral ovary

- Women diagnosed with severe endometriosis and bilateral endometriomas
- Those with co-existent aetiologies for subfertility including low sperm parameters in the male partner
- Women of advanced reproductive age
- Women with co-existent risk factors for premature ovarian insufficiency.

These patients are more likely to need ART to help them conceive in the future and/or are at increased risk of premature ovarian failure. Ovarian cystectomy can reduce a woman's ovarian reserve and a low ovarian reserve can hinder the chance of success with IVF treatment (74).

Ovarian reserve assessments will comprise of follicular phase follicle stimulating hormone (FSH) taken at the same time as an oestradiol level, a pelvic ultrasound scan for AFC and serum AMH. The accuracy of these tests in the presence of ovarian cysts have not been studied well. AFC and serum AMH have been shown to be lower in the presence of endometriomas but they did not appear to be affected by the presence of other types of cysts (30, 31, 75). The reduced AFC associated with endometrioma could be due to the inability to visualize the antral follicles on ultrasound scan in the presence of an endometrioma (76). This theory is further supported by Lima et al. who analyzed the number of oocytes retrieved during IVF/ICSI cycle in women with a unilateral endometrioma (77). Although the AFC was reduced in the ovaries with an endometrioma, the median number of oocytes retrieved was similar ($P = 0.60$) between ovaries with an endometrioma (2.0 (IQR, 0.5–5.0)) and the contralateral ovaries (2.0 (IQR, 0.0–4.0)) (73).

2) Discuss fertility preservation options

If the ovarian reserve is already compromised or there is a significant risk of permanent infertility from performing an ovarian cystectomy, fertility preservation in the form of oocyte or embryo cryopreservation should be discussed. For post-pubertal females, egg or embryo storage following ovarian stimulation is an established technique that allows for subsequent IVF and embryo transfer (78). If the ovarian reserve is already severely compromised, ovarian stimulation may be unsuccessful. The disadvantages of fertility preservation prior to cystectomy include delay in surgery, ovarian hyperstimulation syndrome which is uncommon when ovarian reserve is already compromised and small risk of visceral injury during egg collection and pelvic infection from accidental puncture of the cyst at egg collection (79).

NHS funding is not routinely available for oocyte or embryo cryopreservation other than for oncology patients. However, if there is a significant risk of permanent infertility, for example if the patient has had previous oophorectomy for ovarian torsion of a dermoid cyst and now has a recurrence of the dermoid cyst on the contralateral ovary, individual funding requests can be made to the relevant clinical commissioning group to consider NHS funded oocyte freezing prior to performing a cystectomy. The same would apply to patients with severe endometriosis requiring repeat surgery.

Ovarian tissue cryopreservation is another method of fertility preservation but one that is still considered experimental. It involves either taking an ovarian cortical biopsy or a complete unilateral oophorectomy. The ovarian tissue is subsequently re-implanted back in the pelvis and gradual resumption of ovarian follicle growth and endocrine activity have been seen; worldwide, only a small number of children have been born following reimplantation of frozen/thawed ovarian tissue (80).

This method of fertility preservation however may not be suitable for patients affected by ovarian cysts as it would cause a further reduction in the already compromised ovarian reserve.

3) Perform pelvic ultrasound scan and a bimanual examination

Assess type, size, number and location (unilateral or bilateral) of the ovarian cysts before surgery using pelvic ultrasound and bimanual examination. Greater impact of bilateral cystectomies should be taken into account.

4) Obtain appropriate consent

The patient should be fully informed of all possible risks associated with the surgical procedure, including a potentially reduced ovarian reserve, and the small risk of oophorectomy

5) Refer the woman to a centre of expertise

If the surgery cannot be performed or completed safely, the patient should be referred to a centre of expertise. Good surgical technique and expertise is of utmost importance in order to reduce the risk of injury to a woman's reproductive potential as well as avoid serious complications.

Anatomical consideration during cystectomy

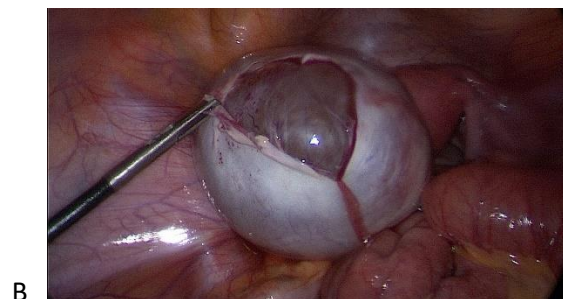
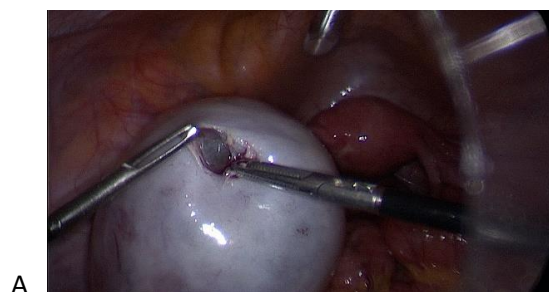The ovary receives its blood supply from two sources, the ovarian artery and an anastomosis between the ovarian artery and the ascending branch of the uterine artery/tubal artery. The ovarian artery approaches the ovary through the infundibulopelvic ligament whilst the uterine/tubal artery are found within the ovarian ligament. These intra-ovarian vessels are found in the anterolateral aspect

of the ovary, at the insertion of the mesovarium. The surgeon needs to avoid excessive bleeding which might lead to destruction of healthy ovarian tissue through cauterisation and disruption of ovarian blood supply (19).

Surgical recommendations

Non-endometriotic cysts

1. Make an incision on the anti-mesenteric surface of ovarian cortex (Figure 1A)
2. Identify the plane between the cyst wall and the ovarian cortex, develop this plane further (Figure 1B)
3. Enucleate the cyst or cyst wall (if the contents spilled or aspirated) by a combination of blunt and sharp dissection, traction and counter traction.
4. Achieve haemostasis by targeted coagulation of blood vessels (Figure 1C) or suturing (Figure 1D). Avoid indiscriminate use of diathermy and consider using haemostatic sealants instead of excessive diathermy.



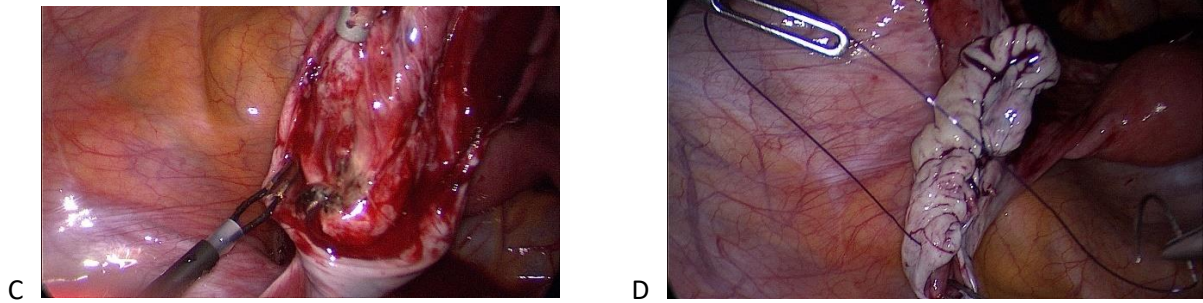


Figure 1

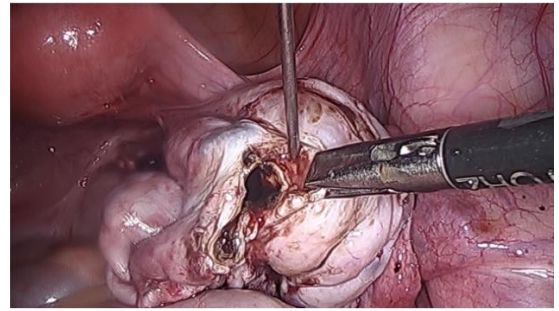
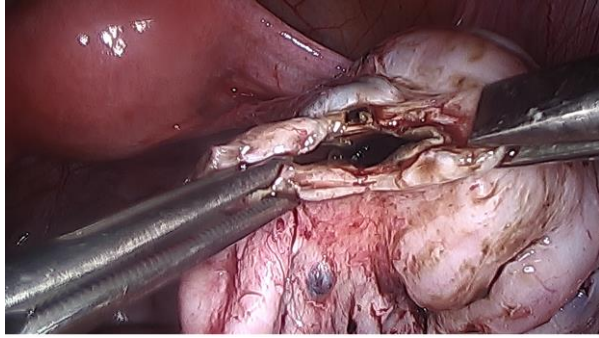
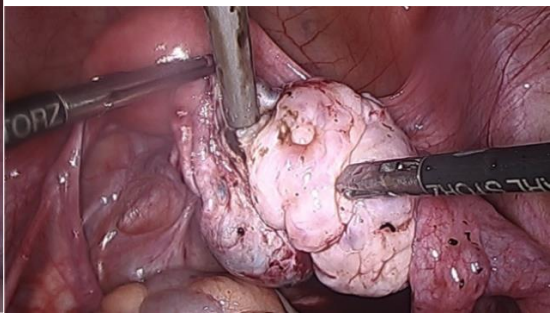
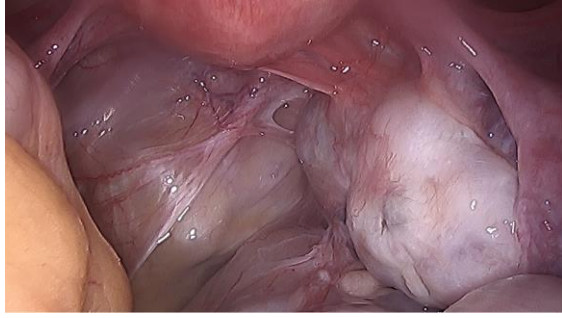
Ovarian cystectomy. A – reveal cleavage plane. B – dissect the cyst wall from the ovarian parenchyma. C & D – achieve haemostasis by targeted coagulation and/or suturing and then reconstruct the ovary.

Endometriotic cysts

The ESGE/ESHRE/WES Working Party on the surgical techniques for ovarian endometriomas recommends the following approaches (18):

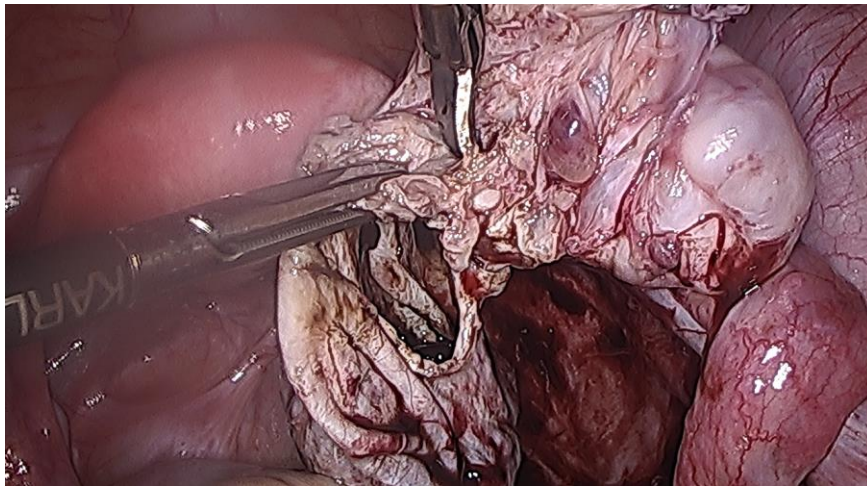
- 1) Mobilise the ovary and drain the cyst (Figure 2A and 2B).
- 2) Make incision to reveal the cleavage plane (2C). This may be either on the edge of the cyst opening or a central incision, which divides the cyst into two halves. With both approaches, the incision should be away from the blood vessels in the hilum/mesovarium. Use of cold cut at the edge of the cyst opening may assist in identifying the cleavage plane.
- 3) To aid dissection and identification of the cyst wall, saline or diluted synthetic vasopressin solution (0.1–1 unit/ml) may be injected under the cyst capsule (Figure 2D). The diluted synthetic vasopressin injection has the additional advantage of reducing bleeding during cyst removal.

- 4) Once the cleavage plane is identified, use gentle traction and counter-traction with appropriate instruments to dissect the cyst capsule from the ovarian parenchyma (Figure 2E and 2F). Avoid use of excessive force to separate a highly adherent cyst from the ovary. This is likely to cause tearing of the ovarian tissue, excessive bleeding, and the need for coagulation or diathermy, which will further damage the normal ovarian tissue.
- 5) Careful identification of the cleavage plane and precise spot bipolar coagulation is the key to achieve haemostasis (Figure 2G). This will prevent unnecessary damage to healthy tissue and avoids blind or excessive diathermy.
- 6) Ensure final haemostasis after complete removal of the cyst capsule. Bipolar coagulation, suturing or intraovarian haemostatic sealant agents may also be used for this purpose. It is important to avoid damaging the major blood supply at the hilum coming in from the ovarian and infundibulopelvic ligaments at this stage.
- 7) After removal of large cysts, reconstruct the ovary and achieve haemostasis with monofilament sutures. For small cysts, suturing is often not required as the ovarian opening usually approximates spontaneously. If a suture is used, it should ideally be placed inside the ovary, as the exposed suture may be prone to adhesion formation.
- 8) Small cyst walls may be retrieved directly through a port. Large cyst walls can be removed in a specimen retrieval bag.



A

B



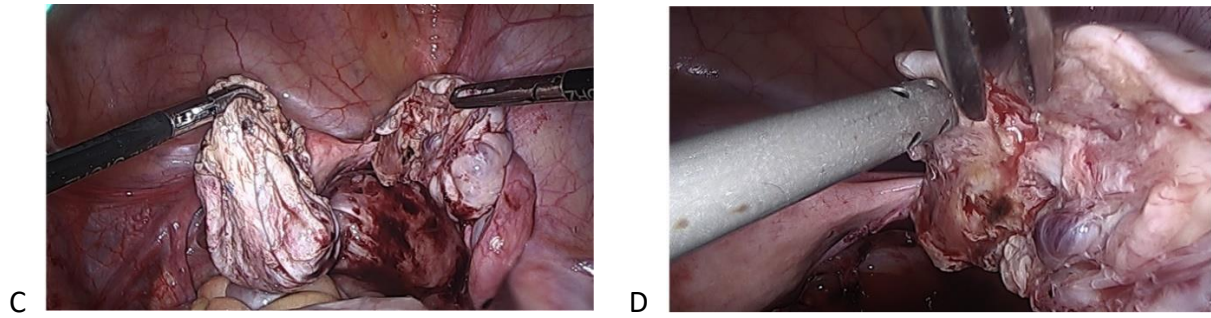


Figure 2

Ovarian cystectomy of an endometrioma. A - Right ovarian endometrioma and adherent right ovary B- drainage of endometrioma after mobilizing the ovary. C - exposure of the plane between the cyst wall and ovarian cortex D – vasopressin injection under the cyst capsule. E - dissect cyst capsule from the ovarian parenchyma. F- Cyst capsule after complete removal G – precise spot bipolar diathermy to achieve haemostasis.

Two-step approach for large endometriomas (19)

After opening and draining the endometrioma as described previously, the cyst wall is inspected and a biopsy taken. Gonadotropin-releasing hormone agonist (GnRHa) therapy is then given for 3 months to reduce the thickness of the cyst wall through atrophy and reduction in stromal vascularisation (81). The surgery is completed with a second laparoscopy in the form of either cystectomy, CO₂ vaporisation, bipolar diathermy or plasma ablation of the cyst wall lining of the cyst (19). Although women have to undergo two invasive procedures, the potential benefit is that this may facilitate the management of larger ovarian endometriomas, reduce recurrence rates and limit decrease in ovarian reserve (19).

Conclusion

Functional ovarian cysts and dermoid cysts do not appear to have a significant impact on fertility. Endometriomas appear to have a negative effect on oocyte quality and ovarian reserve. Surgical management has been shown to improve the chances of spontaneous conception in infertile women whilst reducing the ovarian reserve as determined by AMH levels. Ovarian response in those undergoing IVF treatments appears to be compromised after endometrioma surgery. Performing ovarian reserve assessments would be recommended in all women having repeated surgery, in those with severe endometriosis or if there is a high chance of needing ART to conceive. Regardless of whether or not a cystectomy is performed, it is imperative that the risk to fertility and ovarian function is discussed with all patients and that information on fertility preservation is given to those in whom the ovarian reserve is already compromised.

The management of benign ovarian cysts in women of reproductive age, children and adolescents is complex. The patient's symptom(s) is likely to have the biggest impact on the decision-making process. Those experiencing significant pain related to the cyst and unsuitable for hormonal therapy will often require surgery. Prior to an ovarian cystectomy, the surgeon should take careful consideration of the age of the patient, the nature of the cyst, rate of growth, risk of recurrence, surgical history, future fertility plans and assess for other causes of subfertility which would increase the likelihood of needing ART in the future, including the partners sperm parameters (3).

Societal changes in the Western world have resulted in trends towards pregnancy at older age with the average age of mothers in the UK now at 30.4 (82). With increasing age, there is a decline in the quality and quantity of oocytes which is accelerated from 37-38 years of age (83). At present we do not know the precise incidence of sub-fertility secondary to ovarian cystectomy. However, it is likely that the impact of cystectomy on future fertility will be worse in those women choosing to delay childbearing, in whom the ovarian reserve is already compromised. Hence, in the future, it is likely

that we may see a higher incidence of subfertility secondary to ovarian cystectomy. In the presence of a benign ovarian cyst, our recommendation of a fertility-focused approach, along with fertility-conserving surgery, will be the key to protecting a woman's reproductive potential.

Ethical approval

Not required.

Disclosure of interests

There are no conflicts of interest.

Contribution to authorship

NB and ES conceived the topic. NB planned the scope of the article, researched and wrote the initial draft. EY, DM and ES reviewed and revised the manuscript. All authors approved the final version.

Acknowledgements

The authors would like to thank the Editor of TOG for accepting this topic. No funding has been received for this work.

References

1. Westhoff C, Clark CJ. Benign ovarian cysts in England and Wales and in the United States. *Br J Obstet Gynaecol.* 1992;99(4):329-32.
2. Mimoun C, Fritel X, Fauconnier A, Deffieux X, Dumont A, Huchon C. [Epidemiology of presumed benign ovarian tumors]. *J Gynecol Obstet Biol Reprod (Paris).* 2013;42(8):722-9.

3. Legendre G, Catala L, Morinière C, Lacoëuille C, BouSSION F, Sentilhes L, et al. Relationship between ovarian cysts and infertility: what surgery and when? *Fertility and Sterility*. 2014;101(3):608-14.
4. Baerwald AR, Pierson RA. Ovarian follicular development during the use of oral contraception: a review. *Journal of obstetrics and gynaecology Canada : JOGC = Journal d'obstetrique et gynecologie du Canada : JOGC*. 2004;26(1):19-24.
5. Spinelli C, Di Giacomo M, Cei M, Mucci N. Functional ovarian lesions in children and adolescents: when to remove them. *Gynecological endocrinology : the official journal of the International Society of Gynecological Endocrinology*. 2009;25(5):294-8.
6. Grimes DA, Jones LB, Lopez LM, Schulz KF. Oral contraceptives for functional ovarian cysts. *The Cochrane database of systematic reviews*. 2014(4):CD006134.
7. Vermesh M, Kletzky OA, Davajan V, Israel R. Monitoring techniques to predict and detect ovulation. *Fertil Steril*. 1987;47(2):259-64.
8. Qublan H, Amarin Z, Nawasreh M, Diab F, Malkawi S, Al-Ahmad N, et al. Luteinized unruptured follicle syndrome: incidence and recurrence rate in infertile women with unexplained infertility undergoing intrauterine insemination. *Human reproduction (Oxford, England)*. 2006;21(8):2110-3.
9. Keltz MD, Jones EE, Duleba AJ, Polcz T, Kennedy K, Olive DL. Baseline cyst formation after luteal phase gonadotropin-releasing hormone agonist administration is linked to poor in vitro fertilization outcome. *Fertil Steril*. 1995;64(3):568-72.
10. Qublan HS, Amarin Z, Tahat YA, Smadi AZ, Kilani M. Ovarian cyst formation following GnRH agonist administration in IVF cycles: incidence and impact. *Human Reproduction*. 2006;21(3):640-4.
11. Keltz MD, Jones EE, Duleba AJ, Polcz T, Kennedy K, Olive DL. Baseline cyst formation after luteal phase gonadotropin-releasing hormone agonist administration is linked to poor in vitro fertilization outcome *. *Fertility and Sterility*. 1995;64(3):568-72.
12. Biljan MM, Lapensée L, Mahutte NG, Bissonnette F, Hemmings R, Tan SL. Effects of functional ovarian cysts detected on the 7th day of gonadotropin-releasing hormone analog administration on the outcome of IVF treatment. *Fertility and Sterility*. 2000;74(5):941-5.
13. Sampaio M, Serra V, Miro F, Calatayud C, Castellvi RM, Pellicer A. Development of ovarian cysts during gonadotrophin releasing hormone agonists (GnRHa) administration. *Human Reproduction*. 1991;6(2):194-7.
14. O'Neill KE, Cooper AR. The approach to ovarian dermoids in adolescents and young women. *Journal of pediatric and adolescent gynecology*. 2011;24(3):176-80.
15. Kim JY, Jee BC, Suh CS, Kim SH. Preoperative serum anti-mullerian hormone level in women with ovarian endometrioma and mature cystic teratoma. *Yonsei medical journal*. 2013;54(4):921-6.
16. Schubert B, Canis M, Darcha C, Artonne C, Pouly J-L, Déchelotte P, et al. Human ovarian tissue from cortex surrounding benign cysts: a model to study ovarian tissue cryopreservation. *Human Reproduction*. 2005;20(7):1786-92.
17. Maneschi F, Marasa L, Incandela S, Mazzaresse M, Zupi E. Ovarian cortex surrounding benign neoplasms: a histologic study. *American journal of obstetrics and gynecology*. 1993;169(2 Pt 1):388-93.
18. Caspi B, Weissman A, Zalel Y, Barash A, Tulandi T, Shoham Z. Ovarian stimulation and in vitro fertilization in women with mature cystic teratomas. *Obstetrics and gynecology*. 1998;92(6):979-81.
19. Saridogan E, Becker CM, Feki A, Grimbizis GF, Hummelshoj L, Keckstein J, et al. Recommendations for the surgical treatment of endometriosis-part 1: ovarian endometrioma. *Gynecological surgery*. 2017;14(1):27.
20. Coccia ME, Rizzello F, Mariani G, Bulletti C, Palagiano A, Scarselli G. Ovarian surgery for bilateral endometriomas influences age at menopause. *Human reproduction (Oxford, England)*. 2011;26(11):3000-7.
21. Seracchioli R, Mabrouk M, Frasca C, Manuzzi L, Montanari G, Keramyda A, et al. Long-term cyclic and continuous oral contraceptive therapy and endometrioma recurrence: a randomized controlled trial. *Fertil Steril*. 2010;93(1):52-6.

22. Exacoustos C, Zupi E, Amadio A, Amoroso C, Szabolcs B, Romanini ME, et al. Recurrence of endometriomas after laparoscopic removal: sonographic and clinical follow-up and indication for second surgery. *Journal of minimally invasive gynecology*. 2006;13(4):281-8.
23. The Effect of Surgery for Endometriomas on Fertility: Scientific Impact Paper No. 55. *BJOG : an international journal of obstetrics and gynaecology*. 2018;125(6):e19-e28.
24. Hjordt Hansen MV, Dalsgaard T, Hartwell D, Skovlund CW, Lidegaard O. Reproductive prognosis in endometriosis. A national cohort study. *Acta obstetrica et gynecologica Scandinavica*. 2014;93(5):483-9.
25. Vercellini P, Parazzini F, Pietropaolo G, Cipriani S, Frattaruolo MP, Fedele L. Pregnancy outcome in women with peritoneal, ovarian and rectovaginal endometriosis: a retrospective cohort study. *BJOG : an international journal of obstetrics and gynaecology*. 2012;119(12):1538-43.
26. Sanchez AM, Vanni VS, Bartiromo L, Papaleo E, Zilberberg E, Candiani M, et al. Is the oocyte quality affected by endometriosis? A review of the literature. *J Ovarian Res*. 2017;10(1):43.
27. Hamdan M, Dunselman G, Li TC, Cheong Y. The impact of endometrioma on IVF/ICSI outcomes: a systematic review and meta-analysis. *Hum Reprod Update*. 2015;21(6):809-25.
28. Harb HM, Gallos ID, Chu J, Harb M, Coomarasamy A. The effect of endometriosis on in vitro fertilisation outcome: a systematic review and meta-analysis. *BJOG : an international journal of obstetrics and gynaecology*. 2013;120(11):1308-20.
29. Hamdan M, Omar SZ, Dunselman G, Cheong Y. Influence of endometriosis on assisted reproductive technology outcomes: a systematic review and meta-analysis. *Obstetrics and gynecology*. 2015;125(1):79-88.
30. Uncu G, Kasapoglu I, Ozerkan K, Seyhan A, Oral Yilmaztepe A, Ata B. Prospective assessment of the impact of endometriomas and their removal on ovarian reserve and determinants of the rate of decline in ovarian reserve. *Human reproduction (Oxford, England)*. 2013;28(8):2140-5.
31. Chen Y, Pei H, Chang Y, Chen M, Wang H, Xie H, et al. The impact of endometrioma and laparoscopic cystectomy on ovarian reserve and the exploration of related factors assessed by serum anti-Mullerian hormone: a prospective cohort study. *Journal of ovarian research*. 2014;7:108-.
32. Muzii L, Di Tucci C, Di Felicianantonio M, Marchetti C, Perniola G, Panici PB. The effect of surgery for endometrioma on ovarian reserve evaluated by antral follicle count: a systematic review and meta-analysis. *Human reproduction (Oxford, England)*. 2014;29(10):2190-8.
33. Benaglia L, Somigliana E, Vercellini P, Abbiati A, Ragni G, Fedele L. Endometriotic ovarian cysts negatively affect the rate of spontaneous ovulation. *Human reproduction (Oxford, England)*. 2009;24(9):2183-6.
34. Leone Roberti Maggiore U, Scala C, Tafi E, Racca A, Biscaldi E, Vellone VG, et al. Spontaneous fertility after expectant or surgical management of rectovaginal endometriosis in women with or without ovarian endometrioma: a retrospective analysis. *Fertil Steril*. 2017;107(4):969-76.e5.
35. Seidman JD, Mehrotra A. Benign ovarian serous tumors: a re-evaluation and proposed reclassification of serous "cystadenomas" and "cystadenofibromas". *Gynecologic Oncology*. 2005;96(2):395-401.
36. El-Agwany AS. Recurrent Bilateral Mucinous Cystadenoma: Laparoscopic Ovarian Cystectomy with Review of Literature. *Indian J Surg Oncol*. 2018;9(2):146-9.
37. Saba L, Acharya UR, Guerriero S, Suri JS. *Ovarian Neoplasm Imaging: Springer Science & Business Media*; 2014.
38. Cowan RA, Haber EN, Faucz FR, Stratakis CA, Gomez-Lobo V. Mucinous Cystadenoma in Children and Adolescents. *Journal of pediatric and adolescent gynecology*. 2017;30(4):495-8.
39. Posabella A, Galetti K, Engelberger S, Giovannacci L, Gyr T, Rosso R. A huge mucinous cystadenoma of ovarian: a rare case report and review of the literature. *Rare Tumors*. 2014;6(2):5225-.
40. Hernon M, McKenna J, Busby G, Sanders C, Garden A. The histology and management of ovarian cysts found in children and adolescents presenting to a children's hospital from 1991 to 2007:

a call for more paediatric gynaecologists. *BJOG : an international journal of obstetrics and gynaecology*. 2010;117(2):181-4.

41. Azizkhan RG, Caty MG. Teratomas in childhood. *Current opinion in pediatrics*. 1996;8(3):287-92.
42. Templeman CL, Hertweck SP, Scheetz JP, Perlman SE, Fallat ME. The management of mature cystic teratomas in children and adolescents: a retrospective analysis. *Human Reproduction*. 2000;15(12):2669-72.
43. Hibbard LT. Adnexal torsion. *American Journal of Obstetrics & Gynecology*. 1985;152(4):456-61.
44. Houry D, Abbott JT. Ovarian torsion: a fifteen-year review. *Annals of emergency medicine*. 2001;38(2):156-9.
45. Froyman W, Landolfo C, De Cock B, Wynants L, Sladkevicius P, Testa AC, et al. Risk of complications in patients with conservatively managed ovarian tumours (IOTA5): a 2-year interim analysis of a multicentre, prospective, cohort study. *Lancet Oncol*. 2019;20(3):448-58.
46. Celik A, Ergun O, Aldemir H, Ozcan C, Ozok G, Erdener A, et al. Long-term results of conservative management of adnexal torsion in children. *Journal of pediatric surgery*. 2005;40(4):704-8.
47. Ben-Rafael Z, Bider D, Mashiach S. Laparoscopic unwinding of twisted ischemic hemorrhagic adnexum after in vitro fertilization. *Fertil Steril*. 1990;53(3):569-71.
48. Yasa C, Dural O, Bastu E, Zorlu M, Demir O, Ugurlucan FG. Impact of laparoscopic ovarian detorsion on ovarian reserve. *The journal of obstetrics and gynaecology research*. 2017;43(2):298-302.
49. Muzii L, Bianchi A, Crocè C, Mancini N, Panici PB. Laparoscopic excision of ovarian cysts: is the stripping technique a tissue-sparing procedure? *Fertility and Sterility*. 2002;77(3):609-14.
50. Raffi F, Metwally M, Amer S. The impact of excision of ovarian endometrioma on ovarian reserve: a systematic review and meta-analysis. *The Journal of clinical endocrinology and metabolism*. 2012;97(9):3146-54.
51. Somigliana E, Berlanda N, Benaglia L, Vigano P, Vercellini P, Fedele L. Surgical excision of endometriomas and ovarian reserve: a systematic review on serum antimullerian hormone level modifications. *Fertil Steril*. 2012;98(6):1531-8.
52. Chang HJ, Han SH, Lee JR, Jee BC, Lee BI, Suh CS, et al. Impact of laparoscopic cystectomy on ovarian reserve: serial changes of serum anti-Mullerian hormone levels. *Fertil Steril*. 2010;94(1):343-9.
53. Amooee S, Gharib M, Ravanfar P. Comparison of anti-mullerian hormone level in non-endometriotic benign ovarian cyst before and after laparoscopic cystectomy. *Iran J Reprod Med*. 2015;13(3):149-54.
54. Somigliana E, Ragni G, Infantino M, Benedetti F, Arnoldi M, Crosignani PG. Does laparoscopic removal of nonendometriotic benign ovarian cysts affect ovarian reserve? *Acta obstetrica et gynecologica Scandinavica*. 2006;85(1):74-7.
55. Sarmadi S, Ahmadi FS, Ejtemaei Mehr S, Ghaseminejad A, Mohammad K, Nekuie S, et al. Histopathologic and sonographic analysis of laparoscopic removal ovarian nonendometriotic cyst: the evaluating effects on ovarian reserve. *Acta Med Iran*. 2014;52(5):341-4.
56. Ata B, Urman B. Endometrioma excision and ovarian reserve; do assessments by antral follicle count and anti-Mullerian hormone yield contradictory results? *Human reproduction (Oxford, England)*. 2014;29(12):2852-4.
57. Roman H, Tarta O, Pura I, Opris I, Bourdel N, Marpeau L, et al. Direct proportional relationship between endometrioma size and ovarian parenchyma inadvertently removed during cystectomy, and its implication on the management of enlarged endometriomas. *Human reproduction (Oxford, England)*. 2010;25(6):1428-32.

58. Henes M, Engler T, Taran FA, Brucker S, Rall K, Janz B, et al. Ovarian cyst removal influences ovarian reserve dependent on histology, size and type of operation. *Women's health (London, England)*. 2018;14:1745506518778992.
59. Mehdizadeh Kashi A, Chaichian S, Ariana S, Fazaeli M, Moradi Y, Rashidi M, et al. The impact of laparoscopic cystectomy on ovarian reserve in patients with unilateral and bilateral endometrioma. *International journal of gynaecology and obstetrics: the official organ of the International Federation of Gynaecology and Obstetrics*. 2017;136(2):200-4.
60. Farahani L, Morgan S, Datta S. Reprint of: Benign ovarian cysts. *Obstetrics, Gynaecology and Reproductive Medicine*. 2017;27(7):226-30.
61. Hirokawa W, Iwase A, Goto M, Takikawa S, Nagatomo Y, Nakahara T, et al. The post-operative decline in serum anti-Mullerian hormone correlates with the bilaterality and severity of endometriosis. *Human reproduction (Oxford, England)*. 2011;26(4):904-10.
62. Busacca M, Riparini J, Somigliana E, Oggioni G, Izzo S, Vignali M, et al. Postsurgical ovarian failure after laparoscopic excision of bilateral endometriomas. *American Journal of Obstetrics & Gynecology*. 2006;195(2):421-5.
63. Vercellini P, Somigliana E, Vigano P, Abbiati A, Barbara G, Crosignani PG. Surgery for endometriosis-associated infertility: a pragmatic approach. *Human reproduction (Oxford, England)*. 2009;24(2):254-69.
64. Benschop L, Farquhar C, van der Poel N, Heineman MJ. Interventions for women with endometrioma prior to assisted reproductive technology. *The Cochrane database of systematic reviews*. 2010(11):Cd008571.
65. Demirol A, Guven S, Baykal C, Gurgan T. Effect of endometrioma cystectomy on IVF outcome: a prospective randomized study. *Reproductive biomedicine online*. 2006;12(5):639-43.
66. Alborzi S, Ravanbakhsh R, Parsanezhad ME, Alborzi M, Alborzi S, Dehbashi S. A comparison of follicular response of ovaries to ovulation induction after laparoscopic ovarian cystectomy or fenestration and coagulation versus normal ovaries in patients with endometrioma. *Fertil Steril*. 2007;88(2):507-9.
67. Garcia-Velasco JA, Somigliana E. Management of endometriomas in women requiring IVF: to touch or not to touch. *Human reproduction (Oxford, England)*. 2009;24(3):496-501.
68. Hart RJ, Hickey M, Maouris P, Buckett W. Excisional surgery versus ablative surgery for ovarian endometriomata. *The Cochrane database of systematic reviews*. 2008(2):Cd004992.
69. Tsolakidis D, Pados G, Vavilis D, Athanatos D, Tsalikis T, Giannakou A, et al. The impact on ovarian reserve after laparoscopic ovarian cystectomy versus three-stage management in patients with endometriomas: a prospective randomized study. *Fertil Steril*. 2010;94(1):71-7.
70. Candiani M, Ottolina J, Posadzka E, Ferrari S, Castellano LM, Tandoi I, et al. Assessment of ovarian reserve after cystectomy versus 'one-step' laser vaporization in the treatment of ovarian endometrioma: a small randomized clinical trial. *Human reproduction (Oxford, England)*. 2018;33(12):2205-11.
71. Roman H, Auber M, Mokdad C, Martin C, Diguët A, Marpeau L, et al. Ovarian endometrioma ablation using plasma energy versus cystectomy: a step toward better preservation of the ovarian parenchyma in women wishing to conceive. *Fertil Steril*. 2011;96(6):1396-400.
72. Carmona F, Martinez-Zamora MA, Rabanal A, Martinez-Roman S, Balasch J. Ovarian cystectomy versus laser vaporization in the treatment of ovarian endometriomas: a randomized clinical trial with a five-year follow-up. *Fertil Steril*. 2011;96(1):251-4.
73. Baracat CMF, Abdalla-Ribeiro HSA, Araujo R, Bernardo WM, Ribeiro PA. The Impact on Ovarian Reserve of Different Hemostasis Methods in Laparoscopic Cystectomy: A Systematic Review and Meta-analysis. *Rev Bras Ginecol Obstet*. 2019;41(6):400-8.
74. Leijdekkers JA, Eijkemans MJC, van Tilborg TC, Oudshoorn SC, McLernon DJ, Bhattacharya S, et al. Predicting the cumulative chance of live birth over multiple complete cycles of in vitro fertilization: an external validation study. *Human reproduction (Oxford, England)*. 2018;33(9):1684-95.

75. Almog B, Shehata F, Sheizaf B, Tulandi T. Effect of different types of ovarian cyst on antral follicle count. *Fertil Steril*. 2010;94(6):2338-9.
76. Cranney R, Condous G, Reid S. An update on the diagnosis, surgical management, and fertility outcomes for women with endometrioma. *Acta obstetrica et gynecologica Scandinavica*. 2017;96(6):633-43.
77. Lima ML, Martins WP, Coelho Neto MA, Nastri CO, Ferriani RA, Navarro PA. Assessment of ovarian reserve by antral follicle count in ovaries with endometrioma. *Ultrasound Obstet Gynecol*. 2015;46(2):239-42.
78. Balachandren N, Davies M. Fertility, ovarian reserve and cancer. *Maturitas*. 2017;105:64-8.
79. Moini A, Riazi K, Amid V, Ashrafi M, Tehraninejad E, Madani T, et al. Endometriosis may contribute to oocyte retrieval-induced pelvic inflammatory disease: report of eight cases. *Journal of assisted reproduction and genetics*. 2005;22(7-8):307-9.
80. Anderson RA, Wallace WH. Fertility preservation in girls and young women. *Clinical endocrinology*. 2011;75(4):409-19.
81. Donnez J, Nisolle M, Gillet N, Smets M, Bassil S, Casanas-Roux F. Large ovarian endometriomas. *Human reproduction (Oxford, England)*. 1996;11(3):641-6.
82. Office of National Statistics. Births in England and Wales: 2017 2018, July 18 [Available from: <https://www.ons.gov.uk/peoplepopulationandcommunity/birthsdeathsandmarriages/livebirths/bulletins/birthsummarytablesenglandandwales/2017#the-number-of-live-births-and-the-total-fertility-rate-decreased-in-2017>].
83. Faddy MJ, Gosden RG, Gougeon A, Richardson SJ, Nelson JF. Accelerated disappearance of ovarian follicles in mid-life: implications for forecasting menopause. *Human reproduction (Oxford, England)*. 1992;7(10):1342-6.