

**A SYSTEMATIC REVIEW OF NEUROIMAGING STUDIES OF DEPRESSION IN  
ADULTS WITH EPILEPSY**

**<sup>1</sup>Samia Elkommos and <sup>1,2</sup>Marco Mula**

**<sup>1</sup>Atkinson Morley Regional Neuroscience Centre, St George's University Hospitals NHS  
Foundation Trust, London, United Kingdom**

**<sup>2</sup>Institute of Medical and Biomedical Education, St George's University of London, United  
Kingdom**

Correspondence:

Marco Mula MD PhD FRCP FEAN  
Atkinson Morley Regional Neuroscience Centre  
St George's University Hospitals NHS Foundation Trust  
Blackshaw Road  
London SW17 0QT  
United Kingdom  
Tel. +442087254322  
Fax +442087254591  
Email: mmula@sgul.ac.uk

**Word count for the abstract: 232; Word count for the paper: 4090; Number of  
references: 81; Number of tables: 1; Number of figures: 1**

**ABSTRACT**

**Objective:** Depression is a relatively common comorbidity in people with epilepsy with a lifetime history identified in 1 in 4 individuals. In this paper, we aim to provide a systematic review of structural and functional brain region-specific group differences of adults with epilepsy and depression and to discuss existing evidence as compared to that in people with depression.

**Methods:** We undertook a systematic review of neuroimaging studies of depression in adults with epilepsy through MEDLINE/PubMed, Embase and PsycInfo searches until June 2020.

**Results:** A total of 44 studies were included in the qualitative synthesis: 21 on structural neuroimaging, 9 on functional and 14 on pharmaco/metabolic neuroimaging. Almost all studies focused on temporal lobe epilepsy (TLE). Patterns of changes in the hippocampi and subcortical structures seem to be different from those reported in depression outside epilepsy. Cortical changes are grossly similar as well as the lack of any laterality effect. Serotonin dysfunction seems to be due to different mechanisms with reduced synaptic availability for depression in epilepsy as compared to reduced 5HT1 receptor density outside epilepsy. Depressive symptoms seem to correlate with a dysfunction in temporolimbic structures contralateral to the epileptogenic zone especially in patients with de novo post-surgical depression.

**Conclusions:** Depression, at least in TLE, seems to be associated with a different pattern of brain changes as compared to major depression, potentially supporting the notion of phenomenological peculiarities of depression in epilepsy.

**Key words: epilepsy, depression, neuroimaging, serotonin, temporal lobe**

## 1. INTRODUCTION

Depression is a relatively frequent comorbidity in people with epilepsy, with a lifetime history identified in one of every four individuals [1]. A meta-analysis of 14 population-based studies including over 1,000,000 participants showed an overall prevalence of active (current or last 12 months) depression in epilepsy of 23.1% (95% CI 20.6% - 28.3%) with an increased overall risk of 2.7 (95% CI 2.09 - 3.6) compared with the general population [2].

The complex relationship between epilepsy and depression was well known since ancient times [3] but more recently, it became apparent that these two conditions have a complex and bidirectional relationship [4,5]. The nature of such a relationship seems to be based on quite a solid neurobiological ground apart from psychosocial reasons. Studies in animal models of epilepsy or depression have shown a number of neurobiological changes which can be responsible for both conditions including low serotonin levels [6–8], the reduction in CA3 neuronal cells in the dentate gyrus [9] and the acceleration of the kindling process by high cortisol levels [10]. The connection between epilepsy and depression is also suggested by the role of depression on the outcome of the seizure disorder. In fact, depression in epilepsy is associated not only with poor quality of life [11] but also with antiepileptic drug-resistance [12,13], increased seizure severity [14], increased side effects of anti-seizure medications (ASMs) [15], increased risk of accident and injuries [16], poor outcome after epilepsy surgery [17] and increased mortality [18].

From a neuroanatomical perspective, it is often highlighted that the link between epilepsy and depression is based on the involvement of shared networks comprising mesotemporal structures [19]. During the last few decades, neuroimaging studies have provided insights into brain structural alterations in people with depression without epilepsy, including decreased hippocampal volumes [20], decreased cortical thickness in the frontal lobes and decreased glial/neuronal cell density in the cingulate gyrus, rostral and caudal orbitofrontal cortex and dorsal prefrontal cortex [21,22]. Studies in epilepsy have identified similar areas and networks but data are scattered. In this paper, we aim to provide a systematic review of structural and functional brain region-specific group differences of adults with epilepsy and depression and to discuss existing evidence as compared to that in people with depression.

## 2. METHODS

This systematic review was conducted and reported according to the Preferred Reporting Items for Systematic Reviews and Meta-Analyses (PRISMA) statement. A PROSPERO protocol was developed and registered with registration number CRD42020197868.

A systematic database research on MEDLINE/PubMed, Embase and PsycInfo was conducted using the terms “depression or dysthymia or dysphoria or dysphoric AND epilepsy AND neuroimaging or magnetic resonance or MRI or MRS or positron emission tomography or PET or single photon emission computed tomography or SPECT or single photon emission tomography or SPET”. The search focused on original articles published until 1<sup>st</sup> June 2020. Inclusion criteria included only human studies of adult participants with any epilepsy diagnosis, depression symptomatology/diagnosis through any means including structured interviews, self-reported symptom scales or a combination of multiple methods. We excluded animal studies, as well as conference abstracts or proceedings. We further examined the reference list of all studies meeting our inclusion criteria to find relevant studies not directly identified by the search terms.

For included studies the following data were extracted: imaging technique (MRI, fMRI, MRS, PET, SPECT), publication details (publication names, authors, year of publication,

journal, and country), medication status of sample (% medicated and medications included), sample size, demographic characteristics of sample (age, sex), epilepsy type and diagnosis, seizure frequency, depression diagnosis and assessment, main findings. The authors assessed quality and risk of bias for each included study and disagreements were resolved with discussion. Heterogeneity of studies will be assessed by examining the proportion of studies (specific patient groups and/or particular type of paradigm) contributing to the significance of specific clusters.

### 3. RESULTS

The query revealed 635 results following removal of duplicates, 296 conference abstracts were then removed, and 274 entries were also removed, as they were not pertinent or relevant to the topic of this review (**Figure 1**). We included 44 studies in our systematic review. Qualitative synthesis of included studies is available in **Table 1**. We identified three major groups according to the methodology used: 21 structural, 9 functional and 14 pharmaco/metabolic neuroimaging studies. **One study was a MRI-PET study providing structural as well as metabolic data but it was counted only once and it is presented in the structural section of Table 1.**

### 4. STRUCTURAL NEUROIMAGING

There has been variation in findings from studies examining neuroimaging correlates of depression in patients with epilepsy.

Quiske [23] first suggested an association between depression rating scores and hippocampal sclerosis (HS) and subsequent authors investigated the relationship between laterality of HS and depression with studies supporting either right [24] or the left [25]. Subsequent authors pointed out that probably there is not a laterality effect and even the association between HS and depression was questioned with an equal number of studies showing an association [26] and other authors finding no association between depression and HS [27–29]. The association between depression and the presence of structural abnormalities in the temporal area was then questioned. Adams [30] showed higher incidence of depression in non-lesional focal epilepsies as compared to lesional ones and, more recently, Rayner [31] showed no difference in depression in patients with TLE and HS, TLE and lesions other than HS and MRI-negative TLE, suggesting that mood dysfunction in TLE is not dependent on macroscopic lesions but could be due to underlying network abnormalities.

Some studies have specifically looked at volumetric measurements of the hippocampus and amygdala and the relationship of this to depression in those with TLE. Shamim [32] and Baxendale [25] found that in those patients with right TLE and depression (regardless of whether HS was present) there were also reduced contralateral (left) hippocampal volumes compared to patients without concomitant depression. However, this finding was not replicated in a later study by Hecimovic et al 2014 [33] who found larger hippocampal volumes in those patients with TLE and depression compared to those without depression. Richardson and collaborators [34] found larger amygdala volumes in patients with TLE and depression as compared to patients without depression. Similarly, Van Elst [35] found enlarged left and right amygdala volumes in patients with TLE and dysthymia as well as a significant positive correlation between left amygdala volumes and Beck Depression Inventory (BDI) scores. However, a later study by the same authors [36] found reduced amygdala volumes in patients with epilepsy and concomitant dysphoric disorder, when compared to patients with either epilepsy without depression, or depression without epilepsy.

These earlier studies then gave rise to more recent studies, which have utilized voxel-based morphometry (VBM) to assess brain structure and volume. Salgado [37] showed that patients with TLE and depression had more areas of grey matter volume loss compared with patients with TLE without depression, and normal controls. A study by Butler and colleagues [38] used a different imaging methodology using a quantitative measure of surface-based MRI analysis to assess cortical thickness. They found that in patients with TLE, more severe depressive symptoms were associated with thickening of the orbitofrontal cortex. In contrast, in healthy controls, increasing severity of depression was associated with thinning of the orbitofrontal cortex.

There have also been other novel methods of assessing hippocampal atrophy in patients with TLE such as MRI radial atrophy mapping (RAM), a 3-D surface modeling tool for measuring hippocampal atrophy. Using this method Finegersh [39] found that TLE patients with depression had atrophy in the superoanterior portion of the hippocampus contralateral to seizure focus compared to those without depression, supporting that contralateral hippocampal atrophy in TLE may be related to depression. Finally, there have also been studies using diffusion tensor imaging to assess white matter abnormalities in patients with TLE and depression. Kavanaugh [40] found that white matter abnormalities, particularly within the frontotemporolimbic regions, are associated with depressive symptomatology in patients with TLE.

## **5. FUNCTIONAL NEUROIMAGING**

Functional neuroimaging studies revamped the importance of laterality and hemispheric asymmetries in epilepsy and depression. Doucet [41] demonstrated correlations between impaired functional connectivity and depression/ anxiety levels in both right and left TLE. However, in patients with right TLE, the higher the depression/ anxiety rating, the closer the functional connectivity values approached that of controls, whereas the reverse relationship was demonstrated for those with left TLE. The authors concluded that that right TLE has a more maladaptive impact on emotion-related networks (specific to the amygdala region), than left TLE. Functional changes in right TLE seem to involve also the ipsilateral hippocampal-cerebellar circuits [42].

A few authors showed that patients with epilepsy and depression present with a more complex network dysfunction, which may arise from disrupted fronto-limbic regions or the white matter tracts connecting them [43–46]. Patients with right TLE present with low contralateral uncinate fasciculus fractional anisotropy [44] which showed to be one of the strongest correlates of depressive symptoms. Right TLE and depression have been linked also to dysfunction of the default mode network [46,47]. Interestingly enough, a dysfunction in the default mode network was found also by the only study which focused on patients with genetic generalized epilepsies including juvenile myoclonic epilepsy, juvenile absence epilepsy and generalized tonic clonic seizures only [48].

## **6. PHARMACO AND METABOLIC NEUROIMAGING**

### **6.1 Cerebral Blood Flow**

Early studies used SPECT (Single-Photon Emission Computed Tomography) scanning to assess cerebral blood flow using the marker <sup>99m</sup>Tc-HMPAO. Using this technique, Ring [49] found that patients with TLE and depression present with relatively greater cerebral activity in several regions including the left frontal, temporal, parietal and subcortical

structures than those with epilepsy without depression. However, when compared to normal population data, these patients were not hyper-perfused despite demonstrating greater levels of perfusion and activity than non-depressed patients with epilepsy. Schmitz 1999 [50] also used 99m TC-HMPAO SPECT imaging but specifically compared patients with left versus right focal epilepsy in relation to measures of psychopathology and imaging perfusion findings. This study showed no differences between left and right epilepsy groups on measures of depression and obsessionality but did show different associations in relation to perfusion imaging. In patients with left sided epilepsy, higher scores on the Beck Depression Inventory were associated with lower contralateral temporal and bilateral frontal perfusion as well as higher occipital perfusion. In patients with right sided epilepsy, higher scores on the Leyton Obsessionality Inventory were associated with increased perfusion in ipsilateral temporal, thalamic and basal ganglia regions as well as bilateral frontal regions.

## 6.2 Magnetic Resonance Spectroscopy

Gilliam [51] used 1H magnetic resonance spectroscopy imaging (1H-MRSI) and examined the relationship between this and depressive symptoms as well as self-perceived social and vocational disability. This study found that the degree of hippocampal abnormalities as measured by 1H-MRSI correlated with severity of the depression rating scores. A study by Peng [52] also used 1H-MRSI but mostly in patients with idiopathic generalized epilepsy or unclassified epilepsy. This study also showed that patients with epilepsy and depression have elevated ratio of glutamate/ glutamine to creatine in the right hippocampus, and that this is independently correlated with the Hamilton Depression Rating Scale score.

## 6.3 FDG PET

Studies utilizing FDG-PET (18F Fluorodeoxyglucose PET) to assess cerebral blood glucose metabolism have been conducted in patients with drug resistant TLE undergoing pre-surgical evaluation and requiring PET imaging as part of the pre-surgical work-up. One of the earliest studies by Bromfield [53] showed that patients with left TLE and depressive symptoms present with bilateral frontal cortex hypometabolism as compared to non-depressed patients, as well as normal controls. A further study by Victoroff [54] extended these findings and suggested that the degree of interictal temporal lobe hypometabolism as well as the laterality of ictal onset represent independent factors to the development of depression. **However, Richardson et al. found no correlation between depressive symptoms and amygdala or hippocampus metabolism [34].**

## 6.4 Serotonin 5HT1A PET

A few studies have demonstrated a relationship between the presence of comorbid depression in TLE and altered binding of several tracers including [18F]-FCWAY, [18F]-MPPF and [11C]-WAY. However, both negative and positive correlations between these 5-HT1A receptor binding potentials and depression in patients with TLE have been reported.

One of the earlier studies to examine 5HT1A receptor binding in patients with TLE and depression was that by Theodore [55]. This study showed an inverse correlation between corrected [18F]-FCWAY ligand free fraction in the hippocampus ipsilateral to the seizure focus and depressive symptoms measured with the BDI. A similar but non-significant trend was found for the contralateral hippocampus. The presence of HS and the laterality did not have any effect on the BDI score. At the same time, Hasler and collaborators [56] replicated

the same findings in patients with TLE and a lifetime diagnosis of major depression but they also showed that in patients with TLE and depression the low levels of 5-HT<sub>1A</sub> receptor binding extended to non-lesional limbic areas beyond the epileptic focus itself. Interestingly, when only patients with current (active) depression were included, the hippocampus was the only area that had significantly reduced receptor binding. Hasler's study also replicated the finding that the laterality and HS are associated with a lifetime diagnosis of depression, emphasizing the role for reduced 5-HT<sub>1A</sub> receptor binding in the mechanisms underlying depression in patients with TLE. A subsequent study by Theodore [57] also showed an inverse relationship between [18F]-FCWAY ipsilateral binding and BDI scores and a direct relationship between left hippocampal binding and memory function.

Studies with different tracers include [18F]-MPPF and [11C]-WAY. Lothe [58] found PET evidence of bilateral changes in patients with TLE and depression using [18F]-MPPF tracer. This study included patients with current (active) depression and drug-resistant TLE and HS confirmed on MRI. However, the author pointed out that depressive symptoms in patients with TLE are more likely to be due to lower extracellular concentration of serotonin, rather than the downregulation of receptors. They also showed that cognition symptoms of depression, psychomotor retardation and anhedonia positively correlated with [18F]-MPPF binding in the raphe nuclei and insula contralateral to the seizure focus whereas somatic symptoms were found to be positively correlated with binding in the ipsilateral hippocampal and parahippocampal regions as well as bilaterally in the cingulate gyrus and inferior dorso-lateral frontal cortex.

Interestingly, a study by Assem-Hilger [59] using the [11C]-WAY tracer did not find a correlation between 5-HT<sub>1A</sub> receptor binding and depression scores, but their study included only 13 patients of which only 6 with depression.

## 6.5 Serotonin transporter 5HTT PET

Only two studies have evaluated the 5-HTT-serotonin transporter in patients with TLE and depression. Martinez [60] used the 5-HTT-transporter ligand 11C-3-amino-4-(2-dimethylaminomethylphenylsulfanyl)-benzo-nitrile (11C-DASB) as well as the [18F]-FCWAY ligand. This study pointed out that patients with TLE and depression have relatively reduced serotonin transporter activity ipsilateral to the seizure focus, compared to patients with TLE without depression or healthy controls. Conversely, Liik [61], using the radioligand 123I-ADAM in 7 patients with focal epilepsy and 5 patients with generalized epilepsy, showed no correlation between 123I-ADAM binding and depressive symptoms measured with the BDI or the EST-Q.

## 7. DISCUSSION

### 7.1 Overview of studies and limitations

Overall, almost all studies focused on TLE and a large majority of patients had HS. It is, therefore, unknown if these findings are specific to TLE or they apply to patients with GGE as well.

**All studies are cross-sectional and none of them explored the so-called bidirectional relationship between epilepsy and depression following patients prospectively.** Furthermore, the effect of treatment, both antidepressants and ASMs, is difficult to disentangle and not considered by almost all studies. The effect of antidepressants on brain structures in well-known [62]. The effect of ASMs on brain structures is less clear apart from

the developmental effects [63]. Theodore [64] have specifically explored the effect of ASMs on 5-HT<sub>1A</sub> receptor binding in patients with TLE using PET and showed no effect of ASM on [18F]-FCWAY. However, further studies clarifying this point are needed.

**Another limitation of these studies is the different approach in the assessment of depression and the heterogeneity of clinical instruments. Many studies explored current (active) symptoms of depression without structured clinical interview using standardized criteria to identify the underlying disorder. Depressive symptoms can occur in several conditions from major depression to persistent depressive disorder (formerly dysthymia) to bipolar disorder, psychotic depression etc. The lack of a categorical diagnosis using a structured clinical interview makes difficult to extend findings beyond the mood state.** In this regard, no studies distinguished between first depressive episode and recurrent depression and no studies have considered the number of previous depressive episodes as well as the age of onset of depression. All these factors, as discussed below, are important clinical correlate of neuroimaging findings in people with mood disorders.

Finally, authors did not compare their findings with the large literature on neuroimaging of depression outside epilepsy to try to dissect out the relative contribution of one condition as compared to the other.

## 7.2 Differences between major depression and depression in epilepsy

During recent years, most data on neuroimaging of major depressive disorder (MDD) came from the MDD Working Group of the Enhancing Neuroimaging Genetics through Meta-Analysis (ENIGMA) consortium based on Worldwide Data Sharing from 14 different countries including brain scans from around >5,000 patients with major depression and >9,000 controls [65]. Data from the ENIGMA consortium is providing high quality and highly reliable data on neuroimaging on depression outside epilepsy. Looking at the findings in epilepsy a few differences are noticeable despite the already mentioned limitations of the epilepsy literature.

Regarding structural neuroimaging, hippocampal volume loss is a well-established finding in MDD outside epilepsy [66,67] and, for a long time, it has been considered a very important link between epilepsy and depression. However, data from patients with MDD have pointed out that hippocampal atrophy is a reversible process with antidepressant treatments [68,69] while the same phenomenon does not seem to happen in epilepsy. Furthermore, hippocampal atrophy in MDD seems to be associated with an early onset of the depression (adolescence or childhood) and correlates with the number of depressive episodes and more chronic and persistent symptoms [70]. Interestingly enough, hippocampal volume loss in MDD seems to largely predate the onset of depression as a clinical syndrome [71]. This point can be of potential interest regarding the so-called bidirectional relationship with epilepsy, but no studies have investigated this point.

Finally, the hippocampal areas involved seem to be different between epilepsy and MDD. In fact, in MDD CA2 and CA3 are usually affected with relative preservation of other areas apart from the subiculum [71] while HS involves especially CA1 and CA4 [72]. All studies in patients with epilepsy and depression are concordant in hippocampal volume loss as an hallmark but it is still unknown whether this is more the “epilepsy-type” or “MDD-type” of atrophy in terms of hippocampal structures involved and whether there is a degree of potential reversibility with antidepressant treatment.



Another difference between studies in MDD and depression in epilepsy is the involvement of cortical and subcortical structures. In MDD, it is well established that adult onset MDD is mainly characterized by cortical abnormalities with relative preservation of subcortical structures apart from the hippocampi. Smaller amygdalae are, for example, reported in early onset (childhood, adolescence) depression [71]. Conversely, studies of depression in epilepsy report a number of changes in subcortical structures, especially the amygdala, despite being an adult onset depression.

On the other hand, pattern of cortical changes seem to be similar in both MDD and depression in epilepsy focusing on cortico-limbic thickness alterations including the anterior cingulate and prefrontal cortex as well as medial orbitofrontal cortex which seems to correlate with hippocampal volumes [71]. Another concordant point between studies of depression in epilepsy and studies in MDD is the lack of a laterality effect. Though not specifically investigated in MDD, hemispheric asymmetries seem to play a marginal role [73]. In the same way, the involvement of one specific hemisphere by the epileptic dysfunction does not seem to play a relevant role in terms of pathophysiology. Early PET [53,54] and SPECT studies [50] seem to suggest that left TLE was more likely to be associated with frontal lobe dysfunction and depression, a phenomenon also known as “hypo-frontality” [50]. However, all studies taken together do not suggest an increased association between left TLE as compared to right TLE. A dysfunction in cortico-limbic networks involving the frontal lobes is in fact reported also in MDD.

Data on the involvement of the default mode network seem to be different as MDD seems to be associated with hyperconnectivity [74] while TLE with or without depression is associated with hypoconnectivity [75]. Implications of these differences need to be investigated.

Data coming from pharmaco-neuroimaging are quite interesting. Reduced 5HT1A binding was shown in both MDD and depression in epilepsy. Reduced 5HT1A seems to reflect hippocampal network inhibition mediated by raphe nuclei hypofunction [76]. However, while studies in MDD point towards reduced receptor density than low serotonin levels, studies of depression in epilepsy point towards reduced serotonin levels and serotonin availability. Low serotonin levels have been reported in several animal models of epilepsy and it has been claimed as one of the main mechanisms behind the double relationship between epilepsy and depression [6]. Whether chronically low levels may determine over time network changes responsible for both conditions need to be further clarified.

### **7.3 Post-surgical depression**

Depression following epilepsy surgery deserves a separate discussion. Some neuroimaging studies specifically investigated post-surgical depression. Paparrigopoulos [77] showed that severity of depressive symptomatology in operated patients correlated with the extent of hippocampal and amygdala resection particularly in left-side resections. Wrench [78] explored whether pre-operative MRI hippocampal volumes were associated with depression following epilepsy surgery and demonstrated different findings for those undergoing mesial temporal lobe resections as compared to non-mesial temporal lobe resections. In those undergoing mesial temporal lobe resections, post-operative depression was associated with smaller hippocampal volumes contralateral to the resection and this was also seen for those patients who developed de novo depression. However, for patients with non-mesial temporal lobe epilepsy hippocampal volumes were not related to post-operative depression. Pope [79] specifically looked at patients who developed de novo depression post-operatively using VBM assessment. Patients with left-sided HS who developed de novo depression within 4-

years post-operatively were found to have reduced preoperative bilateral grey matter in orbitofrontal cortices, ipsilateral cingulate gyrus, and thalamus. This is also supported by pharmaco-MRI studies looking at patients undergoing epilepsy surgery. Functional MRI studies in patients with TLE undergoing anterior temporal lobe resections have found specific patterns of activation in patients with right-sided HS but not left. Bonelli [80], using a memory encoding functional MRI paradigm, showed that patients with right TLE, amygdala activation was significantly related to pre-operative levels of anxiety and depression. Activation of the right amygdala pre-operatively was also predictive of post-operative changes of anxiety and depression, but these findings were not demonstrated for patients with left TLE. Salzberg [81] showed that patients with TLE and a history of depression preoperatively had focal hypometabolism in the left orbitofrontal cortex compared to those without a preoperative history of depression and these patients also developed depression post-operatively.

## **8. CONCLUSIONS AND FUTURE DIRECTIONS**

Most neuroimaging studies of depression in epilepsy focused on structural abnormalities in patients with TLE. These studies have shown more widespread subcortical abnormalities as compared to studies in MDD. The pattern of hippocampal abnormalities seems to be different in MDD as compared to HS suggesting that HS per se may not be relevant. Functional neuroimaging studies have shown network dysfunctions like those described in MDD and involving primarily the fronto-limbic circuits. These studies have also often showed a correlation between depressive symptoms and a dysfunction in temporolimbic structures contralateral to the epileptogenic zone especially in patients with post-surgical depression. However, further studies are needed to clarify this point.

Whether differences are clinically relevant and subtend phenomenological or clinical variations is difficult to tell but they may strongly support the notion that depression in epilepsy, at least in TLE, may be phenomenologically different from depression outside epilepsy. Studies aimed at clarifying this point are urgently needed.

Future studies will also need to focus on other epilepsy syndromes, as data on GGE or other syndromes are, at present, non-existent. These data will clarify whether brain changes seen in patients with TLE and depression are more similar to MDD or those reported in TLE, providing further insights on the role of temporal structures on mood dysfunction in epilepsy. Finally, studies should also focus on new onset epilepsies investigating prospectively brain changes in order to clarify neurobiological mechanisms behind the bi-directional relationship between epilepsy and depression.

## **9. ACKNOWLEDGMENT**

This work did not receive any specific funding.

## **10. CONFLICTS OF INTEREST**

SE reports no conflict of interests. MM reports personal fees from UCB, Eisai, Bial, Elsevier, outside the submitted work; in addition, he also has intellectual property rights with Springer and Elsevier.

## 11. REFERENCES

- [1] Mula M. Depression in epilepsy: Current Opinion in Neurology 2017;30:180–6. <https://doi.org/10.1097/WCO.0000000000000431>.
- [2] Fiest KM, Dykeman J, Patten SB, Wiebe S, Kaplan GG, Maxwell CJ, et al. Depression in epilepsy: A systematic review and meta-analysis. *Neurology* 2013;80:590–9. <https://doi.org/10.1212/WNL.0b013e31827b1ae0>.
- [3] Temkin O. *The falling sickness: a history of epilepsy from the Greeks to the beginnings of modern neurology*. 2. ed., rev. Baltimore: Hopkins Univ. Press; 1994.
- [4] Adelow C, Andersson T, Ahlbom A, Tomson T. Hospitalization for psychiatric disorders before and after onset of unprovoked seizures/epilepsy. *Neurology* 2012;78:396–401. <https://doi.org/10.1212/WNL.0b013e318245f461>.
- [5] Hesdorffer DC, Ishihara L, Mynepalli L, Webb DJ, Weil J, Hauser WA. Epilepsy, suicidality, and psychiatric disorders: A bidirectional association. *Ann Neurol* 2012;72:184–91. <https://doi.org/10.1002/ana.23601>.
- [6] Kanner AM. Can neurobiological pathogenic mechanisms of depression facilitate the development of seizure disorders? *The Lancet Neurology* 2012;11:1093–102. [https://doi.org/10.1016/S1474-4422\(12\)70201-6](https://doi.org/10.1016/S1474-4422(12)70201-6).
- [7] Mazarati A, Siddarth P, Baldwin RA, Shin D, Caplan R, Sankar R. Depression after status epilepticus: behavioural and biochemical deficits and effects of fluoxetine. *Brain* 2008;131:2071–83. <https://doi.org/10.1093/brain/awn117>.
- [8] Jobe PC. Common pathogenic mechanisms between depression and epilepsy: an experimental perspective. *Epilepsy & Behavior* 2003;4:14–24. <https://doi.org/10.1016/j.yebeh.2003.08.020>.
- [9] Rajkowska G, Miguel-Hidalgo JJ, Wei J, Dilley G, Pittman SD, Meltzer HY, et al. Morphometric evidence for neuronal and glial prefrontal cell pathology in major depression\*\*See accompanying Editorial, in this issue. *Biological Psychiatry* 1999;45:1085–98. [https://doi.org/10.1016/S0006-3223\(99\)00041-4](https://doi.org/10.1016/S0006-3223(99)00041-4).
- [10] Kumar G, Couper A, O'Brien TJ, Salzberg MR, Jones NC, Rees SM, et al. The acceleration of amygdala kindling epileptogenesis by chronic low-dose corticosterone involves both mineralocorticoid and glucocorticoid receptors. *Psychoneuroendocrinology* 2007;32:834–42. <https://doi.org/10.1016/j.psyneuen.2007.05.011>.
- [11] Boylan LS, Flint LA, Labovitz DL, Jackson SC, Starner K, Devinsky O. Depression but not seizure frequency predicts quality of life in treatment-resistant epilepsy. *Neurology* 2004;62:258–61. <https://doi.org/10.1212/01.WNL.0000103282.62353.85>.
- [12] Hitiris N, Mohanraj R, Norrie J, Sills GJ, Brodie MJ. Predictors of pharmacoresistant epilepsy. *Epilepsy Research* 2007;75:192–6. <https://doi.org/10.1016/j.eplepsyres.2007.06.003>.
- [13] Nogueira MH, Yasuda CL, Coan AC, Kanner AM, Cendes F. Concurrent mood and anxiety disorders are associated with pharmacoresistant seizures in patients with MTLE. *Epilepsia* 2017;58:1268–76. <https://doi.org/10.1111/epi.13781>.
- [14] Cramer JA, Blum D, Reed M, Fanning K, Epilepsy Impact Project Group. The Influence of Comorbid Depression on Seizure Severity. *Epilepsia* 2003;44:1578–84. <https://doi.org/10.1111/j.0013-9580.2003.28403.x>.
- [15] Mula M, von Oertzen TJ, Cock HR, Lozsadi DA, Agrawal N. Clinical correlates of memory complaints during AED treatment. *Acta Neurol Scand* 2016;134:368–73. <https://doi.org/10.1111/ane.12553>.

- [16] Gur-Ozmen S, Mula M, Agrawal N, Cock HR, Lozsadi D, von Oertzen TJ. The effect of depression and side effects of antiepileptic drugs on injuries in patients with epilepsy. *Eur J Neurol* 2017;24:1135–9. <https://doi.org/10.1111/ene.13346>.
- [17] Kanner AM, Byrne R, Chicharro A, Wu J, Frey M. A lifetime psychiatric history predicts a worse seizure outcome following temporal lobectomy. *Neurology* 2009;72:793–9. <https://doi.org/10.1212/01.wnl.0000343850.85763.9c>.
- [18] Fazel S, Wolf A, Långström N, Newton CR, Lichtenstein P. Premature mortality in epilepsy and the role of psychiatric comorbidity: a total population study. *The Lancet* 2013;382:1646–54. [https://doi.org/10.1016/S0140-6736\(13\)60899-5](https://doi.org/10.1016/S0140-6736(13)60899-5).
- [19] Kanner AM, Schachter SC, Barry JJ, Hersdorffer DC, Mula M, Trimble M, et al. Depression and epilepsy: Epidemiologic and neurobiologic perspectives that may explain their high comorbid occurrence. *Epilepsy & Behavior* 2012;24:156–68. <https://doi.org/10.1016/j.yebeh.2012.01.007>.
- [20] Sheline YI, Gado MH, Kraemer HC. Untreated Depression and Hippocampal Volume Loss. *AJP* 2003;160:1516–8. <https://doi.org/10.1176/appi.ajp.160.8.1516>.
- [21] Cotter D. Reduced Neuronal Size and Glial Cell Density in Area 9 of the Dorsolateral Prefrontal Cortex in Subjects with Major Depressive Disorder. *Cerebral Cortex* 2002;12:386–94. <https://doi.org/10.1093/cercor/12.4.386>.
- [22] Cotter D, Mackay D, Landau S, Kerwin R, Everall I. Reduced Glial Cell Density and Neuronal Size in the Anterior Cingulate Cortex in Major Depressive Disorder. *Arch Gen Psychiatry* 2001;58:545. <https://doi.org/10.1001/archpsyc.58.6.545>.
- [23] Quiske A, Helmstaedter C, Lux S, Elger CE. Depression in patients with temporal lobe epilepsy is related to mesial temporal sclerosis. *Epilepsy Research* 2000;39:121–5. [https://doi.org/10.1016/S0920-1211\(99\)00117-5](https://doi.org/10.1016/S0920-1211(99)00117-5).
- [24] Nees H, Moriarty J, Kitchen ND, Trimble MR. Psychosocial and Neurobehavioral Factors Related to Surgical Treatment for Partial Epilepsy: A Multivariate Analysis. *Epilepsy & Behavior* 2001;2:135–9. <https://doi.org/10.1006/ebbeh.2001.0161>.
- [25] Baxendale SA, Thompson PJ, Duncan JS. Epilepsy & depression: The effects of comorbidity on hippocampal volume—A pilot study. *Seizure* 2005;14:435–8. <https://doi.org/10.1016/j.seizure.2005.07.003>.
- [26] Sanchez-Gistau V, Sugranyes G, Baillés E, Carreño M, Donaire A, Bargalló N, et al. Is major depressive disorder specifically associated with mesial temporal sclerosis?: Mesial Temporal Sclerosis. *Epilepsia* 2012;53:386–92. <https://doi.org/10.1111/j.1528-1167.2011.03373.x>.
- [27] Devinsky O, Barr WB, Vickrey BG, Berg AT, Bazil CW, Pacia SV, et al. Changes in depression and anxiety after resective surgery for epilepsy. *Neurology* 2005;65:1744–9. <https://doi.org/10.1212/01.wnl.0000187114.71524.c3>.
- [28] Briellmann RS, Hopwood MJ, Jackson GD. Major depression in temporal lobe epilepsy with hippocampal sclerosis: clinical and imaging correlates. *Journal of Neurology, Neurosurgery & Psychiatry* 2007;78:1226–30. <https://doi.org/10.1136/jnnp.2006.104521>.
- [29] Gonçalves EB, de Oliveira Cardoso TAM, Yasuda CL, Cendes F. Depressive disorders in patients with pharmaco-resistant mesial temporal lobe epilepsy. *J Int Med Res* 2018;46:752–60. <https://doi.org/10.1177/0300060517717825>.
- [30] Adams SJ, O'Brien TJ, Lloyd J, Kilpatrick CJ, Salzberg MR, Velakoulis D. Neuropsychiatric morbidity in focal epilepsy. *Br J Psychiatry* 2008;192:464–9. <https://doi.org/10.1192/bjp.bp.107.046664>.
- [31] Rayner G, Tailby C, Jackson G, Wilson S. Looking beyond lesions for causes of neuropsychological impairment in epilepsy. *Neurology* 2019;92:e680–9. <https://doi.org/10.1212/WNL.0000000000006905>.

- [32] Shamim S, Hasler G, Liew C, Sato S, Theodore WH. Temporal lobe epilepsy, depression, and hippocampal volume. *Epilepsia* 2009;50:1067–71. <https://doi.org/10.1111/j.1528-1167.2008.01883.x>.
- [33] Hecimovic H, Santos J, Price JL, Sheline YI, Mintun MA, Snyder AZ, et al. Severe hippocampal atrophy is not associated with depression in temporal lobe epilepsy. *Epilepsy & Behavior* 2014;34:9–14. <https://doi.org/10.1016/j.yebeh.2014.02.034>.
- [34] Richardson EJ, Griffith HR, Martin RC, Paige AL, Stewart CC, Jones J, et al. Structural and functional neuroimaging correlates of depression in temporal lobe epilepsy. *Epilepsy & Behavior* 2007;10:242–9. <https://doi.org/10.1016/j.yebeh.2006.11.013>.
- [35] Tebartz van Elst L, Woermann FG, Lemieux L, Trimble MR. Amygdala enlargement in dysthymia—a volumetric study of patients with temporal lobe epilepsy. *Biological Psychiatry* 1999;46:1614–23. [https://doi.org/10.1016/S0006-3223\(99\)00212-7](https://doi.org/10.1016/S0006-3223(99)00212-7).
- [36] Elst LT van, Groffmann M, Ebert D, Schulze-Bonhage A. Amygdala volume loss in patients with dysphoric disorder of epilepsy. *Epilepsy & Behavior* 2009;16:105–12. <https://doi.org/10.1016/j.yebeh.2009.06.009>.
- [37] Salgado PCB, Yasuda CL, Cendes F. Neuroimaging changes in mesial temporal lobe epilepsy are magnified in the presence of depression. *Epilepsy & Behavior* 2010;19:422–7. <https://doi.org/10.1016/j.yebeh.2010.08.012>.
- [38] Butler T, Blackmon K, McDonald CR, Carlson C, Barr WB, Devinsky O, et al. Cortical thickness abnormalities associated with depressive symptoms in temporal lobe epilepsy. *Epilepsy & Behavior* 2012;23:64–7. <https://doi.org/10.1016/j.yebeh.2011.10.001>.
- [39] Finegersh A, Avedissian C, Shamim S, Dustin I, Thompson PM, Theodore WH. Bilateral hippocampal atrophy in temporal lobe epilepsy: Effect of depressive symptoms and febrile seizures: 3D Surface Mapping of Epilepsy Comorbidities. *Epilepsia* 2011;52:689–97. <https://doi.org/10.1111/j.1528-1167.2010.02928.x>.
- [40] Kavanaugh B, Correia S, Jones J, Blum A, LaFrance WC, Davis JD. White matter integrity correlates with depressive symptomatology in temporal lobe epilepsy. *Epilepsy & Behavior* 2017;77:99–105. <https://doi.org/10.1016/j.yebeh.2017.07.035>.
- [41] Doucet GE, Skidmore C, Sharan AD, Sperling MR, Tracy JI. Functional connectivity abnormalities vary by amygdala subdivision and are associated with psychiatric symptoms in unilateral temporal epilepsy. *Brain and Cognition* 2013;83:171–82. <https://doi.org/10.1016/j.bandc.2013.08.001>.
- [42] Peng W, Mao L, Yin D, Sun W, Wang H, Zhang Q, et al. Functional network changes in the hippocampus contribute to depressive symptoms in epilepsy. *Seizure* 2018;60:16–22. <https://doi.org/10.1016/j.seizure.2018.06.001>.
- [43] Chen S, Wu X, Lui S, Wu Q, Yao Z, Li Q, et al. Resting-state fMRI study of treatment-naïve temporal lobe epilepsy patients with depressive symptoms. *NeuroImage* 2012;60:299–304. <https://doi.org/10.1016/j.neuroimage.2011.11.092>.
- [44] Kemmotsu N, Kucukboyaci NE, Leyden KM, Cheng CE, Girard HM, Iragui VJ, et al. Frontolimbic brain networks predict depressive symptoms in temporal lobe epilepsy. *Epilepsy Research* 2014;108:1554–63. <https://doi.org/10.1016/j.eplepsyres.2014.08.018>.
- [45] Kemmotsu N, Kucukboyaci NE, Cheng CE, Girard HM, Tecoma ES, Iragui VJ, et al. Alterations in functional connectivity between the hippocampus and prefrontal cortex as a correlate of depressive symptoms in temporal lobe epilepsy. *Epilepsy & Behavior* 2013;29:552–9. <https://doi.org/10.1016/j.yebeh.2013.09.039>.
- [46] Zhu X, He Z, Luo C, Qiu X, He S, Peng A, et al. Altered spontaneous brain activity in MRI-negative refractory temporal lobe epilepsy patients with major depressive disorder: A resting-state fMRI study. *Journal of the Neurological Sciences* 2018;386:29–35. <https://doi.org/10.1016/j.jns.2018.01.010>.

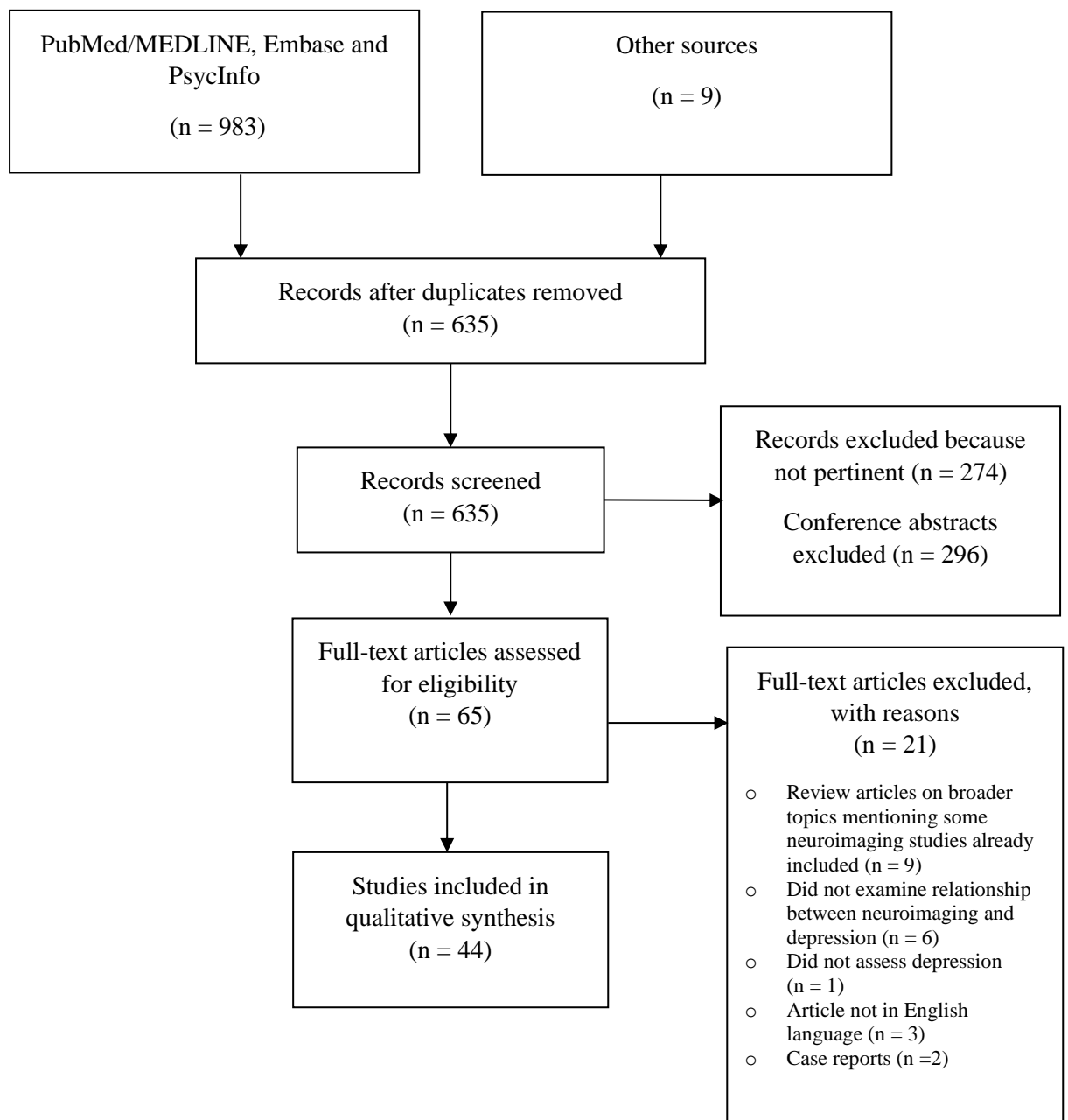
- [47] Stretton J, Pope RA, Winston GP, Sidhu MK, Symms M, Duncan JS, et al. Temporal lobe epilepsy and affective disorders: the role of the subgenual anterior cingulate cortex. *Journal of Neurology, Neurosurgery & Psychiatry* 2015;86:144–51. <https://doi.org/10.1136/jnnp-2013-306966>.
- [48] Garcia D dos S, Polydoro MS, Alvim MKM, Ishikawa A, Moreira JCV, Nogueira MH, et al. Anxiety and depression symptoms disrupt resting state connectivity in patients with genetic generalized epilepsies. *Epilepsia* 2019;60:679–88. <https://doi.org/10.1111/epi.14687>.
- [49] Ring HA, Acton PD, Scull D, Costa DC, Gacinovik S, Trimble MR. Patterns of brain activity in patients with epilepsy and depression. *Seizure* 1999;8:390–7. <https://doi.org/10.1053/seiz.1999.0320>.
- [50] Schmitz EB, Moriarty J, Costa DC, Ring HA, Ell PJ, Trimble MR. Psychiatric profiles and patterns of cerebral blood flow in focal epilepsy: interactions between depression, obsessiveness, and perfusion related to the laterality of the epilepsy. *Journal of Neurology, Neurosurgery & Psychiatry* 1997;62:458–63. <https://doi.org/10.1136/jnnp.62.5.458>.
- [51] Gilliam FG, Maton BM, Martin RC, Sawrie SM, Faught RE, Hugg JW, et al. Hippocampal 1H-MRSI correlates with severity of depression symptoms in temporal lobe epilepsy. *Neurology* 2007;68:364–8. <https://doi.org/10.1212/01.wnl.0000252813.86812.81>.
- [52] Peng W-F, Ding J, Mao L-Y, Li X, Liang L, Chen C-Z, et al. Increased ratio of glutamate/glutamine to creatine in the right hippocampus contributes to depressive symptoms in patients with epilepsy. *Epilepsy & Behavior* 2013;29:144–9. <https://doi.org/10.1016/j.yebeh.2013.07.004>.
- [53] Bromfield EB, Altshuler L, Leiderman DB, Balish M, Ketter TA, Devinsky O, et al. Cerebral Metabolism and Depression in Patients With Complex Partial Seizures. *Archives of Neurology* 1992;49:617–23. <https://doi.org/10.1001/archneur.1992.00530300049010>.
- [54] Victoroff JI, Benson DF, Grafton ST, Engel J, Mazziotta JC. Depression in Complex Partial Seizures Electroencephalography and Cerebral Metabolic Correlates. *Archives of Neurology* 1994;51:155–63. <https://doi.org/10.1001/archneur.1994.00540140061016>.
- [55] Theodore WH, Hasler G, Giovacchini G, Kelley K, Reeves-Tyer P, Herscovitch P, et al. Reduced Hippocampal 5HT1A PET Receptor Binding and Depression in Temporal Lobe Epilepsy: 5HT1A PET AND DEPRESSION IN EPILEPSY. *Epilepsia* 2007;48:1526–30. <https://doi.org/10.1111/j.1528-1167.2007.01089.x>.
- [56] Hasler G, Bonwetsch R, Giovacchini G, Toczek MT, Bagic A, Luckenbaugh DA, et al. 5-HT1A Receptor Binding in Temporal Lobe Epilepsy Patients With and Without Major Depression. *Biological Psychiatry* 2007;62:1258–64. <https://doi.org/10.1016/j.biopsych.2007.02.015>.
- [57] Theodore WH, Wiggs EA, Martinez AR, Dustin IH, Khan OI, Appel S, et al. Serotonin 1A receptors, depression, and memory in temporal lobe epilepsy: 5HT1A Receptors, Depression, Memory, and TLE. *Epilepsia* 2012;53:129–33. <https://doi.org/10.1111/j.1528-1167.2011.03309.x>.
- [58] Lothe A, Didelot A, Hammers A, Costes N, Saoud M, Gilliam F, et al. Comorbidity between temporal lobe epilepsy and depression: a [18 F]MPPF PET study. *Brain* 2008;131:2765–82. <https://doi.org/10.1093/brain/awn194>.
- [59] Assem-Hilger E, Lanzenberger R, Savli M, Wadsak W, Mitterhauser M, Mien L-K, et al. Central serotonin 1A receptor binding in temporal lobe epilepsy: A [carbonyl-11C]WAY-100635 PET study. *Epilepsy & Behavior* 2010;19:467–73. <https://doi.org/10.1016/j.yebeh.2010.07.030>.

- [60] Martinez A, Finegersh A, Cannon DM, Dustin I, Nugent A, Herscovitch P, et al. The 5-HT<sub>1A</sub> receptor and 5-HT transporter in temporal lobe epilepsy. *Neurology* 2013;80:1465–71. <https://doi.org/10.1212/WNL.0b013e31828cf809>.
- [61] Liik M, Paris M, Vahter L, Gross-Paju K, Haldre S. 123I-ADAM SPET imaging of serotonin transporter in patients with epilepsy and comorbid depression. *BMC Neurol* 2013;13:204. <https://doi.org/10.1186/1471-2377-13-204>.
- [62] Dusi N, Barlati S, Vita A, Brambilla P. Brain Structural Effects of Antidepressant Treatment in Major Depression. *CN* 2015;13:458–65. <https://doi.org/10.2174/1570159X1304150831121909>.
- [63] Meador KJ, Loring DW. Developmental effects of antiepileptic drugs and the need for improved regulations. *Neurology* 2016;86:297–306. <https://doi.org/10.1212/WNL.0000000000002119>.
- [64] Theodore WH, Giovacchini G, Bonwetsch R, Bagic A, Reeves-Tyer P, Herscovitch P, et al. The Effect of Antiepileptic Drugs on 5-HT<sub>1A</sub>-Receptor Binding Measured by Positron Emission Tomography. *Epilepsia* 2006;47:499–503. <https://doi.org/10.1111/j.1528-1167.2006.00458.x>.
- [65] the Alzheimer's Disease Neuroimaging Initiative, EPiGEN Consortium, IMAGEN Consortium, Saguenay Youth Study (SYS) Group, Thompson PM, Stein JL, Medland SE, Hibar DP, Vasquez AA, et al. The ENIGMA Consortium: large-scale collaborative analyses of neuroimaging and genetic data. *Brain Imaging and Behavior* 2014;8:153–82. <https://doi.org/10.1007/s11682-013-9269-5>.
- [66] Arnone D, McIntosh AM, Ebmeier KP, Munafò MR, Anderson IM. Magnetic resonance imaging studies in unipolar depression: Systematic review and meta-regression analyses. *European Neuropsychopharmacology* 2012;22:1–16. <https://doi.org/10.1016/j.euroneuro.2011.05.003>.
- [67] Cole J, Costafreda SG, McGuffin P, Fu CHY. Hippocampal atrophy in first episode depression: A meta-analysis of magnetic resonance imaging studies. *Journal of Affective Disorders* 2011;134:483–7. <https://doi.org/10.1016/j.jad.2011.05.057>.
- [68] Arnone D, McKie S, Elliott R, Juhasz G, Thomas EJ, Downey D, et al. State-dependent changes in hippocampal grey matter in depression. *Mol Psychiatry* 2013;18:1265–72. <https://doi.org/10.1038/mp.2012.150>.
- [69] Oltedal L, Narr KL, Abbott C, Anand A, Argyelan M, Bartsch H, et al. Volume of the Human Hippocampus and Clinical Response Following Electroconvulsive Therapy. *Biological Psychiatry* 2018;84:574–81. <https://doi.org/10.1016/j.biopsych.2018.05.017>.
- [70] Elbejjani M, Fuhrer R, Abrahamowicz M, Mazoyer B, Crivello F, Tzourio C, et al. Depression, depressive symptoms, and rate of hippocampal atrophy in a longitudinal cohort of older men and women. *Psychol Med* 2015;45:1931–44. <https://doi.org/10.1017/S0033291714003055>.
- [71] Schmaal L, Pozzi E, C. Ho T, van Velzen LS, Veer IM, Opel N, et al. ENIGMA MDD: seven years of global neuroimaging studies of major depression through worldwide data sharing. *Transl Psychiatry* 2020;10:172. <https://doi.org/10.1038/s41398-020-0842-6>.
- [72] Blümcke I, Thom M, Aronica E, Armstrong DD, Bartolomei F, Bernasconi A, et al. International consensus classification of hippocampal sclerosis in temporal lobe epilepsy: A Task Force report from the ILAE Commission on Diagnostic Methods. *Epilepsia* 2013;54:1315–29. <https://doi.org/10.1111/epi.12220>.
- [73] for the ENIGMA-Major Depressive Disorder Working Group, Schmaal L, Hibar DP, Sämann PG, Hall GB, Baune BT, et al. Cortical abnormalities in adults and adolescents with major depression based on brain scans from 20 cohorts worldwide in the ENIGMA Major Depressive Disorder Working Group. *Mol Psychiatry* 2017;22:900–9. <https://doi.org/10.1038/mp.2016.60>.

- [74] Kaiser RH, Andrews-Hanna JR, Wager TD, Pizzagalli DA. Large-Scale Network Dysfunction in Major Depressive Disorder: A Meta-analysis of Resting-State Functional Connectivity. *JAMA Psychiatry* 2015;72:603. <https://doi.org/10.1001/jamapsychiatry.2015.0071>.
- [75] Liao W, Zhang Z, Pan Z, Mantini D, Ding J, Duan X, et al. Default mode network abnormalities in mesial temporal lobe epilepsy: A study combining fMRI and DTI. *Hum Brain Mapp* 2011;32:883–95. <https://doi.org/10.1002/hbm.21076>.
- [76] Schneck N, Tu T, Falcone HR, Miller JM, Zanderigo F, Sublette ME, et al. Large-scale network dynamics in neural response to emotionally negative stimuli linked to serotonin 1A binding in major depressive disorder. *Mol Psychiatry* 2020. <https://doi.org/10.1038/s41380-020-0733-5>.
- [77] Paparrigopoulos T, Ferentinos P, Brierley B, Shaw P, David AS. Relationship between post-operative depression/anxiety and hippocampal/amygdala volumes in temporal lobectomy for epilepsy. *Epilepsy Research* 2008;81:30–5. <https://doi.org/10.1016/j.eplepsyres.2008.04.011>.
- [78] Wrench JM, Wilson SJ, Bladin PF, Reutens DC. Hippocampal volume and depression: insights from epilepsy surgery. *Journal of Neurology, Neurosurgery & Psychiatry* 2009;80:539–44. <https://doi.org/10.1136/jnnp.2008.152165>.
- [79] Pope RA, Centeno M, Flügel D, Symms MR, Koepp M, Thompson PJ, et al. Neural correlates of de novo depression following left temporal lobe epilepsy surgery: A voxel based morphometry study of pre-surgical structural MRI. *Epilepsy Research* 2014;108:517–25. <https://doi.org/10.1016/j.eplepsyres.2013.12.003>.
- [80] Bonelli SB, Powell R, Yogarajah M, Thompson PJ, Symms MR, Koepp MJ, et al. Preoperative amygdala fMRI in temporal lobe epilepsy: Imaging Amygdala Function in TLE. *Epilepsia* 2009;50:217–27. <https://doi.org/10.1111/j.1528-1167.2008.01739.x>.
- [81] Salzberg M, Taher T, Davie M, Carne R, Hicks RJ, Cook M, et al. Depression in Temporal Lobe Epilepsy Surgery Patients: An FDG-PET Study: TLE SURGERY, DEPRESSION, AND FDG-PET. *Epilepsia* 2006;47:2125–30. <https://doi.org/10.1111/j.1528-1167.2006.00860.x>.



**Figure 1. PRISMA flow diagram neuroimaging studies of depression in epilepsy.**



**Table 1. Neuroimaging studies of depression in epilepsy. Qualitative synthesis of included studies.**

STRUCTURAL NEUROIMAGING								
Reference	No of patients	Country	Epilepsy type	Seizure frequency	Imaging Technique	Depression assessment	Antidepressants	Depression correlates
<b>Van Elst et al 1999 [35]</b>	70	UK	50 mTLE vs. 20 controls	No SF	Structural MRI - Amygdala Volumetry	Psychiatric assessment through DSM-IV BDI	None	Enlarged bilateral amygdala volumes L amygdala volumes correlated with BDI scores
<b>Quiske et al 2000 [23]</b>	60	Germany	mTLE with HS vs. ITLE	No SF	Structural MRI - T1W, T2W, Coronal FLAIR, Hippocampal Volumetry	BDI	Not known	HS independent on lateralization
<b>Nees et al 2001 [24]</b>	50	UK	mTLE (lesional and non-lesional)	22 SF; 21 persistent auras; 6 ongoing BTC seizures	Structural MRI - T1W, T2W, Coronal FLAIR, Hippocampal Volumetry, Hippocampal T2 maps	BDI	Not known	RHS
<b>Baxendale et al 2005 [25]</b>	87	UK	mTLE with HS	Not known	Structural MRI - T1W, T2W, Coronal FLAIR, Hippocampal Volumetry	HADS	Not known	LHS
<b>Devinsky et al 2005 [27]</b>	360	USA Multicenter (7 centers)	mTLE vs. extratemporal epilepsy (frontal, parietal,	Epilepsy surgery sample	Structural MRI - T1W, T2W, Coronal FLAIR,	BDI CIDI	Not known	No association with lateralization and localization

			occipital)		Hippocampal Volumetry			
<b>Briellmann et al 2007 [28]</b>	34	Australia	mTLE with HS	No SF	Structural MRI - Hippocampal and Amygdala Volumes; Tissue Signal - T2 Relaxometry	Psychiatric assessment DSM IV criteria	26.4%	Contralateral amygdala signal changes
<b>Adams et al 2008 [30]</b>	319	Australia	mTLE (HS, others and non lesional) vs. Extratemporal (lesional, non lesional)	Not known	Structural MRI - Laterality and type of lesion	Psychiatric assessment DSM IV criteria	Not known	No difference
<b>Richardson et al 2007 [34]</b>	18	USA	TLE	No SF 44% weekly 66% monthly	Structural MRI - Region of Interest analysis; FDG PET (co-registration of MRI and PET images)	BDI	Not known	Bilateral increased amygdala volumes but no changes in metabolism
<b>Paparrigopoulos et al 2008 [77]</b>	35	UK	mTLE Epilepsy surgery sample	Epilepsy surgery sample 57% SF	Structural MRI (post-op) - Hippocampal and Amygdala Volumetry	BDI	Not known	Post-operative depression correlated with the extent of hippocampal and amygdala resection. L>R
<b>Shamim et al 2009 [32]</b>	55	USA	mTLE	Not known	Structural MRI - Hippocampal Volumetry	Psychiatric assessment DSM IV criteria BDI	No patients	RTLE low left hippocampal volume Left TLE no difference
<b>Wrench et</b>	83	Australia	26 mTLE vs. 26	No SF	Structural	Psychiatric	17%	mTLE

<b>al 2009 [78]</b>			extratemporal focal vs. 41 controls Epilepsy surgery sample	extratemporal TLE >mTLE	MRI – Hippocampal Volumetry on pre-operative MRI	assessment DSM-IV BDI		Pre-operative depression: No association with hippocampal volume Post-operative depression: small hippocampal volumes contralateral to the resection. Extratemporal Post-operative depression: no association with hippocampal volume
<b>Van Elst et al 2009 [36]</b>	53	Germany	Refractory focal epilepsy (temporal, frontal, other focal, non-lesional)	No SF	Structural MRI - Region of Interest analysis	Psychiatric assessment ICD-10 criteria; BDI	Excluded	Bilateral amygdala volume loss R>L;
<b>Salgado et al 2010 [37]</b>	144	Brazil	48 mTLE vs. 96 controls	No SF	Structural MRI - Voxel Based Morphometry	SCID-I for the DSM IV	3 patients	Widespread grey matter volume loss including bilateral hippocampus, parahippocampal gyrus and uncus; left thalamus, cuneus, and fusiform gyrus; right caudate body; inferior and superior temporal gyrus bilaterally; inferior and middle frontal gyrus bilaterally
<b>Finegersh et al 2011 [39]</b>	40	USA	mTLE	Not known	MRI with radial atrophy mapping (3-D	BDI	None but past exposure	Atrophy superoanterior portion of the hippocampus

					surface modeling tool to measure hippocampal atrophy)		reported	contralateral to seizure focus
<b>Sanchez-Gistau et al 2012 [26]</b>	308	Spain	115 mTLE with HS vs. 106 mTLE lesional no HS vs. 87 mTLE non-lesional	No SF	Structural MRI	Psychiatric assessment DSM-IV HADS	12.9%	HS
<b>Butler et al 2012 [38]</b>	81	USA	36 mTLE vs. 45 controls	Not known	Structural MRI - Cortical Thickness (Whole-cortex MRI Morphometric assessment)	BDI	Not known	Orbitofrontal cortex thickening
<b>Pope et al 2014 [79]</b>	30	UK	mTLE with LHS Epilepsy surgery sample	43% SF	Structural MRI – VBM assessment of pre-surgical grey matter volume	Psychiatric assessment DSM-IV	-	Reduced pre-operative bilateral grey matter in orbitofrontal cortex, ipsilateral cingulate gyrus, and thalamus
<b>Hecimovic et al 2014 [33]</b>	28	USA	mTLE	No SF	Structural MRI - Region of Interest analysis	BDI	Not known	Total hippocampal volumes were smaller in the group with BDI < 15
<b>Kavanaugh et al 2017 [40]</b>	31	USA	mTLE non-lesional	No SF	Diffusion Tensor Imaging	MINI HAM-D	48%	Both frontolimbic and non-frontolimbic white matter especially if epilepsy started in childhood
<b>Goncalves</b>	40	Brazil	m TLE	No SF	Structural	Psychiatric	25.8%	No difference

<b>et al 2017 [29]</b>					MRI	assessment ICD-10 criteria; MINI BDI		
<b>Rayner et al 2019 [31]</b>	152	Australia	19 mTLE with HS vs. 30 mTLE lesional no HS vs. 30 mTLE non-lesional vs.73 Controls	NO SF	Structural MRI Interictal 18F FDG-PET (PET concordance)	Psychiatric assessment DSM-IV NDDI-E PHQ-9	Not known	No difference

<b>FUNCTIONAL NEUROIMAGING</b>								
<b>Reference</b>	<b>No of patients</b>	<b>Country</b>	<b>Epilepsy type</b>	<b>Seizure Frequency</b>	<b>Imaging Technique</b>	<b>Depression assessment</b>	<b>Antidepressants</b>	<b>Depression correlates</b>
<b>Bonelli et al 2009 [80]</b>	75	UK	54 mTLE with HS vs. 21 Controls Epilepsy surgery sample	No SF	Memory encoding functional MRI paradigm, including viewing fearful and neutral faces	HADS	Not known	Pre-operative depression: RTLE, bilateral amygdala activation and R amygdala correlated with post-operative depression (not seen in LTLE)
<b>Chen et al 2012 [43]</b>	40	China	23 mTLE vs. 17 Controls	No difference in seizure frequency between	Resting state functional MRI	Psychiatric assessment	Excluded patients receiving antidepressant	Increased activity in bilateral thalami, insula, caudate and right anterior cingulate;

				groups, all seizure free for at least 15-days prior to MRI			medications	Decreased connectivity prefrontal-limbic system and increased connectivity within the limbic system and angular gyrus
<b>Kemmotsu et al 2013 [45]</b>	39	USA	19 mTLE vs. 20 Controls	Not known, all seizure free for at least 24-hours prior to MRI	Volumetric and functional connectivity MRI (fcMRI)	BDI	Not	Increased connectivity frontolimbic networks; Right amygdala
<b>Doucet et al 2013 [41]</b>	41	USA	22 m TLE with HS vs. 19 controls	Not known	Functional MRI - Functional connectivity emerging from Amygdala	Personality Assessment Inventory (PAI) based on the DSM	17%	Opposite functional connectivity
<b>Kemmotsu et al 2014 [44]</b>	41	USA	21 mTLE vs. 20 controls	Seizures per month recorded	Functional MRI - Diffusion Tensor Imaging	BDI	2.4%	Both L and R TLE microstructural compromise to the uncinate fasciculus LTLE: ipsilateral hippocampus and anterior-prefrontal cortex;
<b>Stretton et al 2015 [47]</b>	78	UK	48 mTLE vs. 30 controls	Not known	Functional MRI (visuospatial 'n-back' paradigm to compare working memory between groups)	Psychiatric assessment DSM IV-TR; BDI-Fast Screen	6.4%	Lifetime depression: deactivation in subgenial anterior cingulate cortex (sACC); No significant differences in grey matter volume or structural connectivity

					Structural - Voxel Based Morphometry and Diffusion Tensor Imaging			
<b>Zhu et al 2018 [46]</b>	56	China	35 mTLE non-lesional vs. 21 Controls	Not known	Resting state functional MRI	Psychiatric assessment DSM IV HAM-D	None	Bilateral mesial prefrontal cortex, precuneus, angular gyrus, right parahippocampal gyrus and right temporal pole (prefrontal-limbic system)
<b>Peng et al 2018 [42]</b>	47	China	32 mTLE vs. 15 Controls	No SF	Resting state functional MRI	HAM-D	None	Bilateral cerebellum; R hippocampus
<b>Garcia et al 2019 [48]</b>	112	Brazil	74 Genetic Generalized Epilepsy (JME = 54 JAE = 11 GTCS only = 9) vs. 38 Controls	SF = 12	3T resting state functional MRI (volumetric T1W and resting state)	BDI	Not known	Default mode network; left executive control network, salience, and visuospatial attention

**PHARMACO AND METABOLIC NEUROIMAGING**

<b>Reference</b>	<b>No of patients</b>	<b>Country</b>	<b>Epilepsy type</b>	<b>Seizure Frequency</b>	<b>Imaging Technique</b>	<b>Depression assessment</b>	<b>Antidepressants</b>	<b>Depression Correlates</b>
<b>Bromfield</b>	49	USA	23 mTLE	No SF	FDG PET	Psychiatric	Not known	Bilateral



<b>et al 1992 [53]</b>			vs. 26 Controls		18-F-2-deoxyglucose positron emission tomography	assessment; BDI;		reduction in inferior frontal glucose metabolism
<b>Victoroff et al 1994 [54]</b>	53	USA	mTLE	Not known	18 FDG PET	Semi structured neuropsychiatric interview using structured clinical interview for DSM-III-R HAM-D	Not known	L temporal hypometabolism
<b>Ring et al 1999 [49]</b>	19	UK	mTLE	No SF No seizures for at least 24-hours before imaging	SPECT scan using 99mTc-HMPAO (blood flow marker)	Psychiatric assessment DSM III-R and IV criteria HAM-D	21%	Increased perfusion left frontal, temporal, parietal and subcortical structures
<b>Schmitz et al 1999 [50]</b>	31	UK	Focal epilepsy  Left = 13 Right = 18	Not known	99M Tc-HMPAO SPECT (cerebral blood flow)	BDI	None	Low contralateral temporal and bilateral frontal perfusion and higher occipital perfusion;
<b>Salzberg et al 2006 [81]</b>	23	Australia	mTLE Epilepsy surgery sample	-	FDG PET 18-F-2-deoxyglucose positron emission tomography	Psychiatric assessment – DSM IV	8.7%	Hypometabolism ipsilateral orbitofrontal cortex
<b>Hasler et al 2007 [56]</b>	37	USA	mTLE	Not known	[18F]-FCWAY PET looking at 5-HT1A receptor binding Structural MRI	Psychiatric assessment – DSM IV	Excluded	Reduction in 5-HT1A receptor binding in anterior cingulate, right

								hippocampus and medial and superior temporal gyrus
<b>Gilliam et al 2007 [51]</b>	31	USA	mTLE	No SF CPS, GTCS	1H-Magnetic Resonance Spectroscopic Imaging (1H-MRSI) - using Creatine/ N-Acetylaspartate (Cr/ NAA) maps	POEMS	Not known	Abnormal hippocampal metabolism and Cr/ NAA ratio
<b>Theodore et al 2007 [55]</b>	55	USA	45 mTLE vs. 10 Controls	Not known None had seizures for at least 2-days before PET scanning	[[18F]-FCWAY PET looking at 5-HT1A receptor binding  Structural MRI	BDI	Excluded	Inverse relation with ipsilateral hippocampal binding (according to severity of symptoms)
<b>Lothe et al 2008 [58]</b>	24	France	mTLE with HS Epilepsy surgery sample	71% underwent surgery – 94% Engel Class 1	[18F]-MPPF PET which is a 5-HT1A antagonist – Voxel based and Region of Interest analyses	Psychiatric assessment – DSM IV; BDI-II	Excluded	Cognitive symptoms and anhedonia -> raphe nuclei and insula contralateral to seizure onset; Somatic symptoms -> hippocampal/ parahippocampal region ipsilateral to seizure onset, left mid-cingulate gyrus, inferior

								dorsolateral frontal cortex bilaterally
<b>Assem-Hilger et al 2010 [59]</b>	26	Austria	13 mTLE vs. 13 Controls	Not known	PET using [carbonyl-11C]WAY-100635 (serotonin 1A 5-HT 1A receptor antagonist)	HAM-D BDI	None	No association
<b>Theodore et al 2012 [57]</b>	40	USA	mTLE	Not known None had seizures for at least 2-days before PET scanning	[[18F]-FCWAY PET looking at 5-HT1A receptor binding  Structural MRI	BDI	Not known	Inverse relation ipsilateral focus; No difference between R and L
<b>Martinez et al 2013 [60]</b>	29	USA	13 mTLE vs. 16 Controls	Not known	[[18F]-FCWAY PET looking at 5-HT1A receptor binding  [11C]-DASB PET looking for 5-HTT (transporter)  Structural MRI	Psychiatric assessment – DSM IV; BDI-II	1 patient had been taking fluoxetine until 2-months before study	Reduced 5-HTT in insula and fusiform gyrus
<b>Liik et al 2013 [61]</b>	12	Estonia	7 Focal; 5 Generalized	No SF	Single Photon Emission Tomography (SPET) using SERT radioligand 123I-ADAM (serotonin transporter)	BDI	None	No difference
<b>Peng et al 2013 [52]</b>	50	China	Mix of various	No difference in seizure	Single-voxel proton magnetic	HAM-D	Excluded	Increased Glx/ Cr right

			types	frequency between groups. No seizures for at least 7-days before imaging	resonance spectroscopy (1H- MRS)			hippocampus
--	--	--	-------	--	--	--	--	-------------

mTLE= mesial temporal lobe epilepsy; ITLE= lateral temporal lobe epilepsy; R= right; L=left; HS= hippocampal sclerosis; SF= seizure free; BTC=bilateral tonic clonic seizures; BDI=Beck Depression Inventory; HAM-D: Hamilton Depression Rating Scale; HADS: Hospital Anxiety Depression Scale; DSM= Diagnostic and statistical manual of mental disorders; NDDIE= Neurological Disorders Depression Inventory for Epilepsy; SCID-I= Structured Clinical Interview for DSM Axis I; CIDI=Composite International Diagnostic Interview; MINI= Mini International Neuropsychiatric Inventory