

Cardiovascular Topics

Endovascular aortic aneurysm repair by a multidisciplinary team: lessons learned and six-year clinical update

D.F. DU TOIT, J.A. SAAIMAN, J.P. CARPENTER, K.M. GELDENHUYS

Summary

Background: Endovascular aneurysm repair (EVAR) (using an Federal Drug Association-approved AneuRx® device) compared to conventional surgical repair of abdominal aortic aneurysm (AAA) previously rendered favourable outcomes regarding post-operative pain, avoidance of laparotomy, and rapid rehabilitation and hospital discharge in high-risk patients, including octagenarians.

Objectives: To assess the safety, reduction in aneurysm-related deaths, and interim survival data up to 72 months after AAA exclusion by endoluminal endografts (EVAR).

Design: We carried out an open, controlled, prospective, multidisciplinary EVAR study for the period 1998 to 2003 (six years). In the earlier part of the study, EVAR was compared with previously published results of conventional open aneurysmectomy surgery.

Setting: Heart Unit, Panorama Medi-Clinic, Parow, South Africa.

Participants: We recruited adult male and female patients

School of Basic and Applied Sciences, Faculty of Health Sciences, University of Stellenbosch

*D.F. DU TOIT, D.Phil. (OXON.), Ph.D., F.C.S. (S.A.), F.R.C.S.

Endovascular Unit, Netcare Private Hospital, Kuils River

J. A. SAAIMAN, M.Med.

Department of Surgery, Division of Vascular Surgery, University of Pennsylvania, Philadelphia, United States of America

J.P. CARPENTER, M.D.

Department of Anatomy and Histology, Faculty of Health Sciences, University of Stellenbosch

K.M. GELDENHUYS

*This author is not a recipient of a commercial research grant. Competition of interest: none

presenting with AAA and fulfilling the inclusion criteria for endovascular repair, as recommended by the consensus 2003 meeting of the Vascular Association of South Africa (VASSA). All patients were offered open surgery as an alternative and were entered into the VASSA EVAR trial registry. Pre-operatively, AAA anatomy was assessed by spiral-computed tomography (CT), and selectively with conventional angiography and intravascular ultrasound (IVUS). Informed consent was obtained in accordance with the recommendations of the Senate of Surgery Paper 2, Ethical Guidelines, Great Britain and Ireland. Patients underwent EVAR by a multidisciplinary interventional team.

Interventions: Two hundred and seven adult patients with AAA were assessed. Forty-four of the 207 (21.2%) were excluded from EVAR because of irreversible comorbid factors and complex aneurysm morphology. One hundred and sixty-three patients (78%), with a mean age of 70.7 years (range 60–91 years), underwent EVAR (1998–2003). Five patients were lost to follow-up (3%). Median AAA diameter was 56.9 mm and ASA ratings were I, 1.2%; II, 15.9%; III, 57%; IV, 22.6%; and V, 2.4%. EVAR was performed in high- and low-risk categories of both sexes. Most patients were in ASA groups III and IV.

Devices deployed: EVAR was performed using a selection of endografts over 72 months – AneuRx® (Medtronic) 47; Talent® (Medtronic) 49; Vanguard® three; Zenith® (Cook) one; Powerlink® (Endologix) 62; and other, one.

Results: Thirty-day outcome: successful deployment 99%, primary stent patency 97%, surgical conversion 0.6%, procedural or intra-operative mortality 1.2%, 30-day mortality 4.3%, endoleaks 1.84%, and secondary intraprocedural endovascular interventions 24.5%. Peri-operative mortality was 3.1% (one aneurysm related). One patient had suspected endograft infection. Late mortality was 21.4% (35 patients due to co-morbidities, and one was aneurysm related). Follow-up was a median of 28.3 months (range 1–69 months). In 163 patients, two persisting endoleaks (1.2%) were detected. Endotension was detected in 3/163 (1.8%) with average sac increase

of 0.8 cm. Conversion to open surgery was needed in one patient (0.6%). Co-morbidities that contributed to late mortality included multi-organ failure, ischaemic heart disease (IHD), cardiomyopathy, renal failure, stroke and cancer. One procedural rupture was fatal (0.6%). Two late ruptures occurred; one was successfully endostented and the other patient died after a failed surgical intervention (0.6%).

Endovascular repair of AAA is more expensive than conventional surgery. Introduction of the Endologix stent has reduced operative time from 120 to 60 minutes in uncomplicated patients. Newer-generation aortic stents allow better control of negative remodeling and stent migration.

Conclusion: A multidisciplinary team can safely perform EVAR, with a low 30-day mortality rate in selected patients graded ASA II–IV and with favourable aortic aneurysm morphology. About 22% of patients with AAA are not suited for EVAR. Persisting late endoleaks occurred in 1.2% of the cohort study and were not device specific. Life-long follow-up post EVAR is a prerequisite to detect late device failure, endoleaks and aneurysm-sac enlargement, and to assure the durability of these mid-term results. Short-term aneurysm rupture prevention is a predictable outcome in high-risk groups.

Cardiovasc J South Afr 2005; 16: 36–47.

www.cvjsa.co.za

The clinical consequence of an abdominal aortic aneurysm (AAA) includes unpredictable rupture into the peritoneal or retroperitoneal space with potentially massive, fatal haemorrhage.¹ The purpose of elective prosthetic engraftment for large aneurysms is primarily to prevent aneurysm rupture (aneurysm-related death) and exsanguination.^{1–3} A partial solution to this potentially deadly and preventable complication of AAA is to identify susceptible individuals and to exclude the aneurysm before unpredictable rupture occurs.^{1–3} This is a hotly debated subject² and recently, selection of patients for conventional surgery or endovascular aneurysm repair (EVAR) based on risk for rupture has been questioned.^{3,5} Long-term studies confirm that surgically treated patients with AAA, despite the advent of EVAR, experience a good quality of life and can enjoy a normal lifespan.^{6–10} Recent studies, however, suggest that EVAR could potentially replace open surgery in the treatment of AAA in about 75% of referred cases.^{11–15,16–29}

Despite risk-factor determination, conventional surgical repair of AAA is unquestionably associated with unexpected peri- and post-operative morbidity, such as myocardial infarction, multiple organ failure, respiratory and renal failure, stroke, and graft sepsis.^{5–9,11–13} Our own cardiological experience indicates that 60% of persons undergoing AAA repair, by whatever route, have established coronary artery disease.⁴ Mortality of elective surgery could well be closer to 8% in higher-risk groups.⁴ Although the surgical outcome after conventional repair of AAA is well documented, about 10% of patients develop significant elongation and dilatation at the graft/vessel interface.⁵ Eastcott, Sheil and co-workers commented that late failure at this point was an important cause of aneurysm-related death in long-term follow-up

studies after conventional surgery.^{14,15} Aneurysm-related death due to rupture is therefore also not completely abrogated by conventional open surgery.^{14–16}

With modern advances in endoluminal techniques, elective AAA repair can be accomplished effectively and safely with minimal invasive EVAR, provided patient selection and aneurysm anatomy is optimal, expertise and training appropriate, and the necessary infrastructure, back-up intensive-care facilities and anaesthesia support are available.^{17–33}

EVAR has evolved from an experimental technique to an evidence-based procedure in specialised centres.^{23–35} Open surgery still remains a viable option if aneurysm anatomy is unfavorable.^{6–10} The current series has been supported by extensive prior cadaveric laboratory studies performed at the Faculty of Health Sciences, University of Stellenbosch.^{16,31} In most studies, EVAR has been applied in patients with prohibitive risks, who were refused anaesthesia for traditional surgery or were identified as ‘unfit’ for surgery.²⁸

Recently, centres of excellence have documented clinical experience and learning curves since the pioneering work of Parodi, with reference to the application of minimally invasive EVAR.^{12,36–45} Encouraging short-, intermediate- and late-outcome results are predictable after EVAR.^{24–26,45} EVAR has been applied in low- and high-risk patients with AAA.^{18,19,28} There are no 10-year reported follow-up studies at present. General guidelines have been suggested for training and for the application of EVAR of AAA in clinical practice.^{32,46} In most countries, interventionalists are encouraged to document their patients with EVAR registries, thereby facilitating audit and peer review.^{12,46}

This study describes a multidisciplinary team’s interim 72-month experience using EVAR in the elective treatment of selected low- and high-risk patients with AAA at Panorama Medi-Clinic over a six-year period (1998–2003). Evaluation included outcome-based assessment regarding technical problems, complications, survival, endoleaks, late rupture, device failure, device-related death, aneurysm-related death, morbidity and mortality in 163 patients undergoing consecutive EVAR.

Materials and Methods

Referred patients with abdominal aneurysms were selected for EVAR according to a recognised protocol and guidelines.^{10,23,33} Assessment was performed by a multidisciplinary interventional team consisting of surgeons, vascular surgeons, radiologists and an interventional cardiologist. All patients were counseled, and signed informed consent.⁴⁷ The feasibility of the procedure, risks, treatment options (including conventional surgery), and the chance of conversion to an open procedure, or the need for secondary interventions were explained to recipients. Patients were entered into the VASSA EVAR registry.

Inclusion criteria for EVAR^{10,23,34,35,48–50}

Inclusion criteria were as follows: (i) asymptomatic and symptomatic abdominal aortic aneurysm more than 50 mm in diameter or enlargement of an aneurysm on ultrasound or computed tomography (CT) scan; (ii) patent iliac and femo-

ral arteries that permitted remote endovascular access; (iii) a non-aneurysmal proximal aortic neck diameter measuring between 18 and 26 mm on pre-operative spiral CT scan; (iv) a neck length of 12 mm aorta immediately inferior to the lowest renal ostium; this had to be adapted as the renal arteries often did not come off parallel;³¹ (v) patient prepared to be followed up at six-monthly intervals, indefinitely; (vi) adequate iliac landing zone (proximal to the internal iliac artery) with a diameter of 15 mm or more; (vii) concomitant AAA and potentially reconstructable peripheral vascular occlusive disease (PVD); and (viii) saccular aneurysms, anastomotic aneurysms and iliac aneurysms.

Exclusion criteria for EVAR

Exclusion criteria were: (i) frank rupture or inflammatory aneurysm; (ii) suprarenal extension of AAA: aortic neck length less than 12 mm with severe angulation; (iii) underlying connective tissue disorders (e.g. Marfan's syndrome); (iv) coagulation disorder (i.e. hypercoagulability); (v) renal insufficiency; (vi) underlying systemic infection: moribund patients; (vii) suspected mycotic aneurysm; (viii) patients with an estimated life expectancy of less than one year; (ix) bedridden patients and candidates with underlying cancer or previous stroke; (x) patients unwilling or unable to return for follow-up; (xi) extensive iliac calcification, splaying or tortuosity precluding limb access, or engraftment proximal to the internal iliac artery (one patent hypogastric was always retained); and (xii) PVD associated with gangrenous lesions (i.e. critical ischaemia), incapacitating, multilevel distal disease, or severe distal run-off problems.

Evolution of special investigations prior to EVAR

Pre-endostent work-up was as follows: (i) history, clinical examination and documentation of risk factors, including co-morbidities;^{4,48-52} (ii) detection of other features of PVD, i.e. peripheral aneurysms, occlusive disease and carotid bruits; (iii) aneurysm morphological classification based on spiral CT (types I, II, III); (iv) ankle brachial index (ABI); (v) biochemical baseline tests: full blood count (FBC) and erythrocyte sedimentation rate/C-reactive protein, clotting profile, electrolytes and urea, plasma glucose, creatinine, and liver function tests; (vi) chest X-ray, ECG; (vii) cardiological assessment and lung function tests in selected patients, to rule out IHD, arrhythmias, aortic stenosis and cardiomyopathy; and (viii) spiral CT (with contrast enhancement) including three-dimensional views superior and inferior to the AAA, together with characterisation of the iliacs.⁵¹ Features recorded included aneurysm neck diameter, length and angulation, flow channels, origins of the renal ostia, patency of the inferior mesenteric artery (IMA) and lumbar arteries, presence of large collaterals between the superior mesenteric artery (SMA) and IMA, wall calcification and size of thrombus, degree and extent of iliac tortuosity, calcification, occlusion or stenosis thereof. Three-millimetre sections were taken from the SMA to the superficial femoral artery, allowing definition of important proximal and distal delivery target areas. Transaxial scans and angiograms were considered the reference standard; (ix) peripheral angio-

grams were selectively performed if poor run-off, multilevel disease was anticipated; (x) risk classification (grades I-V) according to the American Society of Anaesthesiologists (ASA);⁴⁹ (xi) identification of symptomatic concomitant vascular lesions (stenotic or occlusive disease, i.e. coronary, carotid, renal, PVD requiring potential intra- or pre-operative concurrent interventional treatment; (xii) coronary angiography in selected patients; and (xiii) ventricular ejection fraction in selected patients.

Assessment prior to discharge

This involved: (i) clinical examination, including abdominal palpation, inspection of the femoral arteriotomy site and evaluation of the status of peripheral foot pulses; (ii) ABI in selected patients; (iii) other procedures deemed necessary if indicated (chest radiograph, abdominal X-ray, ECG, clotting profile, renal function); and (iv) ultrasound to detect endoleaks and graft position.

EVAR follow-up protocol³²

Patient follow-up was scheduled for one and three months, then six-monthly thereafter for a period up to six years or longer after EVAR.²⁴ Ongoing evaluation included: (i) physical examination and evaluation of the status of peripheral circulation in the feet; (ii) ABI in selected patients; (iii) biochemical tests: FBC, urea and creatinine; (iv) abdominal X-ray; and (v) selected spiral CT or colour duplex ultrasound to detect proximal and distal paraprosthetic leakage (endoleaks and perigraft flow), suprarenal aneurysmal dilatation, aneurysm enlargement (endotension), graft migration, stent fracture and device failure.

Statistical analysis

Non-parametric tests and computer data analysis (Statistica) were used to assess significance of difference. Results were considered significantly different when $p < 0.05$. All patient data were entered into the VASSA EVAR registry.

Technique of EVAR of AAA^{16,24,26}

EVAR of AAA was performed by a multidisciplinary team in a fully equipped cardiac catheterisation laboratory, using aseptic techniques, with operation theatre back-up in the event that conversion to an open procedure was needed. Arterial access for endoluminal stent-graft placement was provided by a vascular surgeon via common femoral artery exposure. Either a unilateral or bilateral femoral arteriotomy was used (bilateral for AneuRx®, Talent® devices).²¹ Access for EVAR using the Powerlink® (Endologix) bifurcated system was through one surgically exposed femoral (right-sided) artery and a contralateral percutaneously placed 9-F sheath.²⁶ Stent grafts were oversized by 10 to 20% relative to diameter measurements taken from CT scans. EVAR entailed proximal stent-graft placement in close proximity inferior to the lowest renal artery ostia and distal landing on both common iliac arteries within 10 and 20 mm of the origin of the internal iliac arteries.

Patients received epidural and light general anaesthesia (propofol) and were monitored by an anaesthetist. Intra-

procedural transfemoral haemodynamic monitoring of the aneurysm sac pressure via a 9-F sheath and pigtail catheter was used to predict and seal type I proximal and distal endoleaks. Selective aneurysmal sac contrast angiography was used intraprocedurally to facilitate either thrombin or coil embolisation of endoleaks. Immediately before insertion of the prosthesis and after heparinisation (5 000 units) and triple femoral vessel clamping, a 5- to 7-mm transverse arteriotomy was performed in the common femoral arteries immediately proximal to the origin of the profunda femoris arteries. After stent-graft deployment, completion angiography was performed to determine the exact position, alignment, conformability of the prosthesis, and evidence of intraprocedural endoleaks. Additional stents or extensions were inserted to control type I endoleaks in the theatre. Doppler flow studies were selectively used in theatre to assess distal circulation and perfusion. Prophylactic antibiotics included one gram of intravenous cefazolin.

Results

Two hundred and seven patients with AAA were assessed over a six-year period. Forty-four (21%) were excluded from EVAR due to unfavourable aneurysm morphology, severe distal PVD, access problems, calcification, co-morbidities, aneurysm neck angulation and severe ischaemic heart disease (aortic stenosis, cardiomyopathy). Younger patients under 60 years were referred for open conventional surgery. During a 72-month period (1998–2003), 163 of 207 patients

(78%) underwent EVAR by a multidisciplinary team at Panorama Medi-Clinic, and data were entered into the VASSA EVAR registry. Patient profile and co-morbidities after EVAR are reflected in Table I. With regard to costs, in uncomplicated cases, open conventional surgery for AAA is R20 000 cheaper than the endovascular option.

Patient demographics

There were 150 males and 13 females ($p < 0.005$). Mean age was 70.7 years (range 60 to 91 years). Between 22 and 34 stents were inserted annually in the six-year period (average 27 per annum). ASA classification was as follows: I, 1.2%; II, 15.9%; III, 57%; IV, 22.6%; and V, 2.4%. Median aneurysm diameter was 56.9 mm. Endograft devices inserted included: AneuRx® (Medtronic) 47; Talent® (Medtronic) 49; Vanguard® three; Zenith® (Cook) one; Powerlink® (Endologix) 62; and other, one.

Procedures and complications

The outcome of EVAR in 163 patients is tabulated in Table II and technical difficulties are reflected in Table III. The

TABLE I. CO-MORBIDITIES AND CHARACTERISTICS OF PATIENTS UNDERGOING EVAR (60 MONTHS).

Elective	159	96.9%
Ruptured (contained)	4*	2.4%
High-risk patients (ASA grades III–V)	135	82.3%
<i>ASA grade</i>		
I	2	1.2%
II	26	15.8%
III	95	57.9%
IV	37	22.5%
V	3	1.8%
<i>Risk factors</i>		
TIA/stroke	12	7.3%
CABG	24	14.6%
Ischaemic heart disease	108	65%
Hypertension	68	41.4%
Diabetes mellitus	16	9.7%
Peripheral occlusive disease	33	20%
COPD	22	13.4%
Renal impairment	11	6.7%
Pre-operative dialysis	0	0%
Atrium fibrillation	7	4.2%
Cardiomyopathy	21	12.8%
<i>Pre-operative sizing (mm)</i>		
AAA diameter (range/median)	3.2–9.5 cm	5.6 cm (median)
Aortic neck length	8–7 mm	18.8 mm (median)
Aortic neck diameter	14–50 mm	17.9 mm (median)

*Patient 64: rupture (pre-procedure); Patient 20: dissection (pre-procedure); Patient 41: rupture (during procedure); Patient 109: rupture (at 20 months post-procedure).

TABLE II. EVAR IN 163 PATIENTS – DEVICE ENHANCEMENT AND 30-DAY OUTCOME.

Variable	Total	%
Successful device deployment	162	99
Surgical conversion*	1	0.6
Procedural mortality	2	1.2
30-day mortality rate	7	4.2
Endoleaks	3	1.8
Secondary endovascular interventions (during engraftment)	40	24.5
Endograft sepsis	1	0.6

*Aneurysm rupture one week after EVAR.

TABLE III: TECHNICAL COMPLICATIONS/PROCEDURAL MORBIDITY (60 MONTHS) AFTER EVAR.

	Procedural up until 30 days	Procedural > 30 days
Micro-embolism ('trash' foot)	10	1
Renal-arterioembolism, renal infarction	0	0
Gut ischaemia	2	0
Groin haematoma (required local intervention)	6	0
Femoral artery pseudo-aneurysm	1	0
Seroma groin wound	1	1
Superficial groin infection (diabetes)	1	0
Superficial groin infection (non diabetic)	1	0
UTI	2	0
Brachial artery puncture site haematoma	2	0
Early graft infection	1	0
Iliac artery dissection	1	0
Graft thrombosis/occlusion	1	0
Embolectomy	6	0
Renal insufficiency	1	0
Remote complications (cardiac failure, infarction arrythmia, stroke)	2*	3**
Amputations	1 (pt no 16)	0

*Cardiac failure (1 patient); AV-node dissociation (1 patient)

**Cardiac failure (3 patients).

TABLE IV. AAA NECK MORPHOLOGY (SPIRAL CT).

Variable	Percentage
Neck angulation > 45°	n = 18 (10.9%)
Neck angulation = 45°	n = 15 (9.1%)
Short necks* < 12 mm	n = 18 (10.9%); range (2–12 mm)
Neck length** < 20 mm	n = 22 (13.4%); range (13–20 mm)

*Mean 8.6 mm (n = 11 > 10 mm: 60%)

**Mean 16.6 mm (n ≥ 15 mm: 95%)

TABLE V. DEVICE CONFIGURATION AND STENT DEPLOYMENT IN RELATION TO THE RENAL ARTERY OSTIA.

Device configuration	n = 163
Bifurcation	→ Modular (AneuRx® and Talent®): 101 62.1%
	→ One piece (Endologix): 62 37.8%
Infrarenal stent graft	163 100%

TABLE VI. MORTALITY STATISTICS AFTER EVAR IN THE CURRENT STUDY.*

Variable	Patients (%)
Total mortality	42 (25.7)
Intra-operative mortality	2 (1.2)
Aneurysm related	1 (0.6)
Peri-operative mortality	5 (3.0)
Aneurysm related	1 (0.6)
Late mortality	35 (21.4)
Aneurysm related	1 (0.6)

*Follow-up (median 28.3 months; range 1–69 months). Five patients were lost to follow-up (3.1%).

TABLE VII. STATISTICS OF ENDOLEAKS AND MAJOR CONVERSIONS IN 163 PATIENTS UNDERGOING EVAR.

Endoleak profile	Number (%)
Total number of aortic stents (EVAR)	163
Procedural endoleaks	39 (23.9)
Endoleaks detected at 30 days	2 (1.2)
Endoleaks detected after 30 days	6 (3.6)
Persisting endoleaks	2 (1.2)
Conversion to open surgery	1 (0.6)

TABLE VIII. TOTAL ENDOLEAK RATES AND LOCATIONS AFTER EVAR (PROCEDURAL + LATE: BEFORE EXCLUSION).

	AneuRx®	Talent®	Endologix®	Vanguard®
Total patients done	47	49	62	3
No endoleak	30	35	47	1
Type I	15	13	11	2
Type II	1	1	3	0
Type III	0	0	0	0
Type IV	0	0	0	0
Indeterminate	1*	0	1**	0
Total endoleaks	17	14	15	2

*Dissecting AAA, threatening rupture, excluded (patient 25)

**Rupture, patient died (patient 109).

intraprocedural deployment success rate was 99%. One hundred and thirty-five patients (82%) were classified as high risk based on the ASA classification. Only 28 (17.1 %) of the low-risk EVAR patients were classified as ASA I or II. Thirty-day outcomes in 163 patients are reflected in Table II. Procedural morbidity (local, technical and remote) after device enhancement over 60 months is reflected in Table III. Proximal aneurysm neck morphology, assessed according to spiral CT, is reflected in Table IV. Device configuration and deployment in relation to the renal arteries is given in Table V. Anatomico-pathological variations and examples of aortic morphology affecting the region of the aneurysm neck ('hostile neck') are reflected in Fig. 1. Mortality and endoleak statistics are reflected in Tables VI to X.

Remote and thrombo-embolic morbidity

Peri-operative systemic complications (day 30) were recorded in 28 patients after EVAR. Complications that were detected in 28/163 (17.1%) in this study period correlated strongly with the severity of ASA class and combinations of co-morbidities (Tables I to III). Wound/access-site complications occurred in 11/163 (6.7%) but all underwent resolution. Other important complications included urinary tract infection (1), anaemia (1), cholecystitis (1), cardiac arrest (1), aneurysm rupture (1), and pyrexia (1) (see Table III). Both patients with the cardiac arrest and aneurysm rupture survived. In the latter condition, successful surgical conversion was affected. Thromboembolic complications,

TABLE IX. ENDOLEAK RATES AND LOCATIONS AFTER EVAR (AFTER EXCLUSION = PERSISTING).

	AneuRx®	Talent®	Endologix®	Vanguard®
Total patients done	47	49	62	3
No persisting endoleak	46	49	61	3
Type I	1*	0	1**	0
Type II	0	0	0	0
Type III	0	0	0	0
Type IV	0	0	0	0
Indeterminate	0	0	0	0
Total endoleak	1	0	1	0

*Patient 37: excluded at 3 months, continues at 16 months

**Patient 160: Not yet seen in follow-up.

TABLE X. PERI-OPERATIVE MORTALITY/PATIENT DEMOGRAPHICS AND CO-MORBIDITIES.

Sex	Age at stenting (years) (Mean: 71.6)	Co-morbidity	ASA class	Cause of death	AAA procedure related
Male	58	IHD	IV	Cardiac/renal failure	Yes
Male	75	COPD, HT	IV	Multi-organ failure	Yes
Female	75	ICMP, HT, COAD, AF	IV	Multi-organ failure	Yes
Male	73	Liver/renal failure	V	Multi-organ failure	Yes
Female	77	HT, IHD, ruptured AAA	V	Renal failure	Yes

corrective interventions and outcomes after EVAR are reflected in Table XI. Acute peripheral thrombosis/embolism occurred in 10 patients in the 30-day period after EVAR (6%). Primary stent patency rate at 30 days was 97% (158 stents). Complications included superficial femoral artery (SFA) occlusion, trashing, iliac occlusion, and stent thrombosis (1). In 10 patients, resolution was affected by secondary transcatheter interventions, embolectomy, thrombolysis, percutaneous transluminal angioplasty (PTA) and use of IIb-IIIa platelet inhibitors. In 9/10 patients (90%) effective limb salvage by the endovascular route was achieved. One (1/163, 0.6%) patient had a failed primary vascular salvage operation due to a progressive thrombotic state ('white clot') and underwent proximal amputation (with underlying PVD and retinitis pigmentosa). Suspected pathology was a presensitised heparin thrombotic tendency and platelet abnormality. Heparin-induced thrombocytopenia (HATT) type II and thrombosis could not be excluded due to heparin sensitisation following previous open-heart surgery and other diagnostic vascular interventions. There

were insufficient circulating platelets to do accurate aggregation laboratory tests. The patient was alive at 60 months post EVAR, but was re-admitted twice during this time for cardiac failure (IHD).

Secondary procedures and late mortality

Secondary interventions after engraftment (for various indications) were necessary in 21/163 patients (12.8%). Endovascular or selective surgical repair was indicated for femoral and iliac occlusion, pseudo-aneurysm, aneurysm rupture (one at one week), external iliac rupture, trashing, groin haematoma, seroma and distal thrombo-embolism

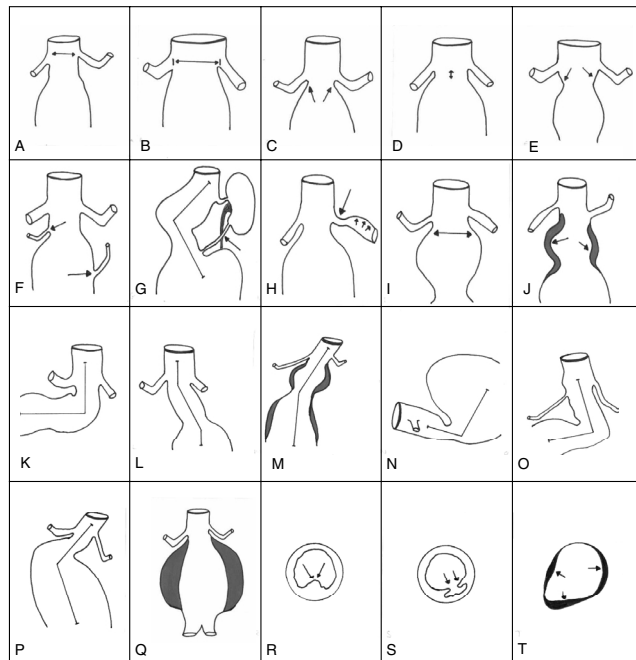


Fig. 1. Illustrations showing important anatomical or pathological variations involving the neck region of the aneurysm in this series. Most configurations contribute to a 'hostile' aneurysm neck. These configurations can impact negatively on stent placement and selection during EVAR. (A): Renal ostia originating at different levels. (B): Aneurysmal dilatation at the neck with suprarenal extension. (C): Short conical neck. (D): Short neck. (E): Reversed conical neck. (F): Aberrant renal arteries. (G): Angulated neck and aberrant renal arteries. (H): Concomitant renal artery stenosis. (I): Juxtarenal aneurysm formation. (J): Juxtarenal thrombus formation. (K, L, M, N, O, P): Degrees of angulation. (Q): Large aneurysm with intramural thrombus. (R, S, T): Cross-section of three aneurysm necks showing posterior plaque, ulceration and thrombus, all of which affect secure fixation of the proximal part of the device and may contribute to the development of type I or device-related proximal endoleaks.

TABLE XI. THIRTY-DAY THROMBO-EMBOLIC COMPLICATIONS AFTER EVAR*/SECONDARY INTERVENTIONS.

Patient	Incident	Intervention	Outcome
1	Left SFA occlusion	Thrombo-embolectomy	Resolved
2	Profunda artery occlusion Left leg	Surgical thrombo-embolectomy and profundaplasty/re-opro*	Proximal amputation
3	Vascular thrombosis	Transcatheter re-opro thrombolysis*	Resolved
4	Femoral occlusion	Reconstruction and transcatheter embolectomy	Resolved
5	Left Iliac occlusion	Thrombolysis and stent	Resolved
6	Total occlusion left leg Compartment syndrome left arm (from A-line)	Transcatheter embolectomy Fasciotomy	Resolved Resolved
7	Threatened left foot (?trash embolisation)	Transcatheter endarterectomy and embolectomy left foot	Resolved
8	Stent thrombosis	Fibrinolysis	Resolved
9	Arterial insufficiency and trashing to left foot	PTA to left iliac	Resolved
10	Occlusion of lower limb cural arteries	Arterial thrombectomy and integrilin**	Resolved

*One late right iliac occlusion occurred but was reversed by insertion of a stent.
**11b-111a platelet inhibitors.

TABLE XII. LATE MORTALITY: CO-MORBIDITIES AND MORTALITY PROFILE AFTER EVAR (N = 35).

Co-morbidity status before stenting	Cause of death after EVAR
Cardiac (IHD): 24 (68%)	Stroke: 3
Cardiomyopathy: 5	Cancer: 9 (mean 14.3 months)
Respiratory failure: 9	Multi-organ failure: 3**
Diabetes mellitus: 4	Myocardial infarction: 7** (20%)
Stroke: 3	Pneumonia: 2
EF < 43%: 9	Cardiac failure: 2**
Arrhythmia: 4	Septicaemia: 2
Cancer: 2	Renal failure: 2
Hypertension: 16 (45%)	Cardiomyopathy: 3**
PVD (occlusive): 10	Ruptured AAA: 1* (0.6%)
Renal failure: 2	Bee-sting anaphylaxis: 1
Liver cirrhosis: 1	Endograft sepsis: 1 (0.6%)
Obesity: 1	Unknown: 1
Hostile abdomen: 1	
AAA rupture: 1*	
Combinations: 28 (80%)	
Age > 90 years: 1	

*One aneurysm-related death
** Cardiac-related deaths (13/35: 35%).

(Table III). Late mortality statistics are reflected in Tables VI, XI and XII. The causes of natural, non-aneurysm related deaths, such as myocardial infarction, cardiomyopathy, cancer and renal failure are displayed in Table XII.

Endoleaks

Thirty-nine (23.9%) intraprocedural endoleaks (considered part of stent deployment and procedure) were detected by completion angiography: type I proximal (17); type I, proximal and distal (5); type I, distal (15), and type II, distal (2). Ninety-five per cent were successfully occluded by the use of proximal or distal devices, thrombin injection into the sac, or coil embolisation (see Table VII). One persisted for 12 months and there was one death due to aneurysm rupture. The latter patient died after surgical conversion and repair. Follow-up after 30 days revealed five late and two persisting endoleaks. The period of endoleak detection occurred between one and 52 months. Five were detected between three and 22 months. Persisting late endoleaks occurred in two patients (1.2%) and the cause remains indefinable. Procedural, 30-day and persisting endoleak incidence in the AneuRx[®] and Powerlink[®] groups did not reach statistical significance ($p > 0.05$). In the AneuRx[®] group, endoleaks were sealed in patients at three months (2), six months (1) and 50 months (1). In the Powerlink[®] group, one endoleak was sealed at four months (1), another one persisted at 30 days.

Endoleak statistics after EVAR are reflected in Tables VII and VIII. The incidence of type II endoleaks due to perigraft flow is reflected in Tables VIII and IX. Procedural and post-exclusion endoleak rates per stent are reflected in Tables VIII and IX. Procedural, 30-day and persisting incidence in the Aneurx[®] and Powerlink[®] groups did not reach statistical difference ($p > 0.05$). Endotension (post-EVAR aneurysm enlargement) was detected in three patients (1.8%) in the study period. Endoleaks were undetectable despite investigations in these patients. Aneurysm size increase was 0.1, 0.7 and 31 mm, respectively. Late mortality figures appear in Table XII. Compared with our earlier experience, the introduction of the Powerlink[®] stent has reduced the incidence of late endoleaks, as aneurysm sac remodeling is better controlled.

Aneurysm sac changes after EVAR

Follow-up showed features of post-EVAR sac reduction, stabilisation and expansion. Average sac reduction was 0.96 cm. In 2/163 (1.2%) there was an increase in sac size due to definable endoleaks. The increase in sac diameter at 13 and 45 months was 0.5 cm and 1.2 cm, respectively. The average increase in sac diameter in these two patients was 0.85 cm. Endotension without definitive endoleak identification occurred in 3/163 patients (1.8%). Increases were 0.1, 0.7 and 3.1 cm, respectively over a mean period of 16.3 months (range 1–37 months). In these patients the average increase was 1.3 cm. One of 163 (1.8%) in the endotension group remained stable after careful, conservative follow-up. The other patients were scheduled for secondary interventions.

Discussion

Application and indications for EVAR as definitive treatment of asymptomatic AAA in low- and high-risk cohorts has been documented by expert vascular interventional consensus.^{9,10,12,13,24,26,29,37,45,53}

Thirty-day outcome statistics after EVAR in the current study showed a low surgical conversion rate and procedural mortality (0.6% and 1.2%, respectively). Deployment success in our series was achieved in 99% of patients undergoing EVAR, and confirmed the results of Criado evaluating the application of Talent grafts.^{27,29} Considering the ASA rating, these results compared favourably with other studies.^{26,29} Analysis of the 30-day data confirmed that endoleaks, and the secondary interventions needed to treat these, are the Achilles heel of EVAR.^{10,24,27,37,44,52-56} Our incidence of late persisting endoleaks was less than 5% and compared favourably with the literature. Other studies showed similar results.^{12,24,26,27,38,40,55} However, although secondary interventions can resolve these issues effectively, this impacts on costs and possibly on reimbursement.⁵⁶

Our persisting endoleak rate at 30 days compared favourably with other studies.^{26,27,38,55} Persisting endoleaks (1.2%) remain a challenging issue regarding diagnosis and treatment. Regarding intraprocedural endoleak detection and prediction, we found intrasac, haemodynamic, monitoring and contrast angiography useful for detecting and occluding type I and II endoleaks. Contrast angiography of the sac and pressure measurements were obtained via a transfemoral 9-F pigtail catheter. This information proved useful in this study in determining if thrombin, coils or cuffs were indicated to ensure intra-operative occlusion of endoleaks. Additional 80- to 100-mm proximal cuffs were used more liberally in patients with an aortic neck less than 12 mm and angulation 40 to 55%. The Powerlink[®] (Endologix) stent showed promising features of columnar strength.²⁶ The additional cuffs used in this situation (with a short, angulated neck) provided further strength and assisted in straightening the angle. Sac contrast angiograms assisted with important decision making in theatre regarding use of additional cuffs, coils, and thrombin in the treatment of perigraft flow.^{57,58} Also, run-off speed of contrast assisted in identifying lumbar perigraft flow, thereby determining the safety and selection of the use of coils or thrombin to obtain effective intra-operative endoleak occlusion.

Our secondary intervention rate of 12.8% compared favourably with international results.^{39,54-56} One patient needed conversion to open surgery after one week (0.6%). Thirty-seven of 163 (22.6%) patients contributed to the late mortality. Many succumbed due to irreversible cardiac disease and cancer. Others have reported similar findings and have emphasised the impact of co-morbidities on eventual outcome and mortality in high-risk patients undergoing AAA repair.^{24,28}

In our study, 132 of 163 patients (80.1%) were classified as ASA III or IV. Two patients died of aneurysm rupture after EVAR and confirmed the importance of life-long surveillance to detect aneurysm enlargement. Other studies confirmed our findings.^{37,38,55-57} Zarins, in a large series, confirmed that the risk of aneurysm-related death is significantly lower following EVAR compared with the risk

of open surgery.²⁴ In the AneuRx[®] stent-graft trial, 0.8% of patients experienced aneurysm rupture after EVAR.^{24,59} However, EVAR using the AneuRx[®] device markedly reduced the risk of aneurysm rupture while eliminating the need for open aneurysm surgery in 98% of patients at one year, and 93% of patients at three years post EVAR.²⁴ The device was effective in preventing aneurysm rupture in 99.5% of patients over a three-year period.²⁴ They showed an overall patient survival rate of 93% at one year and 86% at three years.²⁴ EVAR compared to open surgery renders comparable results.²⁴ In Hallett's population-based study, average five-year survival after open repair of large (> 5 cm) aneurysms was only 60%, with most patients dying of myocardial infarction and other natural causes.⁷ High- and low-risk patients can therefore undergo EVAR with a lower rate of short-term systemic complications and a shorter length of hospital stay compared with open AAA repair.²⁸ However, early functional outcomes are markedly different with EVAR compared with open surgery, whereas there is no difference in late functional outcomes between the two procedures.⁸ Despite the concern regarding the durability of EVAR, high-risk patients should be evaluated according to the Alabama Group for EVAR repair before committing them to open AAA repair.²⁸

Three patients in the current study were diagnosed with endotension.⁵⁴⁻⁶⁰ Other workers have also described endovascular tension or pressure, in which AAA diameter does not decrease in size after EVAR.^{41,42,55,56} The treatment strategy remains controversial at present.^{54,58} These workers have provided evidence for intrasac pressure measurements intra-operatively in decision making regarding endoleaks.⁵⁵ We did not adopt this policy during follow-up because the space between the aneurysm wall and the stent graft was inadequate to be safely cannulated. Zarins, from Stanford University reported that aneurysm enlargement occurs in 10% of patients undergoing EVAR and results in the need for conversion to open repair in 1.6% at three years.^{24,25} Predictors of endotension include age, aneurysm size, endoleak, obesity and cancer.²⁵ Our patients are still under observation and three are scheduled for secondary interventions.

We were unable to comment on post-stent aortic neck dilatation, as routine use of follow-up spiral CT was not part of our follow-up protocol, due to its high cost. May *et al.* has indicated that EVAR protects against proximal neck enlargement.⁴⁵ Selective use of spiral CT was only considered in patients showing a sudden increase in aneurysm size on duplex-doppler assessment. Linear regression was not observed in our Powerlink[®] (Endologix) stent recipients. Freedom from rupture was 98% at 30 days in the current series and compared favourably with other studies.^{24,25} Regarding intraprocedural endoleaks, we accept that type I endoleaks represent a technical failure of EVAR and should be corrected promptly by endovascular means.⁵⁵ This is our policy when performing EVAR. We experienced a high degree of exclusion using extensions/cuffs in our study.⁵⁵ On the other hand, type II endoleaks are generally cited to be benign enough to possibly warrant a short period of observation.^{24,38,40,55,56} We were unable to substantiate these findings from our study.

The question of whether successful EVAR treatment should be based on a reduction of AAA size over time remains unanswered and controversial.⁵⁷ A reduction or stabilisation in sac size over time after EVAR is reassuring.⁵⁷ Reduction in sac size usually means the pressure inside the sac is reduced.⁵⁵ Endotension, with significant increase in sac size after EVAR, mandates further investigation to detect a missed type I endoleak that could cause rupture.⁵⁴ Of importance is that some authors have reported sac expansion and rupture even in the absence of endoleaks.⁵⁸ Sac regression after EVAR varies from study to study. Zarins demonstrated that only 14 to 25% of Aneurx[®] patients had sac regression of more than 5 mm during a one- to three-year follow-up.⁵⁹ Other groups report variable sac shrinkages in mid-term follow-up varying from 27 to 60%.⁵⁹ Malina *et al.* proposed that most sac regression occurred in the first year after EVAR, with minimal changes thereafter.⁶⁰ Others confirm that sac shrinkage is quite variable and depends on the graft type.⁵⁷ Three of 163 (1.8%) developed endotension in this study and two are scheduled for secondary interventions.⁵⁴ For FDA-approved trials, the definition of significant reduction in sac size was set at a minimum of 5 mm. Further studies are needed to elucidate all responsible factors that contribute to sac shrinkage, stabilisation, growth and endotension.³⁸ Long-term post-EVAR surveillance is needed to ensure permanent aneurysm exclusion.^{38,54-56}

This clinical study did not answer the following question: 'Have AAA endografts passed the clinical test?' Currently, the answer is 'no'.³⁹ Veith and co-workers, of Montifiore Hospital have recommended careful selective use of EVAR until more definite devices have proven long-term durability. Also, the question 'Is EVAR of value in the good-risk patient compared to open conventional surgery?' remains unanswered and speculative. At the moment the jury is still out. The justification of EVAR in the young person with AAA remains controversial, and more trials are needed until we have proven long-term results of endograft performance. Our policy is to refer young persons with AAA for open, conventional surgery. Our multidisciplinary group does not concur with the suggestion of Collin and Murie that EVAR is a failed experiment.⁶¹ These authors argue that the observed rupture risks of 1% per year after endovascular repair is not remarkably different from the natural history of most small aneurysms followed up without intervention.⁶¹ Results from large trials and data from the EUROSTAR registry indicate that EVAR can provide substantial clinical benefit for the patient with AAA and that aneurysm-related deaths can be controlled, provided the patient is carefully selected for EVAR.¹² We concur with these findings and recommendations.

Secondary intervention rate in this study was 12.8%, compared to the 18% reported by the EUROSTAR registry.¹² EUROSTAR predicts that the cumulative rate of freedom from secondary interventions at two years post EVAR is 62%.^{12,56} Transabdominal, extra-anatomical, and transfemoral secondary procedures may be indicated in 10 to 76% of patients after aortic stenting.⁵⁶ Therefore surveillance is important to predict the necessity for maintenance interventions.⁵⁶ Our patients are undergoing long-term follow-up. The EUROSTAR registry indicates that researchers do not

fully appreciate the importance of long-term integrity of stent devices, effect of exclusion on AAA remodeling or devices, implications of late endoleaks, and dangers of endotension.

Recommendations from the literature indicate that EVAR is indicated in high-risk patients, those with hostile abdomens, patients with anastomotic and isolated iliac aneurysms, and selected patients with ruptured AAA.^{52,62-66} Regarding ruptured AAA, Hinchliffe *et al.* have suggested that patients with leaking aneurysms were more likely to have larger aneurysms with shorter and narrower proximal necks.⁶⁷ In their study, they found that ruptured AAAs were less likely to be suitable for endovascular repair than their intact asymptomatic counterparts.⁶⁷ They speculate that open repair is likely to remain the treatment of choice in the majority of patients with ruptured AAA, owing to the current morphological constraints of endovascular repair.⁶⁷ Our study did not address these dilemmas and therefore, with regard to ruptured AAA, we adopt highly selective inclusion criteria at present. Other workers have recently indicated that EVAR is a feasible treatment in the majority of patients with ruptured and symptomatic AAA.^{42,65,66} The association of endoleaks and late AAA rupture after EVAR is currently being evaluated.^{59,66-69}

EVAR in women has been reported to present technical challenges and may cause more frequent late complications.⁷⁰ As only 8% (13) of our EVAR study included female patients, our experience is too little to substantiate these findings.⁷⁰ The calibre of the common iliac arteries in our study was critical to allow aneurysm exclusion with the Endologix device. Patients with small vessels and run-off were excluded from EVAR and referred for conventional open surgery.

Acute lower limb ischaemia after conventional aortic grafting for AAA may be due to embolism, 'trashing', thrombosis or technical errors.^{71,72} Prosthetic limb thrombosis is also an important cause of acute ischaemia. Embolism is the most common cause of ischaemic complications and occurs in about 10 to 15% of cases.^{72,73} Lord *et al.* reported an embolism incidence of 29% after 133 open aneurysmectomies over a four-year period.⁷³ In a series of 262 AAA repairs by the open route, Strom *et al.* reported an incidence of acute limb ischaemia in 10.3% of patients post reconstruction.⁷¹ The incidence of post-stent thromboembolism in our EVAR study was 6.1% (10 patients). Primary stent patency rate at 30 days was 97%. In nine of 10 patients, limb salvage was successfully achieved by secondary emergency endovascular interventions, including embolectomy, endarterectomy, thrombolysis, additional stents and the use of IIb-IIIa platelet inhibitors. Incidence of proximal amputation in our series was 0.6% (one patient). This occurred in a high-risk patient with underlying symptomatic PVD (occluded SFA) and ischaemic heart disease, and retinitis pigmentosa (RP) after insertion of a Talent® stent. Coagulopathy and hyperviscosity syndrome predisposes to early graft or distal vessel thrombosis.⁷⁴⁻⁷⁶ Underlying causes of vessel occlusion include thrombocytopenia, antithrombin deficiency, abnormal RBC fragility, or heparin-induced platelet aggregation.⁷⁴⁻⁷⁶ Some of those underlying factors are present in patients with RP and may

explain the reason for failed vascular limb-salvage intervention in our series for acute limb ischaemia.⁷⁴⁻⁷⁶ Additional factors in RP that may predispose to arterial thrombosis include thrombocytopenia, abnormal platelet taurine metabolism, disturbed erythrocyte osmotic fragility and hyperlipidaemia.⁷⁴⁻⁷⁷ These patients with the underlying metabolic syndrome and hyperviscosity are at increased risk for unpredictable arterial thrombosis after aneurysm repair in the early and late post-operative period. Lower-extremity amputation secondary to heparin-associated thrombocytopenia (HATT) due to thrombosis, and limb ischaemia may occur in any patient exposed or previously presensitised to heparin.⁷⁷⁻⁷⁹ Re-exposure to heparin in patients displaying type II HATT results in a rapid decline in platelets within minutes to hours.

Overcoming the problem of an unfavourable or suboptimal proximal aneurysm neck morphology as depicted in Fig. 1 is challenging – most units refer the patient for conventional surgery in such cases. Recent studies show that suprarenal endograft fixation is desirable for a more secure form of proximal fixation and to increase the number of patients eligible for EVAR.^{80,81} Our study did not address this application. However, we are of the opinion that the application of the Powerlink® stent allows better intraoperative control of patients with angulated aneurysm necks. Our impression is that the introduction of the newer-generation stents has impacted more favourably on our initial experience. Operation times seldom exceed one hour, a lower incidence of endoleaks are detectable, stent migration is reduced, and negative aneurysm sac remodeling after EVAR is reduced.

In many high-risk patients, EVAR is considered an end-of-life intervention. Some elderly patients with AAA and severe co-morbidities are not fit for EVAR or open conventional surgery. Our multidisciplinary group agrees with the sentiments of Jones *et al.* from the Center for Medical Ethics and Health Policy, Baylor College of Medicine, 'that once a futility state is realized, it is unethical to apply surgical skills uselessly'.⁸² Our group would not consider a 79-year-old female with advanced Alzheimer's disease, a symptomatic 10-cm AAA and increasing back pain, as suitable for EVAR. Our approach would follow the same recommendations as Jones *et al.*: meet with the immediate family or friends to discuss the patient's values, beliefs and preferences, and outcomes, and select a clinical intervention accordingly.⁸² This may entail withholding futile and heroic surgery and allow to the patient to die a natural death.⁸²

Conclusions

Regarding the primary goals of AAA exclusion, this study supports the hypothesis that it is possible to prevent rupture and aneurysm-related death by EVAR in more than 90% of patients in the intermediate to mid-term.^{9,12,13,18,24,26,44} Due to severe co-morbidities and distorted anatomy affecting safe stent fixation and access, EVAR was not feasible in 21% of referrals. Successful device deployment was possible in more than 90% of selected aneurysm recipients, rendering a 30-day procedural mortality rate of 1.2% and late persisting endoleak incidence of 1.2%. Twenty-four per cent of

patients after EVAR needed secondary endovascular interventions. The EUROSTAR registry demonstrated evidence and outcome for the application of EVAR in patients with AAA.¹² Life-long post-EVAR surveillance is needed to detect late persisting endoleaks and prevent aneurysm rupture.⁸³⁻⁸⁵ EVAR is still undergoing a process of technological evolution with improving mid- to long-term results.²⁴ A high attrition rate in high-risk aged patients with AAA can be expected after EVAR due to natural deaths from cardiac causes and cancer.⁴ This also applies to patients undergoing AAA repair by the conventional open surgical route.⁷⁻¹⁰

We thank Yolanda Swart and Hanlie Mulder for technical assistance, and Elize Arends and Marie de Beer for the word processing. The catheterisation laboratory personnel and intensive care staff are thanked for patient care at the Heart Unit, Panorama Medi-Clinic, Parow, Western Cape. Dr Robert Allen, vascular interventionalist from Stanford University, U.S.A is acknowledged for early peer review.

Appendix 1.

Institutions and investigators participating in this ongoing EVAR study included the following:

D.F. du Toit, Faculty of Health Sciences, University of Stellenbosch; C.F. Pretorius, Vergelegen Medi-Clinic; H. Louwrens, J.A. Saaiman, W. Smit, L. MacGregor, D. van der Merwe, H van Rooyen, G. Warren, S. Weideman, Panorama Medi-Clinic; R. de Beer, Louis Leipoldt Hospital; R. Allen, The Sanger Clinic, Charlotte, North Carolina, U.S.A.; J. Potgieter, C. Treunicht, M. de Kock, N1 City Hospital, Goodwood; J. Stofberg, H. Prins, Louis Leipoldt Hospital; C. Dreyer, Christian Barnard Memorial Hospital; D. du Toit, Tygerberg Hospital; J. Klompje, Paarl Medi-Clinic; G. Morrison, Worcester Medi-Clinic; D. Notling, Stellenbosch Medi-Clinic; E. Swanepoel, Durbanville Medi-Clinic.

References

- Schoen FJ, Cotran RS. The blood vessels. In: Kumar V, Cotran RS, Robbins SL, eds. *Robbin's Pathology*, 7th edn, Ch 10. Philadelphia: Saunders, 2003: 325-360.
- Guirguis EM, Barber GE. Natural history of abdominal aortic aneurysms. *Am J Surg* 1991; **162**: 481-483.
- Brown PM, Zelt DT, Sobolev B. The risk of rupture in untreated aneurysms: the impact of size, gender, and expansion rate. *J Vasc Surg* 2003; **37**: 280-284.
- Aziz IN, Lee JT, Kopchok A, Carlos E, Donayne CE, White RA, De Virgilio C. Cardiac risk stratification in patients undergoing endoluminal graft repair of abdominal aortic aneurysm: A single-institution experience with 365 patients. *J Vasc Surg* 2003; **38**: 56-80.
- The UK Small Aneurysm Trial Participants. Long-term outcomes of immediate repair compared with surveillance of small abdominal aortic aneurysms. *N Engl J Med* 2002; **346**: 1445-1452.
- Williamson WK, Nicoloff AD, Taylor LM, Monetta GL, Landryt GJ, Porter JM. Functional outcome after open repair of abdominal aortic aneurysm. *J Vasc Surg* 2001; **33**: 913-920.
- Hallet JW, Naessens JM, Ballard DJ. Early and late outcome of surgical repair for small abdominal aortic aneurysms: a population based analysis. *J Vasc Surg* 1993; **18**: 684-689.
- Arko FR, Hill BB, Reeves TR, Olcott C, Harris J, Fogarty TJ, Zarins CK. Early and late functional outcome assessment following endovascular and open aneurysm repair. *J Endovasc Ther* 2003; **10**: 2-9.
- Zarins CK, White RA, Schwarten D, Kinney E, Dietrich EB, Hodgson KJ, et al. AneuRx stent graft versus open surgical repair of abdominal aortic aneurysms: multicenter prospective clinical trial. *J Vasc Surg* 1999; **29**: 292-305.
- Matsumura JS, Brewster DC, Makaroun MS, Naftel DC. A multicenter controlled clinical trial of open versus endovascular treatment of abdominal aortic aneurysm. *J Vasc Surg* 2003; **37**: 262-271.
- Zarins CK. Open resection cannot match the endovascular results. *J Endovasc Ther* 2003; **10**: 1-1-S1.
- Harris P, on behalf of the EUROSTAR collaborators. Endovascular AAA repair is not a failed experiment: Improving results from EUROSTAR. *J Endovasc Ther* 2003; **10**: 1-1-S1.
- Brewster DC. Presidential address: what would you do if you were your father? Reflections on endovascular abdominal aortic aneurysm repair. *J Vasc Surg* 2001; **33**: 1139-1147.
- Eastcott HHG. Aneurysms. In: Birnstingl M, ed. *Peripheral Vascular Surgery*. London: Heinemann, 1993: 284-304.
- Sheil AGR, Reeve TS, Little JM, et al. Aorta-intestinal fistulas following operations upon the abdominal aorta and iliac arteries. *Br J Surg* 1969; **56**: 840-849.
- Du Toit DF, Saaiman JA. Endovascular overview. In: Du Toit DF, Saaiman JA, eds. *Illustrated Manual of Endovascular Stent-Graft Treatment of Abdominal Aortic Aneurysms*. Cape Town: JL van Schaik, 1999: 1-14.
- Du Toit DF, Saaiman JA, De Beer R, Pretorius CF. Endovascular stent-graft repair of abdominal aortic aneurysm - single centre experience and acute outcome. *S Afr Med J* 1998; **88**; *Cardiovasc Suppl* **5**: (C273-281).
- May J, White GH, Yu Weiyan Y, et al. Endoluminal repair of abdominal aortic aneurysms: strengths and weaknesses of various prostheses observed in a 4-5 year experience. *J Endovasc Surg* 1997; **4**: 147-151.
- Moore WS. EVT tube and bifurcated endograft systems: Technical considerations and clinical summary. *J Endovasc Surg* 1997; **4**: 182-194.
- Parodi JC. Endovascular repair of aortic aneurysms, arteriovenous fistulas and false aneurysms. *Wld J Surg* 1996; **20**: 625-633.
- Allen RC, White RA, Zarins CK, Fogarty TJ. What are the characteristics of the ideal endovascular graft for abdominal aortic aneurysm exclusion. *J Endovasc Surg* 1997; **4**: 195-202.
- Schwarten DE, White R, Zarins CA, et al. Preliminary results and efficacy of endovascular treatment of aneurysms (AAA). *Circulation* 1997; **96**: suppl 101 (abstract 2461).
- Ivancev VK, Chuter TAM, Risberg B. The Invancev-Malmö system of endovascular aneurysm exclusion. In: Hopkins B, Yusuf W, Whitaker S, Veith F, eds. *Endovascular Surgery for Aortic Aneurysms*, London: WB Saunders, 1997: 104-121.
- Zarins CK. The US AneuRx Clinical Trial: 6-year clinical update 2002. *J Vasc Surg* 2003; **37**: 904-908.
- Zarins CK, White RA, Moll FL, Crabtree T, Bloch DA, Hodgson KH, et al. The AneuRx stent-graft: four-year results and worldwide experience 2000. *J Vasc Surg* 2001; **33**: 135-145.
- Carpenter JP, for the Endologix Investigators. Multicentre Trial of Powerlink Bifurcated System for Endovascular aortic aneurysm repair. *J Vasc Surg* 2002; **36**: 1129-1137.
- Criado FJ, Wilson EP, Fairman RM, Abdulkhoudoud O, Wellons E. Update on the Talent aortic stent-graft: A preliminary report from United States Phase I and II trials. *J Vasc Surg* 2001; **33**: S1 146-149.
- Jordan WD, Aliocer F, Wirthlin DJ, Westfall AO, Whitley D. Abdominal aortic aneurysms in 'high-risk' surgical patients. Comparison of open and endovascular repair. *Ann Surg* 2003; **237**: 623-630.
- Criado FJ, Fairman RM, Becker GJ. For the investigations of Talent LPS Pivotal Clinical Trial. *J Vasc Surg* 2003; **37**: 709-715.
- Rose DFG, Davidson IR, Hinchcliffe RJ, Whitaker SC, Gregson RH, Mac Sweeney ST, Hopkins BR. Anatomical suitability of ruptured abdominal aortic aneurysms for endovascular repair. *J Endovasc Ther* 2003; **10**: 453-457.
- Du Toit DF, Saaiman A. Anatomical importance of infrarenal aortic branches in conventional and endovascular surgery: A review. *Clin Anat* 2000; **1**: 54-62.
- Veith FJ, Martin ML. Guidelines for the development of transluminally placed endovascular graft devices for aortic aneurysm repair. In: Hopkins B, Yusuf W, Whitaker S, Veith F, eds. *Endovascular Surgery for Aortic Aneurysms*, London: WB. Saunders, 1997: 1-16.

33. Parodi JC, Schonholz C, La Mura R. The Parodi System. In: Hopkins B, Yusuf W, Whitaker S, Veith F, eds. *Endovascular Surgery for Aortic Aneurysms*. London: WB. Saunders, 1997: 164–179.
34. Blum U. The Min Tec system. In: Hopkins B, Yusuf W, Whitaker S, Veith F, eds. *Endovascular Surgery for Aortic Aneurysms*. London: WB. Saunders, 1997: 104–121.
35. Dereume JPE, Ferreira J. The Corvita system. In: Hopkins B, Yusuf W, Whitaker S, Veith F, eds. *Endovascular Surgery for Aortic Aneurysms*. London: WB. Saunders, 1997: 122–139.
36. White RA, Fogarty TJ, Kopschok GE, et al. Evaluation of a modular endovascular bifurcation prosthesis in a canine aortic aneurysm model. *J Vasc Surg* 1996; **24**: 1034–1042.
37. Ouriel K, Clair DG, Greenberg RY, Lyden SP, O'Hara PJ, Sarac TP, et al. Endovascular repair of abdominal aortic aneurysms: Device-specific outcome. *J Vasc Surg* 2003; **37**: 991–998.
38. Mehta M, Veith F, Ohki T, Lipsitz EC, Cayne NS, Darling RC. Significance of endotension, endoleak, and aneurysm pulsatility after endovascular repair. *J Vasc Surg* 2003; **37**: 842–846.
39. Sonesson B, Dias N, Malina M, Olofsson P, Griffin D, Lindblad B, Ivancev K. Intra-aneurysm pressure measurements in successfully excluded abdominal aortic aneurysm after endovascular repair. *J Vasc Surg* 2003; **37**: 733–738.
40. Wain RA, Marin ML, Ohki T, Veith F. Endoleaks after endovascular graft treatment of aortic aneurysms. Classification, risk factors and outcomes. *J Vasc Surg* 1998; **27**: 69–80.
41. Zarins CK, Bloch DA, Matsumoto A, Crabtree T, White RA, and Fogarty TJ. What is the significance of aneurysm enlargement following endovascular repair. *J Endovasc Ther* 2003; **10**: 1-1-1-S1.
42. Buth J, Peppelenbosch N, Yilmaz N, van Marrewijk C, Cuypers P, Duijm L, Tielbeek A. Emergency treatment of symptomatic and ruptured AAA's. Outcome of a prospective intent-to-treat-by EVAR protocol. *J Endovasc Ther* 2003; **10**: 1-1-1-S1.
43. Bertges DJ, Chow K, Wyers MC, Landsittel A, Frydrych AV, Stavropoulos W, et al. Abdominal aortic aneurysm size regression after endovascular repair is endograft dependant. *J Vasc Surg* 2003; **37**: 716–723.
44. Boyle JR, Thompson MM. Endovascular abdominal aortic aneurysm repair is less invasive, now we must prove its efficacy. *J Endovasc Ther* 2003; **10**: 16–19.
45. May J, White GH, Cameron N, Jones MA, Harris JP. Endoluminal repair of abdominal aortic aneurysm prevents enlargement of the proximal neck: A 9-year life-table and 5-year longitudinal study. *J Vasc Surg* 2003; **37**: 86–90.
46. Ahn SS, Rutherford RB, Johnston KW, May J, Veith FJ, Baker JD, et al. Reporting standards for infrarenal endovascular abdominal aortic aneurysm repair. *Ad Hoc Committee for Standardized Reporting Practices in Vascular Surgery of the Society for Vascular Surgery/International Society for Cardiovascular Surgery*. *J Vasc Surg* 1997; **25**: 405–410.
47. Guidelines on Ethics for Medical Research, Cape Town: South African Medical Research Council 1993: 1–50.
48. Goldman L, Caldera DL, Nussbaum SR, et al. Multifactorial index of cardiac risk in noncardiac surgical procedures. *N Engl J Med* 1977; **297**: 845–850.
49. Dripps RD, Eckenhoff JE, Vandam LD. In: *Introduction to Anaesthesia: The Principles of Safe Practice*, 6th edn. Philadelphia: WB. Saunders, 1993: 17–18.
50. Campbell WB. How can we prevent complications from elective aortic surgery? In: Barros D'SA AAB, Bell PRF, Darke SG, Harris PL, eds. *Vascular Surgery Current Questions*. Oxford: Butterworth/Heinemann, 1991: 70–84.
51. Whitaker SC. Pre-operative imaging. In: Hopkins B, Yusuf W, Whitaker S, Veith F, eds. *Endovascular Surgery for Aortic Aneurysms*. London: WB. Saunders, 1997: 17–39.
52. Menard MT, Chew DK, Chan RK, Coute MS, Donaldson MC, Mannick JA, Whittemore AD, Belkin M. Outcome in patients at high risk after open surgical repair of abdominal aortic aneurysm. *J Vasc Surg* 2003; **37**: 285–292.
53. Ernst CB. Abdominal aortic aneurysm. *N Engl J Med* 1993; **328**: 1167–1173.
54. Meier GH, Parker FM, Godziachvili V, Demaswi RJ, Parent FN, Gayle RE. Endotension after endovascular aneurysm repair: The Ancure experience. *J Vasc Surg* 2001; **34**: 421–427.
55. Chuter TAM, Faruqi RM, Sawtiney R, Reilly LM, Kerlan R, Cantro CJ, et al. Endoleak after endovascular repair of abdominal aortic aneurysm. *J Vasc Surg* 2001; **34**: 98–105.
56. Sampram ES, Karafa MT, Mascha EJ, Clair DG, Greenberg RK, Lyden SP, O'Hara PJ, et al. Nature, frequency and predictors of secondary procedures after endovascular repair of abdominal aortic aneurysm. *J Vasc Surg* 2003; **37**: 930–937.
57. Rhee RY, Garvey L, Missig-Carol N, Makaroun MS. Does endograft support alter the rate of aneurysm sac shrinkage after endovascular repair? *J Endovasc Ther* 2003; **10**: 411–417.
58. White GH, May J, Petrasac P, et al. Endotension: an explanation for continued AAA growth after successful endoluminal repair. *J Endovasc Surg* 1999; **6**: 308–315.
59. Zarins CK, White RA, Hodgson KG, et al. Endoleak as predictor of outcome after endovascular aneurysm repair: Aneurx® multicentre clinical trial. *J Vasc Surg* 2000; **32**: 90–107.
60. Malina M, Lanne T, Ivancev K, et al. Reduced pulsatile wall motion of abdominal aortic aneurysms after endovascular repair. *J Vasc Surg* 1998; **27**: 624–631.
61. Collin J, Murie JA. Endovascular treatment of abdominal aortic aneurysm: a failed experiment. *Br J Surg* 2001; **88**: 1281–1282.
62. Scharrer-Palmer R, Kotsis T, Kapper X, Gorich J, Sunder-Plussman L. Endovascular stent-graft repair of ruptured aortic aneurysms. *J Endovasc Ther* 2003; **10**: 447–452.
63. Zarins CK, White RA, Fogarty TJ. Aneurysm rupture after endovascular repair using the AneuRx stent graft. *J Vasc Surg* 2000; **31**: 960–970.
64. Torsello GB, Klenk E, Kaspizak B, Umschied T. Rupture of abdominal aortic aneurysm previously treated by endovascular stent graft. *J Vasc Surg* 1998; **28**: 184–187.
65. Politz JK, Newman VS, Stewart MT. Late abdominal aortic aneurysm rupture after AneuRx repair. A report of three cases. *J Vasc Surg* 2000; **31**: 399–406.
66. Kalman PG, Rappaport DC, Merchant N, Clarke K, Johnston KW. The value of late computed tomographic scanning in identification of vascular abnormalities after abdominal aortic aneurysm repair. *J Vasc Surg* 1999; **29**: 442–450.
67. Hinchliffe RJ, Alric P, Owen V, Armon MP, Hopkins BR. Suitability of ruptured AAA's for endovascular repair. *J Endovasc Ther* 2003; **10**: 1-1-1-S1.
68. Faries PL, Cadot-Hadley A, Agarwal G, Kent KG, Hollier LH, Marin ML. Management of endoleak after endovascular aneurysm repair: cuffs, coils and conversion. *J Vasc Surg* 2003; **37**: 1155–1161.
69. Resch T, Malina M, Lindblad R, Dias NV, Sonesson B, Ivancev K. Endovascular repair of ruptured abdominal aortic aneurysms: Logistics and short-term results. *J Endovasc Ther* 2003; **10**: 440–446.
70. Shames ML, Sanchez LA, Rubin BG, Choi ET, Geraghty J, Flaye MW, et al. Delayed complications after endovascular AAA repair in women. *J Endovasc Ther* 2003; **10**: 10–15.
71. Strom JA, Bernhard VM, Towne JB. Acute limb ischaemia following aortic reconstruction: a preventable cause of increased mortality. *Arch Surg* 1984; **119**: 470–473.
72. Towne JB. Acute limb ischaemia following aortic surgery. In: Bergan JJ, Yao JST, eds. *Aortic Surgery*. Philadelphia: WB. Saunders, 1989: 511–518.
73. Lord JW, Rossi G, Daliana M. Unsuspected abdominal aortic aneurysms as the cause of peripheral arterial occlusive disease. *Ann Surg* 1973; **177**: 767–774.
74. Converse CA, Hammer HM, Packard CJ, Shepherd J. Plasma lipid abnormalities in retinitis pigmentosa and related conditions. *Trans Ophthalmol Soc UK* 1983; **103** (part 5): 508–512.
75. Hussain AA, Voaden MJ. Studies on retinitis pigmentosa in man. II. Erythrocyte osmotic fragility. *Br J Ophthalmol* 1985; **69**: 126–128.
76. Voaden MJ, Hussain AA, Chan IP. Studies on retinitis pigmentosa in man. I. Taurine and blood platelets. *Br J Ophthalmol* 1982; **66**: 771–775.
77. Towne JB, Bernard VM, Hussey R, Garancis JC. White clot syndrome. Peripheral vascular complications of heparin therapy. *Arch Surg* 1979; **114**: 372–377.
78. Feng WC, Singk AK, Bert AA, Sanofsky SJ, Crowley JP. Perioperative paraplegia and multiorgan failure from heparin-induced thrombocytopenia. *Ann Thore Surg* 1993; **55**: 1555–1557.
79. Makhoul RG, Greenberg CS, Mc Cann RL. Heparin-associated

- thrombocytopenia: a serious clinical problem and potential solution. *J Vasc Surg* 1986; **4**: 522–528.
80. Lau LL, Hakim AG, Oldenberg A, Neuhauser B, Mc Kinney JM, *et al*. Effect of suprarenal versus infrarenal aortic endograft fixation on renal function and renal patency: A comparative study with intermediate follow-up. *J Vasc Surg* 2003; **37**: 1162–1168.
81. Cao P, Verszini F, Parlani G, De Rango P, Parente B, *et al*. Predictive factors and clinical consequences of proximal aortic neck dilatation in 230 patients undergoing abdominal aorta aneurysm repair with self-expandable stent grafts. *J Vasc Surg* 2003; **37**: 1200–1205.
82. Jones JW, Mc Cullough LB, Richman BW. Advanced age, dementia, and an abdominal aneurysm: intervene? *J Vasc Surg* 2003; **37**: 1132–1133.
83. Chaikof EL, Blankensteijn JD, Harris PL, White GH, Zarins CK, Bernhard VM, Matsumara JS, *et al*. Reporting standards of endovascular aortic aneurysm repair. *J Vasc Surg* 2002; **35**: 1048–1060.
84. Rozenblit AM, Patlas M, Rosenbaum AT, Okhi T, Veith FJ, Laks MP, Ricci ZJ. Detection of endoleaks after endovascular repair of abdominal aortic aneurysms: value of unenhanced and delayed helical CT acquisitions. *Radiology* 2003; **227**: 426–433.
85. Veith FC, Baum RA, Ohki T, Amor M, Adiseshiah M, Blankensteijn JD, *et al*. Nature and significance of endoleaks and endotension: Summary of opinions expressed at an international conference. *J Vasc Surg* 2002; **35**: 1029–1035.