

# Oesophagojejunal Anastomosis after Total Gastrectomy

L. C. J. VAN RENSBURG

## SUMMARY

Techniques of oesophagojejunal anastomosis were studied in chacma baboons (*Papio ursinus ursinus*). End-to-end anastomosis utilizing a Roux-en-Y loop and interrupted silk sutures gave the best results. End-to-side anastomosis performed in 3 animals resulted in jejunal volvulus.

*S. Afr. med. J.*, 56, 173 (1979).

The immediate postoperative mortality rate after total gastrectomy varies from 5% to 35%.<sup>1-3</sup> The most common cause of death is leakage at the oesophago-enterostomy anastomosis. This particular problem was studied experimentally in chacma baboons (*Papio ursinus ursinus*). It must be emphasized that our purpose was to develop a method for this anastomosis, and a food reservoir was therefore not constructed. The nutritional aspects, although interesting, will not be discussed in this paper.

The usual indication for total gastrectomy is carcinoma of the stomach. Although the incidence of this condition is decreasing in certain countries, e.g. New Zealand, Australia, the USA and the UK, it is still prevalent in countries such as Russia, Japan, Chile, Poland and Scandinavia, and has a high incidence in this country among the Coloured population of the Western Cape.

Stomach cancer is often diagnosed late and the overall resectability rate is between 50% and 60%. Radical surgery with the aim of eradicating the disease is possible in only 1 in 4 patients.<sup>1</sup> It is generally believed that about 20-40% of patients with carcinoma of the stomach will require total gastrectomy.<sup>1,2,4,5</sup>

## MATERIAL AND METHODS

Chacma baboons weighing between 12 and 15 kg were used in this study. Total gastrectomy, with splenectomy, was performed. The duodenum was closed in two layers. The technique for the oesophago-enterostomy anastomosis was standardized but the suture material varied. All the operations were performed under general anaesthesia and the abdominal route was used exclusively.

In the first 3 baboons an end-to-side oesophagojejunal anastomosis with an entero-enterostomy was done, but all the animals died from volvulus of the jejunal loop. The small-bowel mesentery is very lax in the baboon, and splinting the anastomosis with a nasogastric tube is not always possible. This, combined with indiscriminate feeding, probably caused volvulus in these cases. We therefore resorted to an end-to-end oesophagojejunal anastomosis using a Roux-en-Y loop.

## TECHNIQUE

Before the stomach is removed, a soft clamp, usually a vascular clamp, is applied to the oesophagus to prevent retraction of the mucosa (Fig. 1). An adequate length of oesophagus can always be found. High transection of the vagi increases this length (Fig. 2). A Roux-en-Y loop is

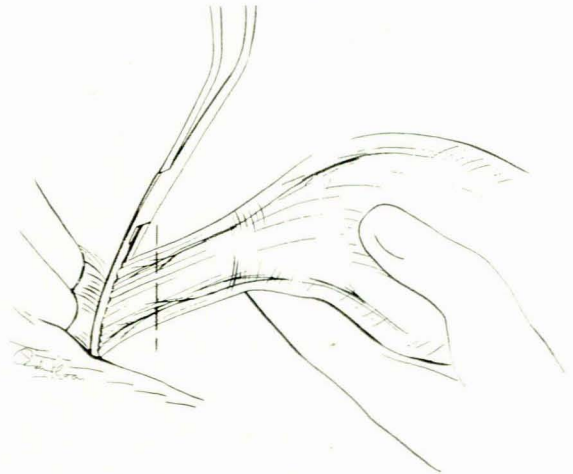


Fig. 1. Vascular clamp on oesophagus.

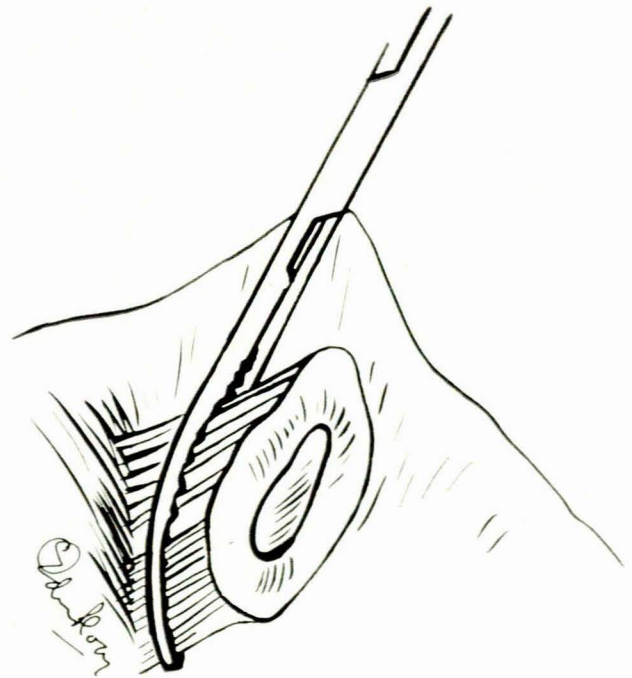


Fig. 2. Oesophagus divided.

Department of Surgery, Tygerberg Hospital and University of Stellenbosch, Parowvallei, CP

L. C. J. VAN RENSBURG, M.MED. (SURG.), F.C.S. (S.A.), F.R.C.S.  
(Present address: 828 Medipark, Foreshore, Cape Town)

Date received: 19 September 1978.

then fashioned (Fig. 3), the proximal end of the jejunum being secured with a small vascular clamp. The first row of sutures is inserted into the oesophagus, starting posteriorly. Six - eight interrupted sutures are inserted from without to within the lumen. It is important to ensure that

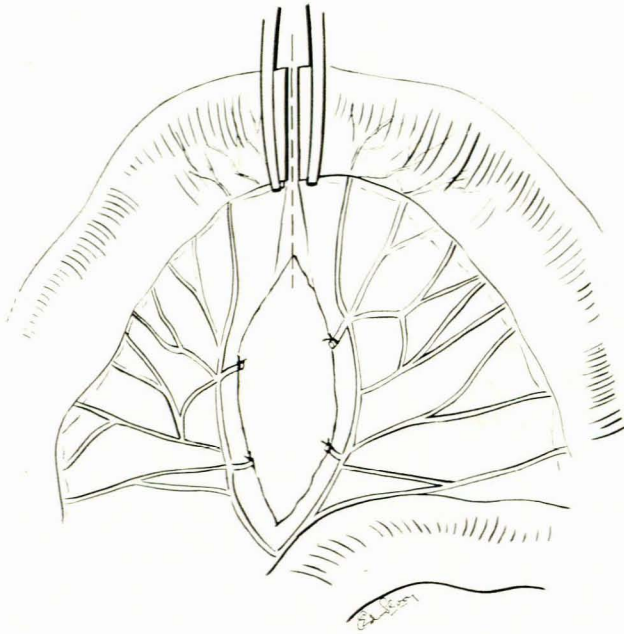


Fig. 3. Preparing Roux-en-Y loop.

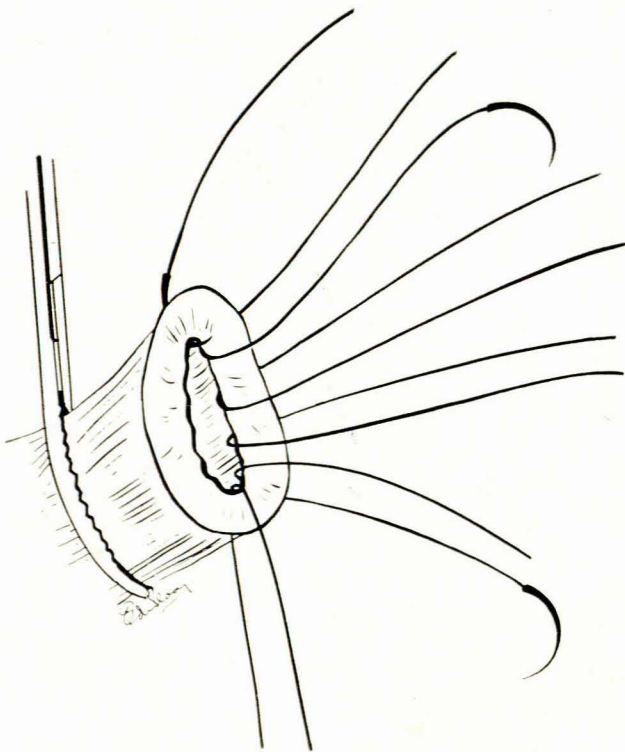


Fig. 4. Insertion of all-layer suture.

an adequate cuff of mucosa is included in the suture (Fig. 4). These suture ends are then held in mosquito forceps and the oesophagus is pulled upward and forwards, exposing its posterior aspect (Fig. 5). This manoeuvre makes it easy to insert and tie an outer interrupted seromuscular layer of sutures (Fig. 6). Once again 6 - 8 sutures are used. The end of the jejunum is trimmed, and it is very easy to loop the oesophageal sutures over the mucosal end and through the jejunum from within outwards (Fig. 7). The sutures are tied, giving an adequate and accurate mucosa-to-mucosa suture line (Fig. 8). The knots are snugly buried in the crevice between the two segments of bowel. The anterior layer is then completed in a similar fashion (Figs 9 and 10). Finally, the anastomosis is anchored to the diaphragm by 2 sutures. An end-to-side entero-anastomosis is then completed in two layers, about 20 - 25 cm distal to the proximal anastomosis (Fig. 11.)

As there were no problems of volvulus with this type of anastomosis, no attempt was made to splint the anastomosis with a tube.

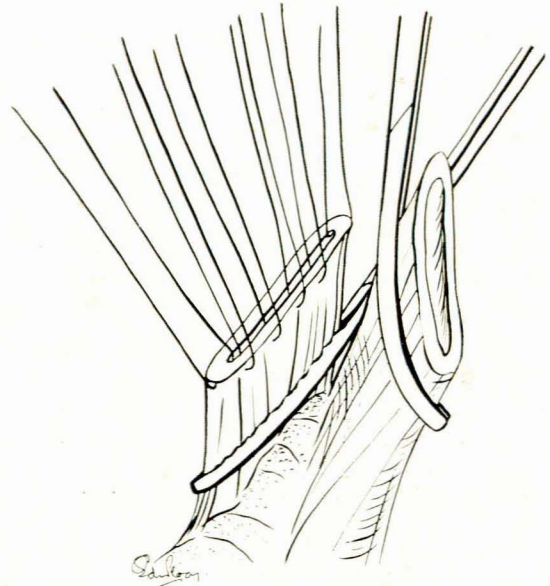


Fig. 5. Anterior flexion of oesophagus to facilitate oesophagojejunal anastomosis.

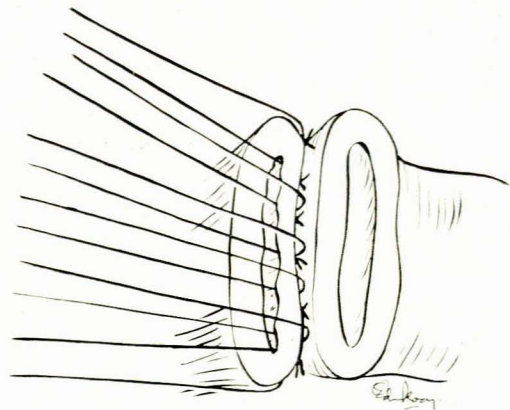


Fig. 6. Posterior oesophagojejunal anastomosis complete.

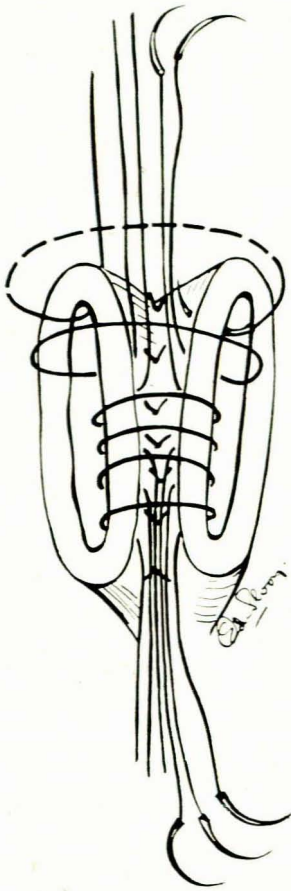


Fig. 7. All posterior inner layer full-thickness sutures in place.

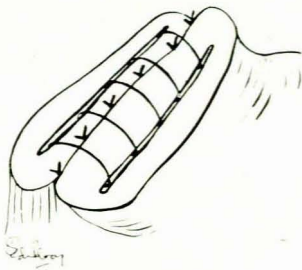


Fig. 8. All inner layer sutures tied, showing mucosa-to-mucosa anastomosis.

**RESULTS**

End-to-side oesophagojejunal anastomosis with jejunojejunostomy caused volvulus of the jejunal loop and death in the first 3 animals on the 26th, 15th and 1st postoperative days.

End-to-end oesophagojejunal anastomosis with a Roux-en-Y loop proximal anastomosis using interrupted 4-0 polyglactin (Vicryl) on both layers caused stenosis of the oesophago-enterostomy and death in 2 animals on the

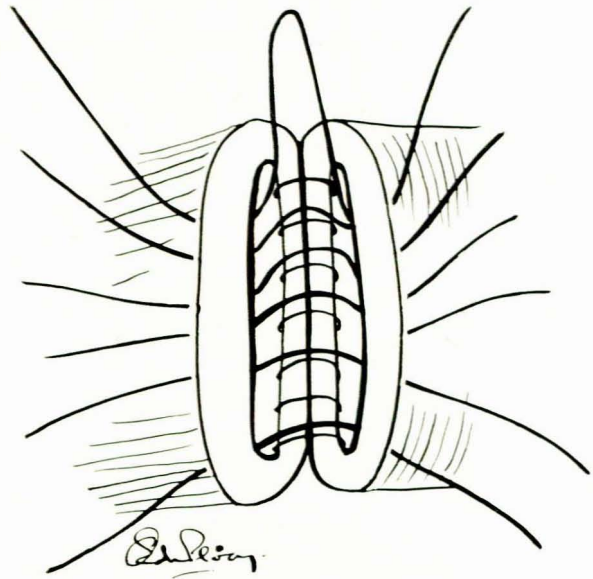


Fig. 9. Anterior full-thickness sutures in place.

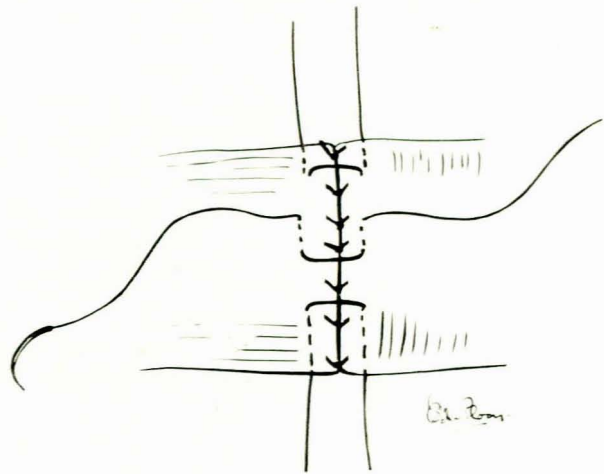


Fig. 10. Completion of anterior layer.

83rd and 60th postoperative days.

End-to-end oesophagojejunal anastomosis with Roux-en-Y loop proximal anastomosis of the inner and outer layers with interrupted 3-0 black silk caused malnutrition and death in 1 animal on the 200th postoperative day. One animal had jejunojejunal intussusception and died on the 72nd postoperative day, and 1 died on the 32nd postoperative day from left basal pneumonia. All anastomoses were patent.

End-to-end oesophagojejunal anastomosis with Roux-en-Y loop proximal anastomosis of the inner layer was done with interrupted 3-0 chromic catgut and of the outer layer with interrupted 3-0 black silk in 3 animals. All 3 died of malnutrition on the 150th, 162nd and 147th postoperative days. All anastomoses were patent.

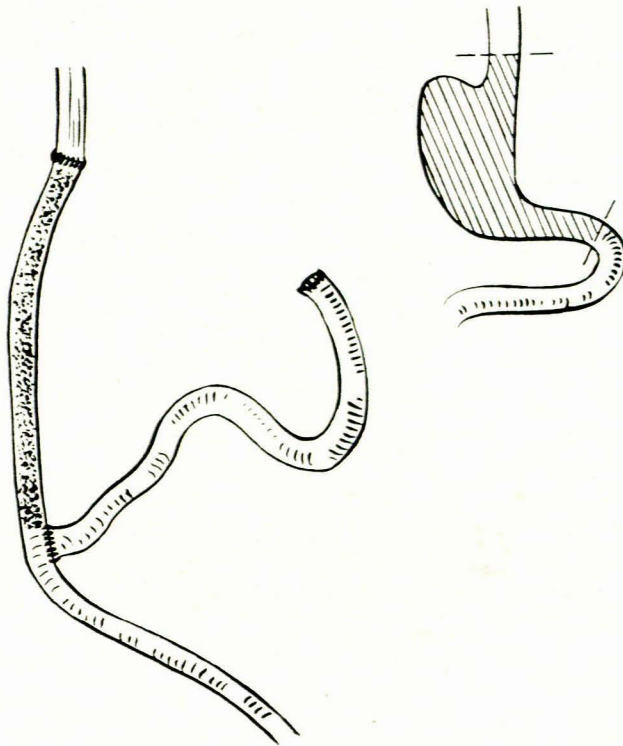


Fig. 11. End-to-side entero-anastomosis completed in two layers.

### DISCUSSION

The best results were obtained with an end-to-end oesophagojejunal anastomosis when interrupted 3-0 black silk was used for both layers, and when an outer layer of interrupted black silk with an inner layer of 3-0 chromic catgut was used. No leakage from the proximal anastomosis occurred in the 6 animals in which these suture materials were used. All 6 animals died, the shortest period of survival

being 32 days and the longest 200 days. The cause of death was malnutrition in 4, left basal pneumonia in 1, and jejunojejunal intussusception in 1. At postmortem examination no evidence was found of alkaline oesophagitis, which confirmed the importance of siting the distal end-to-side jejunal anastomosis at least 25 cm below the proximal anastomosis.<sup>6</sup> There was no evidence of stenosis at the oesophagojejunal anastomosis. End-to-side oesophagojejunal anastomosis resulted in volvulus of the jejunal loop in the 3 animals in which it was used. It was found that an end-to-end anastomosis was more successful; therefore the end-to-side technique was discontinued.

The principles and techniques of this type of anastomosis have been adequately described in the literature,<sup>1-10</sup> and we would like to emphasize two important aspects, i.e. a tension-free suture line and an accurate mucosal approximation. This is easily obtained using this technique, which has been used in several patients with no problems.

The application of a clamp to the oesophagus could be criticized, especially after extensive mobilization of the oesophagogastric junction in a patient with gastric carcinoma. However, the function of the clamp is merely to hold the oesophagus lightly to prevent mucosal retraction. It does not crush the tissue thereby interfering with its blood supply.

I wish to thank the Harry Crossley Research Fund for financial assistance, and my able assistants, Messrs G. Louw, L. Nieuwenhuizen, J. Meyer and J. J. Geldenhuys of the Surgical Research Unit of Tygerberg Hospital. I am also indebted to Dr B. McCulley for the postmortem reports.

### REFERENCES

1. Lundh, G., Ian Burn, J., Kolig, G. *et al.* (1974): *Ann. roy. Coll. Surg. Engl.*, **54**, 219.
2. ReMine, W. H. and Priestly, J. T. (1966): *Ann. Surg.*, **163**, 736.
3. Inberg, M. V., Heinonen, H., Rantakokko, V. *et al.* (1975): *Arch. Surg.*, **110**, 703.
4. Paulino, F. and Roselli, A. (1973): *Curr. Prob. Surg.*, December, p. 3.
5. Marshall, S. F. (1956): *Surg. Clin. N. Amer.*, **36**, 673.
6. Lawrence, W. and McNeer, G. (1960): *Surg. Gynec. Obstet.*, **111**, 691.
7. Zanaroni, A. (1977): *Minerva med.*, **68**, 311.
8. Paulino, F. (1970): *Hospital (Rio de J.)*, **77**, 27.
9. Marshall, S. F. (1956): *Surg. Clin. N. Amer.*, **36**, 673.
10. Horishi, A. (1973): *Arch. Surg.*, **107**, 513.

## Books Received : Boeke Ontvang

**Current Medical Diagnosis and Treatment 1979.** By M. A. Krupp, M. J. Chatton *et al.* Pp. 1130. Illustrated. \$18.00. Los Altos, California: Lange Medical Publications. 1979.

**Obstetrics (Fundamentals of Obstetrics and Gynaecology, Vol. 1).** 2nd ed. By D. Llewellyn-Jones. Pp. 471. Illustrated. £12.00. London: Faber & Faber Limited. 1977.

**Gynaecology (Fundamentals of Obstetrics and Gynaecology, Vol. 2).** 2nd ed. By D. Llewellyn-Jones. Pp. 296. Illustrated. £11.50. London: Faber & Faber Limited. 1978.

**Psigologiesoordeboek.** Deur L. A. Gouws, D. A. Louw, W. F. Meyer en C. Plug. Pp. 484. R10,95. Johannesburg: McGraw-Hill Boekmaatskappy. 1979.

**Conduct Disorders in Youth.** By L. Schlebusch. Pp. viii + 118. Illustrated. R7,75. Durban: Butterworth & Co. (SA) (Pty) Ltd. 1979.

**Echocardiography: A Manual for Technicians.** By Christine Miskovits and E. Frederici. Pp. 224. Illustrated. Berne: Hans Huber Publishers. 1977.