

# Iatrogenic aortocoronary vein fistula

## A case presentation and review of the literature

J. Z. PRZYBOJEWSKI

### Summary

A patient underwent aortocoronary saphenous bypass grafting to the left anterior descending coronary artery (LADA) and its first diagonal branch for the relief of severe angina pectoris. There was difficulty in exposure of the LADA, which was covered by a thick layer of epicardial adipose tissue. Post-operatively the patient continued to experience severe retrosternal pain which prompted early repeat coronary angiography. This revealed an aortocoronary vein fistula (AVF) secondary to the inadvertent anastomosis of one of the saphenous vein grafts to the left anterior descending coronary vein (LADV). It was only after this procedure that clinical examination revealed a grade 2/6 high-frequency continuous murmur best heard in the 2nd and 3rd left intercostal spaces. The persistence of severe angina pectoris at rest and on effort led to performance of a revision operation. The LADV was then transected and ligated, and an extended saphenous vein reimplanted into the LADA proper. This provided complete relief from angina.

This is the first such case reported in South Africa and the sixth documented. In all the aortosaphenous vein grafts had been inserted into the LADV; all exhibited the classic continuous murmur postoperatively, apart from 1 patient who had an ejection systolic murmur. None of the other 5 patients complained of postoperative angina and only 3 were subjected to revision surgery.

The literature is reviewed, with emphasis on the rationale for performing the first elective aortocoronary vein anastomosis in 1968. Clinical features of iatrogenic AVF are detailed and an attempt is made to assess when re-operation is indicated. It is easy to fail to notice this complication; however, its correction can have a dramatic effect on the patient's symptoms. It is the author's belief that many more such cases exist but are not being detected, probably because of lack of appreciation of the possibility of this iatrogenic condition occurring.

*S Afr Med J* 1982; 62: 908-917.

Ischaemic heart disease (IHD) has reached virtually epidemic proportions among White South Africans. As a result of this high incidence more people are being subjected to coronary angiography and coronary artery bypass grafting. Approximately 10%

of those undergoing coronary angiography are found to be ideally suitable for such an operation, primarily to relieve the disabling symptom of angina pectoris. About 150 patients undergo bypass operations annually at Tygerberg Hospital, and this is probably the average figure in other cardiological centres.

Aortocoronary vein fistula (AVF) formation has been carried out electively in earlier times to improve the quality of life in the patient with IHD. This procedure was mainly adopted in patients with a coronary artery anatomy considered unsuitable for modern bypass graft surgery. However, nowadays it would appear that elective creation of an AVF has been largely abandoned in favour of saphenous bypass surgery and cardiac transplantation in the more severely affected patient.

The present case serves to illustrate the ease with which an iatrogenic AVF may be missed and the importance of detecting this most unusual problem. I am convinced that far more similar cases have occurred in the past but that these have been undetected on clinical examination and therefore have not been reported in the literature.

### Clinical presentation

The patient was a 43-year-old White man, apparently completely asymptomatic before his admission to the Cardiac Unit of Tygerberg Hospital on 23 April 1977. His history was that of a severe burning and pressing retrosternal pain brought on by exertion and lasting some 3 hours. There was no radiation or any associated symptoms apart from profuse sweating. Sublingual trinitrin definitely eased the chest pain.

On interrogation the patient admitted to being a heavy smoker (30 cigarettes/d). There was no past history of any cardiovascular illness and the patient was not taking regular medication. Apparently his father had died of an acute myocardial infarction at the age of 50 years.

Examination revealed a slightly overweight man with no detectable stigmata of hyperlipidaemia. His blood pressure was 130/80 mmHg and the radial pulse regular at 76/min. Peripheral pulses were all easily palpable and the fundi normal. The apex beat was impalpable. Heart sounds were normal. The rest of the examination was entirely negative.

A resting ECG showed a sinus rhythm of 75/min, a PR interval of 0,14 second and a mean QRS axis of +70°. Fairly deep symmetrical T-wave inversion was noted in leads aVL and V2-V4. There were no other abnormalities. A chest radiograph delineated a normal cardiac silhouette and normal lung fields. Results of a full blood count and serum biochemical examination were within normal limits. A barium swallow and barium meal examination and a radiograph of the cervical spine were all normal. Repeated serial resting ECGs failed to show any change and daily serum enzyme estimations did not show the typical pattern of an acute myocardial infarction.

On the basis of the above, the patient was managed as a case of recent-onset angina pectoris with the possibility of a non-transmural antero-septal myocardial infarction of indeterminate age. He was started on oral long-acting nitrates and small doses of  $\beta$ -blockers. His course was uncomplicated and he was therefore discharged from hospital after 10 days, on 4 May 1977, but was re-admitted on the following day, again with severe chest

Cardiology Unit, Department of Internal Medicine, Tygerberg Hospital and University of Stellenbosch, Parowvallei, CP

J. Z. PRZYBOJEWSKI, M.B. CH.B., F.C.P. (S.A.)

Date received: 1 April 1982.



pain. Repeated ECGs and enzyme studies failed to show any change. As the patient was experiencing severe and frequent angina at rest despite large doses of nitrates and  $\beta$ -blockers it was decided to perform cardiac catheterization and coronary angiography on 12 May 1977.

### Pre-operative cardiac catheterization

Cardiac catheterization was performed using the standard percutaneous Seldinger technique via the right femoral artery and vein. A 7F pigtail and Goodale-Lubin catheter was used to measure left and right intracardiac pressures, as well as oxygen saturations in the central aorta and main pulmonary artery (Tables I and II). Intracardiac pressures were within normal limits, as were the cardiac output and pulmonary and systemic vascular resistance.

**TABLE I. PRE-OPERATIVE INTRACARDIAC PRESSURES**

Catheter position	Pressure (mmHg)	Comment
<b>Right atrium</b>	'a' wave 6, 'x' descent 3 'v' wave 5, 'y' descent 2 (mean 3)	<b>Normal</b>
<b>Right ventricle</b>	30/1-8	<b>Normal</b>
<b>Main pulmonary artery</b>	30/10 (mean 17)	<b>Normal</b>
<b>Pulmonary capillary wedge</b>	'a' wave 5, 'x' descent 2 'v' wave 6, 'y' descent 3 (mean 5)	<b>Normal</b>
<b>Left ventricle</b>	123/0-9	<b>Normal</b>
<b>Ascending aorta</b>	123/76 (mean 95)	<b>Normal</b>

Left ventricular cine angiography in the right anterior oblique view delineated an anterolateral myocardial infarction. Contractility was otherwise normal and there was no mitral insufficiency (Fig. 1). Injection of dye into the right coronary artery (RCA) showed it to be dominant, ectatic and free of significant obstructive lesions (Fig. 2A). There was no retrograde filling of the left coronary artery (LCA) by way of right-to-left collaterals.

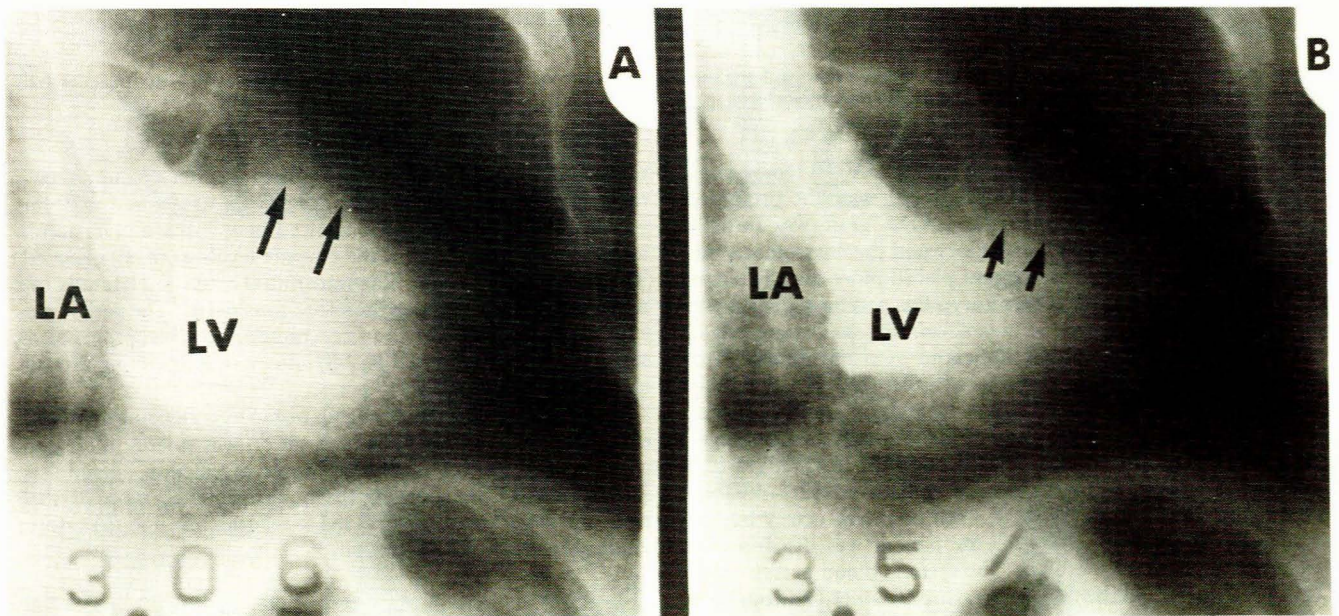
**TABLE II. PRE-OPERATIVE HAEMODYNAMIC CALCULATIONS**

Parameter	Result
<b>Aortic O<sub>2</sub> saturation (%)</b>	<b>94</b>
<b>Pulmonary artery O<sub>2</sub> saturation (%)</b>	<b>73</b>
<b>Arteriovenous O<sub>2</sub> difference (vol %)</b>	<b>3,6</b>
<b>O<sub>2</sub> consumption (ml/min)</b>	<b>250</b>
<b>Cardiac output (Fick) (l/min)</b>	<b>6,9</b>
<b>Cardiac index (Fick) (l/min/m<sup>2</sup>)</b>	<b>3,6</b>
<b>Pulmonary vascular resistance (U)</b>	<b>1,7</b>
<b>Systemic vascular resistance (U)</b>	<b>13,2</b>
<b>Stroke volume (ml/beat)</b>	<b>113</b>
<b>Stroke-work index (g-m/m<sup>2</sup>)</b>	<b>81,9</b>
<b>Left ventricular dp/dt (mm/s)</b>	<b>2 051</b>

LCA angiography (Figs 2B and 3A) outlined a normal left mainstem coronary artery. However, there was a 70% obstructive lesion in the left anterior descending coronary artery (LADA) just distal to the first septal perforator, and a 90% occlusive lesion just proximal to the origin of the first diagonal branch. Both the distal LADA and its first diagonal branch showed good distal run-off and were considered suitable for bypass surgery. The left circumflex coronary artery only demonstrated minor internal luminal irregularities and did not provide any left-to-left collateralization of the LADA.

### First coronary bypass operation

A coronary bypass operation was performed on 12 May 1977. At median sternotomy it was noted that the sternum was very thick and it was difficult to obtain haemostasis of the periosteum. The patient was placed on cardiopulmonary bypass with body cooling at 28°C (rectal). Ventricular fibrillation was electively produced, the ascending aorta was cross-clamped and Plasma-lyte B 300 ml perfused. The heart was of normal size with no overt evidence of recent or old myocardial infarction. A very thick layer of epicardial adipose tissue made it most difficult to assess the exact course of the coronary arteries, especially the LADA and its diagonal branches. The first diagonal branch of the LADA was 8 mm in internal luminal diameter and an end-to-end anastomosis with a saphenous vein was made using Prolene



**Fig. 1.** Pre-operative left ventricular cine angiogram (right anterior oblique projection) in diastole (A) and systole (B). An area of anterolateral myocardial infarction (arrowed) is present. There is no mitral insufficiency.



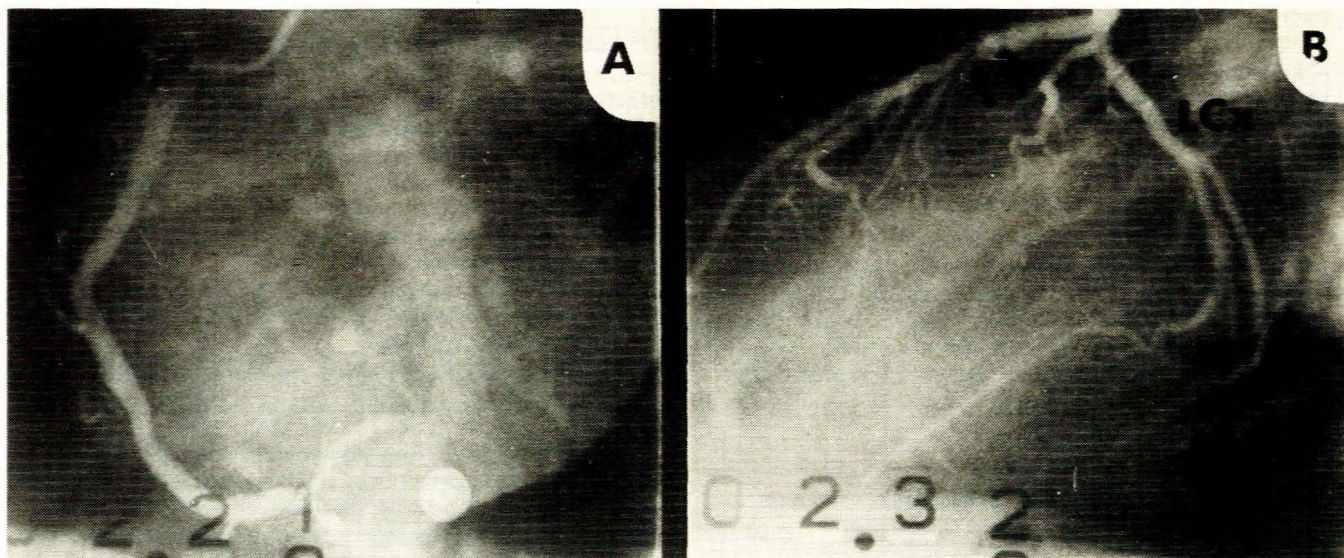


Fig. 2. Pre-operative — (A) RCA (left anterior oblique view) with insignificant lesions; (B) LCA (left anterior oblique projection) showing two significant obstructions (arrowed) in the LADA. Insignificant lesions can be seen in the left circumflex coronary (LCx) artery.

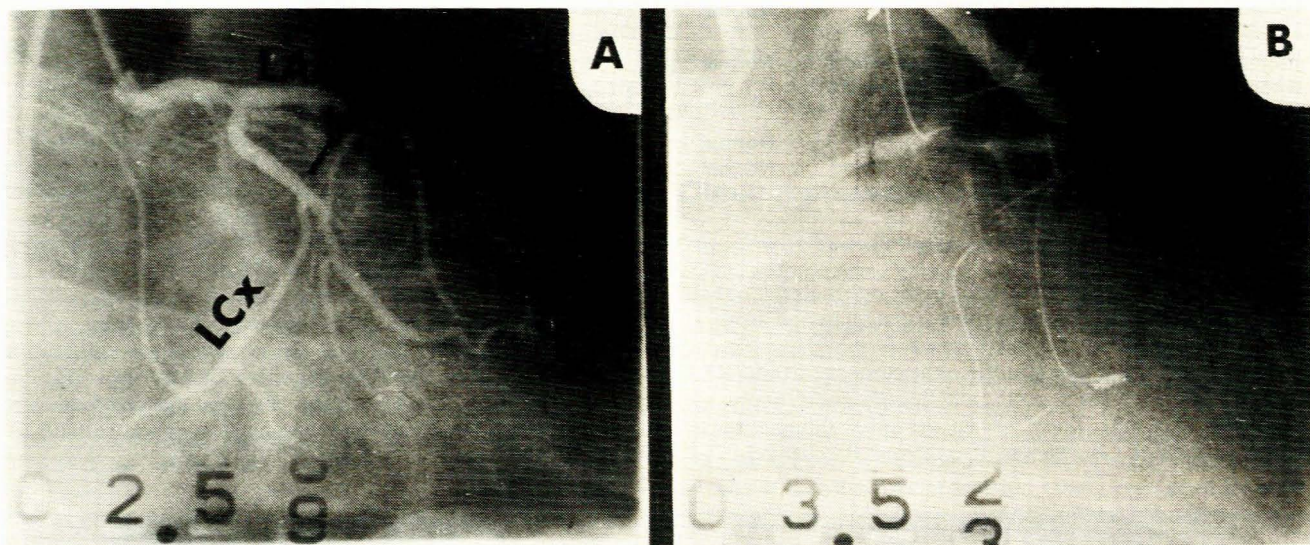


Fig. 3. (A) pre-operative — LCA (right anterior oblique view) with the same lesions (arrowed) as noted in Fig. 2b; (B) postoperative — dye injection into patent first diagonal branch graft (right anterior oblique projection).

6-0 sutures. The fat layer overlying the LADA was then incised and a similar anastomosis was undertaken with the presumed LADA. The back-flow from the LADA graft was initially assessed as not being very satisfactory and the anastomosis was therefore subsequently revised and placed more distally where the back-flow was more satisfactory. The ascending aorta was unclamped and intermittent cross-clamping was employed to carry out the proximal aorta-saphenous vein anastomosis with Prolene 6-0 sutures. This step was satisfactorily completed and the patient was then rewarmed to a body temperature of 35°C (rectal) and the heart defibrillated. Flow through the first diagonal branch was 225 ml/min and through the LADA graft 50 ml/min, but these values were not considered very reliable. Good pulsation was detected in both coronary artery bypass grafts (CABGs), especially after the patient was disconnected from cardiopulmonary bypass. The systolic blood pressure was 100-120 mmHg and the venous pressure 10 cm H<sub>2</sub>O throughout the operation.

In the first few days the patient's postoperative course appeared to be quite satisfactory. However, 10 days after opera-

tion he experienced a further episode of severe retrosternal pain radiating to the left shoulder and not readily relieved by sublingual trinitrin. Repeat ECGs showed new T-wave inversion in leads I and V5 and V6 but the enzyme levels were not elevated. The possibility of slight non-transmural extension laterally of a myocardial infarction was therefore considered. The patient was kept in hospital for a further week, no additional symptoms being seen, and was discharged on high doses of long-acting nitrates and β-blockers.

In the following weeks he again began experiencing angina on effort as well as at rest. His medication was further increased, with the addition of increasing doses of calcium antagonists. Despite this he remained virtually incapacitated by his symptoms and it was therefore decided to readmit him and to perform a repeat cardiac catheterization.

#### Postoperative cardiac catheterization

This was performed from the right femoral artery using the Seldinger technique. The left ventricular and aortic pressures



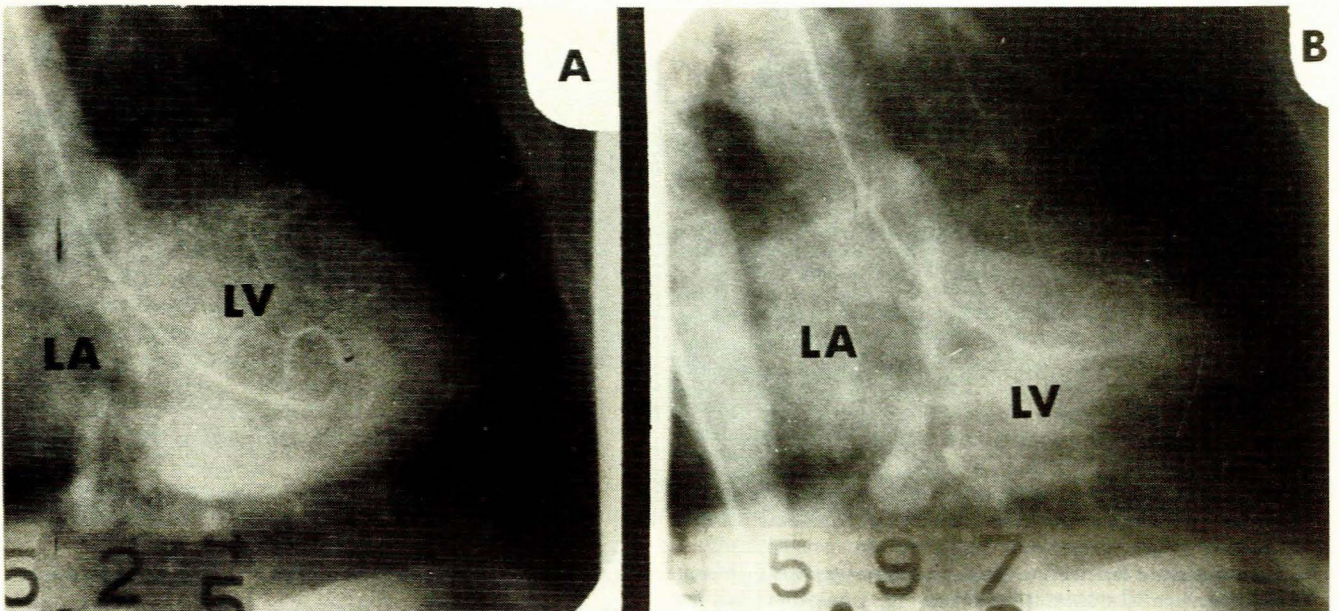


Fig. 4. Postoperative left ventricular cine angiogram (right anterior oblique projection) in (A) diastole and (B) systole. There is no change from the pre-operative angiogram (Fig. 1).

were found to be within normal limits. Left ventricular cine angiography in the right anterior oblique view (Fig. 4) demonstrated features of an anterolateral myocardial infarction. The remainder of the ventricle contracted normally and there was no evidence of mitral insufficiency.

Selective coronary angiography showed that the RCA remained unchanged (Fig. 2A). Injection of dye into the LCA outlined a 90% occlusive lesion of the LADA proximal to its first diagonal branch (Fig. 5B), in addition to the 70% obstruction just proximal to this lesion. The left circumflex coronary artery filled progradely and had minor irregularities of the internal lumen. The graft to the first diagonal branch was noted to fill retrogradely from the LADA. Injection directly into the first diagonal branch graft (Figs 3B and 5A) showed this to be patent at both its proximal aortic and distal coronary anastomoses.

The most extraordinary cine angiograms were obtained when the CABG to the (presumed) LADA was filled with contrast (Fig. 6). Soon after the LADA was injected very rapid filling of the coronary sinus was detected. This was made possible by the iatrogenic AVF since the aortosaphenous vein graft had been anastomosed to the left anterior descending coronary vein (LADV) instead of its accompanying LADA.

Cardiac catheterization was completed without complication and provided a definitive diagnosis of the cause of the patient's continuing postoperative angina pectoris.

In view of these findings the patient was re-examined; auscultation documented a grade 2/6 fairly high-frequency continuous murmur best heard in the 2nd and 3rd left intercostal spaces with no definite radiation. After much discussion it was decided to undertake a revision operation to relieve his severe angina pectoris.

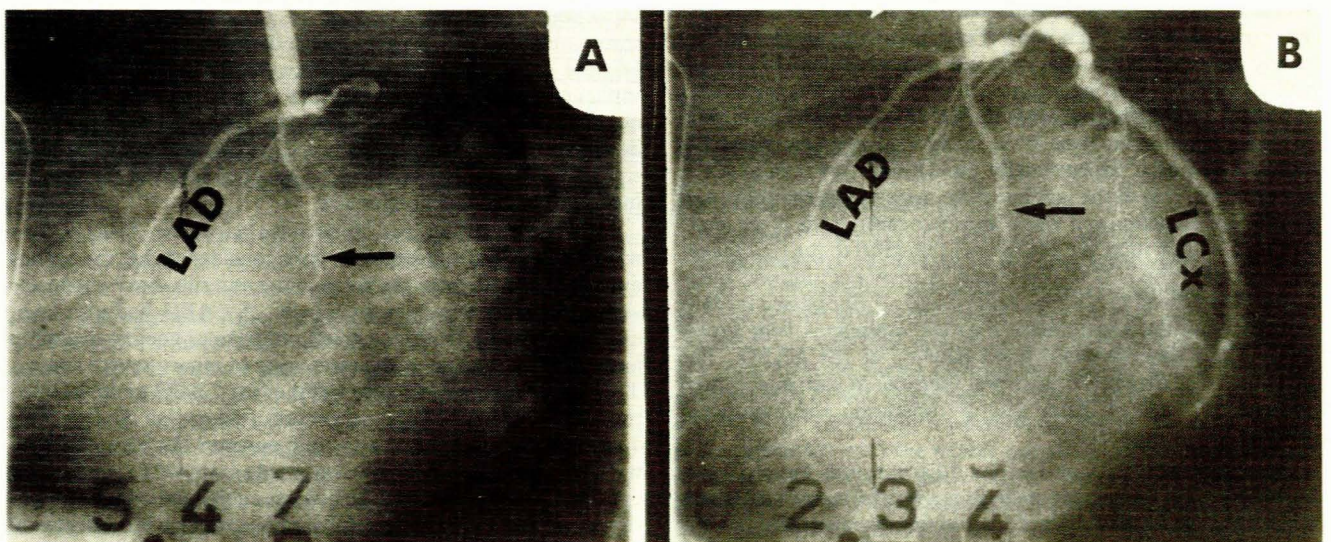


Fig. 5. Postoperative: (A) the patent graft to first diagonal branch (arrowed) of the LADA is seen (left anterior oblique view); (B) LCA (left anterior oblique projection), showing prograde filling of the LADA and left circumflex coronary artery and retrograde filling of the first diagonal branch (arrowed) of the LADA.



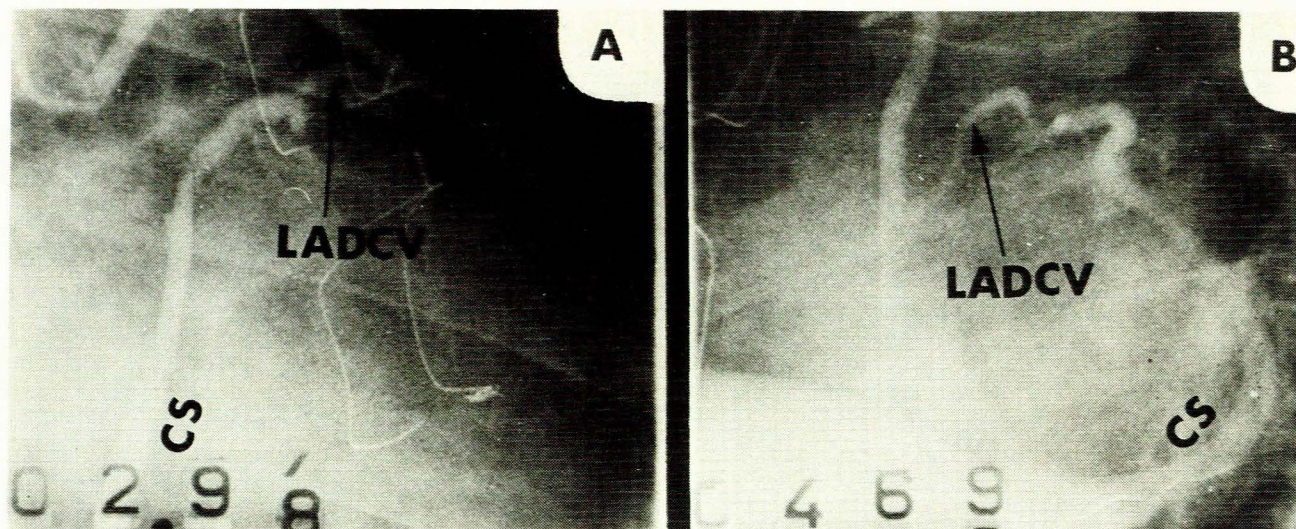


Fig. 6. Postoperative: injection of contrast into presumed LADA graft produces rapid filling of the coronary sinus (CS) via the LADV (A — right anterior oblique view, B — left anterior oblique view).

### Second coronary bypass operation

This was undertaken on 13 July 1977. Thick fibrous tissue between the pericardium and epicardium made dissection exceptionally difficult. Visualization of the myocardium failed to show any evidence of myocardial infarction. Because this tissue had involved the ascending aorta it was decided to perfuse the femoral artery rather than the aorta. Partial cardiopulmonary bypass was then commenced with cooling of the patient to 28°C (rectal). Both previous saphenous vein bypasses were then exposed with careful dissection and identification of the distal vein-artery anastomoses. Elective ventricular fibrillation was instituted and cold Plasmalyte B run into the pericardial sac. The anastomosis between the saphenous vein graft and the anterior interventricular cardiac vein (previously presumed to be the LADA) was transected and the cardiac vein closed with Prolene 6-0. The LADA proper was dissected in a distal-proximal direction as far as the previous saphenous vein-cardiac vein anastomosis. A probe was then inserted into the LADA and passed both proximally and distally without encountering any obstruction. The internal luminal diameter of the LADA was determined as being 1,5 mm. Proximally this vessel coursed very deeply and was covered with a thick layer of epicardial adipose tissue. The newly dissected saphenous vein was then anastomosed end-to-side to the LADA using a continuous Prolene 6-0 suture. After this the 3 cm long saphenous vein was anastomosed end-to-end to the saphenous vein used in the initial inadvertent vein-cardiac vein anastomosis. Exceptionally good blood flow was noted in the proximal part of the saphenous vein graft from the aorta, and prominent pulsation was visualized after completion of the anastomosis. At this stage the saphenous vein graft to the first diagonal branch of the LADA was tested. A small opening was made in the artery distal to the anastomosis and a probe passed into the artery across the anastomosis into the saphenous vein proximally. This demonstrated good patency of the CABG. The incision in the diagonal branch was then closed with interrupted Prolene 6-0 sutures. After this the operation was conducted without any complication.

Postoperatively the continuous cardiac murmur was no longer in evidence and the patient made an uneventful recovery. He was discharged on a small dose of long-acting nitrates. The patient continued to be angina-free. Repeated ECG tracings showed persistent symmetrical T-wave inversion in leads I, aVL and V1-V6.

### Historical background

Only 5 documented cases of the inadvertent anastomosis of a saphenous vein bypass graft to a cardiac vein resulting in an AVF have been reported in the English literature to date. All of these patients were re-catheterized, but only 3 were subjected to re-operation. In 1974 Vieweg *et al.*<sup>1</sup> reported this complication in a patient who developed a continuous murmur over the 2nd left intercostal space some 6 weeks postoperatively, and who was admitted on account of congestive cardiac failure and pneumonia but who did not complain of angina. This patient was re-operated upon despite the absence of angina and a significant left-to-right shunt. The saphenous vein was detached from the anterior interventricular cardiac vein and was anastomosed to the proximal LADA with subsequent disappearance of the continuous murmur.

Lawrie *et al.*<sup>2</sup> documented the second case in 1976. Their patient had undergone three previous unsuccessful coronary bypass operations at other institutions for continuing angina. A soft basal ejection systolic murmur radiating to the neck was noted and selective coronary angiography showed that the saphenous CABG was connected to an LADV which was thrombosed distally. Surgery was undertaken with ligation of the original saphenous vein graft between the origin of the new saphenous vein graft and the LADV. Postoperatively the patient no longer suffered from angina and cardiac catheterization now demonstrated a patent CABG to the LADA and complete occlusion of the AVF. The authors did not state whether the systolic murmur had disappeared or not.

In 1978 Treistman *et al.*<sup>3</sup> reported a third case. Their patient was of particular interest since they considered that the saphenous vein bypass from the aorta to the anterior interventricular vein may well have been beneficial. A CABG had also been inserted into the RCA and a left ventricular aneurysmectomy had been undertaken at the same time to relieve severe angina. They were therefore not sure whether the CABG to the RCA or the AVF was responsible for the relief of the angina. Shortly after operation the patient had a systolic murmur but was otherwise well. Some 3½ years later he was readmitted with supraventricular tachycardia and syncope but was angina-free. On examination a continuous murmur was heard over the 3rd left intercostal space. They decided not to re-operate since the patient had no angina and no significant left-to-right shunting could be detected. He was satisfactorily followed up on anti-arrhythmic medication.



The most recent publication was that of Starling *et al.*<sup>4</sup> who reported 2 cases. Both their patients were initially operated on for uncontrolled angina had a new high-pitched continuous murmur over the 2nd left intercostal space radiating to the cardiac apex in the anatomical course of the anterior cardiac vein within 3 days of surgery. Cardiac catheterization delineated the presence of the saphenous vein bypass graft-anterior cardiac vein anastomosis in both patients. However, since new changes indicative of ischaemia were seen on the ECG of one patient about 3 weeks postoperatively it was decided to re-operate and repair the fistula. The continuous murmur disappeared, nor could ischaemia be demonstrated on the ECG; a thallium-201 treadmill exercise test was normal. The other patient was treated medically since postoperative thallium-201 treadmill stress testing failed to evoke angina or any changes indicating ischaemia on the ECG. In addition, no left-to-right shunt could be demonstrated on postoperative cardiac catheterization.

## Intentional AVFs

Prior to the advent of the accepted modern aortocoronary saphenous vein bypass operation<sup>5</sup> many quite ingenious procedures had been devised to improve myocardial blood supply. Beck and co-workers<sup>6-8</sup> started their pioneering experiments in 1932 by abrading the heart surface and stimulating further inflammation with asbestos dust application, significantly occluding the coronary sinus, and application of parietal pericardium and mediastinal fat to the heart surface. These measures were all aimed at increasing the intercoronary (collateral) circulation in the presence of severe extensive coronary atherosclerosis. Beck claimed that this procedure abolished angina in some 90% of cases, decreased infarct size, probably prevented infarction following total coronary artery occlusion and possibly prolonged life by establishing an 'electrically stable heart'. His second operation entailed first shunting arterial blood from the aorta to the coronary sinus by way of a free vein graft or direct anastomosis between these structures. Some 3 weeks later the second stage was carried out by partially occluding the coronary sinus orifice where it drained into the right atrium. The purpose of this was to increase the pressure within the coronary sinus and thus produce retrograde flow with resultant improved perfusion of ischaemic myocardial zones previously supplied by a severely narrowed coronary artery. Some 186 patients were subjected to one of these two operations.

Bhayana *et al.*<sup>9</sup> modified Beck's approach in those patients with severe disease of the distal coronary arteries and in whom the conventional saphenous CABG would be almost certain to fail. These workers perfused the LADV of sheep with the internal mammary artery and showed a reduction of ischaemia (as assessed by epicardial ST-segment changes) after coronary artery ligation. The unanswered question at that time was whether, subjected to arterial pressure, the coronary vein would undergo atherosclerosis as was known to occur with saphenous vein grafts.

Gardner *et al.*<sup>10</sup> created internal mammary artery LADV anastomoses in dogs. This procedure was shown to create significant retrograde perfusion of the myocardium in that myocardial O<sub>2</sub> uptake was increased from the perfusing blood; the intervention did not create a large arteriovenous shunt but they could not entirely exclude a small shunt. However, the latter possibility was thought to be beneficial in that improved patency and collateral coronary circulation were stimulated.<sup>6</sup>

Chiu and Mulder<sup>11</sup> continued this work with sheep and canine experiments and selectively arterIALIZED the great cardiac vein using internal mammary artery bypass grafts. They clearly showed that retrograde perfusion was achieved without haemorrhage or myocardial oedema. Diastolic flow patterns, simulating those normally observed in humans, were visualized. Furthermore, this intervention gave significant protection to the

myocardium following occlusion of the LADA in that myocardial infarction size was reduced, despite the occurrence of small apical infarctions away from the area supplied by retrograde perfusion. A potential disadvantage of this operation was that significant reversed shunting was noted when microspheres were injected directly into the coronary vein rather than the internal mammary artery. Nevertheless, these workers preferred this intervention to those of Beck and co-workers<sup>6-8</sup> and since Eckstein *et al.*<sup>12</sup> had previously demonstrated that retrograde flow via the coronary sinus was responsible for supplying only 14-25% of the normal myocardial oxygen requirement.

It remained for Park *et al.*<sup>13</sup> to attempt such procedures in patients considered inoperable according to accepted criteria for aortocoronary saphenous vein bypass grafting. They anastomosed the left internal mammary artery to the LADV in 6 patients. An important modification was the ligation of the proximal part of the LADV so as to establish reversed flow towards the capillaries in the myocardium. All these patients had had significant pre-operative angina which had completely disappeared when they were examined 1 year later.

With the onset of time all the above seem to have been abandoned. This may well have been influenced by the advent of cardiac transplantation and the utilization of aortosaphenous bypass surgery in patients not entirely suitable for such a procedure. Nevertheless, it is interesting to note that the inadvertent creation of an AVF, as documented in the aforementioned 6 cases, caused angina pectoris only in our case. This would suggest that the intercoronary circulation is vital in determining which areas will be supplied with adequate nutrient blood supply, which will in turn depend upon prograde and retrograde pressure interactions.

## Haemodynamic effects of AVFs

The diagnosis of the haemodynamic effects of this surgical complication may only be made by postoperative cardiac catheterization, carried out in all 6 cases described so far. Detection of left-to-right shunt can be exceptionally difficult since this is usually small initially and probably increases after operation. Hydrogen inhalation curves were utilized to detect left-to-right shunting in the cases described by Vieweg *et al.*<sup>1</sup> and Treistman *et al.*<sup>3</sup> who found no step-up in O<sub>2</sub> saturation (oximetry) in the right side of the heart. The patients documented by Lawrie *et al.*<sup>2</sup> and the present patient were not suspected of having such a surgical complication and possible left-to-right shunting was therefore not sought. Neither of the cases reported by Starling *et al.*<sup>4</sup> had a left-to-right shunt as assessed by the use of oximetry or indocyanine green dye dilution curves.

## Assessment of murmurs present after bypass surgery

### Systolic murmurs

Karpman<sup>14</sup> reported on a series of 40 patients, in 22 of whom a systolic murmur was first detected after aortocoronary bypass surgery. The murmur was basal in site, maximally audible in the 2nd and 3rd left intercostal spaces, soft and short and displayed a crescendo-decrescendo quality, being especially well heard with the patient in the sitting position and leaning a little forward. Another significant characteristic was that this murmur was usually heard on getting the patient to hold his breath in maximum expiration with the mouth open in order not to perform a Valsalva manoeuvre. In some patients the murmur disappeared completely or was barely audible in the supine position or on deep inspiration. All 22 of these patients had had a CABG inserted into the LADA, and of the 14 who had coronary angiography postoperatively all had patent CABGs. In his series 8 patients had a CABG to the RCA but did not have a clinically



audible cardiac murmur. Of these 8 patients 6 were subjected to coronary angiography and found to have patent RCA bypass grafts. Of the remaining 18 patients 11 had LADA grafts without murmurs. Nine of these 11 patients had repeat coronary angiography; 4 had occluded grafts.

Karpman<sup>14</sup> postulated that the presence of this type of murmur was a very strong indication of the CABG being patent, especially if it was inserted into the LADA. They also suggested that the origin of the murmur was probably due to systolic turbulence created at the proximal aortosaphenous anastomosis. A less likely explanation was that the murmur originated from flow through the CABG itself. This latter suggestion would support the theory that the murmur is heard best over the area in which the CABG took its course, i.e. a LADA graft traverses the anterior chest and an RCA graft runs more deeply and posteriorly.

It must not be forgotten that papillary muscle ischaemia (dysfunction) or actual infarction may occur after bypass surgery; the typical pansystolic murmur of mitral insufficiency would then be evident, the radiation of which would give a good indication as to whether the anterior or posterior papillary muscle was involved.

Far less likely than the above complication is that of ventricular septal rupture secondary to post-bypass anteroseptal myocardial infarction. This murmur would be more harsh and its position of maximum intensity and radiation would help in differentiating it from a mitral insufficiency murmur. A step-up in O<sub>2</sub> saturation in the right ventricle due to left-to-right shunting across the ventricular septal rupture shown on bedside Swan-Ganz catheterization would be pathognomonic.

**Diastolic murmurs**

Coronary blood flow is most rapid during diastole with significant peaking in presystole.<sup>15</sup> Coronary flow murmurs therefore ought to be diastolic in timing with the possibility of some early and late accentuation, a situation very analogous to aortic incompetence with presystolic Flint's murmurs.

Dock and Zonerach<sup>16</sup> documented a diastolic murmur of the above quality in a patient in cardiac failure secondary to hypertension and ventricular aneurysm formation (post-myocardial infarction). This murmur was sharply localized to the 3rd left intercostal space, high-pitched and only audible with the patient in the erect posture. It was ascribed to a stenosis of the LADA. This is in sharp contrast to the systolic murmur arising in a patent CABG to the same LADA described by Karpman.<sup>14</sup> Numerous authors, and more recently Scherf and Brooks,<sup>17</sup> detected diastolic murmurs in patients with proven left ventricular aneurysms. Therefore, patients subjected to bypass surgery with additional left ventricular aneurysm formation may be expected to exhibit such a murmur. Fearon *et al.*<sup>18</sup> explained this on the basis of enlargement of the aortic valve ring secondary to left ventricular dilatation, giving rise to aortic insufficiency. Lund-Larsen<sup>19</sup> reported the case of a 75-year-old woman with severe angina in whom a high-pitched short crescendo-long decrescendo diastolic murmur was audible at the 4th left intercostal space. Coronary angiography showed severe stenosis of the LADA, and some days later she suffered an acute anteroseptal myocardial infarction with concomitant disappearance of this murmur. Autopsy revealed an acute thrombotic occlusion on the coronary stenosis, strongly indicating that the diastolic murmur was due to the coronary narrowing. A similar case was reported by Fearon *et al.*<sup>18</sup> Thus, such a murmur could indicate progression of the disease in the native coronary arteries rather than possible CABG occlusion.

**Continuous murmurs**

The most important and certainly the most common cause of murmurs after bypass surgery documented in the literature is the inadvertent anastomosis of an aortosaphenous vein graft to the

TABLE III. IATROGENIC AVF: CHARACTERISTICS OF PUBLISHED CASES

Author	Age (yrs)	Sex	Angina before bypass	Infarction pre-op.	Angina after bypass	CABGs LADA, LCx, RCA	Continuous murmur post-op.	CABGs patent post-op.	Fistula LADV	Shunt*	Revision operation	Angina after revision operation
Vieweg <i>et al.</i> <sup>1</sup> (1975)	53	3M	Yes	Antero-lateral	No	LADA, LCx, RCA	2nd LICS	LCx, RCA	LADV	No	Yes	No
Lawrie <i>et al.</i> <sup>2</sup> (1976)	44	M	Yes	No	Yes	LADA	No ESM	—	LADV	Not sought	Yes	No
Treisman <i>et al.</i> <sup>3</sup> (1978)	55	M	Yes	Antero-lateral	No	LADA, RCA	3rd LICS	RCA	LADV	No	No	—
Stirling <i>et al.</i> <sup>4</sup> (1981)	47	M	Yes	Postero-lateral	No	LADA, LCx, RCA	2nd LICS	LCx, RCA	LADV	No	Yes	No
	66	M	Yes	Antero-septal	No	LADA, LCx, RCA	2nd LICS	LCx, RCA	LADV	No	No	—
Przybojewski (1982)	43	M	Yes	Antero-septal	Yes	LADA, 1st diag. branch of LADA	2nd LICS	1st diag. branch of LADA	LADV	Not sought	Yes	Yes

LCx = left circumflex coronary artery; LICS = left intercostal space; ESM = ejection systolic murmur. Shunt = as determined by oximetry or dye dilution curves.



LADV. To date, including the present case, there are 6 such cases known. This characteristic murmur was evident in 5 of the 6 cases documented (Table III). The remaining case had an ejection systolic murmur, characteristically high-pitched and maximally heard at the 2nd left intercostal space with slight radiation down the left sternal border towards the cardiac apex.<sup>2</sup> It also appears to be best heard with the patient sitting forward in mid-expiration. The possible existence of this murmur after bypass surgery, more specifically involving the LADA, particularly if the patient complains of angina and has new ischaemic changes on electrocardiography, must alert the attending physician to the possibility of an AVF. After corrective surgery the continuous murmur disappeared in 4 of the 6 patients, whereas it was still evident in the 1 remaining patient not subjected to operation.

Bauman and Tsagaris<sup>20</sup> were the first to describe the appearance of a continuous murmur after bypass surgery. The murmur was high-pitched and blowing in nature, commencing during mid-systole, attaining a maximum loudness at the 2nd heart sound and then continuing into the early part of diastole. Their patient had initially had a Vineberg operation for incapacitating angina pectoris. This was followed by saphenous CABGs to the RCA and LADA on account of continuing severe angina. After this a continuous murmur was maximally heard at the apex, and accentuated in the left lateral position. These authors suggested that the origin of this murmur was the distal anastomosis between the saphenous vein and LADA since the location of the murmur corresponded to that site. They went on further to speculate that the turbulent flow was related to the discrepancy in size between the coronary artery and saphenous vein, or due to possible retrograde filling of the severely occluded LADA by way of the CABG. They were less in favour of coronary artery narrowing as a cause.

Tabrah *et al.*<sup>21</sup> documented a unique cause of continuous murmur after bypass surgery; an iatrogenic fistula had formed between the LADA and the right ventricular cavity. This murmur was detected some 8 weeks after discharge, was pansystolic and soft, and spilled over into diastole whence it became higher in frequency. It was heard best at the mid-left sternal edge and was more audible with the patient sitting forward and holding his breath on inspiration. Coronary angiography demonstrated a patent LADA graft and the presence of a sac arising from the LADA. This sac then communicated with the right ventricular cavity via a maze of vessels which were possibly Thebesian veins. No demonstrable left-to-right shunt was noted on oximetry.

It would appear that the most significant murmur is that of the continuous variety. Generally speaking, this murmur is present almost immediately postoperatively and might signify the existence of a possible AVF, especially if the LADA has been grafted, until proved otherwise. Meticulous pre-operative auscultation is essential if such a complication is to be detected. On the other hand, a systolic murmur postoperatively is probably beneficial to the patient in that this most likely signifies a patent graft, especially if the LADA has been bypassed. As a rule, diastolic murmurs would suggest occlusion of a previously severely narrowed coronary artery or the appearance of a left ventricular aneurysm.

## Possible complications of AVFs

### Angina pectoris

The most fascinating symptom following the inadvertent insertion of an aortosaphenous vein into the LADV is angina pectoris, which occurred in both Lawrie *et al.*'s<sup>2</sup> patient and the present patient (Table III). The angina was debilitating and began within the first 2 weeks; both underwent revision operations when the AVF was corrected and both had virtually imme-

diately relief of angina. One could argue that perhaps both these patients could have undergone a 'Beck 2 operation'<sup>6-8</sup> with narrowing of the coronary sinus. However, re-implantation of the saphenous vein into the LADA seemed preferable since the 'Beck 2 operation' has a success rate of less than 40% and a mortality rate of 26.1%. The occurrence of angina was not unexpected since there was proven underlying atherosclerosis, for which the bypass had been performed initially. Therefore it may be that this symptom was due to progression of the underlying obstructive lesions, or that the arteriovenous shunting in some way precipitated ischaemia with resultant angina. Angina pectoris occurred in 38% of Liberthson *et al.*'s<sup>22</sup> 13 patients with congenital arteriovenous fistulas (CAVFs), but these patients were of an age when coronary atherosclerosis would be expected to be more frequent. Two of these 5 patients with angina had CAVF ligation alone with subsequent disappearance of this symptom. 'Coronary steal' may well be a contributory factor in iatrogenic AVF, but probably plays a more important role in CAVF.

### Acute myocardial infarction

Table III indicates that of the 6 patients with iatrogenic AVF in the literature, proven preceding myocardial infarction was present in 5. Two of these had previous anterolateral myocardial infarction, and 2 had anteroapical and the remaining 1 posterolateral myocardial infarction. However, in none of the 6 could a postoperative myocardial infarction be established. It is not inconceivable that the AVF could cause increased resistance to prograde flow through the already narrowed coronary artery by increasing retrograde pressure. The more likely cause of myocardial infarction would be a progression of obstructive coronary lesions. Long-term 'arteriolization' of the LADV could possibly lead to atherosclerotic involvement and obstruction, as has been known to occur in saphenous vein bypass grafts. This sequence of events could again lead to decrease in prograde flow via the diseased LADA with subsequent total occlusion and hence myocardial infarction.

Of the 6 patients with AVF reported, 3 had undergone triple coronary artery bypass (LADA, RCA and left circumflex coronary artery) suggesting extensive coronary atherosclerosis. Two further patients underwent double coronary artery bypasses (LADA and RCA; LADA and first diagonal branch). Only 1 of the 6 patients had a single CABG (LADA). Furthermore, all 3 patients undergoing triple bypass grafts had patent grafts to the RCA and left circumflex coronary at re-catheterization. One with a double bypass graft had a patent graft to the RCA. The present patient was unwilling to undergo cardiac catheterization after his second operation, but the first diagonal branch CABG was patent when he was catheterized after his first operation. It is not known whether the LADA revision bypass is patent some 4 years later, but the chance of this is high since there is no new ECG evidence of anterolateral myocardial infarction. Likewise, myocardial infarction is rare in patients with CAVF although angina is relatively common.<sup>22-24</sup> Nevertheless, this complication is an important consequence of ligation in older patients, in that it has been reported in some 7% of cases.

### Congestive cardiac failure

This complication was documented in 1 of the 6 patients,<sup>1</sup> this being in quite marked contrast to the clinical presentation of patients with CAVF.<sup>22</sup> In a series of 187 patients, congestive cardiac failure was detected in 6% of those under 20 years of age and in 19% over that age. The development of congestive cardiac failure seems directly related to the degree of left-to-right shunting producing a high output cardiac state, and is therefore unlikely to occur early after creation of an AVF.



## Bacterial endocarditis

The presence of an AVF produced rapid filling of the coronary sinus when visualized on angiocardiography. Hence, the haemodynamic characteristics of this iatrogenic AVF could be closely compared with a congenital coronary artery-coronary sinus fistula as documented by Kimbiris *et al.*<sup>25</sup> and Sabbagh *et al.*,<sup>26</sup> as well as other forms of AVF as described by McNamara and Gross.<sup>27</sup> Some 10% of cases have been complicated by the presence of bacterial endocarditis.<sup>27</sup> Similarly, this complication has been reported in 3% of cases with CAVF.<sup>22</sup> However, none of the 6 patients with AVF documented had the complication of bacterial endocarditis; a likely reason is that 4 have had revision operations, while the remaining 2 patients have not had enough time to develop a significant left-to-right shunt, probably the most important predisposing factor.

## Pulmonary hypertension

This possible complication has not been described in patients with AVF. Again, the reason for this is probably inadequate time to develop sufficient left-to-right shunting in the 2 patients who did not undergo a revision procedure. Nevertheless, this complication must be exceptionally rare. Only 1 case of moderate pulmonary hypertension has been encountered, this in a patient with a CAVF.<sup>27</sup>

## Haemopericardium

This complication has been rarely documented in patients with congenital coronary artery-coronary sinus fistula.<sup>25,28</sup> A case of fatal haemopericardium was reported by Habermann *et al.*<sup>29</sup> but this potential complication has not been seen in any patient with an iatrogenic AVF.

## Prevention of AVFs

It can be seen from Table III that in all of the 6 cases of AVF in the literature, mistaking the LADV or anterior interventricular cardiac vein for the LADA was involved. The surgeon involved was aware of the difficulty in isolating and dissecting out the LADA on account of there being much overlying epicardial adipose tissue or scar tissue from previous cardiac surgery, as well as the fact that this vessel lies deep, especially near its origin from the ascending aorta.

Cardioplegic solution is employed in standard bypass surgery. Thus, when both the LADA and the LADV are perfused with colourless cardioplegic fluid, the advantage of arterial colour differentiation is lost. In addition, this fluid and cross-clamping of the aorta tend to collapse both the LADA and the LADV, especially the former, making for differentiation by palpation almost impossible. The coronary arteries are usually diseased and thicker than the corresponding coronary vein, but the latter may occasionally be quite thick and firm, secondary to sclerosis.

Lawrie *et al.*<sup>2</sup> recommend that the suspected LADA should be meticulously assessed during and after the arteriotomy. Soon after arteriotomy bright red blood should be visualized after temporarily releasing the aortic cross-clamp. A probe should be inserted within the presumed LADA and advanced both proximally as far as the atherosclerotic lesion (often palpable) and distally as far as it will traverse. The LADA is usually more easily identified near the apex from where a probe can be inserted and then passed both distally and proximally. If the epicardial fat layer should happen to be very thick, a diagonal branch of the LADA can be isolated on the lateral aspect of the heart and followed proximally towards its origin from the LADA.

In an attempt to avoid creation of an AVF, Starling *et al.*<sup>4</sup> have suggested localizing the LADA that is to be involved in the

CABG anastomosis while actually beginning the systemic cooling process and before the infusion of cardioplegic solution. These surgeons also insert a Prolene 6-0 suture alongside the LADA which is subsequently used as a guide to its position so that the cardioplegic solution may be infused without causing confusion in differentiating the LADA from the LADV. In addition, Starling *et al.*<sup>4</sup> constantly infuse cardioplegic solution into the aorta and so fill the coronary arteries before arteriotomy. Following incision of the presumed LADA the anterograde flow is inspected and then the cardioplegic solution infusion is temporarily discontinued.

All these variations in the standard accepted technique may serve to minimize the very real chance of incorrectly anastomosing aortosaphenous vein grafts to coronary veins, especially with respect to the LADA.

## Therapeutic and management guidelines

It would seem logical that if the presence of an iatrogenic AVF is established a revision operation should be undertaken. Although possible complications such as acute myocardial infarction, bacterial endocarditis, pulmonary hypertension and haemopericardium have not been encountered in the 6 cases documented in the literature, experience with congenital coronary artery-coronary sinus fistulas would suggest the need for correction. Angina pectoris following initial bypass surgery is certainly an indication for closure of the AVF, as in our case and in that of Lawrie *et al.*<sup>2</sup> Both of these patients were angina-free after corrective surgery, proving the necessity for such an operation. Congestive cardiac failure is another indication for surgery, as in the case of Vieweg *et al.*<sup>1</sup>

Treistman *et al.*<sup>3</sup> were of the opinion that revision surgery should not be undertaken if the patient is asymptomatic and if a postoperative exercise test is more satisfactory than one performed before the initial operation. Their reason was that they believed that the place of aortocoronary vein anastomosis in the management of patients with diffuse distal coronary disease was not clearly established and that in fact this anastomosis might have been beneficial, as opposed to the standard bypass procedure. This view was also expressed by Starling *et al.*,<sup>4</sup> who ligated the AVF in one of their patients because of angina, but only observed the other patient who was asymptomatic and whose thallium treadmill stress test was negative.

In conclusion, because so few cases of iatrogenic AVF have been documented and because of the relatively short follow-up period in those 2 patients not subjected to revision operations, treatment of the asymptomatic patient remains controversial. However, there seems little doubt that corrective surgery in those cases with symptoms, especially angina pectoris, is effective.

I wish to sincerely thank Miss H. Weymar of the Cardiac Clinic, Tygerberg Hospital, for her continued assistance with and interest in the preparation of my publication. Thanks are also due to Mr Chris Wilberforce, Chief of the Department of Photography of University of Stellenbosch Medical School, for the photography. Finally, I wish to thank Dr C. Vivier, Chief Medical Superintendent of Tygerberg Hospital, for permission to publish.

## REFERENCES

1. Vieweg WVR, Folkherth TL, Hagan AD. Saphenous vein graft from aorta to coronary vein with production of continuous murmur: a complication of coronary artery bypass surgery. *Chest* 1975; **68**: 377-379.
2. Lawrie GM, Morris GC, Winters WL. Aortocoronary saphenous vein autograft accidentally attached to a coronary vein: follow-up angiography and surgical correction of the resultant arteriovenous fistula. *Ann Thorac Surg* 1976; **22**: 87-90.
3. Treistman B, Sulbaran TA, Cooley DA. Saphenous vein bypass from the aorta to the anterior interventricular vein. *Ann Thorac Surg* 1978; **26**: 383-386.



4. Starling MR, Groves BM, Frost D, Toon R, Arom KV. Aorto-coronary vein fistula: a complication of coronary artery bypass graft surgery. *Chest* 1981; **79**: 64-68.
5. Effler DB, Favaloro RG, Groves LK. Coronary artery bypass utilising saphenous vein grafts: clinical experience with 224 operations. *J Thorac Cardiovasc Surg* 1969; **58**: 178-185.
6. Beck CS, Stanton DE, Batiuchok W, Leiter E. Revascularization of heart by graft of systemic artery into coronary sinus. *JAMA* 1948; **137**: 436-442.
7. Beck CS, Leighninger DS. Operations for coronary artery disease. *JAMA* 1954; **156**: 1226-1233.
8. Beck CS, Leighninger DS. Scientific basis for the surgical treatment of coronary artery disease. *JAMA* 1955; **159**: 1264-1271.
9. Bhayana JN, Olsen DB, Byrne JP, Kolff WJ. Reversal of myocardial ischaemia by arterialization of the coronary vein. *J Thorac Cardiovasc Surg* 1974; **67**: 125-132.
10. Gardner RS, Magovern GJ, Park SB, Dixon CM. Arterialization of coronary veins in the treatment of myocardial ischaemia. *J Thorac Cardiovasc Surg* 1974; **68**: 273-282.
11. Chiu CJ, Mulder DS. Selective arterialization of coronary veins for diffuse coronary occlusion: an experimental evaluation. *J Thorac Cardiovasc Surg* 1975; **70**: 177-182.
12. Eckstein RW, Hornberger JC, Sano T. Acute effects of elevation of coronary sinus pressure. *Circulation* 1953; **7**: 422-436.
13. Park SB, Magovern GJ, Liebler GA *et al*. Direct selective myocardial revascularization by internal mammary artery-coronary vein anastomosis. *J Thorac Cardiovasc Surg* 1975; **69**: 63-72.
14. Karpman L. The murmur of aortocoronary bypass. *Am Heart J* 1972; **83**: 179-181.
15. Anrep GV, Cruikshank EWH, Downing AC, Rau AS. The coronary circulation in relation to the cardiac cycle. *Heart* 1927; **14**: 111-124.
16. Dock W, Zonerach S. A diastolic murmur arising in a stenosed coronary artery. *Am J Med* 1967; **42**: 617-619.
17. Scherf D, Brooks AM. The murmurs of cardiac aneurysm. *Am J Med Sci* 1949; **218**: 389-398.
18. Fearon RE, Cohen LS, O'Hara JM, Goodyer AVN. Diastolic murmurs due to two sequelae of atherosclerotic coronary artery disease: ventricular aneurysm and coronary artery stenosis. *Am Heart J* 1968; **76**: 252-258.
19. Lund-Larsen PG. Coronary artery stenosis murmur: a case report. *Acta Med Scand* 1967; **182**: 433-435.
20. Bauman DJ, Tsagaris TJ. Continuous heart murmur following aortocoronary bypass surgery. *Chest* 1973; **64**: 269-270.
21. Tabrah F, Aintablian A, Hamby RI. Coronary arteriovenous fistula complicating aortocoronary bypass surgery. *Am Heart J* 1973; **85**: 534-537.
22. Liberthson RR, Sagar K, Berkoben JP, Weintraub RM, Levine FH. Congenital coronary arteriovenous fistula: report of 13 patients, review of the literature and delineation of management. *Circulation* 1979; **59**: 849-854.
23. Bishop JO, Mathur VS, Guinn GA. Congenital coronary artery fistula with infarction. *Chest* 1974; **65**: 233-234.
24. Morgan JR, Forker AD, O'Sullivan MJ, Fosburg RG. Coronary arterial fistulas. *Am J Cardiol* 1972; **30**: 432-436.
25. Kimbiris D, Dasparian H, Knibbe P, Brest AN. Coronary artery-coronary sinus fistula. *Am J Cardiol* 1970; **26**: 532-539.
26. Sabbagh AH, Schocket LI, Griffin T *et al*. Congenital coronary artery fistula. *J Thorac Cardiovasc Surg* 1973; **66**: 794-798.
27. McNamara JJ, Gross RE. Coronary artery fistula. *Surgery* 1969; **65**: 59-66.
28. Jaffe RB, Glancy DL, Epstein SE, Brown BG, Morrow AF. Coronary artery right heart fistulae: long-term observation in seven patients. *Circulation* 1973; **47**: 133-143.
29. Habermann JH, Howard ML, Johnson ES. Rupture of the coronary sinus with haemopericardium. *Circulation* 1963; **28**: 1143-1144.