

Hyperkalaemic complete heart block

A report of 2 unique cases and a review of the literature

J. Z. PRZYBOJEWSKI, C. J. KNOTT-CRAIG

Summary

Two White male patients with temporary complete heart block (CHB) secondary to hyperkalaemia are presented. One, a 40-year-old man, developed CHB with ensuing shock within the first 24 hours of repeat aortic valve replacement for a paraprosthetic leak caused by previous endocarditis. This patient experienced iatrogenic hyperkalaemia. The second was an 81-year-old man who had chronic renal failure and presented with Stokes-Adams attacks. This patient was initially thought to have degenerative CHB and nearly underwent inadvertent permanent pacemaker insertion. Both patients were initially treated with emergency temporary cardiac pacing with subsequent successful management.

Temporary CHB secondary to hyperkalaemia, from whatever cause, has very rarely been documented in the literature. A review of this potentially lethal complication is undertaken and the significance of unifascicular and bifascicular conduction block as a consequence of hyperkalaemia is discussed.

S Afr Med J 1983; 63: 413-420.

An elevated serum potassium level has been traditionally accepted as life-threatening. The recognition of hyperkalaemia on the ECG is therefore of the utmost importance, since therapeutic measures may well have to be applied while awaiting the results of serum potassium estimation.

The classic electrocardiographic changes resulting from increasing hyperkalaemia have been well documented. Perhaps the earliest clue is the appearance of peaked, 'tent-shaped' and narrow-based T waves.¹ This is usually succeeded by P-wave flattening and widening, as well as PR-interval lengthening. ST-segment depression and occasionally elevation may occur. With a further rise in serum potassium levels the P waves disappear and the R-wave height decreases progressively. Widening of the QRS complex (intraventricular block) then occurs and is usually followed by ventricular tachycardia, fibrillation and eventual ventricular standstill.

Less well-recognized electrocardiographic manifestations of hyperkalaemia have been reported less frequently, but abnormal left axis deviation,² right axis shift,² pseudo-myocardial infarction pattern³⁻⁵ and bifascicular blocks (in varying combinations)^{3,6-9} have been known to occur.

Cardiac Unit, Departments of Internal Medicine and Cardiothoracic Surgery, Tygerberg Hospital and University of Stellenbosch, Parowvallei, CP

J. Z. PRZYBOJEWSKI, M.B. CH.B., F.C.P. (S.A.)

C. J. KNOTT-CRAIG, M.B. CH.B.

Complete heart block (CHB) appears to be the most unusual complication of severe hyperkalaemia⁹⁻¹² (Table I).

A total of 3 cases of temporary hyperkalaemic CHB have been reported to date, excluding the 2 cases now documented.⁹⁻¹¹ Bashour *et al.*'s⁹ patient (Table I) died suddenly as a direct result of the conduction defect. The case of CHB documented by Bharati *et al.*¹² was considered to be due to systemic lupus erythematosus as the CHB was still present after normalization of the hyperkalaemia. It is interesting to note that CHB can be uniformly produced with increasing potassium infusion in experimental animals, as opposed to its rare occurrence in spontaneous clinical hyperkalaemia. This peculiarity may be due to the effect of acid-base balance disturbance, as well as abnormality of other serum electrolytes in the clinical setting. Furthermore, the rapidity of serum potassium elevation appears to be crucial in determining the manifestation on the ECG; the more rapid the rate of rise the more likely the appearance of high-degree atrioventricular block and CHB.

The 2 patients to be described both developed indisputable CHB which was directly related to the onset of significant hyperkalaemia. Both received emergency treatment, including temporary cardiac pacing, and the CHB disappeared with the restoration of the serum potassium level to normal.

Case reports

Case 1

The patient was an 81-year-old retired White farmer who had undergone a prostatectomy 1 year previously. At the same time intravenous pyelography had been performed which demonstrated bilateral decreased renal function. At that stage investigation showed the serum potassium level to be 5,0 mmol/l (normal 3,5 - 5,3 mmol/l), serum sodium 137 mmol/l (normal 136 - 145 mmol/l), serum chloride 106 mmol/l (normal 100 - 106 mmol/l), and blood urea 22,5 mmol/l (normal 3,3 - 6,5 mmol/l). A diagnosis of chronic renal failure, hypertension, ischaemic heart disease and diffuse obstructive pulmonary disease was made and the patient was treated conservatively. A resting ECG at this stage (September 1980) showed sinus rhythm at 79/min, a mean QRS axis of -86° , left anterior hemiblock (LAHB), a PR interval of 0,17 second, a QTc of 0,45 second, complete right bundle-branch block (RBBB) and a probable old transmural inferior myocardial infarction (Fig. 1a). He was subsequently followed up in the medical outpatient department at Tygerberg Hospital and was essentially asymptomatic. More specifically there was no history of dyspnoea, angina, palpitations, dizziness or oedema.

On the morning of 8 January 1982 his general practitioner was called to his home because of a history of sudden onset of loss of consciousness associated with profuse sweating. He had apparently stood up from sitting at table, become dizzy and lost consciousness. When examined at home his radial pulse was noted to be regular but very slow at 32/min. Because of this finding he was immediately given atropine 0,6 mg intravenously which, according to the general practitioner's referral note, caused the pulse rate to rise to 80/min.

The patient was immediately transferred to the Intensive Coronary Care Unit (ICCU) at Tygerberg Hospital, some 2

TABLE I. HYPERKALAEMIC CHB IN 5 PATIENTS

Authors	Age	Sex	Diagnosis	ECG before CHB				During CHB				After treatment of CHB				Main symptom during CHB	Final outcome		
				K ⁺ before CHB	Rhythm rate	P-R (ms)	QRS (ms)	Intra-V conduct	K ⁺	QRS (ms)	Rhythm rate	P-R (ms)	QRS (ms)	Intra-V conduct	K ⁺			Rhythm rate	P-R (ms)
Bashour <i>et al.</i> ⁹	33 F		Acute/chronic renal failure	?	?	?	?	Unknown	8,2	180	4,7	?	?	?	?	?	?	Shock	Died
Ohmae and Rabkin ¹⁰	96 M		Chronic renal failure	?	AF	?	?	LAHB	9,0	240	?	?	AF	?	120	RBBB		Unknown	Survived
Grenadier <i>et al.</i> ¹¹	74 F		Toxic thyroid adenoma	?	?	?	?	Unknown	8,3	100	4,5	?	SR 65	180	80	LAHB Mobitz II + 2° AVB		Shock, syncope	Survived
Przybojewski and Knott-Craig (1982)	81 M		Chronic renal failure	5,0	SR 79	170	140	LAHB & RBBB	8,3	140	5,4	?	AF 100	—	140	LAHB + RBBB		Stokes-Adams attacks	Survived
Case 2	40 M		Idiopathic post-AVR	4,2	SR 110	160	80	Normal	8,4	160	4,5	?	SR 79	160	90	Normal		Shock	Survived

CHB = complete heart block; SR = sinus rhythm; AF = atrial fibrillation; LAHB = left anterior hemiblock; RBBB = right bundle-branch block; AVR = aortic valve replacement; F = female; M = male; K⁺ = serum potassium (mmol/l); 2° AVB = second-degree atrioventricular block; V = ventricular.

hours after his syncopal episode. On admission he was apyrexial, somewhat pale and slightly confused. The radial pulse was regular at 22/min and all peripheral pulses were normal. His blood pressure was 100/60 mmHg; there was no clinical cardiomegaly or any evidence of cardiac failure. Features of moderately severe chronic obstructive lung disease were noted. No lateralizing signs could be found on examination of the central nervous system. Side-room investigations demonstrated a haemoglobin value of 10 g/dl, a white blood cell count of 7,3 x 10⁹/l and a slightly elevated ESR of 35 mm/1st h (Westergren). There was also 2+ proteinuria and haematuria.

A resting ECG (Fig. 1b) revealed CHB with an idioventricular rate of approximately 20/min probably arising from the left ventricle. The mean QRS axis was -86° and there was evidence of a possible previous transmural inferior myocardial infarction.

At this stage the clinical presentation was assessed as third-degree heart block (probably secondary to degenerative conduction disease) giving rise to a single Stokes-Adams attack in a patient in chronic renal failure. An isoprenaline infusion was immediately set up and a temporary right ventricular cardiac pacemaker bipolar electrode was inserted percutaneously via the left subclavian vein and connected to a demand pacemaker set at a rate of 70/min. Provisional plans were made to insert a permanent cardiac pacemaker as it was considered that the patient's Stokes-Adams attack was due to irreversible CHB.

Serum electrolytes were estimated at once. The serum potassium result was quite startling in that it was markedly elevated at 8,3 mmol/l, the serum sodium and chloride levels being within normal limits. The serum potassium estimation was repeated and treatment begun in the meantime with intravenous insulin/50% dextrose, sodium bicarbonate 4,2% and calcium gluconate. In addition, the cation exchange resin Kayexalate (sodium polystyrene sulphonate) in a dose of 15 g 6-hourly was administered. The second serum sample again had a potassium level of 8,3 mmol/l. The blood urea level was elevated to 27,6 mmol/l and the serum creatinine level to 681 μmol/l (normal 60 - 120 μmol/l). The ionized calcium level was low at 1,86 mmol/l (normal 2,1 - 2,6 mmol/l) and the inorganic phosphate level high at 1,73 mmol/l (normal 0,8 - 1,4 mmol/l) in keeping with his chronic renal disease.

A chest radiograph showed left ventricular enlargement, some pulmonary congestion and a right-sided pleural effusion.

The patient was carefully monitored with the temporary pacemaker functioning and there was significant improvement in blood pressure, peripheral perfusion and mental state. Within 24 hours the serum potassium level had fallen to 5,4 mmol/l. The temporary demand-mode pacemaker would be intermittently inhibited by the patient's own heartbeat at 60 - 70/min. A repeat ECG on 9 January 1982, with the temporary pacemaker switched off, showed sinus rhythm of 68/min, PR interval 0,17 second, mean QRS axis -88°, QTc 0,47 second, complete RBBB, LAHB, numerous unifocal supraventricular ectopic beats and an old transmural inferior myocardial infarction (Fig. 1c). The pacemaker (Fig. 1d) was left on at a rate of 60/min over the next 4 days, during which time the patient continued to take oral Kayexalate. Numerous serum potassium estimations were within the normal range, apart from a level of 3,0 mmol/l on 13 January 1982. Kayexalate was discontinued and betaine HCl begun orally until the level rose to normal within 2 days, when it was stopped.

The temporary pacemaker was removed on 18 January after 11 days, and the patient transferred to the medical wards in sinus rhythm, with the serum potassium level at 4,3 mmol/l. Sonar examination demonstrated small kidneys in the absence of hydronephrosis. The patient was discharged on the following day on aluminium hydroxide, calcium and a small dose of Kayexalate. A resting ECG on discharge (Fig. 2a) revealed sinus rhythm of 79/min, a PR interval of 0,16 second, a mean QRS axis of -79°, a QTc of 0,44 second, LAHB and complete RBBB.

On 29 January 1982, 11 days after discharge, he was again referred by his general practitioner because of the onset of severe ankle oedema and orthopnoea. He was given intravenous furosemide with little response. Digoxin was withheld in view of the

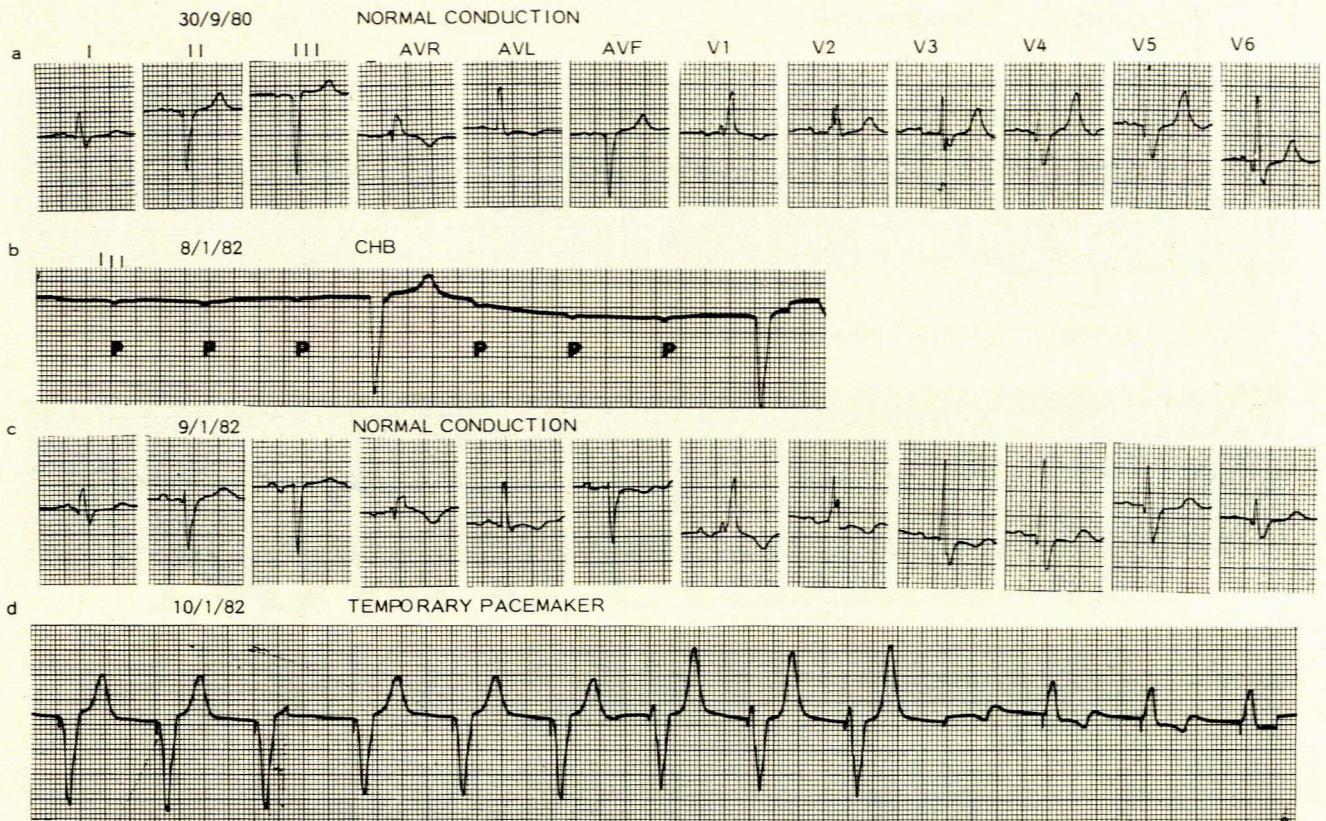


Fig. 1. a — standard 12-lead ECG showing LAHB and complete RBBB; b — standard lead III showing CHB and atrial activity (P waves); c — LAHB and complete RBBB again evident; d — regular right ventricular paced rhythm.

chronic renal failure and recent history of CHB. The patient was again admitted to the medical ward at which time a resting ECG (Fig. 2b) showed atrial fibrillation with a ventricular response of 100/min, mean QRS axis -80° , LAHB and complete RBBB; this was the first time that atrial fibrillation had ever been noted. The serum potassium level was normal at 5,1 mmol/l as were serum sodium and chloride, but the blood urea was still elevated at 26,6 mmol/l. He was given more diuretic therapy with satisfactory effect and discharged after a short stay.

The patient was last seen on 17 March 1982 at which time he was relatively asymptomatic, normotensive and not in cardiac failure. His serum potassium value was normal. A repeat ECG (Fig. 2c) showed atrial fibrillation with a rapid ventricular response of 100/min, a QRS axis of -78° , a QTc interval of 0,55 second, LAHB and complete RBBB.

Case 2

The patient was a 40-year-old White man who had had a Starr-Edwards aortic valve prosthesis inserted in 1971 for luetic aortic insufficiency. He was asymptomatic until 1980 when he was admitted with infective endocarditis successfully treated with penicillin and streptomycin. He was discharged on warfarin. Some 3 months before his latest admission he noted the onset of cough, sweating, palpitations, increasing dyspnoea on exertion, orthopnoea and paroxysmal cardiac dyspnoea. He was then admitted to Paarl Hospital on 16 February 1982 in moderately severe congestive cardiac failure. At that time he was thought to have an aortic paraprosthesis leak as well as possible mitral stenosis and insufficiency. Infective endocarditis was excluded and he was treated with digoxin and diuretics, as well as verapamil for supraventricular tachycardia.

The patient was admitted to Tygerberg Hospital on 27 February 1982, with a regular radial pulse of 90/min and 5 - 8

ventricular extrasystoles per minute. The blood pressure was 130/60 mmHg. All peripheral pulses were present and the jugular venous pressure was elevated at 6 cm H₂O. Significant biventricular cardiomegaly was noted as well as moderately severe biventricular cardiac failure. Auscultation confirmed the presence of a paraprosthesis leak of the prosthesis with well-heard opening and closing clicks. A loud Austin-Flint murmur was audible over the mitral area. A chest radiograph showed left ventricular enlargement, interstitial pulmonary oedema and a moderate right-sided pleural effusion. The resting ECG (Fig. 3a) revealed sinus tachycardia of 110/min, a PR interval of 0,16 second, a mean QRS axis of $+10^\circ$, and left ventricular and left atrial hypertrophy. The serum sodium level was 133 mmol/l, potassium 5,1 mmol/l and chloride 106 mmol/l. Other routine laboratory investigations were all within normal limits. An M-mode echocardiogram showed a normal mitral valve with enlargement of the left atrium and ventricle with moderately good function. No obvious vegetations could be seen.

On 1 March 1982 the patient was subjected to cardiac surgery. This demonstrated a paraprosthesis leak which extended through some 50% of the circumference of the Starr-Edwards aortic prosthetic ring. A No. 25 Björk-Shiley aortic prosthesis was inserted. The mitral valve was found to be free of disease and the operation was completed without complication. On returning from theatre the serum electrolyte values were as follows: sodium 137 mmol/l, potassium 4,2 mmol/l, chloride 109 mmol/l. Over the following 12 hours these values remained much the same, with only the serum potassium creeping up to 5,6 mmol/l. During this period the patient was infused with blood (100 ml/h) and a 'cocktail solution' (20 ml/h), the latter containing insulin, dextrose, magnesium, calcium and 40 mmol potassium chloride in a litre of Maintelyte — a standard solution for postoperative open-heart patients. During this period the ECG showed sinus tachycardia 115/min, PR interval 0,08 second, mean QRS axis

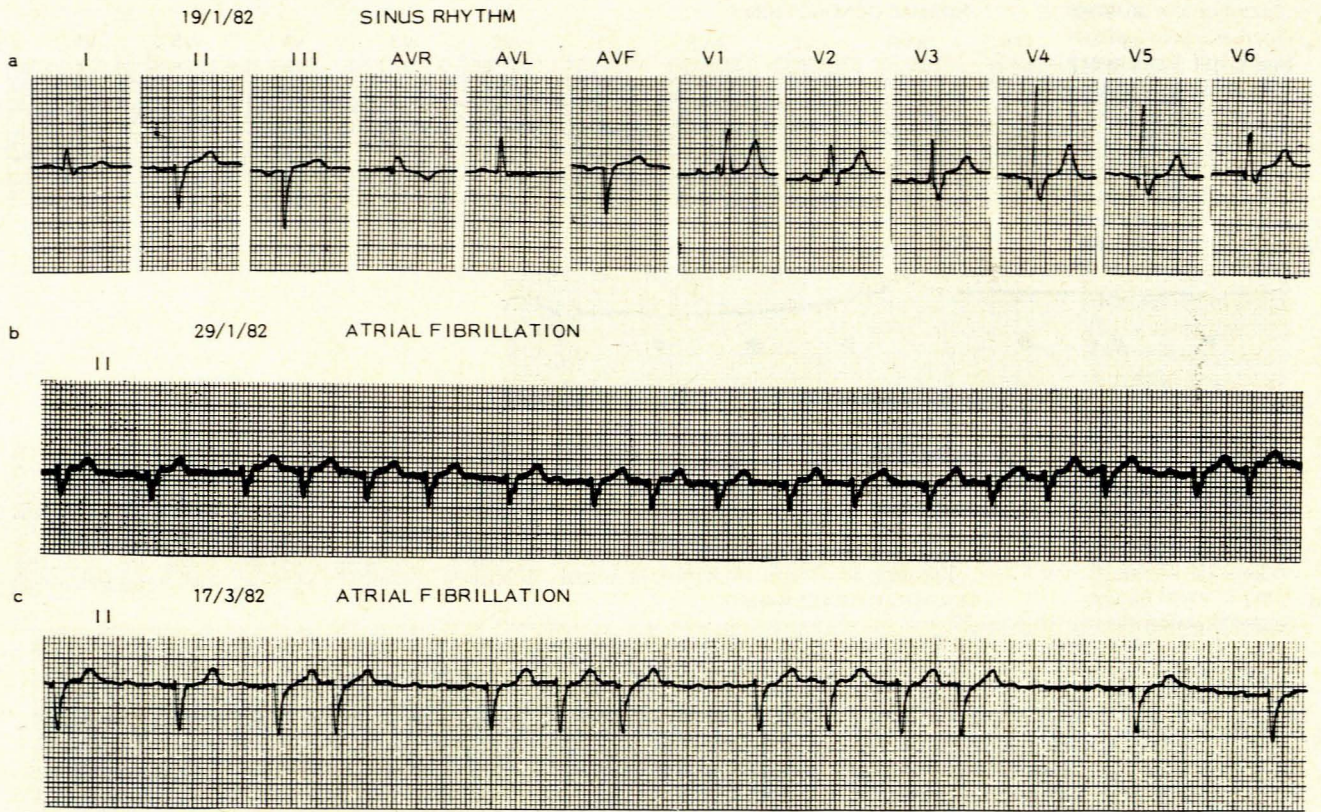


Fig. 2. a — LAHB and complete RBBB; b — standard lead II showing atrial fibrillation with rapid ventricular response; c — standard lead II showing atrial fibrillation with slower ventricular response.

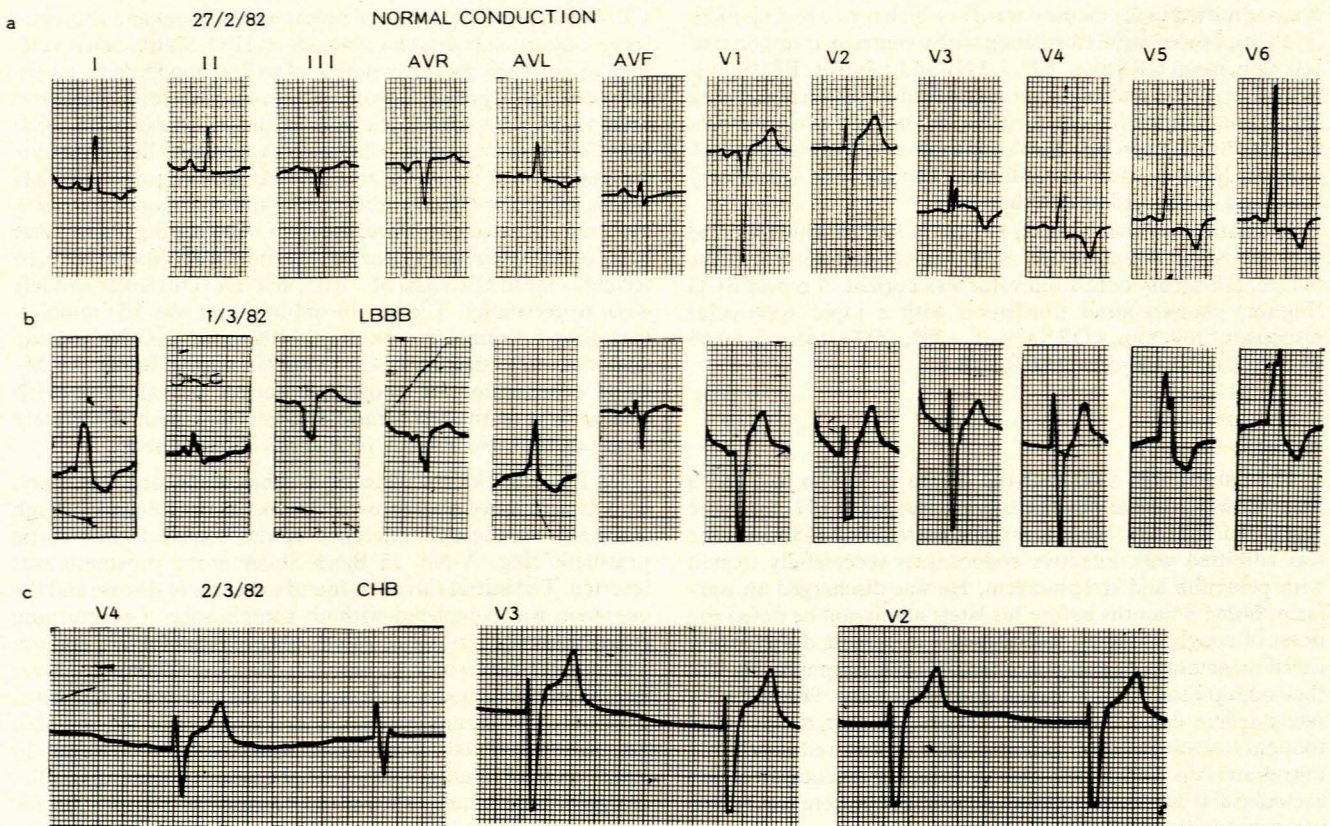


Fig. 3. a — standard 12-lead ECG showing left ventricular and left atrial hypertrophy; b — complete LBBB visualized for the first time; c — leads V2, V3, V4 showing CHB with idioventricular rate of 38/min.

+5° and complete left bundle-branch block (LBBB) (Fig. 3b). The LBBB was noted for the first time and considered to be related to the aortic valve surgery. Numerous unifocal ventricular extrasystoles were also noted, for which lignocaine was administered.

The patient was extubated the following morning and digoxin and bumetanide KCl were recommenced. His urine output had decreased quite markedly and although blood gas values were normal, the serum potassium level was now 7.5 mmol/l. Despite intravenous boluses of soluble insulin and 50% dextrose as well as calcium gluconate and 4.2% sodium bicarbonate, the potassium level rose to 8.4 mmol/l over the next 3 hours. Very soon afterwards the patient collapsed, with a blood pressure of 80/50 mmHg, a pulse rate of 38/min, total heart block and central venous pressure of 25 cm H₂O. The ECG (Fig. 3c) revealed CHB with an idioventricular rate of 38/min (arising from the right ventricle), a QTc of 0.38 second and a mean QRS axis of -15°. The temporary demand pacemaker which had been connected to the epicardial pacing electrodes (inserted prophylactically at the time of surgery) set at 60/min was switched on but failed to 'capture'. This was corrected by increasing the output with subsequent successful 'capture' taking place at a rate of 80/min. An infusion of dobutamine HCl was commenced at 7.5 µg/kg/min and a 40 mg bolus of furosemide was administered. The frequent multifocal ventricular premature beats were subsequently treated successfully with a lignocaine bolus and infusion at 1 mg/kg/h. With the temporary cardiac pacing the patient's condition improved quite dramatically. The serum potassium level was again elevated at 7.6 mmol/l and the patient was given further insulin/dextrose and calcium gluconate intravenously. Within 3 hours the serum potassium level dropped to 5.6 mmol/l and a repeat ECG (Fig. 4a), with the temporary pacemaker switched off, showed a sinus rhythm of 90/min, a PR interval of 0.15 second, a mean QRS axis of -14°, a QTc of 0.42 second, left ventricular hypertrophy and anterolateral T-wave inversion. It is important to note that complete LBBB was no longer present.

On the following day, 3 March, serum potassium levels ranged between 4.5 and 5.0 mmol/l. A resting ECG (Fig. 4b) now

showed sinus rhythm of 72/min, PR interval 0.13 second, mean QRS axis 0°, and some anteroseptal subepicardial damage and left ventricular hypertrophy with strain. The patient continued to make a good recovery until 5 March, when the sudden onset of rapid atrial fibrillation was noted. He was then given intravenous verapamil with resulting sinus tachycardia which did not respond to intravenous propranolol. Digoxin was discontinued as the possibility of toxicity was considered. However, the serum digoxin level was estimated to be 0.5 ng/dl (below the therapeutic level, which is 1-2 ng/dl) and the serum potassium level was 4.5 mmol/l. The dosage was adjusted and quinidine was added until sinus rhythm was re-established on 7 March. An ECG now showed sinus rhythm at 100/min, PR interval 0.14 second, mean QRS axis -20° and left ventricular hypertrophy with strain pattern (Fig. 4c). Quinidine gluconate was continued, as was the digoxin. The patient was discharged on 12 March 1982 with a normal serum potassium level.

Discussion

Basic electrophathophysiology

The normal serum potassium value is in the range of 3.5-5.3 mmol/l and is finely regulated by the body provided there is no significant renal disease. The effect of raising the extracellular potassium is to lower the resting membrane potential and shorten the action potential duration in all cardiac tissue.¹³ A reduction of upstroke velocity follows the former and gives rise to decreased conduction between adjacent cardiac cells. Thus, in the presence of moderate hyperkalaemia (6-7 mmol/l) both the PR and the QT intervals shorten, with classic 'tented' T waves. With increasing hyperkalaemia (8-9 mmol/l) progressive depression of conduction ensues. Usually the atrial myocardial cells are most sensitive to hyperkalaemia, followed by the ventricular myocardium and conduction fibres of the sino-atrial node and the bundle of His. Since the atrial muscle is particularly sensitive the P waves become less prominent and the PR interval lengthens. This is then followed by disappearance of the P waves,

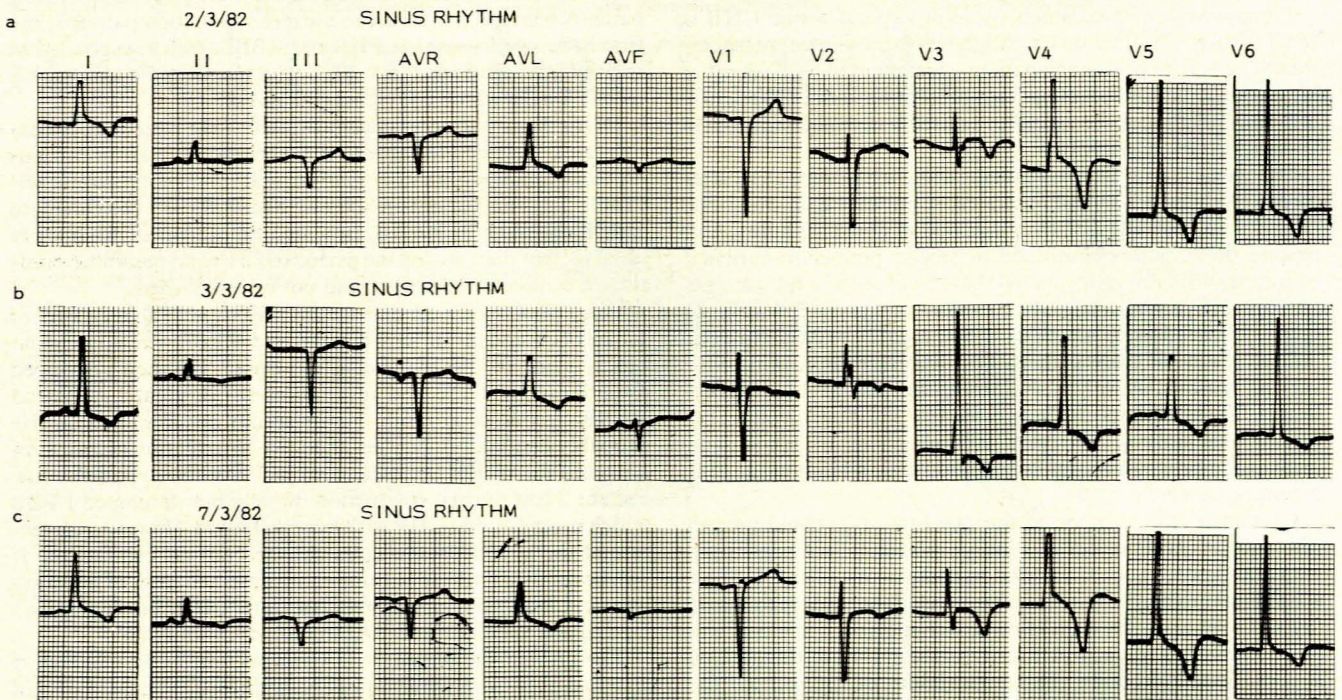


Fig. 4. a — standard 12-lead ECG showing left ventricular hypertrophy with 'strain', complete LBBB no longer evident; b — anteroseptal subepicardial damage with left ventricular hypertrophy and 'strain' pattern; c — 12-lead ECG on discharge showing normal conduction.

with subsequent 'sinoventricular' conduction, although conduction within the atria can be detected by intracardiac electrocardiography.

Fisch¹³ states that a true RBBB or, less frequently, LBBB, does not occur. He claims that as there is an extensive uniform inhibition of the intraventricular conduction system pseudo-RBBB and pseudo-LBBB patterns are encountered. In the former the initial phase of the QRS is also prolonged, and in the latter the terminal QRS width is increased. However, there is indisputable evidence that true RBBB and LBBB (as well as left anterior and left posterior hemiblock) do occur secondary to hyperkalaemia (see below).

When the serum potassium level rises further (9 - 10 mmol/l) QRS widening and QT-interval prolongation ensue, together with depression of sino-atrial, atrioventricular and intraventricular conduction inducing the appearance of escape beats and rhythms.¹⁴ Thus, slow idioventricular rhythm occurs in the presence of CHB. Progressive increase in the serum potassium level (> 10 mmol/l) gives rise to ventricular fibrillation or ventricular asystole.

It is important to note that the rate of serum potassium rise (i.e. the rate of exogenous administration in iatrogenic cases, case 2) determines the form of arrhythmia and conduction abnormality;¹⁵ rapid elevation gives rise to bradycardia and diminished myocardial contractility and is often accompanied by ventricular fibrillation; gradual elevation causes mainly conduction slowing with terminal asystole. Furthermore, the electrocardiographic features of hyperkalaemia can be lessened or even normalized by raising the serum calcium and sodium concentrations and vice versa.¹⁶

Fisch *et al.*¹⁷ demonstrated in dogs that the classic concept of absolute regularity of the ventricular activity might not be a prerequisite for the diagnosis of CHB in hyperkalaemia. They also showed that hyperkalaemia often produces CHB when P waves are still in evidence on the ECG. This latter feature was well demonstrated in our case 2.

Clinical setting

Perhaps the most common cause of hyperkalaemic CHB is renal failure. This fact was highlighted by the clinical presentation of case 1, as well as the patients documented by Bashour *et al.*⁹ Approximately 70% of patients presenting with unifascicular or bifascicular block secondary to a raised serum potassium level had underlying renal failure.

Iatrogenic hyperkalaemia causing acute temporary CHB after cardiac surgery is well demonstrated by our case 2, in which the patient had been oliguric over a period of about 12 hours, and despite these factors continued to receive potassium-enriched infusions. Williams *et al.*¹⁸ noted that 17 out of 150 adult patients developed hyperkalaemia after cardiac surgery (16 within 24 hours of operation) in which cardiopulmonary bypass had been utilized. Some of these patients had decreased urine output for varying reasons, as well as acidosis at the time of the hyperkalaemia. These authors also suggested that multiple blood transfusions, haemolysis, extravascular collections of blood, and inadvertent potassium supplementation were all important contributory factors.

Grenadier *et al.*¹¹ reported the case of a 74-year-old woman who had several episodes of syncope 1 week before presenting with circulatory shock, CHB and hyperkalaemia (Table I). This was thought to be due to acute thyrotoxicosis secondary to a toxic thyroid adenoma. On admission severe metabolic acidosis was present, and this was accepted as the cause of the life-threatening hyperkalaemia although the responsibility of digoxin for the CHB could not be excluded and nor could coronary vasospasm, described once before in the setting of acute thyrotoxicosis.¹⁹ Furthermore, CHB has been documented in acute thyrotoxicosis *per se*.^{20,21} The patient was treated with emergency tem-

porary transvenous right ventricular pacing for 4 hours and went back into normal conduction following attainment of the euthyroid state. It is fascinating to note that the serum potassium returned to normal without any specific therapy apart from correction of the metabolic acidosis. This patient therefore differed quite remarkably from the other patients with hyperkalaemic CHB. Mobitz type II second-degree atrioventricular block also ensued for a few days, but there was no recurrence of CHB with haemodynamic deterioration.

Other clinical settings which must be kept in mind are adrenocortical insufficiency and untreated diabetic keto-acidosis. However, in none of the documented cases of hyperkalaemic CHB did these play a role.

Unifascicular and bifascicular block in relation to CHB

Hyperkalaemia is the most uncommon cause of these conduction disturbances, especially CHB. Review of the literature confirms the documentation of a total of 10 patients with unifascicular block,^{2,9} 13 with bifascicular block^{3,6-10,22-24} and 3 with CHB (excluding our 2 patients).⁹⁻¹¹ Of those with unifascicular block, 6 had left posterior hemiblock (LPHB)^{2,9} and the remaining 4 LAHB.^{2,9} Of the 13 patients with bifascicular block, 9 had a combination of complete RBBB and LAHB,^{3,6-10,22-24} 2 had RBBB and LPHB^{8,9} and the remaining 2 had complete LBBB.⁹

It is of special interest to note that none of the above patients with unifascicular or bifascicular block (irrespective of what combination of fascicles was involved) developed CHB. The great majority also returned to a normal conduction pattern after correction of the hyperkalaemia. The exceptions were the cases documented by Ohmae and Rabkin,¹⁰ Katsikas and Goldsmith²⁴ and Bashour *et al.*⁹ One of the patients reported by Ohmae and Rabkin initially presented with hyperkalaemic CHB which became a RBBB, then replaced by LAHB, which was present before the hyperkalaemic episode. The patient of Katsikas and Goldsmith²⁴ presented with hyperkalaemic RBBB and LAHB which resolved, leaving LAHB. Lastly, Bashour *et al.*⁹ had 2 patients who did not revert to normal conduction patterns; the first had hyperkalaemic LPHB and RBBB, which responded to treatment leaving residual LAHB, and the second had hyperkalaemic LBBB which converted to LAHB.

Of the 3 cases of hyperkalaemic CHB⁹⁻¹¹ the patient of Grenadier *et al.*¹¹ revealed Mobitz type II second-degree atrioventricular block following attainment of normal serum potassium levels (Table I). The patient of Ohmae and Rabkin¹⁰ converted to RBBB and then to LAHB, in which he remained. Bashour *et al.*'s⁹ patient died during the period of CHB and possible resolution of conduction defects could not be established.

Our 2 patients are unique in their own right (Table I). Patient 1 had been known to have LAHB and RBBB, i.e. bifascicular block, prior to the hyperkalaemic event. He then developed hyperkalaemic CHB and reverted to his original LAHB and RBBB after normalization of the serum potassium value. He probably had underlying 'degenerative' conduction disease precipitated into CHB (trifascicular block) by the hyperkalaemia. Patient 2 had normal conduction initially but developed LBBB which progressed to CHB with hyperkalaemia. However, correction of the hyperkalaemia re-established normal conduction. It will be recalled that the only other documented cases of hyperkalaemic LBBB⁹ did not degenerate into CHB; one developed LAHB and the other reverted to normal conduction.

The 12-year-old patient with CHB documented by Bharati *et al.*¹² had proven systemic lupus erythematosus, renal failure and hyperkalaemia. Autopsy revealed that both the sino-atrial and atrioventricular nodes were completely replaced by granulation tissue in keeping with the systemic lupus. The authors did not accept that the cause of CHB was hyperkalaemia, since the block

16. Garcia-Palmieri MR. Reversal of hyperkalemic cardiotoxicity with hypertonic saline. *Am Heart J* 1962; **64**: 483-488.
17. Fisch C, Greenspan K, Edwards RE. Complete atrioventricular block due to potassium. *Circ Res* 1966; **19**: 373-377.
18. Williams JF, Morrow AG, Braunwald E. The incidence and management of 'medical' complications following cardiac operations. *Circulation* 1965; **32**: 608-619.
19. Wei JY, Genecin A, Green HL, Achuff S. Coronary spasm with ventricular fibrillation during thyrotoxicosis: response to attaining euthyroid state. *Am J Cardiol* 1979; **43**: 335-339.
20. Stern MP, Jacobs RL, Duncan GW. Complete heart block complicating hyperthyroidism. *JAMA* 1970; **212**: 2117-2119.
21. Kernoff LN, Rossouw JE, Kennelly BM. Complete heart block complicating thyrotoxicosis. *S Afr Med J* 1973; **47**: 513-515.
22. Goldman MJ. Emergency medicine: do you know your QRS? Jan 1971.
23. Merrill JP, Levine HD, Sommerville W, Smith S. Clinical recognition and treatment of acute potassium intoxication. *Ann Intern Med* 1950; **33**: 797-830.
24. Katsikas J, Goldsmith C. Disorders of potassium metabolism. *Med Clin North Am* 1971; **55**: 503-512.
25. Lee D, Greenspan K, Edwards RE, Fisch C. The effect of electrolyte alteration on stimulus requirements of cardiac pacemakers (Abstract). *Circulation* 1968; **38**: suppl 6, 124.
26. Walker WJ, Elkins JT, Wood LW. Effect of potassium in restoring myocardial response to a subthreshold cardiac pacemaker. *N Engl J Med* 1964; **271**: 597-601.
27. Surawicz B, Chlebus H, Reeves JT, Gettes LS. Increase of ventricular excitability threshold by hyperpotassemia. *JAMA* 1965; **191**: 1049-1054.
28. Gettes LS, Shabetai R, Downs TA, Surawicz B. Effects of changes in potassium and calcium concentrations on diastolic threshold and strength-interval relationship of the human heart. *Ann NY Acad Sci* 1969; **167**: 693-705.
29. Furman S. Fundamentals of cardiac pacing. *Am Heart J* 1967; **73**: 261-277.
30. Ettinger PO, Regan TJ, Oldewartel HA, Khan MI. Ventricular conduction delay and asystole during systemic hyperkalemia. *Am J Cardiol* 1974; **33**: 876-886.
31. Schwartz AB. Management of potassium intolerance. *Drug Therapy* 1972; **2**: 15-26.
32. Schwartz AB. Potassium-related cardiac arrhythmias and their treatment. *Angiology* 1978; **29**: 194-205.
33. Ettinger PO, Regan TJ, Oldewartel HA. Hyperkalemia, cardiac conduction, and the electrocardiogram: a review. *Am Heart J* 1974; **88**: 360-371.
34. Keurig ECH, Siskind SJ, Sonneblick EH *et al*. Dobutamine in acute myocardial infarction. *JAMA* 1981; **245**: 144-146.
35. Leier CV. Taking a look at new cardiac inotropes. *Patient Care* 1981; **15**: 69-100.

Curiosa Paediatrica VII: Penis circumvallatus

THEODORE JAMES

Summary

A curious condition about the base of the infantile penis to which I have given the name penis circumvallatus is described and illustrated with some speculation regarding its probable origin.

S Afr Med J 1983; **63**: 420-421.

A curious appearance of the base of the infantile penis to which I have given the name penis circumvallatus in the traditional anatomical mode of nomenclature, since it is not pathological, is described and illustrated. The anomaly is more a matter of appearance than of functional disability and suggests, if anything, the abortive development in its first or very early phase of the so-called 'concealed penis'. I have seen one other case, in which the 'circumvallation' was less noticeable but still clearly defined.

In the 'concealed penis'¹ the glans with the prepuce covering it seems to peep out from the pubic fat at the base of the penis, the penis itself being otherwise completely normal in structure and function; this is demonstrable by the manual withdrawal of the penis from the fatty pubic bed in which it is couched, while the

bed is compressed posteriorly against the pubis; urination proceeds normally.

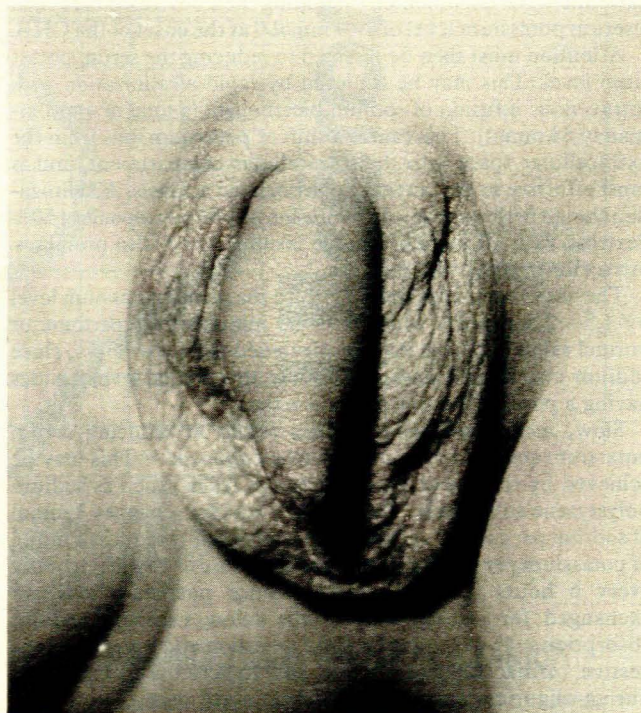


Fig. 1. Anterior aspect of the circumvallation.

16 Spring Gardens, Pinelands, CP
THEODORE JAMES, M.B. CH.B.

Date received: 3 May 1982.