

Hy is met 'n aminoglikosied (tobramisien) behandel omdat Gram-negatiewe basille vantevore uit sy sputum gekweek is. Hierna het hy vinnig herstel en is uit die hospitaal ontslaan.

Bespreking

Die pasiënt het twee ernstige komplikasies ontwikkel na 'n 'eenvoudige' fraktuur. Hy was nooit geskok nie en was na die reduksie van die fraktuur klinies stabiel. Soortgelyke pasiënte word dikwels na immobilisasie van die fraktuur ontslaan. Daar behoort noukeurig gesoek te word na waarskuwingstekens van VES soos respiratoriese probleme, hipoksemie (deur middel van bloedgasbepalings), tagikardie, bewussynsverandering, petechiae asook vet in die urien of sputum, 'n dalende hematokrit of hemoglobienvlak en koors.⁵⁻⁸ Tot dusver is dit nie moontlik om te voorspel watter pasiënte VES sal ontwikkel nie.

Pasiënte met hoë risiko is jong mans wat vroeg hipoksemie ontwikkel.² 'n Plaatjietelling, bepaling van serumvetsure en serumlipase, 'n stolselvriessnit vir vetglobules, meting van geïoniseerde kalsiumvlakke en ander toetse is nie altyd prakties nie.

Pasiënte wat nie binne vinnige bereik van goeie mediese sorg is nie behoort na 'eenvoudige' tibia/fibula-frakture minstens oornag opgeneem te word vir observasie. Pasiënte wat nie opgeneem word nie, moet gewaarsku word teen komplikasies wat mag ontwikkel. Indien VES wel ontwikkel, is die prognose baie goed indien die pasiënt respiratories, met VPLD as die steunpilaar, goed versorg word.⁵

VERWYSINGS

1. Chan KM, Tham KT, Chow YN, Leung PC. Post-traumatic embolism — its clinical and subclinical presentations. *J Trauma* 1984; **24**: 45-49.
2. Pollack R, Meyers RAM. Early diagnosis of the fat embolism syndrome. *J Trauma* 1978; **18**: 121-123.
3. Ahlho A. Clinical manifestations of fat embolism syndrome. *Arch Orthop Trauma Surg* 1978; **92**: 153-158.
4. Hagley SR. The fulminant fat embolism syndrome: case reports. *Anaesth Intensive Care* 1983; **11**: 167-170.
5. Gossling HR, Donahue TA. The fat embolism syndrome. *JAMA* 1979; **241**: 2740-2742.
6. Oh WH, Mital MA. Fat embolism: current concepts of pathogenesis, diagnosis, and treatment. *Orthop Clin North Am* 1978; **9**: 769-779.
7. Lahiri B, Zuwallack R. The early diagnosis and treatment of fat embolism syndrome: a preliminary report. *J Trauma* 1977; **17**: 956-959.
8. Blake DR, Fisher GC, White T, Bramble MG. Ionised calcium in fat embolism. *Br Med J* 1979; **ii**: 902.

Pseudo-myocardial infarction pattern after aortocoronary saphenous vein bypass graft surgery

A case report

J. Z. PRZYBOJEWSKI

Summary

In a 51-year-old medical colleague with symptomatic atherosclerotic coronary artery disease, coronary arteriography delineated significant left mainstem, left anterior descending and left circumflex coronary artery lesions and cine angiography demonstrated normal left ventricular contractility. Aortocoronary saphenous vein bypass grafting was successful. The postoperative appearance of QS waves on the ECG suggested the possible complication of an acute transmural anteroseptal and anterolateral myocardial infarction (MI). However, this possibility was excluded

by resting technetium-99m and thallium-201 scintiscans, as well as by a technetium-99m-gated blood pool scintiscan. The occurrence of acute pericarditis approximately 2 weeks after surgery made clinical evaluation more difficult.

The ECG may represent a pseudo-MI pattern, the patient having suffered a post-pericardiotomy syndrome. The importance of excluding postoperative acute MI is stressed. The causes of the appearance of new Q waves after aortocoronary saphenous vein bypass graft surgery are briefly outlined.

S Afr Med J 1986; **70**: 173-176.

Cardiac Unit, Department of Internal Medicine, Tygerberg Hospital and University of Stellenbosch, Parowvallei, CP
J. Z. PRZYBOJEWSKI, M.B. CH.B., F.C.P. (S.A.), F.I.C.A., F.A.C.C., F.C.C.P., F.A.C.P., F.S.C.A.

Case report

The patient was a 51-year-old medical colleague and friend who had discontinued heavy cigarette smoking 15 years previously. There was no significant family history of ischaemic heart disease

(IHD), apart from his father apparently having had an uncomplicated acute myocardial infarction (MI) at 68 years of age. Acute gout had been diagnosed 18 years previously and was adequately controlled by diet alone. He also had a history of possible essential hypertension and had recently had an episode of pleural effusion thought to have been secondary to viral pneumonitis.

In 1954 the patient had complained of 'dyspepsia' but was found not to have a duodenal ulcer. A diagnosis of 'flying-related stress' was then made (he was then a Royal Air Force fighter-pilot and flying instructor). In 1962 he first began experiencing central chest pain radiating to the jaw but did not undergo investigation of this symptom. Two years later these attacks occurred more frequently, and a stress ECG and barium meal examination were carried out. These were both negative, and a diagnosis of 'oesophageal spasm' was made. However, in 1977, some 12 years later, a routine stress ECG performed for life-insurance purposes was abnormal. Because of this finding, the patient was referred to another teaching hospital and, after treadmill stress testing, was informed that he should not be concerned since he was 'symptom-free'. No further cardiological examination was therefore carried out.

The recent history was one of classic effort-related angina pectoris, first experienced in July 1984. This was soon followed by an episode of *angor animi*. Two days after this the patient was seen by his specialist physician, who excluded the possibility of a recent acute MI. At this stage he was referred to me and was admitted to the Cardiac Unit at Tygerberg Hospital on 1 August for further investigation.

Clinical examination revealed a slightly overweight middle-aged man otherwise in a good general state with no evidence of essential hypertension or cardiac failure. A prominent fourth heart sound was audible in the absence of any cardiac murmurs. The remainder of the physical examination was negative. Examination of the blood and urine and serum biochemical analyses gave normal results. A chest radiograph delineated a normal cardiac silhouette and lung fields. A resting ECG showed sinus rhythm at 64/min, a normal P-R interval, slight left axis deviation, and ischaemic-looking ST segments in the anterolateral leads (Fig. 1, a). In view of the impressive history of angina pectoris it was decided to carry out a submaximal treadmill stress test (Bruce protocol), which demonstrated a maximum of 2 mm horizontal ST-segment depression inferolaterally and anteroseptally at a heart rate of 115/min. This ECG change was accompanied by typical angina pectoris, at which time the stress test was discontinued with rapid relief of this symptom and resolution of the ECG ischaemia. In view of the patient's history and relatively young age it was decided to undertake cardiac catheterization and selective coronary angiography on 2 August.

Cardiac catheterization

This was carried out from the right groin, using the percutaneous Seldinger technique. The aortic and left ventricular (LV) pressures were within normal limits. LV cine angiography in the right anterior oblique (RAO) projection demonstrated normal contractility with no mitral valve prolapse or incompetence. Injection of contrast material into the right coronary artery (RCA) in the left anterior oblique (LAO) and RAO views delineated an angiographically normal and dominant RCA (Fig. 2). However, retrograde filling of the left anterior descending (LAD) coronary artery via right-to-left collateralization was evident. The LAD artery filled as far proximally as the first diagonal branch and appeared suitable for coronary artery bypass graft (CABG) surgery (Fig. 2). The left coronary artery (LCA) cine angiograms, taken in multiple projections, demonstrated an 80% left mainstem lesion, an 80% proximal and 90% distal LAD artery obstruction, a 90% lesion of the first diagonal branch, and 80% stenosis of the left circumflex (LCx) coronary artery (Fig. 3). The patient had no angina pectoris during catheterization, which was completed without complication.

In the light of the coronary arteriographic features it was decided to undertake CABG surgery. Prior to this treatment with nifedipine 10 mg 3 times daily, a transdermal nitrate preparation and sublingual isosorbide dinitrate when necessary was instituted.

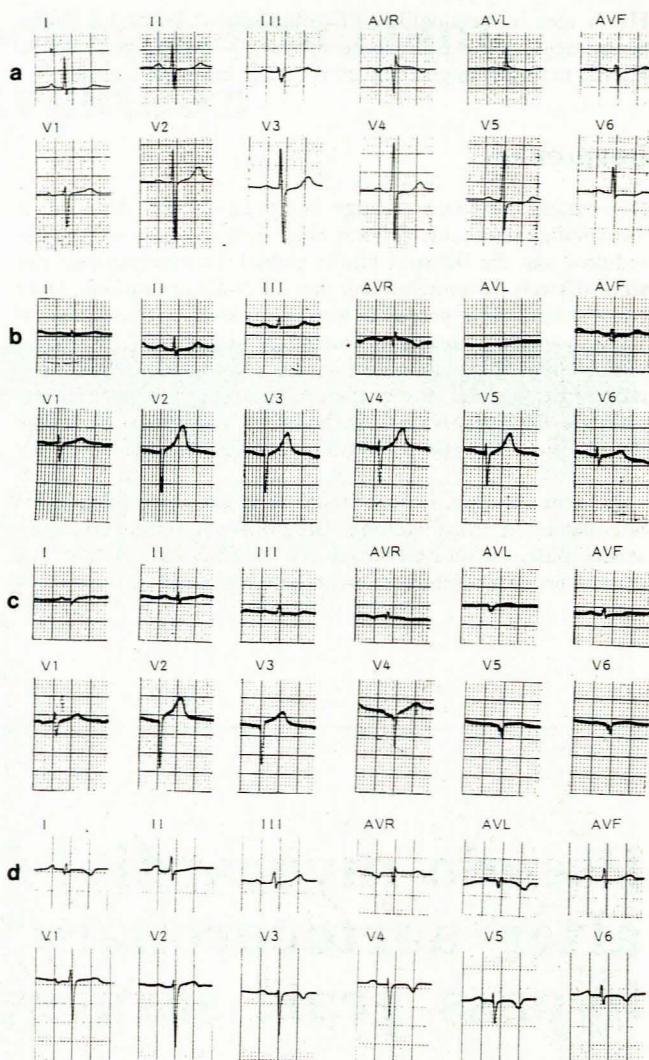


Fig. 1. Resting 12-lead ECG recorded on full standardization: (a) pre-operative tracing showing slight left axis deviation and anterolateral ischaemic ST segments; (b) marked QRS-voltage reduction in the standard limb leads and very poor R-wave progression over the unipolar chest leads immediately postoperatively; (c) QS waves evident in the anteroseptal and anterolateral leads, suggesting an acute transmural myocardial infarction, 1 day postoperatively; and (d) small R waves present in the anteroseptal and lateral leads approximately 10 weeks postoperatively; also, small Q waves can be seen in the high lateral leads and symmetrical T-wave inversion is evident.

A resting ECG recorded on the day before surgery was unchanged from that taken on initial admission.

Coronary artery surgery

This was carried out on 14 August using cold cardioplegia. Inspection of the myocardium showed no evidence of previous MI. CABGs were inserted into the LAD artery proximal to the second diagonal branch and the first diagonal branch. Inspection of the LCx artery showed this to be of small calibre and diffusely diseased and therefore unsuitable for bypass surgery. The operation was completed without complication.

Postoperative course

The resting ECG on the patient's return to the intensive care unit on the day of the operation was significantly altered — the QRS voltage was reduced in the standard limb leads and marked

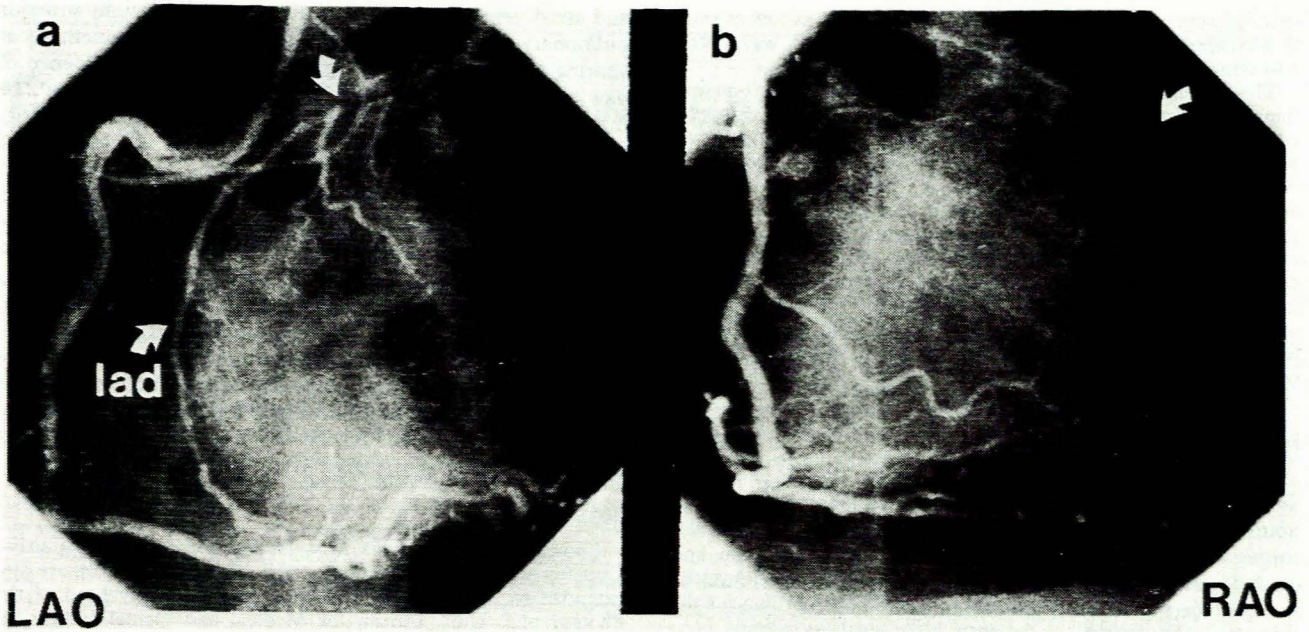


Fig. 2. Right coronary cine angiograms in (a) LAO and (b) RAO views. The vessel is dominant and appears free of disease. Retrograde filling of the LAD coronary artery (arrows) is visualized.

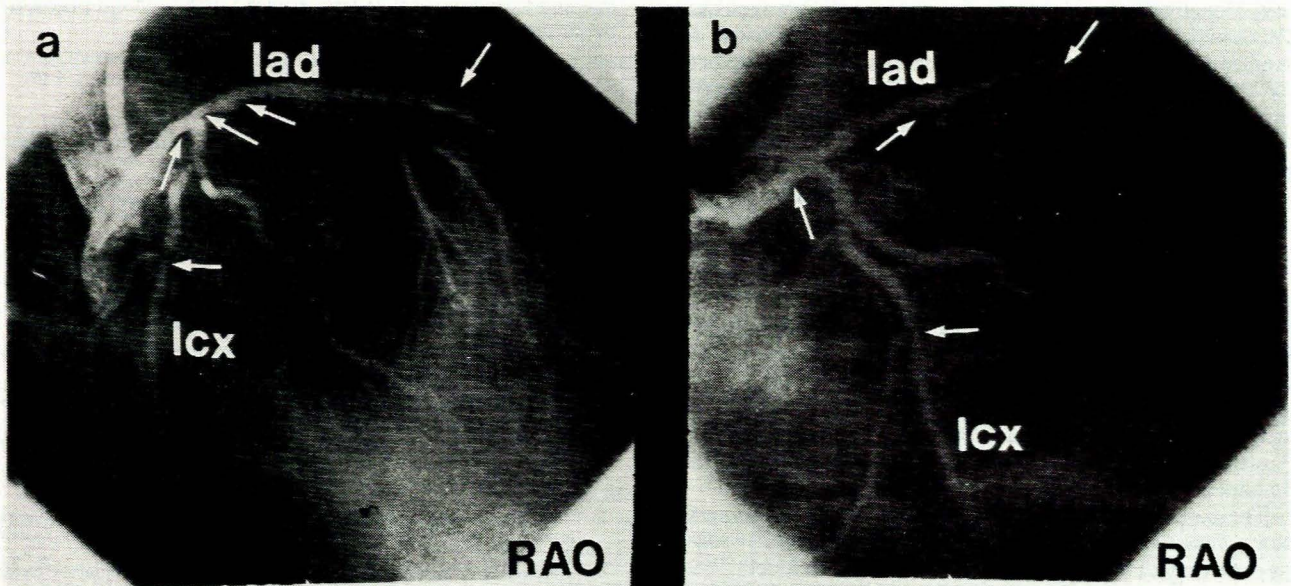


Fig. 3. Left coronary cine angiograms in (a) RAO view and (b) shallow RAO view with caudal angulation. Significant atherosclerotic lesions (arrowed) are seen in the left mainstem, LAD and LCx coronary arteries.

reduction of the R waves was evident over all the unipolar chest leads (Fig. 1, b). On the day after CABG surgery the resting ECG highlighted undoubted QS waves in the anteroseptal and anterolateral leads, suggesting an acute transmural MI (Fig. 1, c). In view of the likelihood of a complicating acute MI, daily resting ECGs were taken and serum cardiac enzyme levels (including MB iso-enzymes) documented. The ECG remained unchanged and the enzyme levels did not fulfil the criteria for an acute MI. Furthermore, a technetium 99m-pyrophosphate scintiscan ('hot-spot scan') done on 21 August (7 days postoperatively) was entirely normal. Throughout this period the patient did not complain of any chest pain and all other clinical signs remained normal. He was then mobilized and discharged home on 26 August, some 12 days after surgery. Discharge medication consisted of dipyridamole 100 mg 3 times daily and a small dose of aspirin.

At this stage his resting ECG still demonstrated QS waves in the anteroseptal and anterolateral leads.

Follow-up

Within a relatively short period after discharge the patient developed a classic post-cardiotomy syndrome which responded most satisfactorily to salicylates and symptomatic therapy. At no stage did he have any recurrence of angina pectoris. To gain further insight into the ECG changes encountered postoperatively, a resting thallium-201 scintiscan ('cold-spot scan') was performed on 18 September. The findings were within normal limits and no evidence of a previous MI was demonstrated. A resting ECG recorded on 31 October, some 10 weeks postoperatively, showed

small R waves in the anteroseptal and lateral leads, as well as small Q waves in the high lateral leads (Fig. 1, d). The T waves were also symmetrically inverted in these leads.

The patient continued to be free of angina on no anti-anginal therapy. In order further to exclude the possibility of a postoperative acute MI, a technetium-99m-gated blood pool scintiscan was performed on 26 February 1985. This investigation demonstrated normally contracting right and left ventricles, the latter displaying an ejection fraction of 53% (normal). An M-mode and cross-sectional echocardiogram also showed normal cardiac dimensions and function. Submaximal stress testing (Bruce protocol) was carried out on 27 February. The patient reached a maximum heart rate of 166/min and managed to exercise for 10 minutes and 44 seconds. He experienced no angina pectoris, and no evidence of myocardial ischaemia could be documented. His resting ECG is continuing to approach normality.

Discussion

Symptomatic atherosclerotic IHD is exceptionally common in South Africa, and aortocoronary saphenous vein bypass graft surgery is frequently undertaken. The cardiac surgeon and cardiologist responsible for postoperative follow-up should be aware of certain difficulties encountered in these cases. One such diagnostic problem is well illustrated by the present case. It is well known that acute MI can complicate CABG surgery and that this event worsens the long-term prognosis; hence the need to prevent such a complication. Nevertheless, the definitive diagnosis of postoperative acute MI is not always clear-cut. Usually the appearance of pathological Q waves on an ECG which did not previously display these is taken as a reliable sign of transmural MI. This diagnosis is strengthened by serum cardiac enzyme elevation and positive scintigraphic investigations. Chest pain is not, however, always a reliable symptom of post-CABG MI. A further difficulty in the present case was the appearance of acute pericarditis a few weeks after surgery. This event would normally have been accepted as due to the post-pericardiotomy syndrome, which occurs in some 10-40% of patients.¹⁻⁴ However, in the light of the new Q waves on the ECG the possibility of a post-MI syndrome (Dressler's syndrome)^{5,6} was considered.

Review of the literature indicates that much controversy exists about the appearance of new Q waves after CABG surgery, the incidence varying between 8% and 40%.⁷⁻¹¹ Some authors¹² state that the presence of left main coronary artery stenosis, as in our patient, increases this incidence. However, Aintablian *et al.*⁷ did not find this to be true in their series of 56 patients with new Q waves.

The pathophysiology of postoperative Q waves is somewhat controversial. Most importantly, an acute MI directly related to occlusion of bypass grafts must first be excluded.¹³⁻¹⁵ Of interest is the fact that acute MI can occur with patent bypass grafts in up to 50% of cases.¹⁴ Although our patient did not undergo postoperative cardiac catheterization and selective coronary angiography to determine the patency or otherwise of the saphenous vein bypass grafts, acute MI was excluded by all other means. It can therefore be assumed that the postoperative Q waves were pseudo-infarction Q waves and that the saphenous vein bypass grafts were patent. Aintablian *et al.*⁷ demonstrated no direct correlation between new Q waves and postoperative LV cine angiograms but established that improved LV function, as determined by cine angiography, correlated directly with patency of bypass grafts despite the presence of new Q waves. The phenomenon of 'unmasking of old infarction', as exemplified by conversion of non-pathological Q waves to pathological ones, has been documented^{7,16} and is believed to be due to a local conduction disturbance. This possibility certainly did not apply in our patient.

Early in the history of CABG surgery the LV was vented through the apex. Nowadays, however, this is no longer done

and atrial venting is usually carried out via the right superior pulmonary vein, as in the present case. These two methods of venting lead to quite striking differences in the incidence of new postoperative Q waves. Aintablian *et al.*⁷ reported a 22% incidence of new Q waves in patients undergoing LV venting, whereas this incidence fell to 5,8% with the introduction of atrial venting. The trauma of venting of the LV apex is said to be sufficient to cause Q waves but not LV dysfunction, since large epicardial coronary arteries are not damaged.⁷ Furthermore, these Q waves are usually located in the anterior or inferior wall. Some authors^{17,18} have suggested that new Q waves can result from an unduly prolonged aortic cross-clamp time, or lengthened pump time, but this is most controversial.

The present case therefore highlights some of the difficulties encountered in management of patients recovering from CABG surgery. Awareness that Q waves may not be due to transmural MI is emphasized, since advice to the patient regarding drug therapy and prognosis is very different.

I wish sincerely to thank Miss H. W. Weymar of the Cardiac Unit for preparing the ECG illustrations. Sincere thanks are also extended to Mr Christopher Wilberforce, formerly head of the Photographic Unit, Bureau for Medical and Dental Education, University of Stellenbosch, for preparing the photographs. I would also like to express my gratitude towards Dr J. P. van der Westhuyzen, Chief Medical Superintendent of Tygerberg Hospital, for permission to publish. Finally, my thanks go to the patient, who was willing to give permission to publish his case in the hope of enlightening medical colleagues faced with a similar problem in the future.

REFERENCES

- Engle MA, Zabriskie JB, Senterfit LB *et al.* Post pericardiotomy syndrome: a new look at an old condition. *Mod Concepts Cardiovasc Dis* 1975; **44**: 59-64.
- Livelli FD jun, Johnson RA, McEnany MT *et al.* Unexplained in-hospital fever following cardiac surgery: natural history, relationship to postpericardiotomy syndrome and a prospective study of therapy with indomethacin versus placebo. *Circulation* 1978; **57**: 968-975.
- Engle MA, Gay WA jun, Kaminsky ME, Zabriskie JB, Senterfit LB. Postpericardiotomy syndrome then and now. *Curr Probl Cardiol* 1978; **3**: 1-40.
- Kaminsky ME, Rodan BA, Osborne DR, Chen JTT, Sealy WC, Putman CE. Postpericardiotomy syndrome. *AJR* 1982; **138**: 503-508.
- Dressler W. The post-myocardial infarction syndrome: a report of forty-four cases. *Arch Intern Med* 1959; **103**: 28-42.
- Lichstein E, Arsura E, Hollander G, Greengart A, Sanders M. Current incidence of post-myocardial infarction (Dressler's) syndrome. *Am J Cardiol* 1982; **50**: 1269-1271.
- Aintablian A, Hamby RI, Hoffman I, Weisz D, Voleti C, Wisoff BG. Significance of new Q waves after bypass grafting: correlations between graft patency, ventriculogram, and surgical venting technique. *Am Heart J* 1978; **95**: 429-440.
- Friedberg D, Zeff H, Siberman R *et al.* Myocardial infarction following coronary surgery: vectorcardiographic assessment (Abstract). *Am J Cardiol* 1973; **31**: 132.
- Anderson WT, Brundage BH, Cheitlin MD. Vectorcardiographic changes following coronary artery bypass surgery. *Am Heart J* 1974; **87**: 421-427.
- Espinoza J, Lipski J, Litwak R, Donoso E, Kack S. New Q waves after coronary artery bypass surgery for angina pectoris. *Am J Cardiol* 1974; **33**: 221-224.
- Schrank JP, Slabaugh TK, Beckwith JR. The incidence and clinical significance of ECG-VCG changes of myocardial infarction following aortocoronary saphenous vein bypass surgery. *Am Heart J* 1974; **87**: 46-54.
- Williams D, Iben A, Jurley E *et al.* Myocardial infarction during coronary artery bypass surgery (Abstract). *Am J Cardiol* 1973; **31**: 164.
- Brewer D, Bilbro RH, Bartel AG. Myocardial infarction as a complication of coronary bypass surgery. *Circulation* 1973; **47**: 58-64.
- Assad-Morell JL, Gau GT, Frye R, Connolly D, Davis GD, Danielson GK. Relation of intraoperative or early postoperative myocardial infarction to patency of aortocoronary bypass grafts and to ungrafted coronary arteries. *Am J Cardiol* 1975; **35**: 767-773.
- Fruehan CT, Johnson JW, Potts JL, Smulyan H, Parker FB jun, Eich RH. Follow-up catheterization of patients with myocardial infarction during coronary artery bypass surgery. *Am Heart J* 1976; **91**: 186-190.
- Bassan MM, Oatfield R, Hoffman I, Matloff J, Swan HJC. New Q waves after aortocoronary bypass surgery: unmasking of an old infarction. *N Engl J Med* 1974; **290**: 349-353.
- Codd JE, Kaiser GE, Barner HB, Millman VL, Miens RD. Aortocoronary bypass grafting: incidence of myocardial infarction. *Circulation* 1974; **49/50**: suppl III, 166.
- Rose MR, Glassman E, Isom OW, Spencer FC. Electrocardiographic and serum enzyme changes of myocardial infarction after coronary artery bypass surgery. *Am J Cardiol* 1974; **33**: 215-220.