

Multiple vanishing tumours simulating pulmonary neoplasms

A case report

W. F. C. VAN GELDEREN

Summary

Vanishing fluid collection (or tumour) in an interlobar fissure associated with congestive cardiac failure is not common. Multiple vanishing tumours are most uncommon and can resemble other multiple opacities, e.g. metastases. The disappearance of these so-called tumours after treatment for cardiac failure provided proof of the diagnosis in the patient reported. This diagnosis is important to consider in order to prevent unnecessary investigation and treatment.

S Afr Med J 1989; 75: 498-499.

A solitary vanishing tumour as part of congestive cardiac failure is uncommon, but multiple vanishing tumours, simulating pulmonary metastatic deposits, is a most unusual condition. The importance of making the correct diagnosis, and thus avoiding unnecessary investigation and treatment, is stressed.

Department of Radiology, Tygerberg Hospital, Parowvallei, CP

W. F. C. VAN GELDEREN, M.B. CH.B., F.F.RAD. (D.) (S.A.)

Accepted 8 Aug 1988.

Case report

An 83-year-old woman presented to hospital with typical signs and symptoms of cardiac failure.

Radiography of the chest (Fig. 1) revealed cardiac enlargement, left ventricular in configuration. Signs of cardiac decompensation included upper lobe blood diversion and large bilateral pleural effusions, which were predominantly sub-pulmonary in position.

However, a remarkable feature was the loculation of fluid in the upper part of the right major fissure and in the middle part of the minor fissure. Both these loculations were dense and sharply defined on the lateral film, and contiguous with thin stripes of fluid in the fissures, but less dense and less well defined on the frontal film.

Two other well-defined fluid collections were noted more peripherally, loculated subcostally within the pleural space and close to the previously mentioned opacities on the frontal film and situated behind the major fissure.

On the lateral film the posterior costophrenic angles were obscured by fluid and there was also a triangular collection of fluid in the inferior aspect of the right major fissure. There was also pleural fluid retrosternal in position extending up to the level of the minor fissure.

The patient was treated with digitalis, diuretics, and bedrest. A follow-up film (Fig. 2) taken 8 weeks later revealed a significant reduction in the cardiac size and complete disappearance of all pleural fluid collections. However, this supine

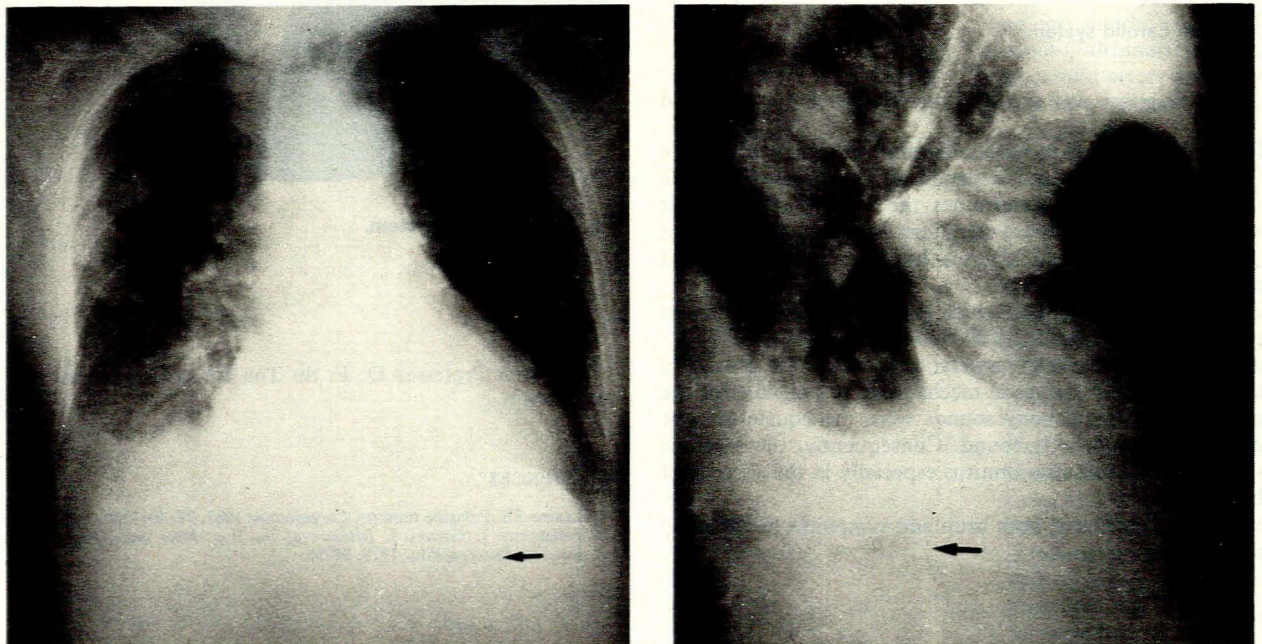


Fig. 1. Note opacities in the right mid-zone, one situated in the major fissure and one in the minor fissure. Two other opacities are situated in a subcostal position on the frontal film superimposed behind the major fissure on the lateral film. Most pleural fluid is sub-pulmonary in position — the gastric air/fluid level is arrowed.

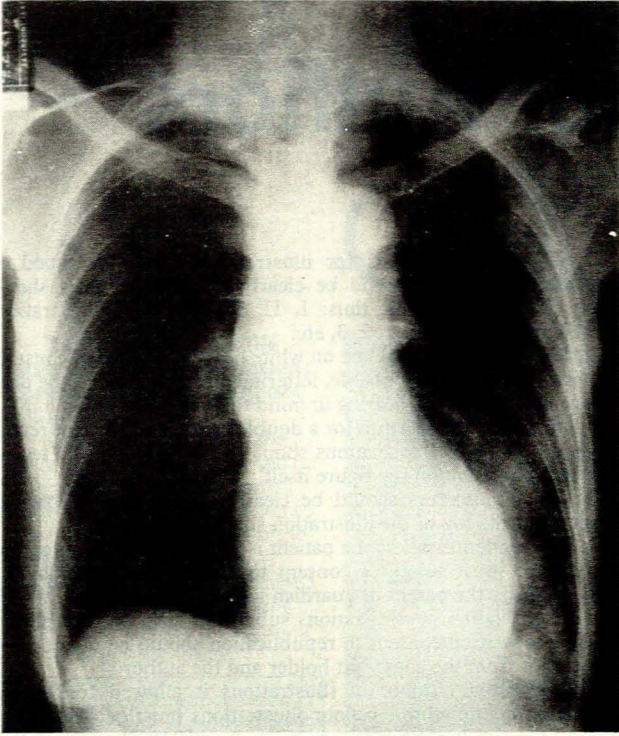


Fig. 2. Follow-up film taken with the patient in the supine position. There is marked reduction in cardiac size and complete disappearance of all pleural fluid collections after treatment for cardiac failure. Pneumonic consolidation involving the left lower lobe is now evident.

film demonstrated evidence of left lower lobe pneumonia. The patient died a few days later.

Discussion

Loculation of pleural fluid within an interlobar fissure, although uncommon, is most often associated with congestive heart failure. In terms of the volume of fluid, such an effusion is not of particular importance since it is too small to compromise pulmonary function. However, it is significant because of its radiographic appearance, which can be confused with that of an intrapulmonary lesion, especially on the frontal chest film, and may lead to unnecessary and sometimes inadvisable treatment.

Although congestive heart failure with pleural effusion is frequently encountered in clinical medicine, the phenomenon of vanishing tumours is rare.¹ At least 48 cases of vanishing

tumours had, however, been reported up to 1966. In a series of 368 patients with cardiac failure, 11 vanishing tumours were found, and the condition was not considered unusual.² The true incidence is nevertheless difficult to assess because of the small number of cases reported.

Interlobar fluid collection most commonly occurs in the right minor fissure (as in over 75% of reported cases) and less frequently in the major fissure.³ The simultaneous existence of separate effusions in two interlobar fissures is extremely rare, although a case of multiple vanishing tumours, one situated in the minor fissure, but the other in the 'anterior superior paramediastinal space' has been reported.⁴

The mechanism of loculation of the effusion in congestive heart failure still remains uncertain. Stewart⁵ and Steele⁶ reported cases of vanishing tumours where subsequent autopsy revealed adhesive pleuritis. Fraser and Paré⁷ mention the possibility that parenchymal disease, i.e. consolidation, atelectasis or fibrosis, may modify the retractability of that portion of the lung locally, causing pleural fluid to be attracted to it.

Radiography (Figs 1 and 2) in this case demonstrated an unusual appearance, and if only a frontal film had been available the diagnosis of metastatic deposits could have been considered, although the close proximity of the four tumours would have been difficult to explain. The cardiomegaly could have been regarded as nonspecific in this age group but the 'pseudodiaphragm' on the left due to sub-pulmonary fluid was significant. Although the lateral film showed that the masses were pleural in origin, they were originally reported to be pleural tumours or metastases as the radiographic signs of cardiac failure were not recognised.

Taking into account the entire picture (Figs 1 and 2) and the follow-up film after therapy (Fig. 3), there was no doubt that these 'tumours' represent loculated, tumour-like fluid collections.

An important clue to the pleural origin of these masses is their crisp, well-demarcated and very radio-dense appearance on one view, and their ill-defined, vague and much less dense appearance on the other projection. This is an important characteristic of pleural disease.

REFERENCES

1. Willerson JT, Fred HL, Eiband JM, Collins IC. Roentgenogram of the month. *Dis Chest* 1965; 48: 85-86.
2. Bedford DE, Lervibond JL. Hydrothorax in heart failure. *Br Heart J* 1941; 3: 93-111.
3. Weich DJV, Theron HduT. Phantom tumour of the lung secondary to left heart failure. *S Afr Med J* 1984; 65: 351-353.
4. DiMaio M. Multiple localised pleural effusions as a manifestation of congestive heart failure. *N Engl J Med* 1948; 238: 502-506.
5. Stewart HJ. Pleural effusion localised in an interlobar space; report of a case of heart failure together with autopsy. *Am Heart J* 1928; 4: 227-235.
6. Steele JM. Report of two cases of localised pleural effusion in heart failure. *Am Heart J* 1931; 7: 212-222.
7. Fraser RG, Paré JA. *Diagnosis of Diseases of the Chest*. Vol. 1. Philadelphia: WB Saunders, 1977: 576.