

Recurrent pancreatitis after partial ileal bypass for hyperlipidaemia

A case report

D. F. DU TOIT, C. KNOTT-CRAIG, L. LAKER

Summary

The case of a 28-year-old man with alcohol-induced bouts of recurrent acute pancreatitis after a partial ileal bypass performed for hyperlipidaemia is presented. Serial computed tomography proved valuable for assessing the resolution of the pancreatic mass. Peripheral parenteral hyperalimentation for 6 weeks had a beneficial effect on the course of the pancreatitis and proved to be useful for nutritional support.

S Afr Med J 1985; 68: 483-484.

The association of pancreatitis with hyperlipidaemia has been well documented.^{1,2} However, the cause and effect remain incompletely understood and despite intensive study the mechanism by which hyperlipidaemia may result in pancreatitis remains to be defined. A major advance in the understanding and definition of the hyperlipidaemias was the demonstration that partial ileal bypass could prevent hypercholesterolaemia and atherosclerosis in experimental models despite consumption of atherogenic diets.³ Recent data suggest that diet and drug therapy, singly or in combination, rarely achieve the lipid reductions reached by partial ileal bypass in selected patients.³⁻⁵

The course and management of a patient with recurrent bouts of acute pancreatitis and associated hyperlipidaemia several years after partial ileal bypass is described.

Case report

A 28-year-old man was admitted to Tygerberg Hospital with a 2-day history of nausea, vomiting and severe epigastric pain radiating to the back. His symptoms had appeared after an alcoholic binge. There was no history of biliary tract disease, jaundice, diabetes or peptic ulcer disease. In 1980 the patient had had a partial ileal bypass for hyperlipidaemia. Before the bypass he had been treated by dietary measures and clofibrate and nicotinic acid. After the operation the patient had been admitted to hospital with pancreatitis on numerous occasions, usually following alcohol consumption. He was not an alcoholic. Within the 3 years after the bypass he was often found to have elevated serum triglyceride and cholesterol levels. Proteinuria and glucosuria were not noted at any time during his outpatient visits.

On admission the blood pressure was 120/70 mmHg, pulse rate 110/min, temperature 37,5°C, haemoglobin concentration 10 g/dl and erythrocyte sedimentation rate 120 mm/1st h (Westergren). No cutaneous eruptions, xanthomas, or xanthelasmas were present. Abdominal examination revealed severe epigastric tenderness associated with an underlying non-discrete mass, involuntary guarding and rebound tenderness. A clinical diagnosis of acute pancreatitis was made.

Initial laboratory results were difficult to interpret as the serum was severely lipidaemic. The blood gas analysis was normal.

The patient was managed with nasogastric suction, intravenous hydration with 0,45% saline and parenteral analgesia at first. On the 7th day in hospital an ultrasound investigation showed a diffusely enlarged pancreas with a normal gallbladder and biliary tree. A barium meal showed widening of the duodenal loop (Fig. 1). Computed tomography (CT) of the pancreas confirmed the ultrasound findings (Fig. 2) and showed a large pancreatic phlegmon.

A liquid diet was begun on the 10th hospital day, but was promptly discontinued because of recurrent upper abdominal pain. Liver function tests and lipid studies at this stage revealed hypertriglyceridaemia, hypercholesterolaemia and

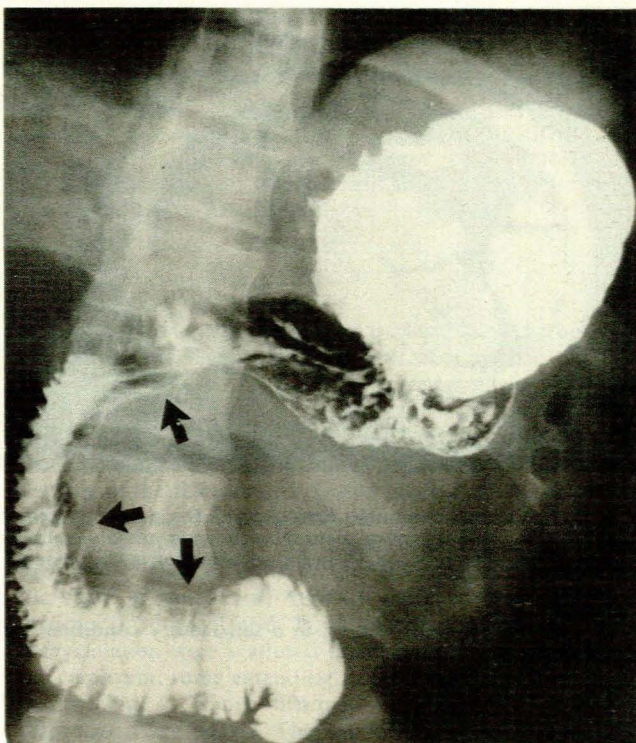


Fig. 1. Barium contrast study of the upper gastro-intestinal tract demonstrating mass effect and mucosal effacement involving the duodenal loop (arrows).

Department of Surgery, University of Stellenbosch and Tygerberg Hospital, Parowvallei, CP

D. F. DU TOIT, D.PHIL., F.R.C.S., Senior Lecturer

C. KNOTT-CRAIG, M.B. CH.B., Registrar

L. LAKER, B.SC., Research Assistant

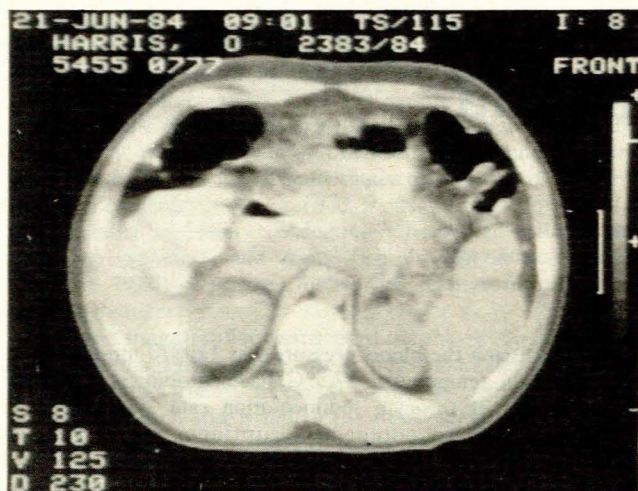


Fig. 2. Transverse computed tomogram of the pancreas on admission showing the features of severe acute pancreatitis.

hyperamylasaemia. A haematological profile revealed mild pancytopenia.

Because the patient was unable to tolerate any form of enteral nutrition, peripheral parenteral nutrition using dextrose, 10% Intralipid and Synthamin was administered continuously for 50 days. During this period no technical or metabolic complications from the intravenous feeding were observed. The epigastric mass underwent resolution, confirmed on serial CT of the abdomen (Fig. 3). Six weeks after admission oral alimentation was recommended. Complications of the pancreatitis such as hypocalcaemia, hyperglycaemia and glucosuria, intravascular coagulation and adult respiratory distress syndrome did not occur.

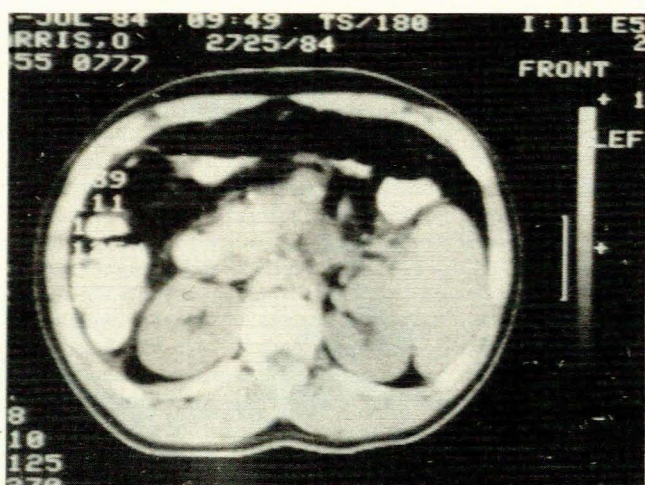


Fig. 3. Transverse computed tomogram of the pancreas after 4 weeks of peripheral hyperalimentation showing partial resolution of the pancreatitis process. Pseudocyst formation is not present.

The patient was discharged in a satisfactory condition and returned to work.

Discussion

A number of observations and tentative conclusions can be drawn from this case. The first is the association of underlying hyperlipidaemia and acute pancreatitis.^{1,2} Secondly, transient hyperlipidaemia may occur during and after a bout of

pancreatitis. Thirdly, almost all patients found to have pancreatitis and hyperlipidaemia are either alcoholics who have been drinking shortly before the onset of pancreatitis or patients with pre-existent hyperlipoproteinaemia.² Fourthly, total parenteral nutrition administered by the peripheral route is effective in providing nutritional support during prolonged illness.^{2,6,7} Although partial ileal bypass has proved consistently to lower cholesterol and triglyceride levels in selected patients it did not afford protection against recurrent bouts of pancreatitis in this patient.

The object of these bypass operations at present is to assess whether partial ileal bypass for maximal lipid reduction can cause retardation, arrest or reversal of the atherosclerotic process in individuals with known coronary atherosclerotic disease.⁵ Trials are at present under way and the results are eagerly awaited; provisional results reported by Buchwald *et al.*⁵ have indicated that regression of atherosclerotic plaque lesions may occur after partial ileal bypass in patients with familial hypercholesterolaemia.

The operation consists of a bypass of the distal 200 cm or one-third of the small intestine, with restoration of intestinal continuity by an end-to-side anastomosis of the proximal small intestine to the caecum.³⁻⁵ Partial ileal bypass is not a weight-reducing operation in contrast with the more extensive 90% jejunio-ileal bypass procedure that is used in the treatment of morbid obesity.⁵

Recent studies by the Minnesota group⁵ have indicated that partial ileal bypass can normalize elevated plasma lipid and lipoprotein levels with a maximal lowering in low-density lipoprotein cholesterol concentration without altering the high-density lipoprotein cholesterol levels. In the short term the results appear to be lasting, although the cholesterol-lowering effect of the operation is neither uniform nor precisely predictable for each person.

The procedure has an operative mortality of less than 0.5% and complications include diarrhoea and impairment of vitamin B₁₂ absorption, necessitating prophylactic parenteral B₁₂ administration.⁵ The need for operative restoration of bowel continuity because of intractable diarrhoea has only been necessary in a small percentage of patients. The complications of hepatic fatty infiltration or fibrosis, arthritis and an increased incidence of nephrolithiasis as seen after jejunio-ileal bypass have not been reported after partial ileal bypass.

In some studies investigators have reported a decrease in the size of peripheral, subcutaneous and tendon xanthomas, together with a subjective improvement in the symptoms of angina pectoris.³

Although partial ileal bypass has firmly established its place in the surgical treatment of the hyperlipidaemias further research and careful appraisal are needed to define the exact indications in the treatment of patients with hypercholesterolaemia.

We thank Mrs M. Louw for typing the manuscript, Dr J. P. van der Westhuyzen, Medical Superintendent of Tygerberg Hospital, for permission to publish, and Dr J. J. Heydenrych for critical review of the manuscript.

REFERENCES

- Greenberger NJ. Pancreatitis and hyperlipidemia. *N Engl J Med* 1973; **289**: 586-587.
- Weinberg RB, Sitrin MD, Adkins GM, Lin CC. Treatment of hyperlipidemic pancreatitis in pregnancy with total parenteral nutrition. *Gastroenterology* 1982; **83**: 1300-1305.
- Buchwald H, Moore RB, Varco RL. Surgical treatment of hyperlipidemia. *Circulation* 1974; suppl 1: 1-2 - 1-37.
- Moore RB, Buchwald H, Varco RL. The effect of partial ileal bypass on plasma lipoproteins. *Circulation* 1980; **62**: 469-476.
- Buchwald H, Moore RB, Matts JP *et al.* The program on the surgical control of the hyperlipidemias: a status report. *Surgery* 1982; **92**: 654-662.
- Goodgame JT, Fischer JE. Parenteral nutrition in the treatment of acute pancreatitis: effect on complications and mortality. *Ann Surg* 1977; **186**: 651-658.
- Chipponi JX, Bleier JC, Rudman D. Current status of peripheral alimentation. *Ann Intern Med* 1981; **95**: 114-115.