

11. Wilkinson R. The frequency of hepatitis A and B viruses as the offending viral type in suspected hepatitis. *Afr Med J* 1983; **63**: 82-85.
12. Abdool Karim SS, Coovadia HM, Windsor IM, Thejpal R, Van den Ende J, Fouche A. The prevalence and transmission of hepatitis B virus infection in urban, rural and institutionalised South African black children. *Int J Epidemiol* 1988; **17**: 100-104.
13. Chin KP, Lok ASF, Wong LSK, Lai CL, Wu PC. Current seroepidemiology of hepatitis A in Hong Kong. *J Med Virol* 1991; **34**: 191-193.
14. El-Hazmi MAF. Hepatitis A antibodies: prevalence in Saudi Arabia. *J Trop Med Hyg* 1989; **92**: 427-430.
15. Tsega E, Nordenfelt E, Mengesha B, Hansson BG, Tsega M, Lindberg J. Age-specific prevalence of hepatitis A virus antibody in Ethiopian children. *Scand J Infect Dis* 1990; **22**: 145-148.
16. Innis BL, Snitbhan R, Hoke CH, Munindhorn W, Laorakpongse T. Declining transmission of hepatitis A in Thailand. *J Infect Dis* 1991; **163**: 989-995.
17. Noguchi A, Hayashi J, Nakashima K, Ikematsu H, Hirata M, Kashiwagi S. Decrease of hepatitis A and B virus infections in the population of Okinawa, Japan. *J Infect* 1991; **23**: 255-262.
18. Editorial. Hepatitis A: a vaccine at last. *Lancet* 1992; **339**: 1198-1199.
19. Kane MA. Prospects for the introduction of hepatitis A vaccine into public health use. *Prog Med Virol* 1990; **37**: 96-100.
20. Kiepiela P, Coovadia HM, Loening WEK, Coward P, Abdool Karim SS. Loss of maternal measles antibody in black South African infants in the first year of life — implications for age of vaccination. *S Afr Med J* 1991; **79**: 145-148.
21. Leentvaar-Kuijpers A, Coutinho RA, Brulein V, Safary A. Simultaneous passive and active immunisation against hepatitis A. *Vaccine* 1992; **10**: suppl 1, S138-S141.

## Congenital pseudarthrosis of the tibia — treatment with free vascularised fibular grafts

C. S. F. SMIT, B. J. v. R. ZEEMAN, W. J. WADE

**Abstract** Congenital pseudarthrosis is uncommon. We report on a series of 4 patients treated by means of free vascularised fibular grafts. Complications encountered were graft fracture, delayed union and angulation deformities. Modifications in the surgical technique improved later results. We recommend wide excision of pathological bone, bridging of the defect by free vascularised fibular grafts and rigid fixation.

*S Afr Med J* 1993; **83**: 750-752.

**A** pseudarthrosis is a pathological entity in which deossification of a long bone is followed by bending and pathological fracture. Inability to form normal callus produces the false joint that gives the condition its name (Fig. 1).

Congenital pseudarthrosis is a rare condition the cause of which is unknown.<sup>1,2</sup> Neurofibromatosis seems to be the commonest associated feature.<sup>3-5</sup> The tibia is most often affected. To achieve bony union in these patients is a considerable surgical challenge.<sup>6</sup>

### Patients and methods

Since April 1990 we have treated 4 patients with this condition by means of free vascularised fibular grafts. Their ages ranged from 22 to 58 months. There was an equal number of males and females. The left leg was predominantly affected, with the distal half of the tibia the involved segment.

Pre-operative arteriograms of both lower legs are essential. Visualisation of the vascular pattern of the donor leg is important to detect the small percentage of cases in which the peroneal artery is the dominant vessel

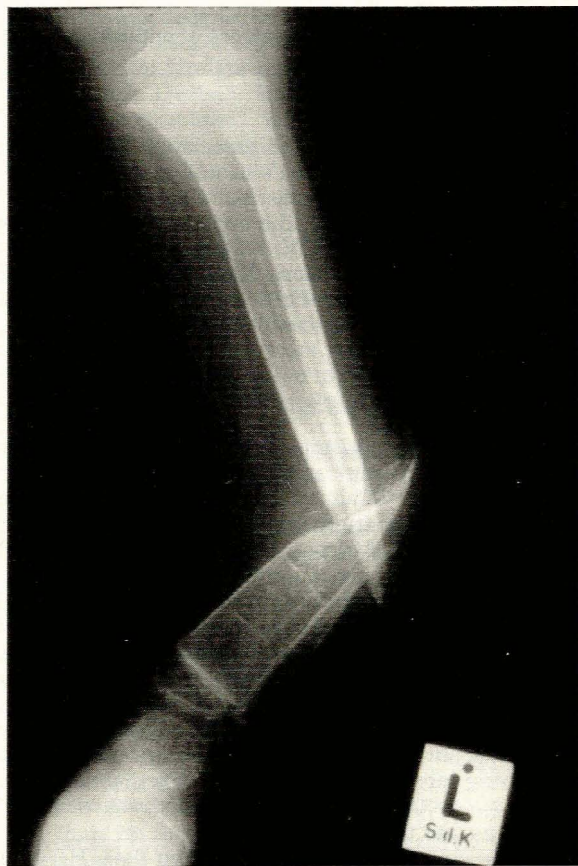

FIG. 1.  
Pseudarthrosis of the tibia and fibula.

in the leg.<sup>7</sup> In such cases the fibula should not be harvested, as interruption of the peroneal artery would compromise vascularity of the foot.

Arteriography usually shows vascular abnormalities in the area of the pseudarthrosis. Major vessels of the lower leg may be abnormally small or terminate in the region of the pseudarthrosis. These abnormalities will obviously influence the choice of recipient vessels.

Departments of Plastic and Reconstructive Surgery and Orthopaedic Surgery, University of Stellenbosch and Tygerberg Hospital, Tygerberg, CP

C. S. F. SMIT, M.B. CH.B.

B. J. v. R. ZEEMAN, B.SC., M.B. CH.B., M.MED.

W. J. WADE, M.B. CH.B., M.MED.

For fibular transfers two surgical teams operate simultaneously. The fibular graft is harvested by the team of plastic surgeons, while the orthopaedic surgeons resect the pseudarthrosis; the recipient vessels are located by a second team of plastic surgeons. In the second stage the orthopaedic surgeons fixate the graft and the donor wound is closed. The microsurgical anastomoses are then performed.

The artery was anastomosed to the anterior tibial artery and the donor vein to one of the venae comitantes in all cases. The diameter of the arteries ranged from 0,75 to 1,75 mm and the veins from 0,75 to 2,5 mm. End-to-end anastomoses with interrupted 10/0 nylon sutures were used throughout. The operation time was about 6 hours, with an average ischaemia time of 2 hours 20 minutes. The extra time taken to achieve orthopaedic stabilisation accounts for this rather long ischaemia time.

## Results

There were no immediate postoperative complications. Initial results were promising, but an analysis of the long-term results proved otherwise. In 3 cases there were 5 complications. In 1 case the fibular graft fractured, but fortunately healed uneventfully. Two cases had delayed union proximally, and the bones only united after non-vascularised bone grafting. Angulation deformities were present in 2 cases, and corrective osteotomies were needed. Nevertheless, 1 year after the initial procedure all patients are weight-bearing in a protective orthosis.

## Discussion

Over the years several operations have been proposed to achieve bony union in congenital pseudarthrosis, but the overall results are disappointing.<sup>8</sup> Except for the Farmer procedure<sup>9</sup> (composite skin and bone pedicle from the other leg), which has a reasonable union rate (53%), other procedures have unacceptably low rates of union: onlay grafts 12,5%, bypass procedures 7%, Sofield procedures 25%, sliding grafts 35%, bone allografts 17% and autogenous grafts 10%. Before modern techniques became available, an eventual amputation rate of around 40% was not unusual.

At present there are only three techniques in common use for treatment of this condition. Electro-stimulation can be used to promote union of nonvascularised bone grafts after the false joint only is resected. Success rates of up to 70% have been reported,<sup>10-12</sup> but this technique is rarely effective in severe cases. The Ilizarov technique involves distraction after a corticotomy, followed by pseudarthrosis compression with an external fixator. No bone is resected. The initial results of this technique have been encouraging,<sup>13</sup> although reported follow-up times are short.

It is well known that in congenital pseudarthrosis the bone is abnormal for a considerable distance from the visible defect.<sup>8</sup> In the previous two procedures minimal or no affected bone is resected. This is a disadvantage, as pathological bone remains behind and may cause recurrence of the pseudarthrosis.

If the false joint as well as affected bone is resected, a long bony defect results. A free vascularised bone graft is ideally suited to bridge this defect. A fibular graft has the additional advantage that it is straight. Success rates of 80 - 100% have been achieved with this method.<sup>14-16</sup>

Logic suggests that direct replacement of all diseased bone with healthy vascularised normal bone is the ideal. Why, in that case, did we have problems with 3 of our 4 patients? There appear to be two main reasons:

**Not all affected bone was resected.** It is pointless to put a well-vascularised graft in contact with diseased bone — sound healing is unlikely to occur. As it is impossible to say with certainty where the area of abnormal bone ends, it is better to err on the side of caution and resect bone generously.

**Inadequate fixation.** In the initial cases the proximal end of the fibular graft was impacted into the tibial medullary cavity, while the distal fibular end was slotted into the tibial cortex and fixed with circumferential dental wires. A Hoffman exoskeleton was added for final stabilisation (Fig. 2). This method, however, does not

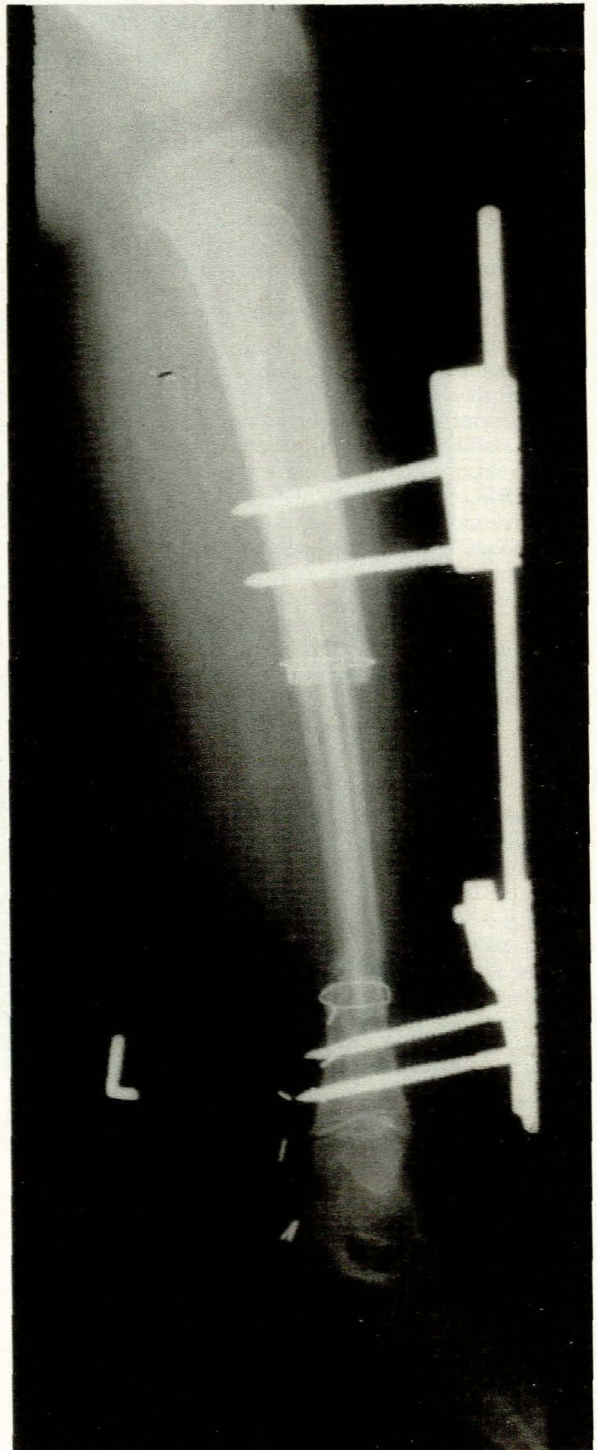
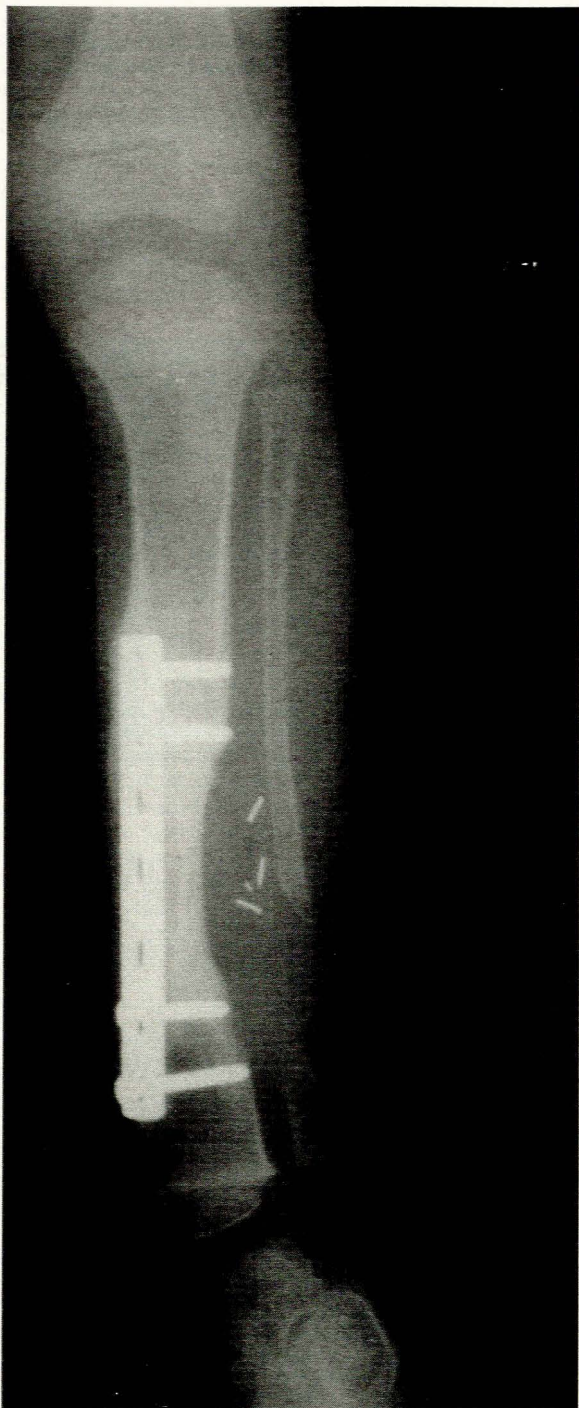

FIG. 2. Fibular graft stabilised with dental wires and Hoffman apparatus.



**FIG. 3.**  
**Fibular graft fixation with plate and screws. Note excellent callus formation.**

provide complete stability. We believe that the lack of truly rigid fixation was partly responsible for the problems in these patients. In the last case we discarded the Hoffman apparatus in favour of a plate and screws. This patient rapidly developed impressive callus formation (Fig. 3) and is doing well after 1 year.

### Conclusion

Critical review of our cases showed that rates of primary healing were disappointing, although eventually all patients achieved union. While our numbers are too small for statistical analysis, our experience leads us to make the following suggestions: (i) resect all potentially diseased bone; (ii) bridge the defect with a vascularised bone graft; and (iii) use rigid plate and screw fixation. We believe that these measures will ensure better results.

We would like to thank Dr A. Bruce-Chwatt for his help in preparing this manuscript.

### REFERENCES

1. Boyd HB. Pathology and natural history of congenital pseudarthrosis of the tibia. *Clin Orthop* 1982; **166**: 5-13.
2. Masserman AL, Peterson HA, Bianco AJ. Congenital pseudarthrosis of the tibia: a review of the literature and 52 cases from the Mayo Clinic. *Clin Orthop* 1974; **99**: 160-165.
3. Sofield HA. Congenital pseudarthrosis of the tibia. *Clin Orthop* 1971; **76**: 33-42.
4. McBryde AM jun, Stelling FH. Infantile pseudarthrosis of the tibia. *J Bone Joint Surg (Am)* 1972; **54**: 1354-1355.
5. McElhannon FM jun. Congenital pseudarthrosis of the tibia. *South Med J* 1975; **68**: 824-827.
6. Murray HH, Lovell WW. Congenital pseudarthrosis of the tibia: a long-term follow-up study. *Clin Orthop* 1982; **166**: 14-20.
7. Taylor GI, Wilson KR, Rees MD, Corlett RJ, Cole WG. The anterior tibial vessels and their role in epiphyseal and diaphyseal transfer of the fibula: experimental study and clinical applications. *Br J Plast Surg* 1988; **41**: 451-469.
8. Morrissy RT, Riseborough EJ, Hall JE. Congenital pseudarthrosis of the tibia. *J Bone Joint Surg (Br)* 1981; **63**: 367-375.
9. Farmer AW. The use of the composite pedicle graft for pseudarthrosis of the tibia. *J Bone Joint Surg (Am)* 1952; **34**: 591-600.
10. Bassett CAL, Caulo BSN, Kort J. Congenital 'pseudarthroses' of the tibia: treatment with pulsating electromagnetic fields. *Clin Orthop* 1981; **154**: 136-149.
11. Sutcliffe ML, Goldberg AAJ. The treatment of congenital pseudarthrosis of the tibia with pulsating electromagnetic fields: a survey of 52 cases. *Clin Orthop* 1982; **166**: 45-57.
12. Paterson DC, Simonis RB. Electrical stimulation in the treatment of congenital pseudarthrosis of the tibia. *J Bone Joint Surg (Br)* 1985; **67**: 454-462.
13. Fabry G, Lammens J, Van Melkebeek J, Stuyck J. Treatment of congenital pseudarthrosis with the Ilizarov technique. *J Pediatr Orthop* 1988; **8**: 67-70.
14. Chen CW, Yu ZJ, Wang Y. A new method of treatment of congenital tibial pseudarthrosis using free vascularized fibular graft: a preliminary report. *Ann Acad Med Singapore* 1979; **8**: 465-473.
15. Pho RWH, Levack B, Satku K, Patradul A. Free vascularised fibular graft in the treatment of congenital pseudarthrosis of the tibia. *J Bone Joint Surg (Br)* 1985; **67**: 64-70.
16. Dorman JP, Krajbich JJ, Zuker R, Demuynek M. Congenital pseudarthrosis of the tibia: treatment with free vascularized fibular grafts. *J Pediatr Orthop* 1990; **10**: 623-628.