

## CASE REPORT

# Adenolipomas: a case series of 16 patients over 5 years

Juanita Parnis Luca Borg, Francis X. Darmanin

## INTRODUCTION

An adenolipoma is a benign, rare variant of a lipoma and is histologically very similar to a lipoma but contains eccrine glands amongst the mature adipose tissue. According to our knowledge, this case series of adenolipomas, is the largest one in the literature. The aim is to increase awareness about this variant of lipoma.

## METHOD

The data was collected retrospectively from the histopathology department and patients' notes.

## RESULTS

We had a total of 16 cases of adenolipomas between 2013 and 2017 in our hospital. 75% of the patients were being managed by General Surgeons. 88% of them occurred in female patients and the patients' age varied between 15 and 64 years. The most common location of adenolipomas was the thighs and the largest diameter of the histology specimen varied between 15 and 100mm. 31% were encapsulated, 25% had apocrine glands present and 6% had myxoid changes. None of them had mast cells present. No recurrences were documented.

## CONCLUSION

It is a benign lesion and awareness amongst pathologists is imperative so that it can be identified histologically.

**Juanita Parnis\*** MD MRCS EBOPRAS  
Plastic Surgery and Burns Unit  
Mater Dei Hospital,  
Msida Malta  
[juanita.parnis@gov.mt](mailto:juanita.parnis@gov.mt)

**Luca Borg** MD  
Mater Dei Hospital,  
Msida Malta

**Francis X. Darmanin** MD FRCSI  
MMed. Sci. DSM  
Plastic Surgery and Burns Unit  
Mater Dei Hospital,  
Msida Malta

\*Corresponding author

---

## INTRODUCTION

---

An adenolipoma is a benign, rare variant of a lipoma and is histologically very similar to a lipoma but contains eccrine glands amongst the mature adipose tissue.<sup>1</sup> It was initially described by Hitchcock et al in 1993.<sup>2</sup> This was followed by another case series by Ait-Ourhrouil and Grosshans in 1997 where they disagreed about the name. They recommended using the term "per-sudoral lipoma" instead, because it originated from the adipose tissue itself without proliferation of the eccrine glands.<sup>3</sup> According to our knowledge, this case series of adenolipomas, is

the largest one in the literature. The aim is to increase awareness about this variant of lipoma.

---

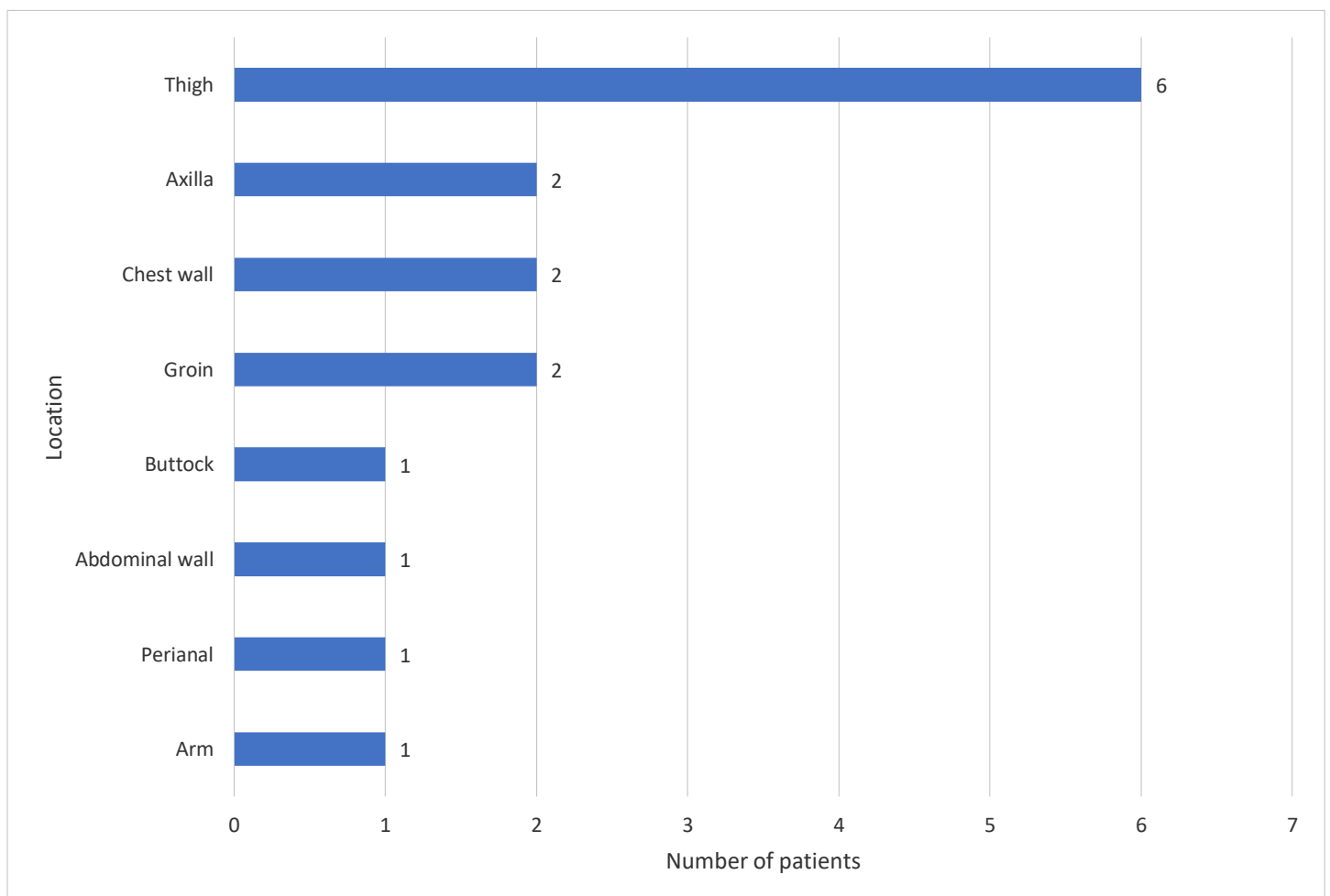
## METHOD

---

The data was obtained retrospectively from the histopathology department at Mater Dei Hospital, Malta, after approval from the Data Protection Department. All the adenolipomas from the year 2013 to 2017 were included. The data was obtained from the histopathology reports and patients' notes and inputted into an excel sheet.

---

**Figure 1** The location of the adenolipomas excised



**Table 1** Summary of the data for the 16 cases of adenolipoma

	Year	Age	Gender	Site	Size	Encapsulation	Myxoid changes	Mast cells	Apocrine glands	Specialty
<b>1</b>	2013	15	F	Anterior Abdominal Wall	100 x 17 x 10 mm	No	No	No	No	Paediatric Surgery
<b>2</b>	2015	40	M	Left arm	60 x 40 x 20mm	Yes	No	No	No	General Surgery
<b>3</b>	2014	40	F	Right buttock	55 x 30 x 25mm	No	Yes	No	No	General Surgery
<b>4</b>	2015	61	F	Perianal area	45 x 45 x 10mm	No	No	No	No	General Surgery
<b>5</b>	2013	36	F	Left chest wall	45 x 45mm	Yes	No	No	No	General Surgery
<b>6</b>	2014	41	F	Right chest wall	40 x 39 x 12mm	Yes	No	No	No	General Surgery
<b>7</b>	2014	50	F	Thigh	40 x 35 x 15mm	No	No	No	No	General Surgery
<b>8</b>	2013	48	F	Right axilla	35 x 25 x 10mm	No	No	No	Yes	General Surgery
<b>9</b>	2016	36	F	Left thigh	30 x 15 x 15mm	No	No	No	No	General Surgery
<b>10</b>	2013	61	F	Right thigh	25 x 25 x 5mm	No	No	No	No	Vascular Surgery
<b>11</b>	2013	51	F	Left thigh	26 x 18 x 5mm	No	No	No	No	General Surgery
<b>12</b>	2014	33	F	Right axilla	25 x 20 x 5mm	No	No	No	Yes	General Surgery
<b>13</b>	2014	38	F	Left groin	20 x 13 x 8mm	Yes	No	No	Yes	Plastic Surgery
<b>14</b>	2014	64	M	Left groin	15 x 10 x 6mm	No	No	No	Yes	General Surgery
<b>15</b>	2014	28	F	Thigh	15 x 10 x 3mm	No	No	No	No	Plastic Surgery
<b>16</b>	2017	37	F	Right thigh	N/A	Yes	No	No	No	General Surgery

---

## RESULTS

---

In 5 years, we had a total of 16 histology proven adenolipomas in our hospital. 75% of them ( $n=12$ ) were diagnosed in 2013 and 2014. 88% ( $n=14$ ) of adenolipomas were in female patients and 12% ( $n=2$ ) were in male patients. 75% of the patients ( $n=12$ ) were being managed by General Surgery, 13% ( $n=2$ ) were managed by Plastic Surgery, 6% ( $n=1$ ) was under the care of Vascular Surgery and the last 6% ( $n=1$ ) was being managed by Paediatric Surgery. The age of the patients varied from 15 to 64 years. 38% ( $n=6$ ) of the adenolipomas occurred in the thighs. Other areas included the axillae, arms, trunk, groin, buttock, perianal area as shown in figure 1. The largest diameter of the histology specimen varied from 15mm to 100mm. In one specimen, the size was not specified in the histology report. 31% ( $n=5$ ) of the adenolipomas were encapsulated, 25% ( $n=4$ ) had apocrine glands present, 6% ( $n=1$ ) had myxoid changes and none had mast cells present. No recurrences were documented. A summary of the data is shown in table 1 in decreasing adenolipoma size.

---

## DISCUSSION

---

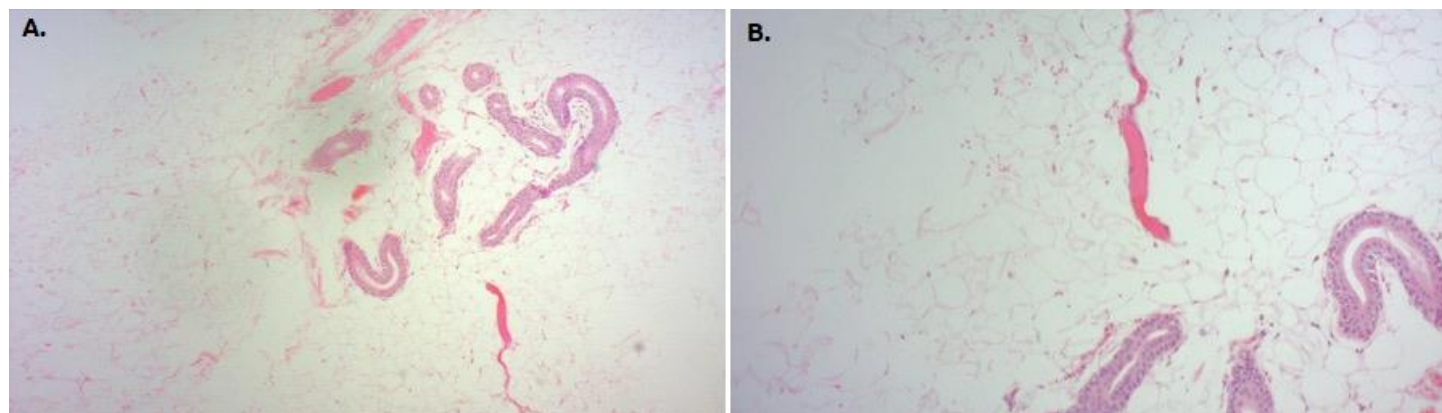
Adenolipomas typically present as a soft, slow-growing, painless lump, commonly arising in the thighs, as shown in our case series, where 6 of our 16 patients had an adenolipoma in the thigh. However, it is also documented that they can arise in the thyroid gland, parathyroid, bronchus, colon, lip, liver, nose, female external genitalia and breast.<sup>4-13</sup> The management and prognosis of an adenolipoma mirrors that of a typical lipoma.

The age range is said to be between 25 and 75 years of age but our case series shows a wider spectrum ranging from 15-75 years.<sup>14</sup> We document the size range to be between 1.5 and 10cm compared to the case series by Amir et al where they found it to be between 1 and 6cm.<sup>1</sup>

Macroscopically, they appear to be soft, lobulated, yellow masses. Microscopically, they consist of lobules of adipose tissue that are larger than those of subcutaneous tissue. Dispersed amongst these adipocytes, are eccrine glands and ducts which may show epithelial hyperplasia, cystic duct dilatation and squamous or clear cell metaplasia, as shown in figures 2(a) and 2(b).<sup>15</sup> Amir et al document that apocrine glands are rarely seen.<sup>1</sup> In contrast, 25% of our lesions had apocrine glands present histologically. Most reported cases of adenolipomas are encapsulated.<sup>1</sup> However, in our series, only 31% of the lesions had a capsule when compared to the 9% of encapsulated adenolipomata described in a case series by Amir et al.<sup>1</sup>

Misdiagnosis of adenolipomas is possible because specimens are usually presented to the Histopathologist in a fragmented manner. This makes it more difficult to determine the location of the eccrine glands. Eccrine glands in the periphery of the lesion, makes it more challenging to distinguish between glands originating from the tumour itself and normal glands lying adjacent to the tumour. It is also important that pathologists are aware that this variant exists, to be able to identify it as such.<sup>1</sup> The incidence of adenolipomata may be underestimated as not all lipomata are sent for histological analysis once they are removed.

**Figure 2** Both photos show sheets of mature adipocytes with occasional embedded glandular structures lined by a bilayer of epithelial cells, in keeping with eccrine glands. H&E stain. (a) x100 and (b) x200 magnification.



### CONCLUSION

An adenolipoma is a rare variant of a lipoma that contains eccrine glands surrounded by mature adipose tissue. It is a benign lesion and awareness amongst pathologists is imperative so that it can be identified histologically.

### ACKNOWLEDGEMENTS

We would like to thank Dr Alexandra Betts, Consultant Histopathologist at Mater Dei Hospital, Malta, for her time, in order to obtain the data for this case series.

### REFERENCES

1. Amir R, Sheikh S. Adenolipoma of the Skin: A Report of 11 Cases. *Case Rep Dermatol*. 2018 Apr 5;10(1):76-81.
2. Hitchcock MG, Hurt MA, Santa Cruz DJ. Adenolipoma of the skin: A report of nine cases. *Journal of American Academy of Dermatology*. 1993;29(1):82-85.
3. Ait-Ourhrouil M, Grosshans E. Peri-sudoral lipoma. *Ann Dermatol Venerol*. 1997;124(12):845-8.
4. Borges A, Catarino A. Case 53: Adenolipoma of the thyroid gland. *Radiology*. 2002. Vol. 225, No. 3.
5. Gupta A, Mathur SK, Batra C, Gupta A. Adenolipoma of the thyroid gland. *Indian J Pathol Microbiol*. 2008;51:521-2.
6. Geelhoed GW. Parathyroid adenolipoma: clinical and morphological features. *Surgery*. 1982 Nov;92(5):806-10.
7. Cherian SV, Ocazionez D, Ambelil M, Estrada-Y-Martin RM. Adenolipoma of the Bronchus. A Rare Entity. *American Journal of Respiratory and Critical Care Medicine*. 2018. Vol. 197, No. 4.
8. Di Tommaso L, Damiani S. Colonic adenolipoma with lipoblast-like cells. *Histopathology*. 2004. 44(4):400-401.
9. Ide F, Mishima K, Saito I. Adenolipoma of the lip. *Br J Dermatol*. 2003 Mar;148(3):606-7.
10. Kurdziel JC, Stines J, Parache RM, Chaulieu C. Adenolipoma of the liver. A unique case with ultrasound and CT patterns. *Eur J Radiol*. 1984 Feb;4(1):45-46.
11. Orhan KS, Karaaltın MV, Demirel T, Polat B, Basaran B. Adenolipoma of the nose: a case report. *Kulak Burun Bogaz Ihtis Derg*. 2010. Sep-Oct;20(5):264-6.
12. Pantanowitz L, Henneberry JM, Otis CN, Zakhary M. Adenolipoma of the external female genitalia. *Int J Gynecol pathol*. 2008. Apr;27(2):297-300.

13. Ram D, Selvakumar VP. Adenolipoma of the Breast: A Clinicoradiological Entity and Pathologist's Dilemma! J Clin Diagn Res. 2016 Jun;10(6):XD03-XD04.

14. Agua CD, Felipo, F. Adenolipoma of the skin. 2004. Dermatology Online Journal, 10(2).

15. Lee HS, Song YS. Adenolipoma of the Skin Arising at Neck Region. Korean J Pathol. 2012;46(6):587-589.