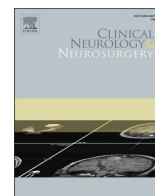


Contents lists available at ScienceDirect

Clinical Neurology and Neurosurgery

journal homepage: www.elsevier.com/locate/clineneuro

Spinal meningiomas: Treatment outcome and long-term follow-up

L.E. Kwee^a, B.S. Harhangi^b, G.A. Ponne^b, J.M. Kros^c, C.M.F. Dirven^d, R. Dammers^{b,*}^a Department of Neurosurgery, Noordwest Ziekenhuisgroep, Alkmaar, the Netherlands^b Department of Neurosurgery, Brain Tumor Center, Erasmus MC, Rotterdam, the Netherlands^c Department of Pathology and Laboratory for Tumor Immuno-Pathology, Brain Tumor Center, Erasmus MC Cancer Institute, Erasmus MC, Rotterdam, the Netherlands^d Department of Neurosurgery, Brain Tumor Center, Erasmus MC Cancer Institute Erasmus MC, Rotterdam, the Netherlands

ARTICLE INFO

Keywords:

Spinal meningioma
Surgical outcome
Functional outcome
Long-term follow-up

ABSTRACT

Background: Spinal intradural tumors can be classified as intradural extramedullary or intramedullary tumors. Spinal meningiomas are among the most frequent intradural, extramedullary tumors (IDEMs), representing 12 % of all meningiomas and 25–45 % of all intradural spinal tumors.

Objective: To evaluate postoperative outcome, defined by mortality, tumor recurrence and modified Rankin Scale in patients with spinal meningiomas. Furthermore, to identify factors related to these outcome measures and define possible prognosticators.

Methods: A large single center retrospective analysis of 166 consecutive spinal meningioma patients during a 29-year period (1989–2018).

Results: Female to male ratio was 5.15 to 1. Of all 166 resected tumors, 159 were WHO grade I and seven were WHO grade II. Histopathologically, the psammomatous type was most common (42.8 %). The thoracic region was the most frequent location (71.1 %), followed by cervical and lumbar locations. A complete resection (Simpson I–III) was achieved in 88.7 %. In 12 cases (7.2 %) recurrences of a spinal meningioma occurred after an interval of 0.70–13.78 years. Postoperative complications consisted of CSF leakage and wound healing problems. Three patients died of direct postoperative complications (1.8 %), nine patients died in follow-up due to unrelated causes. Post-operative complications were related to the overall outcome ($p = 0.029$). Clinical outcome showed improvement in 117 patients out of 148 (79.1 %) according to modified Rankin Scale; 24 patients remained stable and 7 patients deteriorated. Patients with pre-existing bladder/bowel problems and incomplete resections had higher chance of recurrences. Younger patients also had a higher recurrence rate. Follow-up ranged from 0 to 23 years, median of 0.77 years, most were discontinued after 2 years.

Conclusions: The primary treatment of spinal meningiomas remains surgery. Complete resection of spinal meningiomas is achieved in most of the cases, however preserving and improving neurological status has priority over complete tumor resection. Morbidity and mortality is relatively low. Longer follow-up periods are recommended, since recurrences can occur after 10–15 years.

1. Introduction

Spinal tumors are classified as either extradural or intradural in relation to the spinal meninges. Intradural tumors can be further subcategorized into extramedullary (IDEM) or intramedullary spinal cord tumors (IMSCT). Meningiomas are among the most frequent IDEMs, representing about 12 % of all meningiomas [30] and 25 %–45 % of all

intradural spinal tumors [13,46,6]. Meningiomas are often benign, slow-growing tumors with a peak age incidence between 40 and 70 years and a male:female ratio of 1:4 [38].

Their distribution along the spinal axis varies whereby the majority (67–84 %) of spinal meningiomas are located within the thoracic region [2,11,45]. The incidence of spinal meningiomas in the cervical and lumbar region is 14–27 % and 2–14 %, respectively [11].

Abbreviations: ASA, American Society of Anesthesiologists; CSF, cerebral spinal fluid; EMG, electromyography; IDEM, intradural, extramedullary tumors; IMSCT, intramedullary spinal cord tumors; IONM, intraoperative neuromonitoring; IQR, interquartile range; KPS, Karnofsky Performance Score; MRI, Magnetic resonance imaging; mRS, modified Rankin Scale; SD, standard deviation; WHO, World Health Organization.

* Correspondence author at: Department of Neurosurgery, Erasmus MC, Brain Tumor Center, and Erasmus MC Sophia Children's Hospital, Dr. Molewaterplein 40, NA-2112 PO Box 2040, 3000 CA Rotterdam, the Netherlands.

E-mail address: r.dammers@erasmusmc.nl (R. Dammers).

<https://doi.org/10.1016/j.clineuro.2020.106238>

Received 1 June 2020; Received in revised form 31 August 2020; Accepted 12 September 2020

Available online 18 September 2020

0303-8467/© 2020 The Authors. Published by Elsevier B.V. This is an open access article under the CC BY license (<http://creativecommons.org/licenses/by/4.0/>).

The primary treatment option is surgical resection with the goal to achieve complete tumor removal and spinal cord decompression, avoiding further neurological deterioration. [32] Outcomes are mostly favourable, however not many studies have been published with respect to post-operative outcome. Because of further developing minimally invasive techniques there is a need for larger cohorts of patients that were treated via microsurgical open techniques for future comparison.

During a 29-year period from 1989 to 2018, 166 patients with spinal meningiomas were operated at our institution via an open microsurgical approach. In this study, we retrospectively analyzed this cohort of patients over a long time period. We evaluated mortality, tumor recurrence, and neurologic function and searched for possible factors related to outcome and recurrence.

2. Patients and methods

A consecutive cohort of 166 patients who had undergone open microsurgical treatment for spinal meningioma at the Erasmus Medical Center from January 1989 until December 2018 was retrospectively reviewed. These patient data were extracted from our institutional meningioma database.

Demographics, including patient age, sex, previous medical history, ASA classification, presenting symptoms, postoperative complications, and length of hospital stay were extracted from the database. Furthermore, the tumor site as well as dural attachment was noted. Perioperative characteristics, such as perioperative complications and Simpson grade of resection were scored from the operative report. Surgery was performed through microsurgical techniques using an operating microscope. X-ray localization was used in all patients and when needed intraoperative ultrasound imaging was used for localization. Intraoperative neuromonitoring (IONM) was available since 2009, the use of which was extracted from the operative report.

The 4th edition WHO classification of tumors of the central nervous system was used to provide histological characterization [22]. Before the WHO classification was introduced, meningiomas were classified according to Jääskeläinen [16]. For the purpose of the present study, Jääskeläinen type 1 and 2 meningiomas were considered benign meningiomas according to the WHO classification. Recurrence was defined as reoperation for tumor recurrence and clinical outcome was evaluated through pre- and postoperative modified Rankin scores [44], where the functional neurological condition of patients was described in their medical files and interpreted by the first author. Alternatively, the modified Rankin scores were also dichotomized according to Nurick criteria where independent ambulation is of importance [29]. Favourable outcome was as such classified as mRS 0–3 and unfavourable as mRS 4–5.

In the earlier years, there was no standard follow-up scheme. Patients were generally seen in the outpatient clinic some six weeks after discharge. Neurological status determined further follow-up and imaging. Since about 2005 a postoperative MRI is mandated at three months and again further follow-up depended on this imaging and neurological status. From 2010 on a more strict protocol is followed in which MRI is performed at 3 and 6 months, 1, 2, 5, and 10 years after surgery, depending on the extent of resection and WHO grade.

3. Statistical analysis

All data were analyzed with the commercially available statistical software package SPSS® Statistics version 22 (IBM Corp.©). Continuous variables were univariately compared using a Student's T-test for parametric data and a Mann-Whitney *U* test for non-parametric data and reported as mean values \pm standard deviations (SD). Normal distribution was tested with Kolmogorov-Smirnov test for skewness and kurtosis. Dichotomous and nominal variables were compared with Chi-square and Fisher's exact test, where applicable, and presented as absolute numbers and percentages. P-values <0.05 were considered statistically

significant.

As outcome measures, death, tumor recurrence and postoperative modified Rankin scores were used. In order to analyze factors relating to the outcome the variables were initially explored univariately as described above. Variables for which there was a high probability of association with the outcome ($p < 0.20$) were considered for the final multivariate regression model. Backward stepwise logistic regression was used for this purpose and odds ratios (OR) and 95-percent confidence intervals (95 %-CI) and p-values are presented. To exclude the possible early effects of surgery, regression analysis was done on all patients and on patients with a follow-up of more than 0.5 years ($n = 90$).

Kaplan-Meier survival analysis was used to estimate the risk of recurrence over time.

4. Results

4.1. Patient and tumor characteristics

In this retrospective analysis 166 consecutive patients were included with a median follow-up of 0.77 years per patient (range; 0–23 years, IQR 4.6 years).

Table 1 summarizes preoperative patient and tumor characteristics. Of 166 patients, 139 were female (83.7 %) and 27 were male (16.2 %). The pathology report showed benign meningioma in 159 patients (95.8 %) and 7 atypical meningiomas (4.2 %). Histologically, the psammomatous type meningioma was the most frequent (42.8 %), followed by transitional (28.9 %) and meningothelial/syncytial (14.5 %) meningioma. The most common location was the thoracic spinal canal (71.1 %). The dural attachment of the spinal meningiomas was predominantly lateral (62.9 %). Information about tumor size was only available in 55 cases, with a mean meningioma volume of 2.1 ± 1.2 mL, and a minimum and maximum length of around 10 and 50 mm, respectively. Presenting symptoms were mostly motor deficits (84 %), followed by sensory deficits (63.1 %), pain (27.6 %) and bladder/bowel problems (23.3 %).

4.2. Surgical outcome

Of 166 patients, data about Simpson grade resection was found in 159 (95.8 %) patients. In 141 patients (88.7 %) a complete resection was achieved (Simpson grade I-III). In 18 patients (11.3 %) a subtotal resection was achieved. In the cervical, thoracic and lumbar spine, 2 (7.4 %), 13 (11.5 %) and 3 (33.3 %, $p = 0.067$) incomplete resections were observed, respectively. IONM was used in 13 of 65 patients (20 %) since its institution in 2009. Lesions with a ventral attachment were more commonly operated on with IONM, although not significantly ($p = 0.123$). Some perioperative problems that were encountered were hemostasis problems and in one patient the wrong level was operated on at first and during operation corrected for the right level.

Forty-one postoperative complications occurred in 35 patients (21.7 %; Table 2). Seven patients had CSF leakage, which required temporary external lumbar drainage. Six patients had wound healing problems, requiring antibiotics. Other complications in this study group were pneumonia, pulmonary embolus, increased level of pain experience at the surgical site and worsening of neurologic condition, amongst others.

4.3. Clinical outcome

Of 161 patients, 85 patients had a preoperative favourable modified Rankin Score (mRS 0–3) and 76 patients had an unfavourable mRS score (mRS 4–5). Postoperatively, in 162 patients, there was a favourable mRS score in 149 patients and unfavourable score in 13 patients of which 12 patients died in the follow-up period. When comparing preoperative and postoperative mRS scores (not including total deaths) 117

Table 1
Patient demographics and perioperative and tumor characteristics.

Patient demographics	n = 166
Sex (male : female)	27 : 139 = 1 : 5.15
Age in years (mean ± SD; range)	66.0 ± 13.5; 13.5–88.7
Medical history (%)	24/161 (14.9)
Malignancy	24/161 (14.9)
Cardiovascular	49/161 (30.4)
Hypertension	16/162 (9.9)
Diabetes	18/161 (11.2)
Respiratory disease	2/163 (1.2)
Neurofibromatosis	
ASA physical status (%)	18/130 (13.8)
1 (healthy)	86/130 (66.2)
2 (mild systemic disease)	26/130 (20)
3 (severe systemic disease)	
Presenting symptoms (%)	137/163 (84.0)
Motor	103/163 (63.2)
Sensory	45/163 (27.6)
Pain	38/163 (23.3)
Bladder and/or bowel complaints	
Preoperative modified Rankin score (mRS; %)	85/161 (52.8)
Favourable (mRS 0–3)	76/161 (47.2)
Unfavourable (mRS 4–5)	
Tumor characteristics	
Tumor site (%)	5 (3)
Cranio-cervical	27 (16.3)
Cervical	4 (2.4)
Cervicothoracic	118 (71.1)
Thoracic	4 (2.4)
Thoracolumbar	8 (4.8)
Lumbar	
Dural attachment	21/151 (13.9)
Dorsal	35/151 (23.2)
Ventral	95/151 (62.9)
Lateral	
WHO classification (%)	159 (95.8)
Benign (WHO I)	7 (4.2)
Atypical (WHO II)	
Perioperative characteristics	
Blood loss in mL (mean ± SD; range)	Mean 655 ± 560; range 150 – 3000
Intraoperative neuromonitoring (%)	13/65 (20)
Simpson resection grade (%)	33/159 (20.8)
I (complete)	96/159 (60.4)
II (complete and coagulation of dural attachment)	12/159 (7.5)
III (complete without resection or coagulation dura)	18/159 (11.3)
IV (subtotal resection)	
Perioperative complication (%)	8/162 (4.9)
Postoperative complication (%)	35/161 (21.7)
Length of hospital stay in days (mean ± SD; range)	12.3 ± 8.2; 2 – 55
Follow-up	
Modified Rankin score (mRS) at latest follow-up (%)	142/161 (88.2)
Favourable (mRS 0–3)	7/161 (4.3)
Unfavourable (mRS 4–5)	12/161 (7.5)
Dead (mRS 6)	
Recurrent spinal meningioma for which reoperation(%)	12 (7.2)
Duration until reoperation in years (mean ± SD; range)	3.4 ± 4.7; 0.1–23.1

ASA American Society of Anesthesiologists.

mRS modified Rankin Score, mRS 0: no symptoms, mRS 1: no significant disability, mRS 2: slight disability, mRS 3: moderate disability, mRS 4: moderately severe disability, mRS 5: severe disability, mRS 6: dead.

WHO World Health Organization.

Simpson grade I: macroscopically complete resection with excision of dural attachment and abnormal bone, Simpson grade II: macroscopically complete resection with coagulation of dural attachment, Simpson grade III: macroscopically complete resection without resection or coagulation of its attachment, Simpson grade IV: subtotal resection, Simpson grade V: simple decompression of tumor.

patients (79.1 %) showed clinical improvement, 24 patients (16.2 %) remained stable and 7 patients showed deterioration in their mRS (4.7 %); **Table 3**. Among the 7 deteriorated patients are 3 patients that died of complications directly postoperatively, pertaining a surgical mortality of 1.8 % (**Table 2**). One of these three is an 88-year old patient with a

Table 2
Postoperative complications after spinal meningioma surgery.

Complication	N =
CSF leakage	7
ELD/EVD needed	3
Postoperative wound infection	6
Resulting in sepsis	1
Skin defect needing split skin graft	1
Respiratory insufficiency	1
Pulmonary bleeding	1
Mucous plug	2
Pneumonia	
Pulmonary embolus	2
Hyperglycemia due to corticosteroid use	3
Difficult to treat (wound) pain	3
Urinary tract infection	3
Worsening of neurological status	2
Increased paresis	1
Brown-Séquard	
Syrinx development	1
Myelum edema with hydrocephalus and secondary meningitis	1
Ileus	2
Cardiac decompensation	2
Epileptic seizure	1
Hypertension	1
Hypotension	1

Postoperative complications occurring in 35 patients (21.7 %) after surgery for spinal meningioma.

CSF: cerebrospinal fluid. ELD: external lumbar drainage. EVD: external ventricular drainage.

Table 3
Pre- and post-operative modified Rankin scores at initial follow-up.

mRS_preop	mRS_postoperative						
	mRS 0	mRS 1	mRS 2	mRS 3	mRS 4	mRS 5	mRS 6
mRS 0							
mRS 1	0	2	3	0	0	0	0
mRS 2	1	6	7	7	1	0	0
mRS 3	5	13	20	15	3	1	1
mRS 4	0	4	15	49	5	0	2
mRS 5	0	0	0	1	0	0	0
mRS 6							

Crosstable with the preoperative mRS score and the postoperative mRS scores. mRS 0: no symptoms, mRS 1: no significant disability, mRS 2: slight disability, mRS 3: moderate disability, mRS 4: moderately severe disability, mRS 5: severe disability, mRS 6: dead.

pre-operative KPS of 50 who developed pulmonary bleeding post-operatively followed by hematemesis and respiratory insufficiency. Another 88-year old patient developed a wound infection, followed by sepsis, eventually succumbing to pulmonary embolism. The third patient, 61 years old, developed hydrocephalus with spinal cord edema, for which an external ventricular shunt was placed. This patient eventually succumbed due to respiratory insufficiency.

Nine patients died during follow-up to causes unrelated to the spinal meningioma.

Of the patients that deteriorated after surgery one had a Brown-Séquard syndrome, and another showed worsening of the pre-existing paresis. Two other patients developed complications likely related to co-morbidities; One had a wound healing disorder resulting in a defect requiring a split-skin-graft and another also had wound healing problems and ileus in the presence of metastasized prostate cancer. Thus, at final follow-up 117 patients (73.1 %) showed improvement, 24 patients (15 %) remained stable, and 19 patients (11.8 %) deteriorated, which included 12 deaths (**Table 4**).

Table 4
Pre- and post-operative modified Rankin scores at final follow-up.

mRS_preop	mRS_postoperative						
	mRS 0	mRS 1	mRS 2	mRS 3	mRS 4	mRS 5	mRS 6
mRS 0							
mRS 1	0	4	0	0	0	0	0
mRS 2	1	12	6	3	0	0	0
mRS 3	4	13	21	12	3	1	4
mRS 4	0	5	16	44	2	0	8
mRS 5	0	0	0	1	0	0	0
mRS 6							

Crosstable with the preoperative mRS score and the postoperative mRS scores. mRS 0: no symptoms, mRS 1: no significant disability, mRS 2: slight disability, mRS 3: moderate disability, mRS 4: moderately severe disability, mRS 5: severe disability, mRS 6: dead.

4.4. Favourable vs. unfavourable factors

In univariate analysis, presenting symptoms had no relation to outcome overall (motor deficits, $p = 0.312$; sensory deficits, $p = 0.642$; pain, $p = 0.281$; bladder/bowel deficits, $p = 0.776$). A non-significant more favourable outcome was observed in younger patients ($p = 0.087$) and patients with postoperative complications had a higher chance on an unfavourable outcome ($p = 0.054$). Although non-significant, a higher preoperative KPS related to a favourable outcome ($p = 0.093$). Meningioma volume was not related to outcome ($p = 0.255$). In multivariate analysis, only postoperative complications, a history of cardiovascular disease, and surgery in the years since the introduction of IONM (2009) were correlated to outcome (Table 5).

When only patients with a follow-up longer than 0.5 years were

Table 5
Logistic regression model.

Logistic regression Outcome mRS 0-3	B	p=	OR	95% CI
Surgery since 2009	1.409	0.037	4.094	1.090-15.377
Cardiovascular history	1.598	0.017	4.945	1.335-18.318
Postoperative complications	-1.221	0.029	0.295	0.099-0.880
Logistic regression Outcome mRS 0-3 with a follow-up > 0.5 years				
Surgery since 2009	2.177	0.061	8.821	0.901-86.333
Male sex	-2.530	0.003	0.080	0.015-0.416
WHO II (atypical meningioma)	-2.920	0.013	0.054	0.005-0.541
Logistic regression Recurrence				
Presenting bladder/bowel problems	1.588	0.029	4.893	1.181-20.274
Simpson grade IV resection	2.124	0.008	8.362	1.757-39.794
Age	-0.62	0.006	0.940	0.900-0.982

Variables with p-values <0.05 were statistically significant. These variables were univariately analyzed in order to analyze relation to outcome. Variables with high probability of association with outcome ($p < 0.20$) were included for final multivariate logistic regression model.

B: coefficient for the constant, OR: Odds ratio, CI: Confidence Interval.

included, only male sex and a previous history of malignancy showed a relation to an unfavourable outcome at last follow-up, $p = 0.011$ and $p = 0.065$ respectively. In multivariate analysis, only male sex and the diagnosis of an atypical meningioma proved related to an unfavourable outcome at last follow-up. Also, surgery since 2009 had a positive effect on outcome (Table 5), although non-significant ($p = 0.061$).

4.5. Recurrence

Recurrences occurred in 12 cases (7.2 %), of which those with an incomplete resection, i.e. Simpson grade IV, had a significantly higher chance of recurrence (OR 8.362, 95 %-CI 1.757–39.794, $p = 0.008$). Of the 12 cases that recurred 2 were Simpson grade I (6.1 % of 33 patients), 5 grade II (5.2 % of 96 patients) and 5 grade IV resections (27.8 % of 18 patients). None of the recurrences had dorsal dural attachments. Mean patient age at time of surgery was 66 ± 13.5 years, and a younger age related to meningioma recurrence. (OR 0.940, 95 %-CI 0.900–0.982, $p = 0.006$). Mean duration to reoperation was 5.2 ± 4.4 years in the present study. Also, patients presenting with bladder/bowel problems had a significantly higher chance of recurrence (OR 4.893, 95 %-CI 1.181–20.274, $p = 0.029$). Interestingly, an atypical meningioma did not show a significantly higher chance of recurrence on univariate analysis ($p = 0.082$) and did not remain in the multivariate analysis. Only one of the six patients with an atypical meningioma received radiotherapy. Follow-up periods in those patients ranged from 0.02–15 years.

With Kaplan-Meier survival analysis an overall recurrence-free survival at 5, 10, and 15 years of 91.0 %, 75.9 %, and 59.0 % was observed (Fig. 1). For complete resection (Simpson I-III), 10 and 15-year recurrence free survival was 86.4 and 67.2 %. For incomplete resection this was 21.9 % for both 10 and 15-year recurrence free survival. Because of the low numbers of WHO II meningiomas, life table analysis according to tumor grading was not applicable.

5. Discussion

We report the surgical outcomes of a retrospective cohort of 166 consecutive patients with spinal meningiomas treated through an open microsurgical approach at our institution during a 29-year period. In this regard, albeit that it is one of the largest study cohorts presented, the main limitation of this study is that it has a retrospective nature.

5.1. Presenting signs and symptoms

Most patients were referred to our institution for surgical treatment

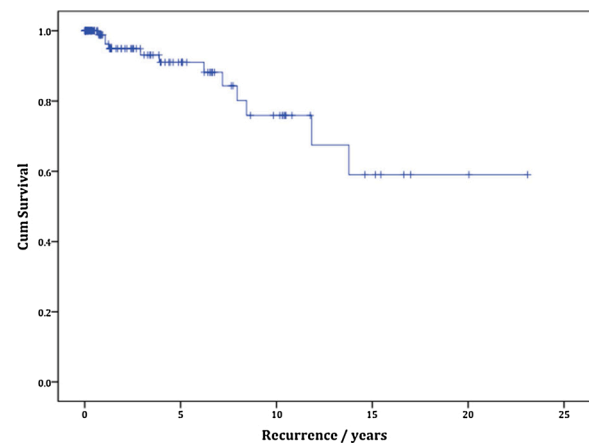


Fig. 1. Kaplan-Meier survival analysis of overall recurrence-free survival. SE = standard error of the mean. The + signs illustrate the patients that were censored from the analysis because of end of follow-up.

because of progressive neurological deficits, mostly motor deficits. In literature, however, the first symptoms patients with spinal meningiomas present with are often reported to be local and radicular pain [43, 24]. In a series by Sandalcioğlu et al. 39 % of patients were unable to walk at first presentation [34]. Klekamp and Samii reported that 59 % of 117 patients presented with gait ataxia as predominating neurological symptom [19]. Twenty percent complained of pain and 16 % of motor weakness. Solero et al. described a series of 174 patients, of which 42 % presented with pain, 33 % complained of motor deficits, and 25 % complained of sensory deficits [38]. In the most recent large cohort study, encompassing 173 patients, 32 % and 33 % of patients complained of motor deficits and pain, respectively, as symptom onset [31].

5.2. Tumor characteristics

In the present study almost all spinal meningiomas were benign, WHO grade I. Information about tumor size was only available in 55 cases, with a mean meningioma volume of 2.1 ± 1.2 mL. The majority was located in the thoracic spine region, which is concurrent with described literature. Reportedly, in women, spinal meningiomas occur in 80 % in the thoracic region [38,21,11,35]. In men however, spinal meningiomas occur in only 50 % in the thoracic region [43]. This gender difference in relation to spinal meningioma location was not observed in the present case series. Furthermore, in our study dural attachment originated mostly from the lateral side (62.9 %). Ventrally or ventrolaterally located meningiomas have been shown to be a negative prognostic factor with regards to functional outcome and Simpson grade of resection [31,23], although this could not be established in our series. Occurrence and frequency of histopathological subtypes in our study were concordant with reported literature [24,35,33,31].

Because of the retrospective nature of this large cohort we faced a great number of missing values regarding the imaging characteristics. We realize this to be a major limitation. Tumor size could not be related to either outcome or recurrence, what might as well be explained by the limited patients of whom this parameter was known ($n = 55$). In addition to site, location in reference to the spinal cord and size, other parameters, such as spinal cord edema, calcification and spinal stenosis, might be of importance to predict extent of resection and outcome assessment. [14,34,47]

5.3. Resection and recurrence

The extent of resection was based on the surgeon's opinion according to the Simpson grading scale, since direct postoperative MRIs have only been introduced recently into our treatment protocol. This in itself might be a limitation to the study, although recent studies still show its relevance and prognostic value. [12,28] In this study, a complete resection (Simpson I-III) was achieved in 88.7 % of cases. This is comparable to previous reports where a complete resection ranged from 82 % to 98 % [38,34,19,21,33,4,9,17,27,36,37,31,14,26,45]. In the present study there was no correlation found between tumor size and grade of resection or recurrence, which can in part be due to the limited number of cases where tumor size was available.

In 12 cases (7.2 %) recurrences were noted, relatively more in the Simpson grade IV group (5 out of 12 cases). Previous studies reported recurrence rates of 1.3 %–21.4 %. [13,38,19,21,33,17,46,31,25,40,26, 45] The definition of recurrence that we used was "reoperation for recurrence", which might well have underestimated true recurrence rates. This definition was used since many patients in the past were not followed for longer times with MR imaging because of stable neurological functional state and/or no residual on the last MRI. Nakamura et al. described in their series a recurrence rate of 9.7 %, all in patients who underwent Simpson grade II resection for ventral lesions [27]. Mean duration for reoperation in these patients was 12.2 ± 5.2 years, compared to 5.2 ± 4.4 years in the present study. This may be due to a shorter follow-up period in our study compared to other series.

In the present study, patients who presented with bladder/bowel problems had a significantly higher chance of recurrence than those who did not. To our best knowledge this has not yet been described in other studies. Although tumors in the lumbar region presented with bladder/bowel problems relatively more often (56 %, $p = 0.033$) we are not able to explain this finding in relation to meningioma site or extent of resection. Because of the low patient count, this might as well be an accidental finding of no significance. In this light, however, Raco et al. have shown a worse functional outcome after surgery in patients with sphincter involvement. [31]

The present study showed more recurrences in younger patients. This finding is similar with Nakamura et al., who reported a recurrence rate of 35 % in the under-50-age group compared to 10 % in the older range [27]. Also, Cohen-Gadol et al. reported higher recurrence rates in the younger compared to the older age groups, 22 % and 5% respectively [4]. This finding is most likely due to a longer life expectancy in the younger age group.

5.4. Outcome

Clinical outcome was determined by the pre- and postoperative modified Rankin Scale. Several grading scales have been described. There is no consensus, however, which grading system is most applicable when measuring clinical outcome in this particular group of patients since these scales were designed for spinal traumatic injury (ASIA, Frankel), degenerative disease (Nurick, JOA, EMS), or intramedullary tumors (McCormick). Most applicable seems the scoring system proposed by Klekamp and Samii, introduced for the clinical evaluation of patients with spinal processes. [18] Unfortunately, because of the retrospective nature of the study we were not able to reproduce reliable data to calculate this score. We postulated that since ambulation is a key element in functional outcome, we decided to use the Nurick Scale. As such, a cut-off for favourable and unfavourable functional outcome according to the modified Rankin Scale was conceived (mRS 0–3 and mRS 4–5, respectively). Nevertheless, we are aware that this might unjustly depict the outcome of spinal pathology in general.

This study showed post-surgical improvement in 117 (79.1 %) patients, 24 (16.2 %) remained stable and 7 (4.7 %) patients deteriorated. Sandalcioğlu et al. reported in their series of 131 patients improvement or stable neurological status in 96.2 % [34], which is comparable to our series (95.3 %). Klekamp and Samii showed 80 % improvement after 1-year follow-up [19]. Solero et al. described 84 % improvement at long-term follow-up [38]. In a recent report by Hohenberger et al. 80 % of patients showed fully recovered sensory deficits, 76 % showed improved gait disorders, and 63.1 % had improvement in motor deficits [14]. Potential risk factors for permanent neurological deterioration have been described such as tumor calcification, anterior dural adherence, infiltrative meningioma, tumor adherence to spinal cord, worse functional grade at onset, prolonged presentation before diagnosis and old age [3,47,31,23].

One way to prevent worsening of neurological outcome is by implementing intraoperative neuromonitoring (IONM), which has been available at our institution since 2009. For the surgery of spinal meningioma it has been used on indication, resulting in only 13 patients thus far, i.e. in 20 % of all patients operated upon since 2009. These numbers are too small to justify statistical analysis or make strong conclusions on outcomes. The use of IONM in intramedullary spinal cord tumor resection in detecting neurologic injury during resection has been reported extensively in literature, however scarcely in IDEM. Korn et al. described a sensitivity of 0.82, a specificity of 0.95, with a positive predictive value of 0.82, and a negative predictive value of 0.95 with a multimodality approach [20]. They used transcranial motor evoked potential, somatosensory evoked potential and EMG monitoring in a retrospective study, which consisted of 100 patients who underwent intradural extramedullary spinal cord tumor resection. Of these, 22 patients had meningiomas [20]. Ghadirpour et al. reported in their

series IONM changes in 5 out of 68 patients with IDEMs (7.3 %) [10]. In 63 patients (92.7 %) IONM invariably predicted a good neurological outcome [10]. In other series, using IONM during surgery of IDEMs proved valuable in 5.7–17.7 % [8,15,39,14].

Other reported methods to improve surgical outcome are the use of the operating microscope and intraoperative ultrasonography, but these are not able to monitor neurological function during surgery. Furthermore, precise radiological classification might aid in selecting the most adequate and safe surgical corridor for spinal meningioma resection. [1]

More recently, minimally invasive techniques have been developed for the microsurgical resection of intradural spinal tumors. [42,5,7] A paraspinous unilateral hemilaminectomy approach centered over the lesion has been shown to offer a safe surgical corridor for resection while preserving paraspinous muscles, facet complexes, and posterior tendon bands [41,48]. This might reduce surgical morbidity and mortality, postoperative discomfort, and spinal instability, with equal surgical results regarding extent of resection and neurological function. Nevertheless, larger randomized clinical trials comparing both open surgery to minimally invasive surgery need to be established.

5.5. Follow-up

In the present study the follow-up period ranged from 0 to 23 years. However, most follow-ups were discontinued after 1–2 years when patients had improved neurologically and had no signs of residual tumor on follow-up MRI scans. Those patients who had recurrences were obviously followed for a longer period. Mirimanoff et al. reported recurrence-free rates 5, 10, and 15 years after total resection of 93 %, 80 %, and 68 % respectively, whereas progression-free rates after subtotal resection were only 63 %, 45 %, and 9% [25]. Nakamura et al. reported that recurrence rates increase progressively with length of follow-up after Simpson grade I and II resection; 0%, 3.2 %, and 8% at 5, 10, and 15 years respectively [27]. In our series, overall recurrence-free survival needing surgery was 91.0 %, 75.9 %, and 59.0 % at 5, 10, and 15 years. Recurrence free survival at 15 years was 67.2 % and 21.9 % for complete resection (Simpson I-III) and incomplete resection, respectively.

There is no defined period described in previous studies on how long the follow-up period should be and at which intervals. Recurrences are reported even after complete resection, so further study data with longer follow-up periods are needed to determine the long-term follow-up policy for improving prognosis. For now, at our facility we propose a follow-up scheme in which control MR imaging is done within 48 h post-operatively, at three and six months, and at yearly intervals up to 3 years, extending this interval depending on previous imaging, WHO grade, neurological status, and life expectancy.

6. Conclusion

Spinal meningiomas are benign, slow-growing tumors, for which the primary treatment consists of surgical resection in order to remove the tumor completely. Peroperative modalities, such as IONM, are valuable attributes to prevent neurological deterioration.

The majority of patients will show improvement of neurological function after tumor removal. Mortality may occur in patients of extreme high age and with severe co-morbidity. Recurrences occur in about 12 % of patients and do not seem to be directly related to WHO grade or extent of resection.

Although recurrences are infrequent they may occur even after 10–15 years, therefore an individualized follow-up scheme needs to be planned based on risk factors for recurrence and prognostic lifespan for each individual patient.

Funding

No funding was received for this research.

Ethical approval

All procedures performed in studies involving human participants were in accordance with the ethical standards of the institutional and/or national research committee and with the 1964 Helsinki declaration and its later amendments or comparable ethical standards. For this type of study, i.e., retrospective chart study, formal consent is not required.

This article does not contain any studies with human participants or animals performed by any of the authors.

CRediT authorship contribution statement

L.E. Kwee: Conceptualization, Methodology, Validation, Formal analysis, Investigation, Data curation, Writing - original draft. **B.S. Harhangi:** Conceptualization, Methodology, Writing - review & editing. **G.A. Ponne:** Validation, Investigation, Data curation. **J.M. Kros:** Conceptualization, Writing - review & editing. **C.M.F. Dirven:** Conceptualization, Writing - review & editing, Supervision. **R. Damers:** Conceptualization, Methodology, Validation, Formal analysis, Data curation, Writing - review & editing, Supervision.

Declaration of Competing Interest

The authors report no declarations of interest.

References

- [1] A.B. Bayoumi, Y. Laviv, B. Yokus, I.E. Efe, Z.O. Toktas, T. Kilic, M.K. Demir, D. Konya, E.M. Kasper, Proposal of a new radiological classification system for spinal meningiomas as a descriptive tool and surgical guide, *Clin. Neurol. Neurosurg.* 162 (2017) 118–126, <https://doi.org/10.1016/j.clineuro.2017.10.001>.
- [2] B.D. Birch, P.C. McCormick, D.K. Resnick, Intradural extramedullary spinal lesions., in: E.C. Benzel (Ed.), *Spine Surgery Techniques, Complications Avoidance, and Management*, 2, Elsevier, Philadelphia, 2005, pp. 948–960.
- [3] M. Bydon, Z.L. Gokaslan, Spinal meningioma resection, *World Neurosurg.* 83 (2015) 1032–1033, <https://doi.org/10.1016/j.wneu.2015.01.049>.
- [4] A.A. Cohen-Gadol, O.M. Zikel, C.A. Koch, B.W. Scheithauer, W.E. Krauss, Spinal meningiomas in patients younger than 50 years of age: a 21-year experience, *J. Neurosurg.* 98 (2003) 258–263.
- [5] D. Dahlberg, C.M. Halvorsen, B. Lied, E. Helseth, Minimally invasive microsurgical resection of primary, intradural spinal tumours using a tubular retraction system, *Br. J. Neurosurg.* 26 (2012) 472–475, <https://doi.org/10.3109/0268897.2011.644823>.
- [6] L.M. Duong, B.J. McCarthy, R.E. McLendon, T.A. Dolecek, C. Kruchko, L. Douglas, U.A. Ajani, Descriptive epidemiology of malignant and nonmalignant primary spinal cord, spinal meninges, and cauda equina tumors, United States, 2004–2007, *Cancer* 118 (2012) 4220–4227, <https://doi.org/10.1002/cncr.27390>.
- [7] M. Formo, C.M. Halvorsen, D. Dahlberg, T. Brommeland, H. Fredo, J. Hald, D. Scheie, I.A. Langmoen, B. Lied, E. Helseth, Minimally invasive microsurgical resection of primary, intradural spinal tumors is feasible and safe: a consecutive series of 83 patients, *Neurosurgery* 82 (2018) 365–371, <https://doi.org/10.1093/neuros/nyx253>.
- [8] M.T. Forster, G. Marquardt, V. Seifert, A. Szelenyi, Spinal cord tumor surgery—importance of continuous intraoperative neurophysiological monitoring after tumor resection, *Spine (Phila Pa 1976)* 37 (2012) E1001–1008, <https://doi.org/10.1097/BRS.0b013e31824c76a8>.
- [9] F. Gezen, S. Kahraman, Z. Canakci, A. Beduk, Review of 36 cases of spinal cord meningioma, *Spine (Phila Pa 1976)* 25 (2000) 727–731.
- [10] R. Ghadirpour, D. Nasi, C. Iaccarino, D. Giraldo, R. Sabadini, L. Motti, F. Sala, F. Servadei, Intraoperative neurophysiological monitoring for intradural extramedullary tumors: why not? *Clin. Neurol. Neurosurg.* 130 (2015) 140–149, <https://doi.org/10.1016/j.clineuro.2015.01.007>.
- [11] O.N. Gottfried, W. Gluf, A. Quinones-Hinojosa, P. Kan, M.H. Schmidt, Spinal meningiomas: surgical management and outcome, *Neurosurg. Focus* 14 (2003) e2.
- [12] K. Gousias, J. Schramm, M. Simon, The Simpson grading revisited: aggressive surgery and its place in modern meningioma management, *J. Neurosurg.* 125 (2016) 551–560, <https://doi.org/10.3171/2015.9.JNS15754>.
- [13] A. Helseth, S.J. Mork, Primary intraspinal neoplasms in Norway, 1955 to 1986. A population-based survey of 467 patients, *J. Neurosurg.* 71 (1989) 842–845, <https://doi.org/10.3171/jns.1989.71.6.0842>.
- [14] C. Hohenberger, C. Gugg, N.O. Schmidt, F. Zeman, K.M. Schebesch, Functional outcome after surgical treatment of spinal meningioma, *J. Clin. Neurosci.* (2020), <https://doi.org/10.1016/j.jocn.2020.05.042>.
- [15] S.J. Hyun, S.C. Rhim, J.K. Kang, S.H. Hong, B.R. Park, Combined motor- and somatosensory-evoked potential monitoring for spine and spinal cord surgery: correlation of clinical and neurophysiological data in 85 consecutive procedures, *Spinal Cord* 47 (2009) 616–622, <https://doi.org/10.1038/sc.2009.11>.

- [16] J. Jääskeläinen, M. Haltia, A. Servo, Atypical and anaplastic meningiomas: radiology, surgery, radiotherapy, and outcome, *Surg. Neurol.* 25 (1986) 233–242.
- [17] A.T. King, M.M. Sharr, R.W. Gullan, J.R. Bartlett, Spinal meningiomas: a 20-year review, *Br. J. Neurosurg.* 12 (1998) 521–526.
- [18] J. Klekamp, M. Samii, Introduction of a score system for the clinical evaluation of patients with spinal processes, *Acta Neurochir. (Wien)* 123 (1993) 221–223.
- [19] J. Klekamp, M. Samii, Surgical results for spinal meningiomas, *Surg. Neurol.* 52 (1999) 552–562.
- [20] A. Korn, D. Halevi, Z. Lidar, T. Biron, P. Ekstein, S. Constantini, Intraoperative neurophysiological monitoring during resection of intradural extramedullary spinal cord tumors: experience with 100 cases, *Acta Neurochir. (Wien)* 157 (2015) 819–830, <https://doi.org/10.1007/s00701-014-2307-2>.
- [21] W.J. Levy Jr., J. Bay, D. Dohn, Spinal cord meningioma, *J. Neurosurg.* 57 (1982) 804–812, <https://doi.org/10.3171/jns.1982.57.6.0804>.
- [22] D.N. Louis, A. Perry, G. Reifenberger, A. von Deimling, D. Figarella-Branger, W. K. Cavenee, H. Ohgaki, O.D. Wiestler, P. Kleihues, D.W. Ellison, The 2016 world health organization classification of tumors of the central nervous system: a summary, *Acta Neuropathol.* 131 (2016) 803–820, <https://doi.org/10.1007/s00401-016-1545-1>.
- [23] T.K. Maiti, S.C. Bir, D.P. Patra, P. Kalakoti, B. Guthikonda, A. Nanda, Spinal meningiomas: clinicoradiological factors predicting recurrence and functional outcome, *Neurosurg. Focus* 41 (2016) E6, <https://doi.org/10.3171/2016.5.FOCUS16163>.
- [24] P.C. McCormick, K.D. Post, B.M. Stein, Intradural extramedullary tumors in adults, *Neurosurg. Clin. N. Am.* 1 (1990) 591–608.
- [25] R.O. Mirmanoff, D.E. Dosoretz, R.M. Linggood, R.G. Ojemann, R.L. Martuza, Meningioma: analysis of recurrence and progression following neurosurgical resection, *J. Neurosurg.* 62 (1985) 18–24, <https://doi.org/10.3171/jns.1985.62.1.0018>.
- [26] K. Naito, T. Yamagata, H. Arima, T. Takami, Low recurrence after Simpson grade II resection of spinal benign meningiomas in a single-institute 10-year retrospective study, *J. Clin. Neurosci.* (2020), <https://doi.org/10.1016/j.jocn.2020.04.113>.
- [27] M. Nakamura, O. Tsuji, K. Fujiyoshi, N. Hosogane, K. Watanabe, T. Tsuji, K. Ishii, Y. Toyama, K. Chiba, M. Matsumoto, Long-term surgical outcomes of spinal meningiomas, *Spine (Phila Pa 1976)* 37 (2012) E617–623, <https://doi.org/10.1097/BRS.0b013e31824167f1>.
- [28] A. Nanda, S.C. Bir, T.K. Maiti, S.K. Konar, S. Missios, B. Guthikonda, Relevance of Simpson grading system and recurrence-free survival after surgery for World Health Organization Grade I meningioma, *J. Neurosurg.* 126 (2017) 201–211, <https://doi.org/10.3171/2016.1.JNS151842>.
- [29] S. Nurick, The natural history and the results of surgical treatment of the spinal cord disorder associated with cervical spondylosis, *Brain* 95 (1972) 101–108.
- [30] *Pathology of Tumors of the Nervous System*, 5th edn., Arnold, London, England, 1989.
- [31] A. Raco, A. Pesce, G. Toccaceli, M. Domenicucci, M. Miscusi, R. Delfini, Factors leading to a poor functional outcome in spinal meningioma surgery: remarks on 173 Cases, *Neurosurgery* 80 (2017) 602–609, <https://doi.org/10.1093/neuros/nyw092>.
- [32] V.M. Ravindra, M.H. Schmidt, Management of spinal meningiomas, *Neurosurg. Clin. N. Am.* 27 (2016) 195–205, <https://doi.org/10.1016/j.nec.2015.11.010>.
- [33] F.X. Roux, F. Nataf, M. Pinaudeau, G. Borne, B. Devaux, J.F. Meder, Intraspinal meningiomas: review of 54 cases with discussion of poor prognosis factors and modern therapeutic management, *Surg. Neurol.* 46 (1996) 458–463, discussion 463–454.
- [34] I.E. Sandalcioğlu, A. Hunold, O. Müller, H. Bassiouni, D. Stolke, S. Asgari, Spinal meningiomas: critical review of 131 surgically treated patients, *Eur. Spine J.* 17 (2008) 1035–1041, <https://doi.org/10.1007/s00586-008-0685-y>.
- [35] C. Saraceni, J.S. Harrop, Spinal meningioma: chronicles of contemporary neurosurgical diagnosis and management, *Clin. Neurol. Neurosurg.* 111 (2009) 221–226, <https://doi.org/10.1016/j.clineuro.2008.10.018>.
- [36] B. Schaller, Spinal meningioma: relationship between histological subtypes and surgical outcome? *J. Neurooncol.* 75 (2005) 157–161, <https://doi.org/10.1007/s11060-005-1469-4>.
- [37] M. Setzer, H. Vatter, G. Marquardt, V. Seifert, F.D. Vrionis, Management of spinal meningiomas: surgical results and a review of the literature, *Neurosurg. Focus* 23 (2007) E14, <https://doi.org/10.3171/FOC-07/10/E14>.
- [38] C.L. Solero, M. Fornari, S. Giombini, G. Lasio, G. Oliveri, C. Cimino, F. Pluchino, Spinal meningiomas: review of 174 operated cases, *Neurosurgery* 25 (1989) 153–160.
- [39] M. Sutter, A. Eggspuehler, D. Grob, D. Jeszenszky, A. Benini, F. Porchet, A. Mueller, J. Dvorak, The validity of multimodal intraoperative monitoring (MIOM) in surgery of 109 spine and spinal cord tumors, *Eur. Spine J.* 16 (Suppl 2) (2007) S197–208, <https://doi.org/10.1007/s00586-007-0422-y>.
- [40] K. Tsuda, H. Akutsu, T. Yamamoto, K. Nakai, E. Ishikawa, A. Matsumura, Is Simpson grade I removal necessary in all cases of spinal meningioma? Assessment of postoperative recurrence during long-term follow-up, *Neurol. Med. Chir. (Tokyo)* 54 (2014) 907–913.
- [41] L.M. Tumlialan, N. Theodore, M. Narayanan, F.F. Marciano, P. Nakaji, Anatomic basis for minimally invasive resection of intradural extramedullary lesions in thoracic spine, *World Neurosurg.* 109 (2018) e770–e777, <https://doi.org/10.1016/j.wneu.2017.10.078>.
- [42] M.K. Turel, W.P. D'Souza, V. Rajshekhar, Hemilaminectomy approach for intradural extramedullary spinal tumors: an analysis of 164 patients, *Neurosurg. Focus* 39 (2015) E9, <https://doi.org/10.3171/2015.5.FOCUS15170>.
- [43] J.W. Van Goethem, L. van den Hauwe, O. Ozsarlak, A.M. De Schepper, P. M. Parizel, Spinal tumors, *Eur. J. Radiol.* 50 (2004) 159–176, <https://doi.org/10.1016/j.ejrad.2003.10.021>.
- [44] J.C. van Swieten, P.J. Koudstaal, M.C. Visser, H.J. Schouten, J. van Gijn, Interobserver agreement for the assessment of handicap in stroke patients, *Stroke* 19 (1988) 604–607.
- [45] R. Voldrich, D. Netuka, V. Benes, Spinal meningiomas: is Simpson grade II resection radical enough? *Acta Neurochir. (Wien)*. (2020) <https://doi.org/10.1007/s00701-020-04280-2>.
- [46] C. Weber, S. Gulati, A.S. Jakola, S. Habiba, O.P. Nygaard, T.B. Johannesen, O. Solheim, Incidence rates and surgery of primary intraspinal tumors in the era of modern neuroimaging: a national population-based study, *Spine (Phila Pa 1976)* 39 (2014) E967–973, <https://doi.org/10.1097/BRS.0000000000000412>.
- [47] H.J. Westwick, S.J. Yuh, M.F. Shamji, Complication avoidance in the resection of spinal meningiomas, *World Neurosurg.* 83 (2015) 627–634, <https://doi.org/10.1016/j.wneu.2014.12.015>.
- [48] M.G. Yaşargil, B.I. Tranmer, T.E. Adamson, P. Roth, Unilateral partial hemilaminectomy for the removal of extra- and intramedullary tumours and AVMs, in: al. LSe (Ed.), *Advances and Technical Standards in Neurosurgery*, vol 18, Springer-Verlag, Wien New York, 1991, pp. 113–132.