

## Retinopathy of prematurity care in peripheral districts in Odisha, India: Pilot for a sustainable model

Tapas R Padhi, Lingaraj Pradhan<sup>1</sup>, Srikanta K Padhy, Ashwani Meherda<sup>2</sup>, Balakrushna Samantaray<sup>3</sup>, Kumari K Patro<sup>3</sup>, Sabita Devi<sup>4</sup>, Mita Mishra<sup>5</sup>, Sujit Mahapatra<sup>6</sup>, Samir Sutar, Sameer R Nayak, Anup Kelgaonkar, Ashish Khalsa, Rajan Shukla<sup>7</sup>, Clare Gilbert<sup>8</sup>

The outcome of a retinopathy of prematurity (ROP) program initiated in five districts of Odisha over 3 years with partnerships between the government and non-government organizations was prospectively analyzed. The mentoring partners trained the district ophthalmologists and neonatal care providers; the program was handed over when the trainees were considered competent enough to diagnose and treat babies with ROP. During the project period (July 2016–June 2019), 3058 babies were examined; ROP was detected in 33.81% ( $n = 1034$ ) and 5.06% ( $n = 159$ ) babies required treatment. At the end of the project, ROP screening was possible in all five districts, and treatment was possible in three districts. ROP care nodal centers were built in one government medical college. To strengthen the initial gain, we recommend creating an Odisha Retinopathy of Prematurity (OD-ROP) steering committee with private–public partnerships to support the program and monitor its progress in other districts of Odisha.

**Key words:** Odisha, retinopathy of prematurity, sustainable model

An increasing number of premature babies survive in India today because of improved neonatal care, and the State of Odisha is no exception. Odisha, which has a population of 42.6 million,<sup>[1]</sup> has 40 government district special newborn care units (SNCUs). Each unit admits an average of 15 babies a month with a birth weight less than 2000 g (unpublished data). Based on our experience in the state,<sup>[2]</sup> approximately 80 babies are at risk of becoming blind from untreated retinopathy of prematurity (ROP) every month, equally divided between the government and private neonatal units. Prior to 2016, systematic and comprehensive ROP services that also included posttreatment visual rehabilitation were offered by one non-government tertiary eye care facility in the capital city, Bhubaneswar;<sup>[2,3]</sup> another private eye care facility in the neighboring city of Cuttack offered some services in ROP care. We have reported an increase in the number of babies with advanced ROP in the peripheral districts of Odisha.<sup>[2]</sup> Given the growth of the SNCUs in the state and that many prematurely born babies survive,<sup>[4]</sup> there is an urgent need to expand the ROP services.

Department of Retina and Vitreous, LV Prasad Eye Institute, Bhubaneswar, <sup>1</sup>Departments of Pediatrics and <sup>2</sup>Ophthalmology, Capital Hospital, Bhubaneswar, <sup>3</sup>Department of Ophthalmology, SCB Medical College, Cuttack, <sup>4</sup>Department of Ophthalmology, MKCG Medical College, Berhampur, <sup>5</sup>Department of Ophthalmology, District Headquarter Hospital, Mayurbhanj, <sup>6</sup>Department of Ophthalmology, District Headquarter Hospital, Balasore, Odisha, <sup>7</sup>Associate Professor, Public Health Foundation, Hyderabad, India, <sup>8</sup>Department of Clinical Research, London School of Hygiene and Tropical Medicine, London, UK

**Correspondence to:** Dr. Tapas R Padhi, LV Prasad Eye Institute, Patia, Bhubaneswar - 751 024, Odisha, India. E-mail: [tapaspadhi254@gmail.com](mailto:tapaspadhi254@gmail.com)

Received: 20-Oct-2019

Revision: 06-Dec-2019

Accepted: 12-Dec-2019

Published: 17-Jan-2020

### Access this article online

**Website:**

[www.ijo.in](http://www.ijo.in)

**DOI:**

10.4103/ijo.IJO\_1914\_19

### Quick Response Code:



## Methods

With funding from the Queen Elizabeth Diamond Jubilee Trust (The Trust), UK, a ROP project was launched in five districts of Odisha [Fig. 1] after signing of a memorandum of understanding (MoU) between the Department of Health and Family Welfare, Government of Odisha, L. V Prasad Eye Institute, Bhubaneswar (ophthalmic mentor institute), Department of Pediatrics, Capital Hospital, Bhubaneswar (pediatric mentor center), and the Public Health Foundation of India (PHFI), Hyderabad. The State Rashtriya Bal Swasthya Karyakram (RBSK) program was partnered for state-wise program implementation. The program was initiated after a state level co-ordination meeting with ophthalmologists, pediatricians, SNCU in-charges from the project districts, PHFI representatives, and government stakeholders. This was followed by training of ophthalmologists in ROP screening from the five districts and in laser and intravitreal anti-vascular endothelial growth factor (VEGF) injection in three districts.

Different strategies were adopted across the districts [Table 1]. The mentor institute and RBSK team trained pediatricians and nurses in each district in quality improvement for newborn care

This is an open access journal, and articles are distributed under the terms of the Creative Commons Attribution-NonCommercial-ShareAlike 4.0 License, which allows others to remix, tweak, and build upon the work non-commercially, as long as appropriate credit is given and the new creations are licensed under the identical terms.

**For reprints contact:** [reprints@medknow.com](mailto:reprints@medknow.com)

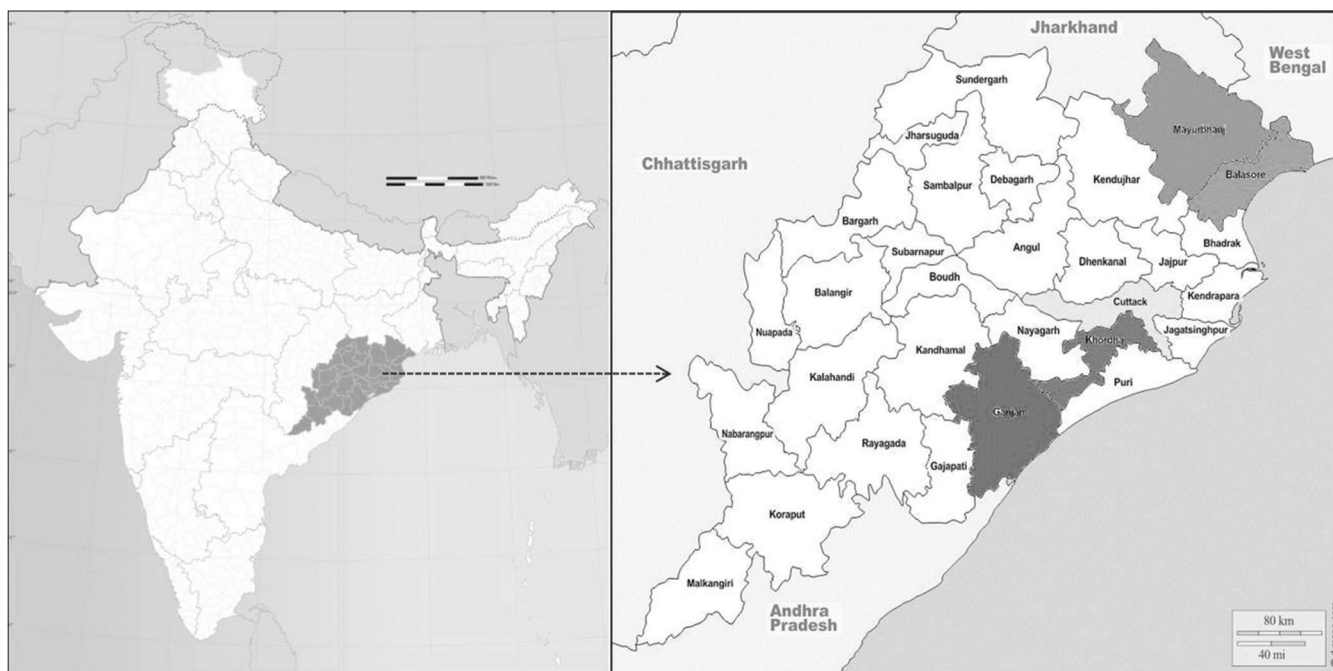**Cite this article as:** Padhi TR, Pradhan L, Padhy SK, Meherda A, Samantaray B, Patro KK, *et al.* Retinopathy of prematurity care in peripheral districts in Odisha, India: Pilot for a sustainable model. Indian J Ophthalmol 2020;68:S124-7.

and basic ROP care at the start and during the program. Each SNCU was provided with indirect ophthalmoscope, 20 D lens, pediatric eye speculum, indenter, ROP evaluation cards, and ROP dilating drops. Frequency-doubled Nd: YAG green laser machines (IRIS Medical Oculight TX, IRIDEX, CA, USA) were supplied to the east coast and capital districts one by the Trust and another by the state government, respectively. These two centers were designated to be ROP care nodal centers in the public health system. Staff in the five districts were mentored quarterly by onsite visits by the mentor. The ophthalmology mentor institute trained ophthalmologists, pediatricians, and

nurses in ROP care. The mentor ophthalmologist also provided round-the-clock ROP support to the mentee ophthalmologists over the phone. The momentum was maintained by workshops for the nurses and pediatricians by the mentoring neonatologist in the project districts, distribution of ROP education leaflets, banners, and work instructions, and sharing ROP videos among SNCU staff in the different districts.

### Results

The following results were obtained over the 3 years (July 2016–June 2019).



**Figure 1:** Location of the districts where the project was initiated

**Table 1: Pretraining experience, strategies adopted, and final outcome of the program in different districts**

Location of district	Distance from mentoring institute	Ophthalmologist's pretraining experience		State government strategic decision	Strategy adopted	Progress in ROP care
		I/O	ROP care			
District capital	6 km	Yes	None	Nodal center	Onsite training in ROP screening and treatment for 1.5 years	Steady and satisfactory throughout
East coast	30 km	Yes	None	Nodal center	2 months of training in ROP screening followed by onsite training on laser	Initial delay, peaked fast, and satisfactory
Northern	252 km	Yes	None	ROP screening at present. Possible nodal center in future as it is attached to a medical college.	2 months of training in ROP screening and followed a year later by 2 months of training on laser	Uniform and steady
Southern	170 km	Yes	None	ROP screening at present and possible nodal center in future	2 months of training in ROP screening followed 1 year later by 2 months of training in laser	Long initial delay; peaked well toward the end of the project
North coast	196 km	No	None	ROP screening alone	15 days of training in ROP screening followed by periodic reorientation for a day or 2 throughout the project	Very slow

I/O=Indirect ophthalmoscopy; ROP=Retinopathy of prematurity

### Patient care

During the project period, 3058 babies were screened, from 152 to 1528 per SNCU and from 10.1 to 46.3 babies per month. About 33.8% ( $n = 1034$ ) of them were detected to have ROP of any severity [Table 2]. The proportion of babies with any ROP was far higher in three SNCUs (range 35.7%–47.2%) than in the other two (1.2% and 9.1%). In the SNCU with the highest rate, 15 of 29 babies with ROP had aggressive posterior ROP (AP-ROP). During the project period, 159 babies (15.4% of babies detected to have ROP and 5.2% of screened babies) were treated: peripheral retinal laser 121 babies (234 eyes), anti-VEGF intravitreal injections 24 babies (43 eyes), laser + anti-VEGF injection 11 babies (22 eyes), and anti-VEGF+ laser + vitreous surgery 3 babies (6 eyes). Over time, there was an increase in the number of babies screened and detected with ROP [Supplemental Fig. 1] and it was highest in the last 6 months of the project.

### Capacity-building

Six ophthalmologists were trained in ROP care [Table 3]. Four of them had experience in indirect ophthalmoscopy, one had received short-term retina training, but none had undergone a long-term retina fellowship. At the end of the project, all six ophthalmologists were confident and competent in diagnosing ROP. Three ophthalmologists were also trained in retinal laser and intravitreal injections. Two of them were trained to perform intravitreal injections in the adult first and then the infants under direct supervision of the ROP specialist. In addition, they were also supervised during their initial intravitreal injections in infants at the local district NCIUs. The third ophthalmologist, who already had experience in intravitreal injections in adults and elderly, was directly inducted to intravitreal injections for ROP in infants. Among the different strategies adopted, the following worked best for quality, regularity, and quantity of

eligible babies screened: initial training of ophthalmologist and allied ROP care personnel at the mentor's institute, followed by mentor supervised onsite screening and treatment for 6–12 months, and finally seamless, but step-wise handing over the responsibilities (screening to laser to intravitreal injections). In preparation of the next group of ophthalmologists trained for ROP, the RBSK supported training of five ophthalmologists from five additional districts in indirect ophthalmoscopy.

### Quality improvement in neonatal care

Fifteen meetings were conducted for the pediatricians, nurses, and other child healthcare providers during the project. Experience sharing by the mentors helped to motivate the pediatric teams on the need and importance of timely ROP care.

### Improved co-ordination between government and mentor institute

Fig. 2 represents a pictorial case study of a very sick baby – the pre (a and b) and post laser fundus picture (c and d) illustrates coordination between the government and mentor institute. This baby was detected to have severe ROP by the district ophthalmologist 20 days after birth. The parents were poor and illiterate; the local RBSK team transported the baby to the mentor institute for treatment, and once stabilized the baby was returned to the district ophthalmologists' care.

### Discussion

The ROP care model in the state of Odisha was different from the tele-screening model using a wide-field pediatric camera.<sup>15,61</sup> In the tele-screening model, babies suspected to having sight-threatening ROP are referred to one tertiary facility. In contrast, we built the capacity for ROP screening and treatment in the peripheral districts of Odisha; this decentralized the entire process. The project involved pediatric

**Table 2: Outcome of ROP screening in peripheral districts of Odisha**

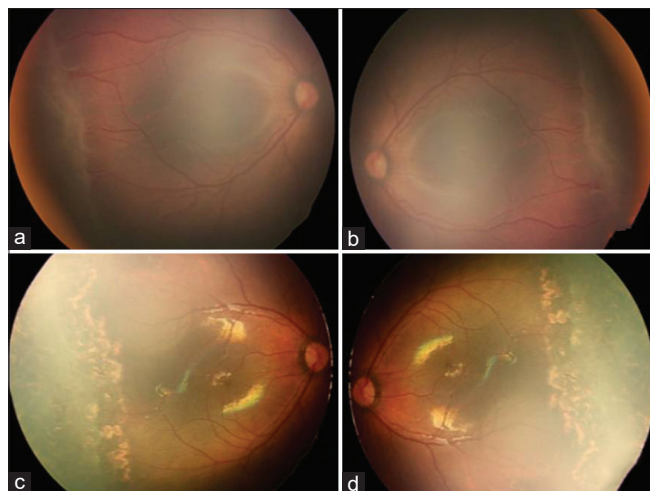
District location	Screening		Detected with any ROP	Treatment method				Total treated (% screened)
	Babies screened	Screened/ months		Laser: (eyes)	Anti-VEGF injection (eyes)	Anti-VEGF + laser (eyes)	Laser, injection or surgery (eyes)	
District capital	652	18.1	233 (36%)	31 (60)	6 (11 eyes)	3 (6)	1 (2 eyes)	41 (6.3%)
East coast	1528	46.3	601 (39%)	67 (130)	8 (15 eyes)	5 (9)	0	80 (5.2%)
Northern	410	17.2	32 (8%)	7 (14)	1 (2 eyes)	0	1 (2 eyes)	9 (2.2%)
Southern	316	15.8	149 (47%)	16 (30)	9 (15 eyes)	3 (6)	1 (2 eyes)	29 (9.2%)
North coast	152	10.1	19 (13%)	0	0	0	0	0
Total	3058	23.8	1034 (33.8%)	121 (234)	24 (43 eyes)	11 (21)	3 (6 eyes)	159 (5.2%)

ROP=Retinopathy of prematurity; anti-VEGF=Anti-vascular endothelial growth factor

**Table 3: Ophthalmic and pediatric capacity-building for retinopathy of prematurity services**

District location	ROP tool kit	Training pediatricians and SNCU nurses	Ophthalmic capacity building		
			Screening	Laser	Intravitreal injections
District capital	I/O, laser from state government	Completed	√	√	√
East coast	I/O, laser from the Trust	Completed	√	√	√
Northern	I/O	Completed	√	√	√
Southern	I/O, green laser from state government	Completed	√	√	-
North coast	I/O	Completed	√	Not required at present	Not required at Present

ROP=Retinopathy of prematurity; I/O=Indirect ophthalmoscope; SNCU=Special newborn care unit



**Figure 2:** A baby hailing from a tribal territory in northern Odisha was referred for high-risk prethreshold retinopathy of prematurity in both the eyes (a and b). Collaboration between the Rashtriya Bal Swasthya Karyakram of the referring and the referred district ensured the baby gets treated successfully with regressed retinopathy of prematurity (c and d)

nurses, which improved the reach and care as they played a vital role during the second and third years of the program.

In the absence of the electronic medical records (EMR) throughout the state, the problems of manual data entry were overcome by involving the treating ophthalmologists. We hope the difficulty would reduce once the EMR is introduced which would also greatly facilitate follow-up care. Proficiency in indirect ophthalmoscopy is an essential requirement for better and faster skills acquisition in ROP screening and treating babies with ROP. We observed that the ophthalmologists without prior indirect ophthalmoscopy skills required as long as 2 years to be proficient in indirect laser treatment. Based on these experiences, we suggest that indirect ophthalmoscopy training in adults should always precede indirect ophthalmoscopy in infants and children.

As an impact of the project, more SNCUs implemented screening for ROP and this resulted in increase in babies suspected to having ROP, but there was no corresponding increase in qualified eye health personnel. The incidence of ROP was several times higher in three district SNCUs; this could be due to several factors such as case mix (extremely preterm infants or more out-born babies or earlier discharge), referral patterns (the sickest babies are referred to other units for neonatal care or ROP treatment), and/or the quality of neonatal care (variation in oxygen delivery practices and sepsis rates). Incidentally, we observed that the recent spurt in AP-ROP was linked to increase in delivery of 88%–95% concentration of oxygen in these SNCUs.

We suggest that an Odisha Retinopathy of Prematurity (OD-ROP) steering committee be established under the State Ministry of Health, with members drawn from government and non-government sectors, involving ophthalmologists, neonatologists, and neonatal nurses, and representatives of national bodies such as RBSK, eye health, and neonatal care. This group should be entrusted with planning and monitoring to scale up of ROP services across Odisha. We also propose a comprehensive ROP care that includes screening, treatment, long-term follow-up, and rehabilitation. A state-wise ROP register would be essential for these purposes.

## Conclusion

We had many interesting observations in a non-tele-screening ROP model in five districts of Odisha. The most glaring one is in the wide variation in the incidence and severity of ROP between district SNCUs (1.2%–47.2%). Facility for ROP care did not exist in these five districts before the project and this could be true in the remaining 25 districts. At the end of the 3 years, the project demonstrated superior ROP care by adequate capacity-building and infrastructure development in five districts. Similar strategy will likely help the remaining 25 districts for a pan Odisha coverage and good public–private partnership.<sup>[3]</sup>

## Financial support and sponsorship

The Queen Elizabeth Diamond Jubilee Trust, London, UK.

## Conflicts of interest

There are no conflicts of interest.

## References

1. Government of India. Orissa population 2011–2019. Available from: <https://www.census2011.co.in> › States. [Last accessed on 2019 Dec 23].
2. Padhi TR, Jain L, Behera UC, Pradhan L. Retinopathy of prematurity profile and trend over the years: Experience from a two tier City in Eastern India. *Indian Pediatr* 2016;53(Suppl 2):S76-9.
3. Padhi TR, Badhani A, Mahajan S, Savla LP, Sutar S, Jalali S, *et al.* Barriers to timely presentation for appropriate care of retinopathy of prematurity in Odisha, Eastern India. *Indian J Ophthalmol*. 2019;67:824-7.
4. Som M, Nayak C, Padhi BK, Ashwani N. Pattern of morbidity among newborns admitted in SNCUs of Odisha. *India. Int J Health Sci Res* 2018;8:10-9.
5. Vinekar A, Mangalesh S, Jayadev C, Gilbert C, Dogra M, Shetty B. Impact of expansion of telemedicine screening for retinopathy of prematurity in India. *Indian J Ophthalmol* 2017;65:390-5.
6. Shah P, Narendran V, Kalpana N. Evolution of ROP screening at Aravind Eye Hospital, Coimbatore-Lessons learnt and the way ahead. *Community Eye Health* 2018;31:S23-4.

# TIME IS OF THE ESSENCE

Keeler's MIO – a revolution in Fundus Imaging Technology for adult and paediatric patients, helping Ophthalmologists worldwide conduct fast and affordable retinal examination!



Non-contact & portable digital retinal exams



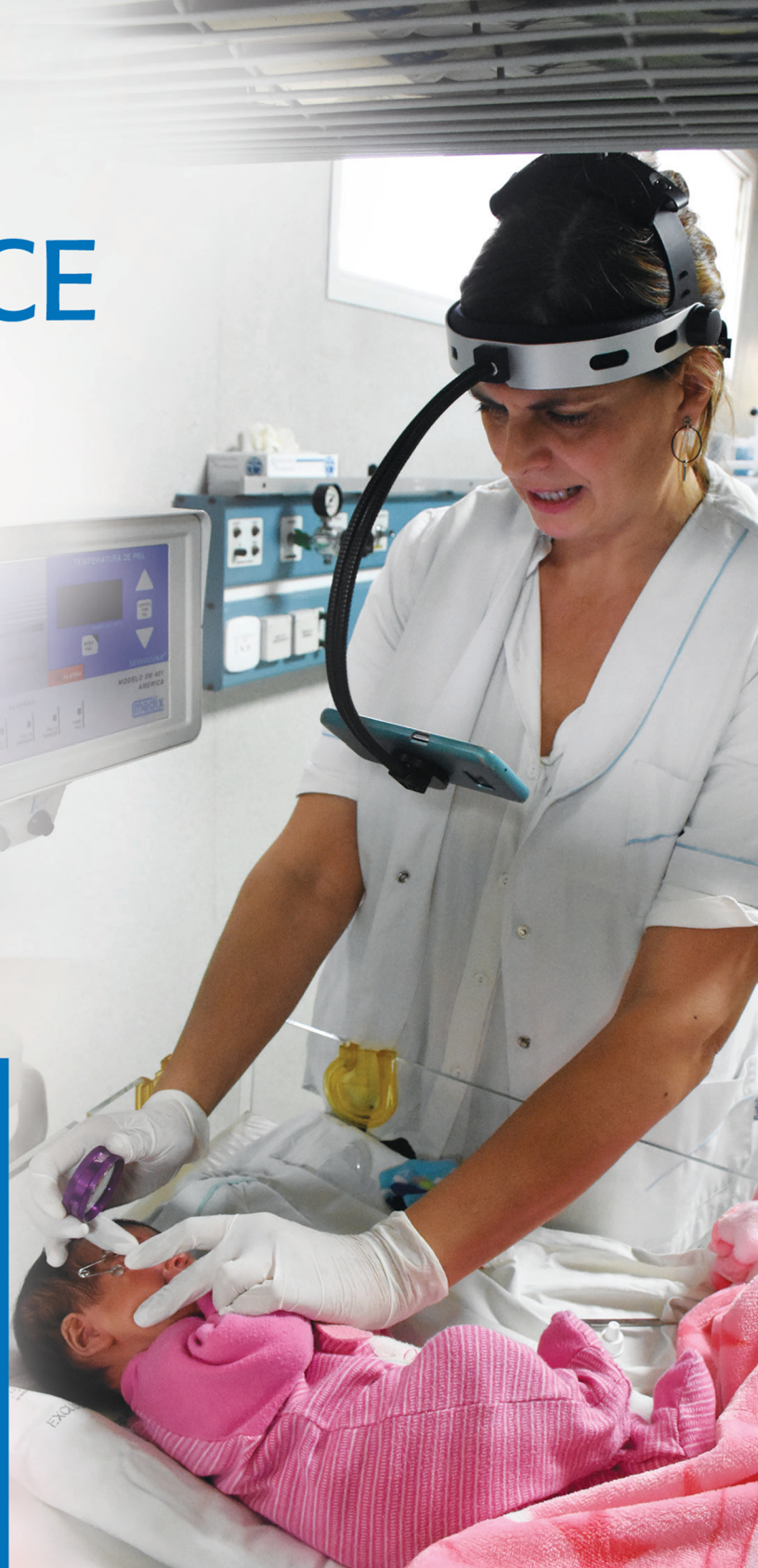Saves time with KineXis Imager for fundus auto-capture



Share documentation securely for patient engagement, education and analysis

“In a busy out-patient environment, the visit led to quick diagnosis, clear explanation of the required treatment to the patient and urgent treatment. The diagnosis would have been difficult to explain to the patient without images of the eye, prolonging the appointment and potentially delaying treatment.”

Dr. N.R. Rangaraj  
Premiere Eye Care, Chennai



Today patients across the world are avoiding essential eye treatment for fear of the on-going pandemic. Innovative telemedicine technology in the ophthalmic field, like MIO, helps ensure safety for both doctor and patient. Retinal treatment is important. #EyeCareCannotWait

Available in India

[www.keelermio.com](http://www.keelermio.com)



A Halma Company

**Keeler**  
– A world without vision loss –