

## SYSTEMATIC REVIEW

# A systematic review on diagnostic test accuracy of magnetic resonance neurography versus clinical neurosensory assessment for post-traumatic trigeminal neuropathy in patients reporting neurosensory disturbance

<sup>1,2</sup>Frederic Van der Cruyssen, <sup>1,2</sup>Frederik Peeters, <sup>1,2</sup>Tomas-Marijn Croonenborghs, <sup>1,2</sup>Jasper Fransen, <sup>3</sup>Tara Renton, <sup>1,2</sup>Constantinus Politis, <sup>4,5</sup>Jan Casselman and <sup>2,6,7</sup>Reinhilde Jacobs

<sup>1</sup>Department of Oral & Maxillofacial Surgery, University Hospitals Leuven, Leuven, Belgium; <sup>2</sup>Department of Imaging and Pathology, OMFS-IMPACT Research Group, Faculty of Medicine, University Leuven, Leuven, Belgium; <sup>3</sup>Department of Oral Surgery, King's College London Dental Institute, London, United Kingdom; <sup>4</sup>Department of Radiology, AZ St-Jan Brugge-Oostende, Bruges, Belgium; <sup>5</sup>Department of Radiology, AZ St-Augustinus, Antwerp, Belgium; <sup>6</sup>Department of Oral Health Sciences and Department of Dentistry, University Hospitals Leuven, Leuven, Belgium; <sup>7</sup>Department of Dental Medicine, Karolinska Institutet, Stockholm, Sweden

**Objectives:** To perform a systematic review of published studies on diagnostic accuracy of magnetic resonance neurography (MRN) vs clinical neurosensory testing (NST) for post-traumatic trigeminal neuropathy (PTTN) in patients reporting neurosensory disturbances (NSD).

**Methods:** Human studies except case reports, reviews, systematic reviews and meta-analyses were included. PubMed, Embase, Web of Science and Cochrane Library were consulted. Risk of bias assessment was conducted using the Quality Assessment of Diagnostic Accuracy Studies 2 tool. Predetermined data extraction parameters were noted and summarized.

**Results:** 8 studies met eligibility criteria of which 7 were retrospective, representing 444 subjects. Most studies were at high risk of bias with low applicability concerns. Populations and objectives were divergent with a large variation in timing (3 days–17 years post injury) and parameters (multiple coil designs, fat suppression techniques, additional contrast agent) of MRI acquisition.  $T_2$  weighted 3 T imaging with short echo times (2.2–100 ms) and fat suppression was applied in seven studies, techniques varied. Determination of sensitivity and specificity could not be performed due to the methodological variation between studies and lacking comparative data between index and reference tests. Based on limited data, PTTN correlated reasonably well between clinical assessment, intraoperative findings and MRN abnormalities ( $k = 0.57$ ). Increased signal intensity correlated with persistency of neurosensory disturbances in one study. Intra- (ICC 0.914–0.927) and interobserver ( $k = 0.70$ – $0.891$ ) MRN variability was considered good to excellent. One retrospective study showed substantial impact of MRN on clinical decision making in one-third of patients.

**Conclusion:** Currently, there is insufficient scientific knowledge to support or refute the use of MRN. Based on limited data, MRN seems promising and reliable in detection and grading of PTTN. Methodological issues underline the importance for prospective blinded studies with standardization of signal intensity calculation and rigorous reporting of MRI acquisition parameters.

*Dentomaxillofacial Radiology* (2020) 50, 20200103. doi: [10.1259/dmfr.20200103](https://doi.org/10.1259/dmfr.20200103)

**Cite this article as:** Van der Cruyssen F, Peeters F, Croonenborghs T-M, Fransen J, Renton T, Politis C, et al. A systematic review on diagnostic test accuracy of magnetic resonance

neurography versus clinical neurosensory assessment for post-traumatic trigeminal neuropathy in patients reporting neurosensory disturbance. *Dentomaxillofac Radiol* 2020; **50**: 20200103.

**Keywords:** magnetic resonance neurography; trigeminal nerve; post-traumatic neuropathy; neuropathic pain

## Background

The peripheral trigeminal nerves are a daily concern for anyone operating in the head and neck area.<sup>1</sup> There is a risk of damage to these branches in numerous dentoalveolar and oral or maxillofacial surgeries such as wisdom tooth extraction, endodontic treatments, placement of implants and administration of local anesthesia.<sup>2</sup> Once damage occurs, there is usually a neurosensory disturbance which can be superimposed with neuropathic pain and phenomena such as allodynia and hyperalgesia. Diagnosing these post-traumatic trigeminal neuropathies (PTTN) and predicting prognosis in the early post-traumatic period is not straightforward.<sup>3–5</sup> Currently, diagnosis is mainly based on patient-reported neurosensory disturbances (NSD) and qualitative or quantitative psychophysical neurosensory tests (NST), which have their own methodological problems.<sup>6</sup> Electrophysiological tests are available but are difficult to apply in the trigeminal distribution.<sup>6</sup> Additionally, they cannot precisely depict the localization and extent of trauma, which is important if surgical management is considered.

From a clinical but also medicolegal point of view, it is important to be able to make a distinction in severity between nerve damage, localization and sensory profiles.<sup>3,7</sup> Many patients experience spontaneous recovery, but in select cases with severe nerve damage, a microsurgical release or repair may be appropriate. It is generally agreed that a faster intervention leads to better neurosensory recovery.<sup>8–12</sup> The current standard in diagnosing pathology of the peripheral sensory nervous system is quantitative sensory testing (QST). It was introduced by the German Research Network on Neuropathic Pain in 2006 and is already strongly substantiated in its value, being that it can clarify if a neurosensory deficit is present or not.<sup>13–19</sup> However, for the time being, it remains unclear how these tests evolve in the transition from the acute to the chronic phases of trigeminal nerve damage and if they can predict prognosis and treatment outcomes in PTTN.<sup>17,20,21</sup>

Magnetic resonance neurography (MRN) is an MRI technique in which dedicated sequences are used to enhance the visualization of the peripheral nervous system and its pathology.<sup>22</sup> It has the potential to visualize and quantify nerve injuries and the associated severity of damage.<sup>23</sup> Evidence has already been demonstrated for plexus lesions and in neuromusculoskeletal imaging, but to the best of our knowledge no aggregate analysis of literature is known for the diagnostic accuracy and value in post-traumatic trigeminal

nerve lesions.<sup>22,24,25</sup> Therefore, the main objective of this study was to conduct a systematic review of diagnostic test accuracy (DTA) of MRN *vs* clinical neurosensory testing or patient-reported NSD in patients with PTTN. Secondary objectives were to identify currently used MRN sequences, their parameters and performance as well as how they correlate with nerve injury severity. Finally, we looked for any impact on clinical decision-making when adding MRN to the diagnostic work-up.

## Methods

### *Systematic search*

The PICO question included (P) patients suffering from PTTN resulting in NSD within the trigeminal distribution who (I) underwent MRI in (C) comparison with clinical (neurological) examination or patient-reported NSD and (O) to assess techniques reported, its diagnostic accuracy, performance and correlation with nerve injury severity. The current systematic review was registered in the International Prospective Register of Ongoing Systematic Reviews (PROSPERO; [https://www.crd.york.ac.uk/PROSPERO/display\\_record.php?RecordID=117971](https://www.crd.york.ac.uk/PROSPERO/display_record.php?RecordID=117971); number: CRD42018117971) and was performed according to the Preferred Reporting Items for Systematic Reviews and Meta-Analysis-Diagnostic Test Accuracy (DTA) guidelines (see Appendix). The abstract was written using the Preferred Reporting Items for Systematic Reviews and Meta-Analysis-DTA for Abstracts checklist. An experienced librarian was consulted before starting the study to co-create the search method. A systematic search was conducted in PubMed, Embase, Web of Science, and Cochrane Library in October 2019 and updated in February 2020. The search query is illustrated in [Table 1](#) and consisted of two concepts: “MRI” and “PTTN”. These concepts were combined using the AND operator. Reference lists of included studies also were screened.

### *Selection criteria*

The search was limited to original research articles without restrictions on language or publication date.

Inclusion criteria included cohort studies, observational case-control, cross-sectional, randomized controlled trials (RCTs) and case series. In general, studies were included if the investigated patients were diagnosed with PTTN on the basis of sensory tests or

**Table 1** Overview of the applied search strategy

Database	Concept 1: MRI	Concept 2: PTTN
Pubmed	“Magnetic Resonance Imaging”[Mesh] OR magnetic-resonance-imag*[tiab] OR MRI[tiab] OR NMR-Imag*[tiab] OR MR-tomography[tiab] OR NMR-tomography[tiab] OR MRI-scan*[tiab] OR fMRI[tiab] OR functional-MRI[tiab] OR functional-magnetic-resonance-imag*[tiab] OR spin-echo-imag*[tiab] OR diffusion-magnetic-resonance-imag*[tiab] OR diffusion-MRI[tiab] OR diffusion-weighted-MRI[tiab] OR nuclear-magnetic-resonance-imag*[tiab] OR arterial-spin-label*[tiab] OR diffusion-tensor-imag*[tiab] OR diffusion-weighted-imag*[tiab] OR dynamic-contrast-enhanced-magnetic-resonance-imag*[tiab] OR multiparametric-magnetic-resonance-imag*[tiab] OR neurography[tiab]	“Trigeminal Nerve Injuries”[Mesh] OR trigeminal-nerve-injur*[tiab] OR Fifth-Cranial-Nerve-Injur*[tiab] OR Traumatic-Fifth-Nerve-Palsies [tiab] OR Traumatic-Trigeminal-Neuropath*[tiab] OR Injury-Cranial Nerve-V[tiab] OR Traumatic-Fifth-Nerve-Palsy[tiab] OR Trauma-Trigeminal-Nerve[tiab] OR Cranial-Nerve-V-Injury[tiab] OR Fifth-Nerve-Trauma[tiab] OR Trigeminal-Nerve-Contusion[tiab] OR Trigeminal-Nerve-Transsection[tiab] OR Trigeminal-Nerve-Avulsion[tiab] OR inferior-alveolar-nerve[tiab] OR lingual-nerve[tiab] OR mandibular-nerve[tiab]
Embase	'magnetic resonance imaging'/exp OR 'magnetic resonance imag*':ti,ab,kw OR 'arterial spin label*':ti,ab,kw OR 'diffusion tensor imag*':ti,ab,kw OR 'diffusion weighted imag*':ti,ab,kw OR 'dynamic contrast-enhanced magnetic resonance imag*':ti,ab,kw OR 'functional magnetic resonance imag*':ti,ab,kw OR 'multiparametric magnetic resonance imag*':ti,ab,kw OR 'perfusion weighted imag*':ti,ab,kw OR 'NMR imag*':ti,ab,kw OR 'MR tomography':ti,ab,kw OR 'NMR tomography':ti,ab,kw OR 'MRI scan':ti,ab,kw OR 'fMRI':ti,ab,kw OR 'functional MRI':ti,ab,kw OR 'functional magnetic resonance imag*':ti,ab,kw OR 'spin echo imag*':ti,ab,kw OR 'diffusion magnetic resonance imag*':ti,ab,kw OR 'diffusion MRI':ti,ab,kw OR 'diffusion weighted MRI':ti,ab,kw OR 'neurography':ti,ab,kw OR 'NMR':ti,ab,kw	'trigeminal nerve injury'/exp OR 'trigeminal nerve injur*':ti,ab,kw OR 'fifth-cranial nerve injur*':ti,ab,kw OR 'traumatic fifth nerve palsies':ti,ab,kw OR 'traumatic trigeminal neuropath*':ti,ab,kw OR 'injury cranial nerve V':ti,ab,kw OR 'traumatic fifth nerve palsy':ti,ab,kw OR 'trauma trigeminal nerve':ti,ab,kw OR 'cranial nerve V injury':ti,ab,kw OR 'fifth nerve trauma':ti,ab,kw OR 'trigeminal nerve contusion':ti,ab,kw OR 'trigeminal nerve transection':ti,ab,kw OR 'trigeminal nerve avulsion':ti,ab,kw OR 'inferior alveolar nerve':ti,ab,kw OR 'lingual nerve':ti,ab,kw OR 'mandibular nerve':ti,ab,kw
Web of Science	“Magnetic resonance imag*” OR “MRI” OR “nuclear magnetic resonance imag*” OR “arterial spin label*” OR “diffusion tensor imag*” OR “diffusion weighted imag*” OR “dynamic contrast-enhanced magnetic resonance imag*” OR “functional magnetic resonance imag*” OR “multiparametric resonance imag*” OR “perfusion weighted imag*” OR “neurography” OR “NMR” OR “MR tomography” OR “NMR tomography” OR “MRI-scan” OR “functional MRI” OR “functional magnetic resonance imag*” OR “diffusion MRI” OR “diffusion weighted MRI” OR “nuclear magnetic resonance imag*” OR “fMRI”	“Trigeminal nerve injury” OR “Trigeminal nerve injur*” OR “fifth cranial nerve injur*” OR “traumatic fifth nerve palsies” OR traumatic trigeminal neuropath*” OR “injury cranial nerve V” OR “traumatic fifth nerve palsy” OR “trauma trigeminal nerve” OR cranial nerve V injury” OR “fifth nerve trauma” OR “trigeminal nerve contusion” OR “trigeminal nerve transection” OR “trigeminal nerve avulsion” OR “inferior alveolar nerve” OR “lingual nerve” or “mandibular nerve”
Cochrane library	# 1: [mh “magnetic resonance imaging”] # 2: ((magnetic NEXT resonance NEXT imag*) OR MRI):ti,ab,kw # 3: (nuclear NEXT magnetic NEXT resonance NEXT imag*):ti,ab,kw # 4: (arterial NEXT spin NEXT label*):ti,ab,kw # 5: (diffusion NEXT tensor NEXT imag*):ti,ab,kw # 6: (diffusion NEXT weighted NEXT imag*):ti,ab,kw # 7: (dynamic NEXT contrast NEXT enhanced NEXT magnetic NEXT resonance NEXT imag*):ti,ab,kw # 8: (functional NEXT magnetic NEXT resonance NEXT imag*):ti,ab,kw # 9: (multiparametric NEXT resonance NEXT imag*):ti,ab,kw # 10: (perfusion NEXT weighted NEXT imag*):ti,ab,kw # 11: (neurography):ti,ab,kw # 12: (NMR):ti,ab,kw # 13: (MR NEXT tomography):ti,ab,kw # 14: (NMR tomography):ti,ab,kw # 15: (MRI-scan):ti,ab,kw # 16: (functional NEXT MRI):ti,ab,kw # 17: (functional NEXT magnetic NEXT resonance NEXT imag*):ti,ab,kw # 18: (diffusion NEXT MRI): ti,ab,kw # 19: (diffusion NEXT magnetic NEXT resonance NEXT imag*):ti,ab,kw # 20: (diffusion NEXT weighted NEXT MRI):ti,ab,kw # 21: (fMRI):ti,ab,kw # 22: #1 OR #2 OR #3 OR #4 OR #5 OR #6 OR #7 OR #8 OR #9 OR #10 OR #11 OR #12 OR #13 OR #14 OR #15 OR #16 OR #17 OR #18 OR #19 OR #20 OR #21	# 1:[mh “trigeminal nerve injuries”] # 2: (trigeminal NEXT nerve NEXT injur*):ti,ab,kw # 3: (fifth NEXT cranial NEXT nerve NEXT injur*):ti,ab,kw # 4: (traumatic NEXT fifth NEXT nerve NEXT palsies):ti,ab,kw # 5: (traumatic NEXT trigeminal NEXT neuropath*):ti,ab,kw # 6: (injury NEXT cranial NEXT nerve NEXT V):ti,ab,kw # 7: (traumatic NEXT fifth NEXT nerve NEXT palsy):ti,ab,kw # 8: (trauma* NEXT trigeminal NEXT nerve):ti,ab,kw # 9: (cranial NEXT nerve NEXT V NEXT injury):ti,ab,kw # 10: (fifth NEXT nerve NEXT trauma):ti,ab,kw # 11: (trigeminal NEXT nerve NEXT contusion):ti,ab,kw # 12: (trigeminal NEXT nerve NEXT transection):ti,ab,kw # 13: (trigeminal NEXT nerve NEXT avulsion):ti,ab,kw # 14: (inferior NEXT alveolar NEXT nerve):ti,ab,kw # 15: (lingual NEXT nerve):ti,ab,kw # 16: (mandibular NEXT nerve):ti,ab,kw #17: #1 OR #2 OR #3 OR #4 OR #5 OR #6 OR #7 OR #8 OR #9 OR #10 OR #11 OR #12 OR #13 OR #14 OR #15 OR #16

PTTN, post-traumatic trigeminal neuropathy.  
Concept 1 and 2 were combined with the AND operator.

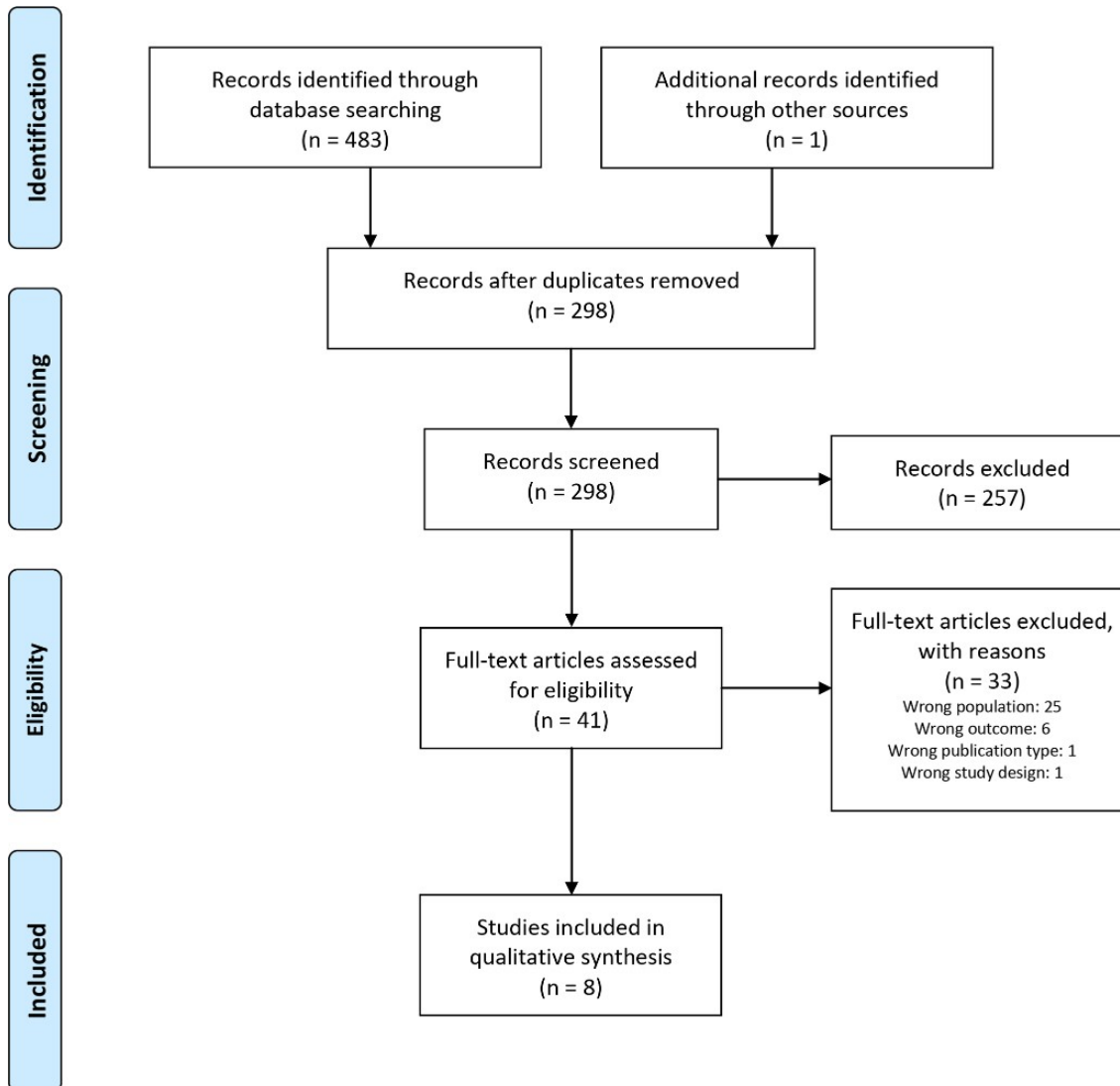
patient-reported NSD and if MRN was examined as an index test.

Exclusion criteria included animal trials, case reports, reviews, systematic reviews and meta-analyses.

### Screening and selection of records

The first author (FVDC) executed the literature search and exported all references to Rayyan QCRI after deduplication.<sup>26</sup> Two researchers (FVDC and FP)

independently screened titles and abstracts according to inclusion and exclusion criteria. Disagreements were resolved in a consensus meeting with a third researcher (TMC). The first author screened the reference lists for additional articles that did not appear in the systematic search. Both researchers again independently determined which articles should be retained and consensus was reached in a second consensus meeting with the three researchers.



**Figure 1** Flow diagram according to PRISMA illustrating the systematic search and results. PRISMA, Preferred Reporting Items for Systematic Reviews and Meta-Analysis.

#### *Risk of bias assessment*

The Quality Assessment of Diagnostic Accuracy Studies 2 (QUADAS-2) tool was used to assess the risk of bias and applicability concerns.<sup>27</sup> Four levels were tested, including patient selection, index test, reference standard and flow and timing. A total score was plotted and indicates if included studies were at high, low or unclear risk of bias or applicability concern. FVDC and FP both independently assessed the included studies according to the QUADAS-2 manual. Discrepancies were discussed in a meeting with a third researcher aiding (TMC) in reaching a consensus. Resulting scores were plotted on a stacked bar chart.

#### *Recorded variables, data collection and analysis*

Predetermined variables were extracted from the selected articles when possible and included: type of

study, use of a reporting guideline, number of patients, age and gender, inclusion criteria, review questions, timing of MRI acquisition, investigated nerve branch, number of nerves observed, reference test, MRI device, coil type, sequence and sequence settings, use of post-processing techniques, use of contrast, evaluator level, blinding of evaluators, number of readings, type of analysis, formulas used for calculations, measurement areas and region of interests, intra- and interobserver variability, nerve caliber and relative signal intensity, correlation of MRN with NST, clinical and surgical findings, impact on clinical management and the author's conclusions. The first author extracted the data and correctness was verified by the second author.



**Table 2** QUADAS-2 risk assessment for each included study

Study	Risk of bias				Applicability concerns		
	Patient selection	Index test	Reference standard	Flow and timing	Patient selection	Index test	Reference standard
Zuniga <i>et al.</i> (2018) <sup>31</sup>	☹️	☹️	😊	☹️	😊	😊	😊
Dessouky <i>et al.</i> (2018) <sup>33</sup>	😊	😊	☹️	😊	😊	😊	😊
Terumitsu <i>et al.</i> (2017) <sup>29</sup>	☹️	😊	☹️	☹️	?	😊	☹️
Cox <i>et al.</i> (2016) <sup>32</sup>	😊	😊	☹️	☹️	😊	😊	😊
Cassetta <i>et al.</i> (2014) <sup>35</sup>	?	😊	😊	😊	😊	😊	😊
Terumitsu <i>et al.</i> (2011) <sup>28</sup>	☹️	?	☹️	☹️	☹️	😊	☹️
Kress <i>et al.</i> (2004) <sup>30</sup>	☹️	☹️	☹️	☹️	☹️	☹️	☹️
Kress <i>et al.</i> (2003) <sup>34</sup>	☹️	☹️	☹️	?	☹️	😊	😊

QUADAS 2, Quality Assessment of Diagnostic Accuracy Studies 2. M3: third molar; “?”: unclear; ☹️: high risk; 😊: low risk.

## Results

### Study selection

The search yielded 483 articles, and 1 additional article was retrieved by reference list screening. After deduplication, 298 articles remained. These were screened based on title and abstract, after which 41 articles remained for full-text analysis. Eight articles were retained for the systematic review. Overview of the selection procedure is shown in Figure 1.

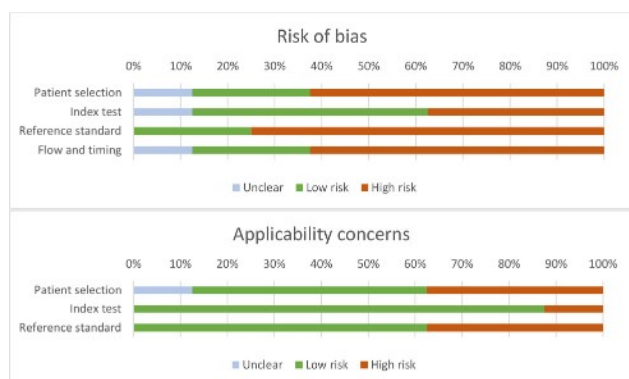
### Study characteristics

Most included studies were retrospective (7/8) and 5 of these were case series, representing 444 subjects in total.<sup>28–32</sup> Two studies applied a case–control design<sup>33,34</sup> and one study a prospective cohort design.<sup>35</sup> None of the articles mentioned the use of a reporting guideline. Using the QUADAS-2 tool, most studies were at

high risk of bias but with low applicability concerns (Table 2, Figure 2). The inclusion criteria and study-specific research questions turned out to be divergent (Table 3). There was a large variation in timing of the MRI acquisition (3 days–17 years). All studies assessed the inferior alveolar nerve (IAN) and some additionally included lingual nerve injuries (4/8). The reference test mostly consisted of a clinical (neurological) evaluation. Four studies added intraoperative findings as a reference test.<sup>31–34</sup> In three studies it was unclear which reference test was applied.<sup>29,30,34</sup> Due to the low methodological quality with widely varying methods, a DTA-analysis nor a meta-analysis could be performed. Consequently, after consultation with all authors, it was decided to provide a broad overview of the study and MRN characteristics, the evaluation methods used, their results and the conclusions drawn by the authors of the selected articles.

### Synthesis of results

**Characteristics of included studies & MRI parameters:** An overview of all MRN parameters is given in Table 4. The majority of included studies used 3.0 T Philips scanners (5/8). Three studies originated from the same research group.<sup>31–33</sup> This research group used a multichannel head coil; other groups used neurovascular (3/8), temporomandibular joint (1/8), or custom-made coils (1/8). Sequence protocols differed between all studies. However, six studies used gradient echo  $T_2$  weighted imaging with short echo times (2.2–100 ms). Slice thickness varied between 0.6 and 5 mm. Fat suppression was achieved by using adiabatic inversion pulses in the group of Chhabra *et al.* Terumitsu *et al* applied a chemical shift selective pulse. Three studies



**Figure 2** QUADAS-2 risk of bias assessment results. QUADAS 2, Quality Assessment of Diagnostic Accuracy Studies 2.

**Table 3** Characteristics of included studies

Study	Nature	Design	Reported guideline	Number of Patients (M/F)	Inclusion criteria	Review question	Timing of MRI acquisition	Investigated nerve (number of nerves investigated)	Reference test
Zuniga et al. (2018) <sup>31</sup>	Retrospective	Case series	NS	60 Patients	Suspected peripheral trigeminal neuropathy	(1) Can MRN differentiate normal from abnormal/non-injured nerves (2) Correlation of MRN with clinical NST and surgical findings	NS	LN (20) IAN (40)	Clinical NST (60/60) Intraoperative findings (26/60)
Dessouky et al. (2018) <sup>33</sup>	Retrospective	Case-control	NS	24 Patients (10/14) 18 Controls (3/15)	Neurosensory disturbances of IAN or LN	(1) MRN can differentiate between normal and injured nerves (2) Nerve injury classification correlates with MRN, NST and surgical classification	NS	IAN (NS) LN (NS) (122 in total)	Clinical NST (24) Intraoperative findings (24)
Terumitsu et al. (2017) <sup>29</sup>	Retrospective	Case series	NS	19 (4/15)	Persistent neurosensory disturbances of IAN or LN	(1) Anatomic evaluation IAN or LN using 3DACC-PROPELLOR sequence (2) Correlation of NSD severity with MRI morphology	Ranging from 1 month to 108 months after start of symptoms	IAN (12) LN (7)	Patient reported symptoms Contralateral side
Cox et al. (2016) <sup>32</sup>	Retrospective	Case series	NS	17 Patients (7/10)	Suspected peripheral trigeminal neuropathy	(1) Assess correlation of MRN with surgical findings (2) Assess impact of MRN on clinical management	Ranging from 2 weeks to 17 years after start of symptoms	LN (4) IAN (13)	Contralateral side? Intraoperative findings
Cassetta et al. (2011) <sup>35</sup>	Prospective	Cohort	NS	196 Patients (112/84)	Indication for mandibular third molar extraction AND on panoramic radiograph: root apexes reach upper border mandibular canal OR Superimposition of roots over mandibular canal	Course of inferior alveolar neurovascular bundle and SI after third molar surgery	3 days postoperative	IAN (343)	Clinical evaluation +QST (before and after operation)
Terumitsu et al. (2011) <sup>28</sup>	Retrospective	Case series	NS	16 Patients (3/13)	Persistent neurosensory disturbances of IAN	Evaluating IAN using high-resolution 3D volume rendering	Ranging from 1 month to 8 years after start of symptoms	IAN (16)	Clinical evaluation Contralateral side

(Continued)

Table 3 (Continued)

Study	Nature	Design	Reported guideline	Number of Patients (MIF)	Inclusion criteria	Review question	Timing of MRI acquisition	Investigated nerve (number of nerves investigated)	Reference test
Kress <i>et al.</i> (2004) <sup>30</sup>	Retrospective	Case-control	NS	30 Healthy subjects 41 Patients (39/2)	MRI following removal of third molar because of swelling, abscess or postoperative bleeding All patients were free of neurological symptoms	Response of neurovascular bundle to trauma associated with third molar surgery	3–36 h postoperative	IAN (73)	Contralateral side? Healthy mandibles
Kress <i>et al.</i> (2003) <sup>34</sup>	Retrospective	Case series	NS	23 Patients (19/4)	Fracture of the mandible	(1) Visualize the neurovascular bundle after mandibular fracture (2) Assess its continuity	After fracture but before operative reduction and fixation of the fracture	IAN (21)	Intraoperative evaluation of neurovascular bundle Healthy mandibles

F, female; IAN, inferior alveolar nerve; LN, lingual nerve; M, male; MRN, magnetic resonance neurography; NS, not specified; NSD, neurosensory disturbances; NST, neurosensory testing; QST, quantitative sensory testing; SI, signal intensity.

made use of contrast agents. Post-processing was done in all studies and included multiplanar reformatting (MPR) following the nerve trajectory.

**MRI evaluation:** The evaluation of MRN images and classification was carried out differently in each study (Table 5). Blinding of observers was not guaranteed in most studies (5/8). The number of readings was not mentioned in five articles. In addition to a qualitative analysis, four studies carried out a quantitative analysis. Signal intensities (SIs) or relative signal intensities (RSIs) of target areas were calculated based on different formulas, at different sites and with different measurement areas. These calculations were therefore not comparable.

**Summary of findings:** PTTN correlated with MRN abnormalities including nerve deformity and signal alterations (Table 6). Terumitsu found that deformity of the nerve was correlated with severity of symptoms. Nerve injury resulted in increased RSI in six studies. Cassetta *et al* concluded that higher RSIs correlated with PTTN persisting beyond three months after injury. Pathologic nerve enlargement in PTTN patients was mentioned in six studies.

MRN intraobserver variability was reported in one study by Cassetta (intraclass correlation coefficient 0.914–0.927). Interobserver agreement was reported by Cohen's  $\kappa$  ( $k$ ) in three studies and ranged from 0.70 to 0.891.

Correlation of MRN findings with NST or clinical evaluation was reported by the group of Chhabra *et al* in two studies ( $k = 0.57$ ). Correlation of MRN findings with surgical exploration ranged from moderate to excellent and was reported in four studies.

The impact of MRN on clinical decision-making was reported in one study by Cox *et al*. They stated that 29% did not have a change in clinical management and in 35% of cases MRN had substantial impact on their management, meaning a change in treatment.

## Discussion

MRN appears promising in the detection and grading of post-traumatic trigeminal lesions and correlates with clinical and surgical findings as well as neurosensory testing. However, there is a large heterogeneity in the reported studies with high risk of bias. None of the studies reported the use of a guideline or framework such as the STARD guideline.<sup>36</sup> This makes reproducibility and further MRN research difficult. Partly because of this, our primary objective to measure the diagnostic accuracy of MRN in patients with PTTN was not achieved.

Most research groups used 3 T scanners with  $T_2$  weighted gradient echo imaging. Coil type differed between studies, further complicating comparison between protocols. Uniform fat suppression is important

**Table 4** MRI parameters for each study

Study	MRI device	MRI coil	Sequence protocol	Generic MRI Technique	Acquisition orientation	TE (echo time) (ms)	TR (repetition time) (ms)	Slice thickness (mm)	Matrix (pixels)	FOV (cm)	Number of excitations	Flip angle (°)	Other parameters	Fat suppression techniques	Post processing	Contrast
Zuniga et al. (2018) <sup>31</sup>	1.5T Siemens Avanto 3.0T Philips Ingenia 3.0T Philips Achieva	Multichannel headcoil	T2 SPAIR T1W CISS 3D DTI 3D STIR SPACE 3D DW PSIF	Spectral attenuated inversion recovery Conventional Balanced dual excitation Diffusion tensor imaging Short tau IR Reverse-echo gradient-echo	Axial Axial Axial Axial Coronal Coronal	69 8.7 2.66 83 78 3.25	5320 710 5.32 7100 3000 12	3.5 3.5 0.8 4 1.5 (iso) 0.9 (iso)	320 × 342 320 × 342 to chin 256 × 256 74 × 74 to chin 320 × 259 Suprasellar area 256 × 208 to C2	Corpus callosum to chin Corpus callosum to chin Corpus callosum to chin Skull base to chin Corpus callosum to chin Corpus callosum to chin			Adiabatic inversion pulse	MPR coronal and oblique following nerve trajectory	No	
Dessokey et al. (2018) <sup>33</sup>	1.5T Siemens Avanto 3.0T Philips Ingenia 3.0T Philips Achieva	Multichannel headcoil	3D DW PSIF	Reverse-echo gradient-echo	Coronal	3.25	12	0.9 (iso)	256 × 208 to chin	Corpus callosum to chin			Adiabatic inversion pulse	MPR coronal and oblique following nerve trajectory	No	
Terumitsu et al. (2017) <sup>29</sup>	3.0T GE SIGNA	8CH neurovascular Custom 3-inch surface coil	PROPELLOR	Diffusion-weighted imaging	Coronal/axial	78.7	4000	5	128 × 128 18 × 18 (neurovascular coil) 11 × 11 (surface coil)		3				MPR coronal and oblique following nerve trajectory 3DAC	No
Cox et al. (2016) <sup>32</sup>	1.5T Siemens Avanto	Multichannel headcoil	T2 SPAIR T1W CISS 3D DTI 3D STIR SPACE 3D DW PSIF	Spectral attenuated inversion recovery Conventional Balanced dual excitation Diffusion tensor imaging Short tau IR Reverse-echo gradient-echo	Axial Axial Axial Axial Coronal Coronal	69 8.7 2.66 83 78 3.25	5320 710 5.32 7100 3000 12	3.5 3.5 0.8 4 1.5 (iso) 0.9 (iso)	320 × 342 320 × 342 to chin 256 × 256 74 × 74 to chin 320 × 259 Suprasellar area 256 × 208 to C2	Corpus callosum to chin Corpus callosum to chin Skull base to chin Corpus callosum to chin Corpus callosum to chin			Tau = 160 ms B values: 0, 800, 1000/Directions: pulse 12	MPR coronal and oblique following nerve trajectory	2/17 Patients	
Cassetta et al. (2014) <sup>35</sup>	3.0T GE Discovery MR750	8CH neurovascular	3D FIESTA (T2) 3D SPGR (T1)	Balanced gradient-echo Fast gradient-echo	Axial Axial	2.2 3	4.6 8	0.6 0.6	512 × 512 20 × 20 512 × 512 15 × 21		1 2			Standard + MPR following nerve trajectory	No	
Terumitsu et al. (2011) <sup>28</sup>	3.0T GE	8CH neurovascular	3D SPGR (T1)	Incoherent gradient-echo	Not mentioned	4.06	15.576	1.0	320 × 256 18 × 18		2	20	Bandwidth 31.2 kHz / Voxel size = 0.35 x 0.35 mm x 0.5 mm (CHES)	Chemical shift-selective + MPR following nerve trajectory Ray-casting process	No	

(Continued)



**Table 4** (Continued)

Study	MRI device	MRI coil	Sequence protocol	Generic MRI Technique	Acquisition orientation	TE (echo time) (ms)	TR (repetition time) (ms)	Slice thickness (mm)	Matrix (pixels)	FOV (cm)	Number of excitations	Flip angle (°)	Other parameters	Fat suppression techniques	Post processing	Contrast
Kress <i>et al.</i> (2004) <sup>30</sup>	Philips (no further specifics)	Temporomandibular joint coil	T2 TSE T1 FFE	Turbo spin-echo Incoherent gradient-echo	Axial Sagittal	100 6.1	4523 15	3 1.5	512 × 326 512 × 326	23 x ? 27 x ?				Principle Of Selective Excitation Technique (Proset)	MPR parasagittal following nerve trajectory	Yes
Kress <i>et al.</i> (2003) <sup>34</sup>	1.5T (no further specifics)	Not mentioned	T1-weighted Proton density	Conventional Conventional	Not mentioned	6.1 6.1	15 15	1.5 1.5	512 × 326 512 × 326	27 x ? 27 x ?	30 15		Fat saturated MPR	MPR parasagittal following nerve trajectory	Yes	

CH, channel; FA, flip angle; FFE, fast field echo; FIESTA, fast spoiled gradient recalled echo; FOV, field of view; FS, fat saturated; MPR, multiplanar reformatting; SPGR, spoiled gradient recalled echo; TE, time to echo; TR, repetition time.

to allow adequate evaluation of the peripheral nervous system.<sup>22</sup> Different methods have been described to achieve this and were observed in the selected studies of this review.<sup>37</sup> Future studies should identify which of these sequences render the best suppression and thus nerve selective imaging of the peripheral trigeminal branches.

Post-processing was performed in all studies in which multiplanar reformatting was applied along the course of the nerve. Given the tortuous course of the trigeminal nerve, this would allow for a more holistic assessment. An isotropic voxel size is preferable to further assess its course in three dimensions, improving resolution and possibly reducing artifacts.<sup>38</sup> This requires a thin slice thickness to adequately visualize these fine nerve branches, which are often less than 2 mm in diameter.<sup>39</sup>

Image interpretation and reporting was diverse with considerable methodological concerns. The outcomes that were assessed ranged from qualitative anatomic considerations towards quantitative RSI calculations. SI calculations require a methodological approach to allow standardization, especially if pulsed sequences are used.<sup>40,41</sup> Since the RSI value seems of prognostic importance as illustrated by Cox *et al*, determining a standard approach and cutoff values is important for future research into DTA of MRN.<sup>32</sup> In the included studies no cutoff values for relative signal intensity were defined; however the study by Dessouky *et al* did report sensitivity and specificity for MRN compared to clinical neurosensory testing and surgical findings, suggesting they determined cut-off values.<sup>33</sup> They reported moderate to good correlation of MRN with injury severity, which was measured using NST or was surgically observed. Additionally, we need to consider that the region of interest where RSI values are measured would depend on the etiology of the PTTN and differ depending on the patient inclusion criteria, further complicating future comparison of studies. Therefore, mapping of the whole nerve trajectory could be a methodological approach to consider in future DTA studies.<sup>42</sup>

Finally, the use of MRN and its impact on clinical decision-making was demonstrated in one retrospective study by Cox *et al.*<sup>32</sup> They illustrated a substantial impact in about one-third of patients, meaning a change in treatment. Although this concerns a small number of patients, it immediately raises the question whether this also has had an impact on outcomes and quality of life. Additionally, future studies should add a cost-benefit analysis of adding MRN to the diagnostic work-up. Limitations of this review are the small number of articles obtained, which were of low quality with different methodologies and results. No randomized controlled trials could be identified. Because of these arguments, DTA could not be determined.

In conclusion, there is insufficient scientific base to support or refute the use of MRN in the diagnosis and grading of PTTN. MRN seems promising in improving PTTN diagnostics and steering treatment decision.

**Table 5** MRI evaluation and analysis for each study

Study	Evaluation by	Blinded observer?	Number of readings	Type of analysis or measurement	Type of variable	Used formula	Signal intensity measurement area	Region of interest
Zuniga et al. (2018) <sup>31</sup>	2 Musculoskeletal radiologists	No (aware of clinical findings, not of NST)	1	Modified Sunderland classification	Categorical	/	/	/
Dessouky et al. (2018) <sup>33</sup>	Expert radiologist (classification) 2 Expert radiologists (measurements)	No (classification) Yes (measurements)	NS (Training with six scans)	Modified Sunderland classification T2SIR CNR Nerve thickness	Categorical Quantitative	T2SIR = SI nerve $\div \sqrt{\text{SI nerve}}$ CNR = SI nerve - SI pterygoid muscle $\div \sqrt{\text{SI nerve}}$	SI: freehand ROI	Control group: predefined landmarks • Coronal midmandibular canal • Nerve thickness IAN: maximum transverse dimension in midmandibular canal • Nerve thickness LN: maximum transverse dimension in its midcourse Patient group: site of most visible abnormality of affected nerve
Terumitsu et al. (2017) <sup>29</sup>	3 Neuroimaging researchers	Yes	NS	Isolated, deformity or incorporated nerve lesion	Categorical	/	/	/
Cox et al. (2016) <sup>32</sup>	Multiple (radiologist attending, fellows)	No	1	Signal change/caliber change: Y/N Mass lesion: Y/N Perineural fibrosis: Y/N Final impression: Y/N	Categorical	/	/	/
Cassetta et al. (2014) <sup>35</sup>	2 Expert radiologists	Yes	3	First session: course of IAN Second session: SI/RSI measurements Third session (1 month after second session): RSI	Qualitative Quantitative	SI on coronal reconstructed FIESTA RSI = SI ROI nerve at surgical site/SI ROI masseter muscle	15 mm <sup>2</sup>	IAN at M3 masseter muscle (reference to calculate RSI)
Terumitsu et al. (2011) <sup>28</sup>	NS	NS	NS	Enlargement/tortuosity: Y/N Mass: Y/N Diffuse connective tissue: Y/N Other: Y/N	Categorical	/	/	/
Kress et al. (2004) <sup>30</sup>	NS	NS	NS	Increase in SI was assessed on T1-weighted images comparing non-contrast versus contrast-enhanced sequences	Quantitative	$S_{i_{rel}} = (S_{ic} - S_{in}) / S_{in} \times 100$	area not defined	Ascending ramus Second premolar, M1, M2, M3
Kress et al. (2003) <sup>34</sup>	Radiologist	Yes	NS	Continuity was assessed on PD images Increase in SI was assessed on T1-weighted images comparing non-contrast versus contrast-enhanced sequences	Qualitative Quantitative	$S_{i_{rel}} = (S_{ic} - S_{in}) / S_{in} \times 100$	15–32 voxels	two regions proximal, two regions distal of fracture site

CNR, contrast-to-noise ratio; IAN, inferior alveolar nerve; LN, lingual nerve; M1, first molar; M2, second molar; M3, third molar; NS, not specified; NST, neurosensory testing; ROI, region of interest; RSI, relative SI; SI, signal intensity;  $S_{ic}$ , SI after contrast administration;  $S_{in}$ , SI before contrast administration;  $S_{i_{rel}}$ , relative intensity increase; T2SIR, signal intensity on T2 image; Y/N, yes/no.

However, shortcomings in methodology currently prevent the determination of DTA in a PTTN population. There is a need for prospective blinded DTA studies evaluating MRN versus QST in PTTN with a rigorous and reproducible study design if a broader clinical implementation is to be achieved.

## Implications

This systematic review shows that MRN could aid in the diagnosis, treatment decision and prediction of neurosensory recovery of PTTN. However, current studies are

**Table 6** Summary of findings

Study	MRN		Nerve Thickness of pathologic nerve	Correlation with clinical/NST findings	Correlation with surgical findings	Impact on clinical management	Author's conclusion
	Intraobserver variability (ICC)	MRN Interobserver agreement (k)					
Zuniga et al. (2018) <sup>31</sup>	NS	NS	Enlargement	$k = 0.57$	$k = 0.5$ PCC = 0.67	None: 5/17 Mild: 6/17 Substantial: 6/17	Good to moderate correlation of MRN with NST and surgical findings
Dessouky et al. (2018) <sup>33</sup>	NS	0.75–0.83 (LN) 0.70–0.79 (IAN)	Enlargement	$k = 0.57$ PCC = 0.68	$k = 0.4$ PCC = 0.81	None: 5/17 Mild: 6/17 Substantial: 6/17	(1) MRN is reliable and accurate for diagnosis of PTN related to third M3 extractions (2) Good to excellent correlation of imaging findings with clinical and surgical results
Terumitsu et al. (2017) <sup>29</sup>	NS	NS	Enlargement	N/A	N/A	None: 5/17 Mild: 6/17 Substantial: 6/17	Deformity of the nerve is correlated with severity of symptoms
Cox et al. (2016) <sup>32</sup>	NS	NS	Enlargement	NS	Moderate to excellent*	None: 5/17 Mild: 6/17 Substantial: 6/17	(1) Moderate to excellent correlation between MRN and surgical exploration (2) Significant impact on clinical management
Cassetta et al. (2014) <sup>35</sup>	0.927 (Reader 1) 0.914 (Reader 2)	0.891	Enlargement	NS	N/A	NS	(1) Course of IAN did not differ (2) Neurosensory disturbances persisting beyond 3 months had higher nerve RSI
Terumitsu et al. (2011) <sup>28</sup>	NS	NS	Enlargement	N/A	N/A	NS	15/16 cases with clinical symptoms showed MR abnormalities
Kress et al. (2004) <sup>30</sup>	NS	NS	NS	NS	N/A	NS	SI increase after M3 removal comparing to healthy mandibles when measuring at second molar and second premolar area

(Continued)

Table 6 (Continued)

Study	MRN Intraobserver variability (ICC)	MRN Interobserver agreement (k)	Relative Signal Intensity of pathologic nerve	Nerve Thickness of pathologic nerve	Correlation with clinical/INST findings	Correlation with surgical findings	Impact on clinical management	Author's conclusion
Kress <i>et al.</i> (2003) <sup>34</sup>	NS	NS	Increased	NS	NS	$\kappa = 1$	NS	(1) Continuity or discontinuity of IAN could be correctly observed on MRI (2) Fracture induced increased signal intensity after contrast administration compared to healthy mandibles

IAN, inferior alveolar nerve; LN, lingual nerve; M3, third molar; N/A, not applicable; NS, not specified; PCC, Pearson correlation coefficient; PTTN, post-traumatic trigeminal neuropathy; RSI, relative signal intensity; SD, standard deviation; SI, signal intensity;  $k$ , Cohen's  $k$ .

at high risk of bias, indicating the need for prospective blinded studies with a rigorous study design, allowing to determine diagnostic test accuracy.

## REFERENCES

1. Renton T, Van der Cruyssen F. Diagnosis, pathophysiology, management and future issues of trigeminal surgical nerve injuries. *Oral Surg [Internet]* 2019;: 1–15.
2. Klazen Y, Van der Cruyssen F, Vranckx M, Van Vlierberghe M, Politis C, Renton T, *et al.* Iatrogenic trigeminal post-traumatic neuropathy: a retrospective two-year cohort study. *Int J Oral Maxillofac Surg* 2018; **47**: 789–93. doi: <https://doi.org/10.1016/j.ijom.2018.02.004>
3. Themistocleous AC, Crombez G, Baskozos G, Bennett DL. Using stratified medicine to understand, diagnose, and treat neuropathic pain. *Pain* 2018; **159 Suppl 1**: S31–42. doi: <https://doi.org/10.1097/j.pain.0000000000001301>
4. Zakrzewska JM. Differential diagnosis of facial pain and guidelines for management. *Br J Anaesth* 2013; **111**: 95–104. doi: <https://doi.org/10.1093/bja/aet125>
5. Schnabel A. Acute neuropathic pain and the transition to chronic postsurgical pain. *Pain Manag* 2018; **8**: 317–9. doi: <https://doi.org/10.2217/pmt-2018-0026>
6. Teerijoki-Oksa T, Forssell H, Jääskeläinen SK, Jaaskelainen SK, Teerijoki-Oksa T, Forssell H. Validation of diagnostic methods for traumatic sensory neuropathy and neuropathic pain. *Muscle Nerve* 2019; **59**: 342–7. doi: <https://doi.org/10.1002/mus.26400>
7. Bouhassira D, Attal N. Translational neuropathic pain research: a clinical perspective. *Neuroscience* 2016; **338**: 27–35. doi: <https://doi.org/10.1016/j.neuroscience.2016.03.029>
8. Zuniga JR, Yates DM, Phillips CL. The presence of neuropathic pain predicts postoperative neuropathic pain following trigeminal nerve repair. *J Oral Maxillofac Surg* 2014; **72**: 2422–7. doi: <https://doi.org/10.1016/j.joms.2014.08.003>
9. Bagheri SC, Meyer RA, Cho SH, Thoppay J, Khan HA, Steed MB. Microsurgical repair of the inferior alveolar nerve: success rate and factors that adversely affect outcome. *J Oral Maxillofac Surg* 2012; **70**: 1978–90. doi: <https://doi.org/10.1016/j.joms.2011.08.030>
10. Bagheri SC, Meyer RA, Khan HA, Kuhmichel A, Steed MB. Retrospective review of microsurgical repair of 222 lingual nerve injuries. *J Oral Maxillofac Surg* 2010; **68**: 715–23. doi: <https://doi.org/10.1016/j.joms.2009.09.111>
11. Robinson PP, Loescher AR, Smith KG, prospective A. A prospective, quantitative study on the clinical outcome of lingual nerve repair. *Br J Oral Maxillofac Surg* 2000; **38**: 255–63. doi: <https://doi.org/10.1054/bjom.2000.0463>
12. Kushnerev E, Yates JM. Evidence-Based outcomes following inferior alveolar and lingual nerve injury and repair: a systematic review. *J Oral Rehabil* 2015; **42**: 786–802. doi: <https://doi.org/10.1111/joor.12313>
13. Rolke R, Baron R, Maier C, Tölle TR, Treede R-D, Beyer A, *et al.* Quantitative sensory testing in the German research network on neuropathic pain (DFNS): standardized protocol and reference values. *Pain* 2006; **123**: 231–43. doi: <https://doi.org/10.1016/j.pain.2006.01.041>
14. Jääskeläinen SK. Clinical neurophysiology and quantitative sensory testing in the investigation of orofacial pain and sensory function. *J Orofac Pain* 2004; **18**: 85–107.
15. Jääskeläinen SK, Teerijoki-Oksa T, Forssell H. Neurophysiologic and quantitative sensory testing in the diagnosis of trigeminal neuropathy and neuropathic pain. *Pain* 2005; **117**: 349–57. doi: <https://doi.org/10.1016/j.pain.2005.06.028>
16. Agbaje J, De Laat A, Constantinus P, Svensson P, Baad-Hansen L. Agreement between quantitative and qualitative sensory testing of changes in oro-facial somatosensory sensitivity. *J Oral Rehabil* 2017; **44**: 30–42. doi: <https://doi.org/10.1111/joor.12455>



17. Svensson P, Baad-Hansen L, Pigg M, List T, Eliav E, Ettlin D, et al. Guidelines and recommendations for assessment of somatosensory function in oro-facial pain conditions—a taskforce report. *J Oral Rehabil* 2011; **38**: 366–94. doi: <https://doi.org/10.1111/j.1365-2842.2010.02196.x>
18. Haanpää M, Attal N, Backonja M, Baron R, Bennett M, Bouhassira D, Smith BH, Kauppila T, Rowbotham M, et al. NeuPSIG guidelines on neuropathic pain assessment. *Pain* 2011; **152**: 14–27. doi: <https://doi.org/10.1016/j.pain.2010.07.031>
19. Forstenpointner J, Otto J, Baron R. Individualized neuropathic pain therapy based on phenotyping. *Pain* 2018; **159**: 569–75. doi: <https://doi.org/10.1097/j.pain.0000000000001088>
20. Pigg M, Svensson P, List T. Orofacial thermal thresholds: time-dependent variability and influence of spatial summation and test site. *J Orofac Pain* 2011; **25**: 39–48.
21. Backonja MM, Attal N, Baron R, Bouhassira D, Drangholt M, Dyck PJ, et al. Value of quantitative sensory testing in neurological and pain disorders: NeuPSIG consensus. *Pain* 2013; **154**: 1807–19. doi: <https://doi.org/10.1016/j.pain.2013.05.047>
22. Chhabra A, Madhuranthakam AJ, Andreisek G. Magnetic resonance neurography: current perspectives and literature review. *Eur Radiol* 2018; **28**: 698–707. doi: <https://doi.org/10.1007/s00330-017-4976-8>
23. Dessouky R, Xi Y, Zuniga J, Chhabra A. Role of Mr neurography for the diagnosis of peripheral trigeminal nerve injuries in patients with prior molar tooth extraction. *AJNR Am J Neuroradiol* 2018; **39**: 162–9. doi: <https://doi.org/10.3174/ajnr.A5438>
24. Wang X, Harrison C, Mariappan YK, Gopalakrishnan K, Chhabra A, Lenkinski RE, et al. Mr neurography of brachial plexus at 3.0 T with robust fat and blood suppression. *Radiology* 2017; **283**: 538–46. doi: <https://doi.org/10.1148/radiol.2016152842>
25. Bäumer P, Dombert T, Staub F, Kaestel T, Bartsch AJ, Heiland S, et al. Ulnar neuropathy at the elbow: MR neurography—nerve T2 signal increase and caliber. *Radiology* 2011; **260**: 199–206. doi: <https://doi.org/10.1148/radiol.11102357>
26. Ouzzani M, Hammady H, Fedorowicz Z, Elmagarmid A. Rayyan—a web and mobile APP for systematic reviews. *Syst Rev* 2016; **5**: 210. doi: <https://doi.org/10.1186/s13643-016-0384-4>
27. Whiting PF, Rutjes AWS, Westwood ME, Mallett S, Deeks JJ, Reitsma JB, et al. QUADAS-2: a revised tool for the quality assessment of diagnostic accuracy studies. *Ann Intern Med* 2011; **155**: 529–36. doi: <https://doi.org/10.7326/0003-4819-155-8-201110180-00009>
28. Terumitsu M, Seo K, Matsuzawa H, Yamazaki M, Kwee IL, Nakada T. Morphologic evaluation of the inferior alveolar nerve in patients with sensory disorders by high-resolution 3D volume rendering magnetic resonance neurography on a 3.0-T system. *Oral Surgery, Oral Medicine, Oral Pathology, Oral Radiology, and Endodontology* 2011; **111**: 95–102. doi: <https://doi.org/10.1016/j.tripleo.2010.09.002>
29. Terumitsu M, Matsuzawa H, Seo K, Watanabe M, Kurata S, Suda A, et al. High-Contrast high-resolution imaging of post-traumatic mandibular nerve by 3DAC-PROPELLER magnetic resonance imaging: correlation with the severity of sensory disturbance. *Oral Surg Oral Med Oral Pathol Oral Radiol* 2017; **124**: 85–94. doi: <https://doi.org/10.1016/j.oooo.2017.02.017>
30. Kress B, Gottschalk A, Anders L, Stippich C, Palm F, Bähren W, et al. High-Resolution dental magnetic resonance imaging of inferior alveolar nerve responses to the extraction of third molars. *Eur Radiol* 2004; **14**: 1416–20. doi: <https://doi.org/10.1007/s00330-004-2285-5>
31. Zuniga JR, Mistry C, Tikhonov I, Dessouky R, Chhabra A. Magnetic resonance neurography of traumatic and nontraumatic peripheral trigeminal neuropathies. *J Oral Maxillofac Surg* 2018; **76**: 725–36. doi: <https://doi.org/10.1016/j.joms.2017.11.007>
32. Cox B, Zuniga JR, Panchal N, Cheng J, Chhabra A. Magnetic resonance neurography in the management of peripheral trigeminal neuropathy: experience in a tertiary care centre. *Eur Radiol* 2016; **26**: 3392–400. doi: <https://doi.org/10.1007/s00330-015-4182-5>
33. Dessouky R, Xi Y, Zuniga J, Chhabra A. Role of Mr neurography for the diagnosis of peripheral trigeminal nerve injuries in patients with prior molar tooth extraction. *AJNR Am J Neuroradiol* 2018; **39**: 162–9. doi: <https://doi.org/10.3174/ajnr.A5438>
34. Kress B, Gottschalk A, Stippich C, Palm F, Bähren W, Sartor K. Mr imaging of traumatic lesions of the inferior alveolar nerve in patients with fractures of the mandible. *AJNR Am J Neuroradiol* 2003; **24**: 1635–8.
35. Cassetta M, Pranno N, Barchetti F, Sorrentino V, Lo Mele L, et al. 3.0 Tesla MRI in the early evaluation of inferior alveolar nerve neurological complications after mandibular third molar extraction: a prospective study. *Dentomaxillofac Radiol* 2014; **43**: 20140152. doi: <https://doi.org/10.1259/dmfr.20140152>
36. Cohen JF, Korevaar DA, Altman DG, Bruns DE, Gatsonis CA, Hooft L, et al. Stard 2015 guidelines for reporting diagnostic accuracy studies: explanation and elaboration. *BMJ Open* 2016; **6**: e012799–17. doi: <https://doi.org/10.1136/bmjopen-2016-012799>
37. Del Grande F, Santini F, Herzka DA, Aro MR, Dean CW, Gold GE, et al. Fat-suppression techniques for 3-T MR imaging of the musculoskeletal system. *Radiographics* 2014; **34**: 217–33. doi: <https://doi.org/10.1148/rg.341135130>
38. Homsí R, Gieseke J, Luetkens J, Kupczyk P, Maedler B, Kukuk G, et al. Three-Dimensional isotropic Fat-Suppressed proton Density-Weighted MRI at 3 tesla using a T/R-Coil can replace multiple plane two-dimensional sequences in knee imaging. *Fortschr Röntgenstr* 2016; **188**: 949–56. doi: <https://doi.org/10.1055/s-0042-111826>
39. von Arx T, Lozanoff S. Clinical oral anatomy. *Switzerland: Springer International Publishing* 2017;561 p.
40. Dietrich O, Raya JG, Reeder SB, Reiser MF, Schoenberg SO. Measurement of signal-to-noise ratios in Mr images: influence of multichannel coils, parallel imaging, and reconstruction filters. *J Magn Reson Imaging* 2007; **26**: 375–85. doi: <https://doi.org/10.1002/jmri.20969>
41. Bergeest JP, Jäger F. A comparison of five methods for signal intensity standardization in MRI. *Inform aktuell* 2008;: 36–40.
42. Sollmann N, Weidlich D, Klupp E, Cervantes B, Ganter C, Zimmer C, et al. T2 mapping of the distal sciatic nerve in healthy subjects and patients suffering from lumbar disc herniation with nerve compression. *Magn Reson Mater Phys Biol Med* 2020;(0123456789).