



University of Kentucky  
UKnowledge

---

Surgery Faculty Publications

Surgery

---

10-2020

## From Leads to Leadless: A Convoluted Journey

Vipin Dulam  
*Temple University*

Joshua M. Cooper  
*Temple University*

Chethan Gangireddy  
*Temple University*

Mohammed A. Kashem  
*Temple University*

Yoshiya Toyoda  
*Temple University*

*See next page for additional authors*

Follow this and additional works at: [https://uknowledge.uky.edu/surgery\\_facpub](https://uknowledge.uky.edu/surgery_facpub)



Part of the [Cardiology Commons](#), and the [Surgery Commons](#)

**Right click to open a feedback form in a new tab to let us know how this document benefits you.**

---

### Repository Citation

Dulam, Vipin; Cooper, Joshua M.; Gangireddy, Chethan; Kashem, Mohammed A.; Toyoda, Yoshiya; and Keshavamurthy, Suresh, "From Leads to Leadless: A Convoluted Journey" (2020). *Surgery Faculty Publications*. 43.

[https://uknowledge.uky.edu/surgery\\_facpub/43](https://uknowledge.uky.edu/surgery_facpub/43)

This Article is brought to you for free and open access by the Surgery at UKnowledge. It has been accepted for inclusion in Surgery Faculty Publications by an authorized administrator of UKnowledge. For more information, please contact [UKnowledge@lsv.uky.edu](mailto:UKnowledge@lsv.uky.edu).

---

## From Leads to Leadless: A Convoluted Journey

Digital Object Identifier (DOI)

<https://doi.org/10.1016/j.hrcr.2020.07.010>

### Notes/Citation Information

Published in *HeartRhythm Case Reports*, v. 6, issue 10.

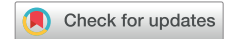© 2020 Heart Rhythm Society

This is an open access article under the CC BY-NC-ND license (<https://creativecommons.org/licenses/by-nc-nd/4.0/>).

### Authors

Vipin Dulam, Joshua M. Cooper, Chethan Gangireddy, Mohammed A. Kashem, Yoshiya Toyoda, and Suresh Keshavamurthy

# From leads to leadless: A convoluted journey



Vipin Dulam, BS,\* Joshua M. Cooper, MD, FACC, FHRS,<sup>†</sup> Chethan Gangireddy, MD, MPH,<sup>†</sup> Mohammed A. Kashem, MD, PhD,<sup>‡</sup> Yoshiya Toyoda, MD, PhD,<sup>‡</sup> Suresh Keshavamurthy, MD, FACS, FRCS<sup>‡§</sup>

From the \*Lewis Katz School of Medicine at Temple University, Philadelphia, Pennsylvania, <sup>†</sup>Department of Medicine, Division of Cardiology – Cardiac Electrophysiology, Temple University Hospital, Philadelphia, Pennsylvania, <sup>‡</sup>Department of Surgery, Division of Cardiovascular Surgery, Temple University Hospital, Philadelphia, Pennsylvania, and <sup>§</sup>Department of Cardiothoracic Surgery, University of Kentucky Hospital, Lexington, Kentucky.

## Introduction

Pacemaker infections are one of the most distressing and morbid complications for patients and can present a challenging management problem for physicians. Pacemaker leads, especially those that dwell in the venous system and inside the cardiac chambers, are prone to becoming colonized with bacteria owing to their sizeable surface area, the nature of their external exposed materials (usually silicone or polyurethane) that are prone to biofilm formation, and their close association with the skin surface at the level of the pacemaker pocket.<sup>1</sup> Leads that cross the tricuspid valve (TV) may be at additional risk for lead-associated endocarditis owing to contact with infected valvular structures, and the local environment of turbulent, high-velocity jets.

Leadless pacemakers, on the other hand, have features that may reduce their risk of becoming infected, including a smaller surface area, a metal-only exposed surface, no interaction with the TV, and no component that has proximity to the skin surface. Micra (Medtronic, Minneapolis, MN) is a battery-operated leadless intracardiac pacemaker that was designed to stay anchored inside the right ventricle, thus reducing the infection risk of conventional pacemakers. The cylindrical device is 26 mm long, about the size of a large pill (a volume of 1 cm<sup>3</sup>), occupying clinically insignificant space within the right ventricular chamber. The Micra leadless pacemaker is placed with a transvenous implantation catheter via the right femoral vein, so no thoracotomy is required for this procedure.<sup>2</sup>

**KEYWORDS** Endocarditis; Leadless pacemaker; MICRA; Pacemaker infection; Tricuspid valvectomy  
(Heart Rhythm Case Reports 2020;6:757–760)

**Funding:** The authors have no funding sources to disclose. **Conflict of Interest:** Joshua Cooper discloses consulting fees from Medtronic Inc, Boston Scientific, and Abbott Laboratories. There are no other conflicts of interests from any other author. **Address reprint requests and correspondence:** Dr Suresh Keshavamurthy, University of Kentucky Hospital -Department of Cardiothoracic Surgery, 800 Rose St, Lexington, KY 40536. E-mail address: [suresh.keshavamurthy@uky.edu](mailto:suresh.keshavamurthy@uky.edu).

We present a case where a Micra leadless pacemaker was used to manage a challenging patient with a history of TV endocarditis, complete heart block, and multiple pacemaker system infections.

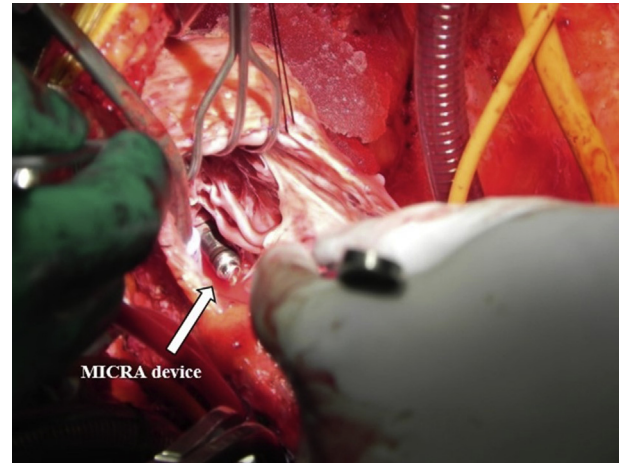
## Case report

Our patient is a 48-year-old man who presented to our institution with a complaint of shortness of breath. His past medical history is significant for hepatitis C infection, intravenous (IV) drug-related endocarditis, and a tricuspid valvectomy in 1996. At the time of valve surgery, he developed complete heart block, became completely pacemaker dependent, and had an epicardial pacemaker system implanted with an upper abdominal pacemaker pocket. In June 2013, owing to epicardial lead malfunction, he had a left pectoral transvenous pacemaker system implanted, and the epicardial leads were abandoned. In June 2016, in the context of recurrent IV drug use after an 11-year period of abstinence, he presented with back pain and fever, and was diagnosed with lead-associated endocarditis (methicillin-sensitive *Staphylococcus aureus*) and spinal L5-S1 osteomyelitis. He underwent left pectoral pacemaker system extraction and implantation of a temporary pacemaker system, and was started on an aggressive prolonged course of IV antibiotics. The patient had a new permanent right pectoral transvenous pacemaker system implanted after a week of negative blood cultures.

Three months after the contralateral pacemaker implantation, in October 2016, the patient presented with fever, chills, and pacemaker pocket pain and erythema. He was diagnosed with a right pectoral pocket infection (methicillin-resistant *S. aureus*), again necessitating pacemaker system removal and use of another temporary pacing system via the right internal jugular vein. The patient had 2 epicardial ventricular leads (Medtronic epicardial screw-in, unipolar, model 5071) surgically implanted via a left minithoracotomy and connected to a permanent pacemaker in the left upper quadrant of the abdomen, because both subclavicular pocket locations had housed infected pacemaker systems within the preceding

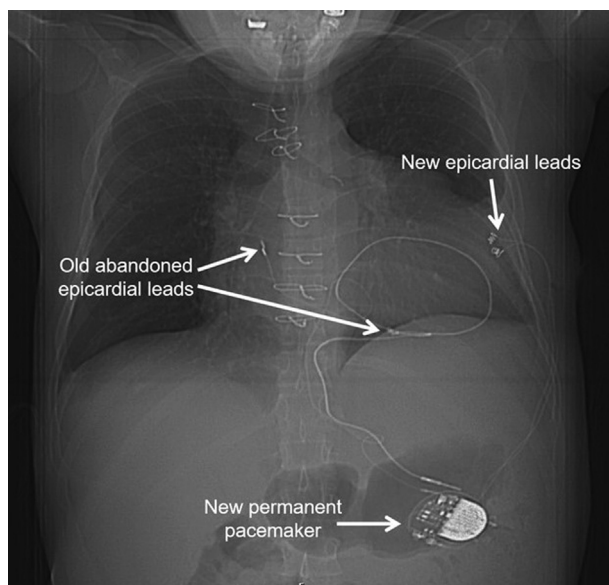
## KEY TEACHING POINTS

- Standard pacemaker leads are prone to bacterial adherence and chronic colonization in the setting of bacteremia and endocarditis. Full extraction of the pacing system is needed as part of curative treatment when lead-associated endocarditis is present.
- Multiple episodes of endocarditis over time can mandate sequential removal of transvenous hardware (including pacemaker leads) in order to achieve definitive control of these infections. The need for multiple lead extractions does not preclude the possibility of long-term cure from relapsing endocarditis.
- The Micra (Medtronic, Minneapolis, MN) leadless pacemaker has a lower risk of bacterial colonization than standard transvenous pacemaker leads for several reasons, and may be an appropriate choice for chronic pacing in patients at high risk for bacterial endocarditis.



**Figure 2** Intraoperative photograph of the indwelling Micra (Medtronic, Minneapolis, MN) leadless pacemaker in the right ventricle, as viewed through the right atriotomy. The leadless pacemaker had not yet been fully encapsulated by fibrous tissue, having only been in place for under 4 months at the time of tricuspid valve surgery.

few months, and also owing to the higher risk for infection of leads in the bloodstream (Figure 1). During the surgical epicardial lead placement, an intraoperative transesophageal echocardiogram (TEE) revealed severe tricuspid insufficiency owing to his tricuspid valvectomy. He also had a severely dilated right ventricle and right atrium and was therefore advised to undergo TV replacement. The valvular replacement surgery was planned after he recovered from his minithoracotomy.



**Figure 1** Intraoperative radiograph of epicardial lead placement with a generator placed in the hypochondrium.

However, 3 months after epicardial pacemaker system implantation, in January 2017, the patient presented again to the emergency room, complaining of fever, chills, severe joint pain, and purulent drainage coming from the lateral thoracotomy wound (methicillin-resistant *S. aureus*). A full-body computed tomography (CT) scan revealed infection of his epicardial leads, along with a right psoas muscle abscess (4.2 × 3.5 × 8.9 cm). The scan also demonstrated the 2 old epicardial abandoned leads as well as the 2 newer epicardial leads. After consultation with both electrophysiology and cardiothoracic surgery, it was felt that implanting yet another conventional pacemaker would pose a high risk of infection, especially with active abscess collections present that could cause intermittent seeding of the bloodstream. The psoas muscle abscess was inaccessible for CT-guided drainage, and the patient was put on IV vancomycin and then a long course of oral doxycycline.

When a repeat CT scan revealed resolution of the psoas abscess several months later, a Micra leadless pacemaker was implanted into the right ventricle in July 2017. The delivery sheath was introduced to the right femoral vein, advanced up the inferior vena cava to the right atrium, and deflected to allow advancement into the right ventricle. The Micra leadless pacemaker was deployed into the apical portion of the right ventricular septum, with good fixation of the anchoring tines. The retention suture was cut and removed, thereby releasing the leadless pacemaker from the delivery sheath assembly, which was then retracted down to the inferior vena cava. Reliable pacing was demonstrated from the leadless pacemaker, and the epicardial pacemaker system was programmed to a lower pacing rate to serve as a temporary backup device while it remained in place.

In November 2017, 4 months after implantation of the Micra leadless pacemaker, and with ongoing negative blood

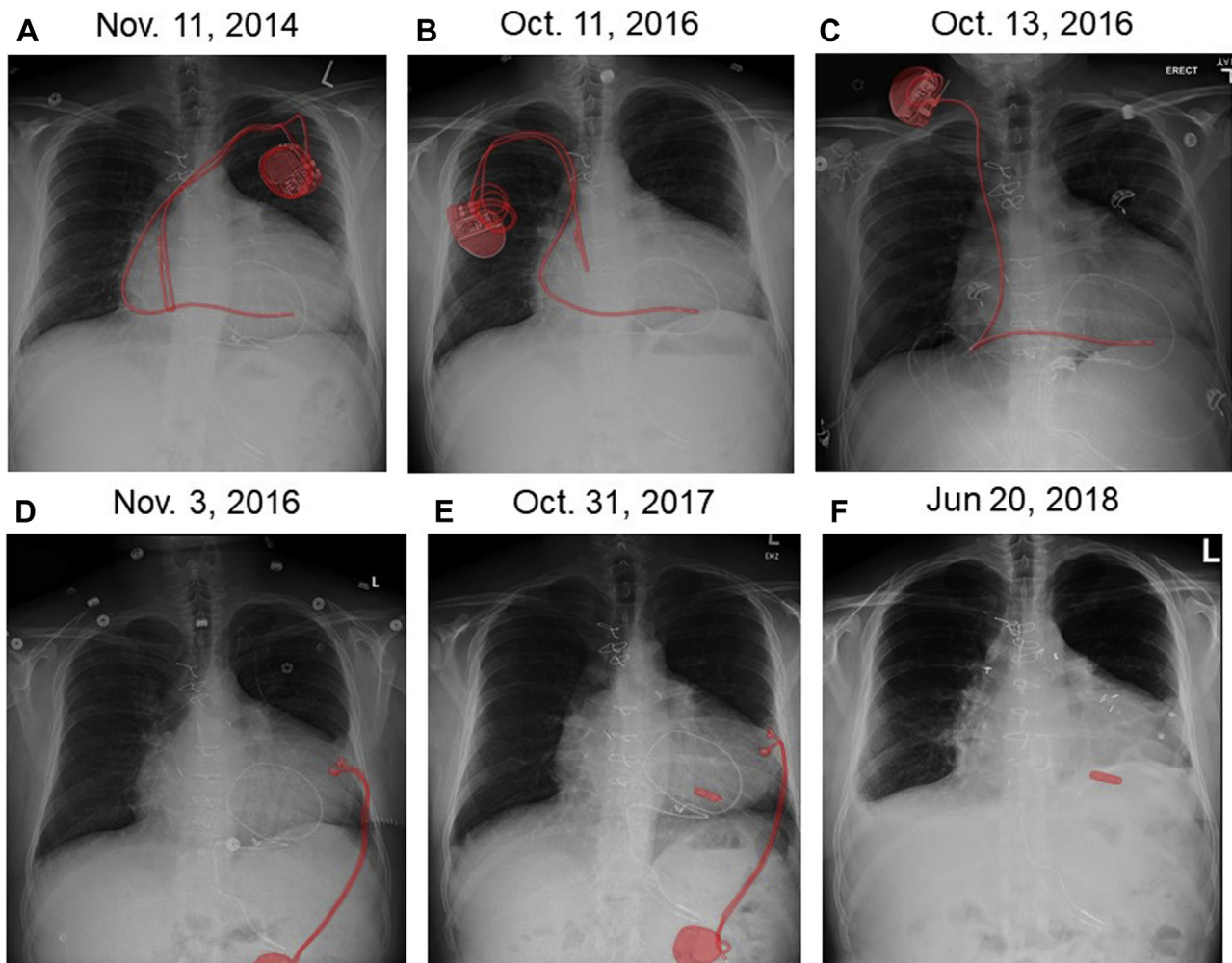
cultures on oral antibiotics, the patient underwent a redo sternotomy. He had a TV replacement with a 33 mm St. Jude Biocor bioprosthetic valve (St. Jude Medical SJM BIOCOR® Valve), full removal of the infected epicardial pacing system implanted in October 2016, and subtotal removal of the epicardial portion of the 1996-abandoned epicardial leads. During the TV replacement portion of the surgery, we were able to visualize the Micra leadless pacemaker deep in the right ventricle (Figure 2). An intraoperative TEE done following valve implantation revealed the new valve was well functioning and seated appropriately.

The patient had 1 more bout of bacteremia with methicillin-resistant *S. aureus* in June 2018, and a TEE was performed to confirm that there were no vegetations on the Micra device. The patient was treated successfully with 6 weeks of IV daptomycin. He has been free of infection for the past 2 years, with the leadless pacemaker remaining in place. He is doing well clinically and is actively enrolled in a drug rehabilitation program.

## Discussion

Pacemaker lead infection is a major cause of morbidity and mortality and is particularly problematic in pacemaker-dependent patients. Sohail and colleagues<sup>3</sup> found that there was a significant increase in mortality following infection of cardiovascular implantable electronic devices. Another group, Johansen and colleagues,<sup>4</sup> showed, in their retrospective study, that the risk of infection after 2 years of cardiac pacemaker implant could be up to 9.5%. Of note was Kirkfeldt and colleagues'<sup>5</sup> retrospective study showing that the risk of infection in the case of device replacement and revision is between 2- and 4-fold higher than the risk after initial implantation.

Amidst these published studies and discussions, the question arises as to what needs to be done to avoid recurrent device infections. Adding to this concern are the patients at disproportionately higher risk of bloodstream infections, such as active IV drug users who are still in the process of seeking treatment for their addiction.



**Figure 3** Serial chest radiographs demonstrating some of the active pacemaker systems used in this patient over the years, with the active pacemaker generator(s) highlighted in red. **A:** Left pectoral transvenous dual-chamber pacemaker. **B:** Right pectoral transvenous dual-chamber pacemaker. **C:** Temporary single-chamber ventricular externalized pacemaker via the right internal jugular vein. **D:** Epicardial single-chamber pacemaker. **E:** Leadless pacemaker (primary functioning pacemaker) and epicardial single-chamber pacemaker (set for backup pacing). **F:** Leadless pacemaker after epicardial pacing system was explanted. Note that the original abdominal pacemaker system and the temporary externalized pacing system that was in place between panels A and B are not pictured.

In the case of our patient, his history of IV drug use and severe valvular endocarditis many years ago had warranted a tricuspid valvectomy. The TV is known to be a nidus for infection in IV drug use patients.<sup>6</sup> IV antibiotics are the first line of treatment for TV infections, and typically can be curative without the need for surgical intervention. Recurrent bloodstream infection, persistent valvular vegetations, and valve leaflet destruction usually warrant a more aggressive surgical approach. One of these surgical approaches (especially in known IV drug users) is a tricuspid valvectomy, which was first performed by Arbulu and colleagues<sup>7</sup> in the early 1980s. Arbulu and colleagues had found in their practice that the actuarial survival in 53 patients 22 years post valvectomy was 64%. Surprisingly, the severe tricuspid regurgitation was well tolerated in most patients but did cause low cardiac output syndrome in about one-third of those patients owing to right ventricular dilation and systolic dysfunction.<sup>7</sup>

As seen in this case, our patient was able to survive almost 20 years with few cardiac complications post tricuspid valvectomy. Eventually, however, the severe tricuspid regurgitation did call for a TV replacement. His clinical course became much more complex when transvenous pacemaker leads were implanted, serving as a nidus for bloodstream infection perpetuation. He had done well for 17 years with an epicardial pacemaker system in place, but during the 4 years after a transvenous pectoral pacemaker was implanted, he underwent 7 pacing system–related procedures and was sequentially paced by 6 different temporary and permanent pacing systems (Figure 3).

We were finally able to circumvent the problem of recurrent device system infections by selecting a technology that eliminated the dominant predisposing factor for infection—the pacemaker leads that provided a robust surface for bacterial adhesion and biofilm formation, and that served as a physical link between the heart and the subcutaneous space. The Micra leadless pacemaker has several advantages over traditional pacemaker systems that may reduce the risk for device-related infection. With a leadless pacemaker, there is no subcutaneous pocket; there is minimal handling of the device during implantation; the exposed surface is only parylene-coated titanium, in contrast to standard pacemakers that include the silicone or polyurethane outer insulation of the leads; the surface area of a leadless pacemaker exposed to the bloodstream is  $\sim 620 \text{ mm}^2$ , in contrast to  $\sim 3500 \text{ mm}^2$  of exposed intravascular lead surface with a single-chamber pacemaker (a dual-chamber pacemaker would have approximately double that surface area in the bloodstream); and the Micra leadless pacemaker undergoes extensive or complete fibrous encapsulation, which protects it from direct bloodstream exposure.<sup>8,9</sup> In addition, transvenous pacemaker leads traverse the TV, which can interfere with valve function and also interact with the tissue that most often becomes infected during right-sided endocarditis. In contrast, the leadless pacemaker sits in the apical

portion of the right ventricle and does not interact with the TV.

The Micra leadless pacemaker has been shown to have 63% less major complications than the transvenous pacemaker systems in a study conducted by El-Chami and associates.<sup>10</sup> The same group also showed that in a study of 720 patients who had the Micra pacemaker implanted, only 21 developed serious infectious events; but none of them had vegetation on the Micra pacemaker, and they were successfully managed with antibiotics and device removal was not necessary.

Leadless pacemakers might therefore be particularly useful in patients with high risk of infection, including IV drug users. The latest model of leadless pacemaker to be approved by the US Food and Drug Administration can function in the VDD mode, thereby tracking atrial activity and maintaining atrioventricular synchrony.<sup>11</sup> Future innovations will no doubt include a leadless pacing platform that can perform biventricular pacing as well. This case demonstrates how leadless pacemaker technology can be leveraged to reduce infectious complications in a high-risk patient. This patient was able to move forward with his life and seek long-term help to overcome drug addiction with the cycle of infection being broken.

## Acknowledgements

Publication of this article was funded by the Temple University Libraries Open Access Publishing Fund.

## References

- Kołodzińska A, Kutarski A, Kozłowska M, et al. Biodegradation of the outer silicone insulation of endocardial leads. *Circ Arrhythm Electrophysiol* 2013; 6:279–286.
- Bhatia N, El-Chami M. Leadless pacemakers: a contemporary review. *J Geriatr Cardiol* 2018;15:249–253.
- Sohail MR, Henrikson CA, Braid-Forbes MJ, Forbes KF, Lerner DJ. Mortality and cost associated with cardiovascular implantable electronic device infections. *Arch Intern Med* 2011;171:1821–1828.
- Johansen JB, Jørgensen OD, Møller M, Arnsbo P, Mortensen PT, Nielsen JC. Infection after pacemaker implantation: infection rates and risk factors associated with infection in a population-based cohort study of 46299 consecutive patients. *Eur Heart J* 2011;32:991–998.
- Kirkfeldt RE, Johansen JB, Nohr EA, Jørgensen OD, Nielsen JC. Complications after cardiac implantable electronic device implantations: an analysis of a complete, nationwide cohort in Denmark. *Eur Heart J* 2014;35:1186–1194.
- Akinosoglou K, Apostolakis E, Koutsogiannis N, Leivaditis V, Gogos CA. Right-sided infective endocarditis: surgical management. *Eur J Cardiothorac Surg* 2012;42:470–479.
- Arbulu A, Holmes RJ, Asfaw I. Tricuspid valvectomy without replacement. Twenty years' experience. *J Thorac Cardiovasc Surg* 1991;102:917–922.
- Reynolds DW, Ritter P. A leadless intracardiac transcatheter pacing system. *N Engl J Med* 2016;374:2604–2605.
- El-Chami MF, Mayotte J, Bonner M, Holbrook R, Stromberg K, Sohail MR. Reduced bacterial adhesion with parylene coating: Potential implications for Micra transcatheter pacemakers. *J Cardiovasc Electrophysiol* 2020;31:712–717.
- El-Chami MF, Al-Samadi F, Clementy N, et al. Updated performance of the Micra transcatheter pacemaker in the real-world setting: A comparison to the investigational study and a transvenous historical control. *Heart Rhythm* 2018; 15:1800–1807.
- Steinwender C, Khelae SK, Garweg C, et al. Atrioventricular synchronous pacing using a leadless ventricular pacemaker: Results from the MARVEL 2 Study. *JACC Clin Electrophysiol* 2020;6:94–106.