



Submillisievert chest CT in patients with COVID-19 - experiences of a German Level-I center

Christina M. Hamper^{a,*}, Florian Nima Fleckenstein^{a,b}, Laura Büttner^a, Bernd Hamm^a, Nadine Thieme^a, Hans-Martin Thiess^a, Oriane Scholz^a, Felix Döllinger^a, Georg Böning^a

^a Charité – Universitätsmedizin Berlin, corporate member of Freie Universität Berlin, Humboldt-Universität zu Berlin, and Berlin Institute of Health, Germany

^b Berlin Institute of Health (BIH), Anna-Louisa-Karsch 2, 10178 Berlin, Germany

ARTICLE INFO

Keywords:

COVID-19
Low-dose chest CT
Dose reduction
SARS-CoV2
German Level-I center
Coronavirus

ABSTRACT

Purpose: Computed tomography (CT) is used for initial diagnosis and therapy monitoring of patients with coronavirus disease 2019 (COVID-19). As patients of all ages are affected, radiation dose is a concern. While follow-up CT examinations lead to high cumulative radiation doses, the ALARA principle states that the applied dose should be as low as possible while maintaining adequate image quality. The aim of this study was to evaluate parameter settings for two commonly used CT scanners to ensure sufficient image quality/diagnostic confidence at a submillisievert dose.

Materials and methods: We retrospectively analyzed 36 proven COVID-19 cases examined on two different scanners. Image quality was evaluated objectively as signal-to-noise ratio (SNR)/contrast-to-noise ratio (CNR) measurement and subjectively by two experienced, independent readers using 3-point Likert scales. CT dose index volume (CTDIvol) and dose-length product (DLP) were extracted from dose reports, and effective dose was calculated.

Results: With the tested parameter settings we achieved effective doses below 1 mSv (median 0.5 mSv, IQR: 0.2 mSv, range: 0.3–0.9 mSv) in all 36 patients. Thirty-four patients had typical COVID-19 findings. Both readers were confident regarding the typical COVID-19 CT-characteristics in all cases (3 ± 0). Objective image quality parameters were: SNR_{normal lung}: 17.0 ± 5.9 , CNR_{GGO/normal lung}: 7.5 ± 5.0 , and CNR_{consolidation/normal lung}: 15.3 ± 6.1 .

Conclusion: With the tested parameters, we achieved applied doses in the submillisievert range, on two different CT scanners without sacrificing diagnostic confidence regarding COVID-19 findings.

1. Introduction

The new coronavirus (SARS-CoV-2) and the disease it causes (COVID-19) were first reported in the city of Wuhan, China, in December 2019 [1,2]. In most cases, SARS-CoV-2 manifests with only mild symptoms, but some patients develop a severe disease, which can lead to acute respiratory distress syndrome (ARDS), multiple organ failure, and death [3,4].

There are specific pulmonary findings associated with COVID-19 in chest computed tomography (CT), including bilateral ground-glass opacities (GGO) with peripheral distribution, consolidations, and the “crazy-paving” pattern or “reverse halo” sign [5–13]. In the course of the disease, CT can show these typical changes, even if no virus is detected in the nasopharyngeal or throat swab [14,15]. Reverse transcription

polymerase chain reaction (RT-PCR) testing is limited by a longer waiting time for results. Therefore, CT imaging can speed up diagnosis of COVID-19 and provide valuable findings in the further course of disease [16]. Kang et al. even recommended low-dose CTs for initial diagnosis and to monitor the course of COVID-19 [14]. They underline that a CT can be very helpful early at the onset of symptoms or when the swab test is negative [14,15]. Esposito et al. also conclude that chest CT is a good and fast imaging modality for first-line triage of patients with suspected COVID-19 [17]. Radpour et al. focus on the advantages of low-dose CT especially in regions with many patients and limited availability of RT-PCR tests [18]. Nevertheless, the results should be interpreted with caution, as they depend on the disease status, testing method, and imaging technique (e.g., applied dose).

As all age groups are affected by COVID-19 according to a multi-

* Corresponding author at: Charité – Universitätsmedizin Berlin, Campus Virchow-Klinikum, Augustenburger Platz 1, 13353 Berlin, Germany.

E-mail address: christina-maria.hamper@charite.de (C.M. Hamper).

<https://doi.org/10.1016/j.ejro.2020.100283>

Received 6 October 2020; Received in revised form 20 October 2020; Accepted 25 October 2020

Available online 3 November 2020

2352-0477/© 2020 The Author(s).

Published by Elsevier Ltd.

This is an open access article under the CC BY-NC-ND license

(<http://creativecommons.org/licenses/by-nc-nd/4.0/>).

center study of Yang et al., which was also summarized in an article of Yi et al. [19], the potential risks arising from the radiation dose associated with CT need to be addressed [14] as findings like GGO are sometimes not visible in chest radiographs [20]. Nevertheless, the diagnostic confidence of chest CT must be guaranteed regarding typical pulmonary findings associated with COVID-19.

The aim of this study was therefore, based on experiences of a German center, to evaluate parameter settings for two commonly used CT scanners that potentially ensure sufficient image quality/diagnostic confidence regarding COVID-19 findings at submillisievert dose levels.

2. Materials and methods

2.1. Study design/patient cohort

This retrospective study was approved by the Local Ethics Committee of our hospital (EA4/074/20). Based on published data and our experience, we selected acquisition parameters for low-dose chest scans in patients with suspected COVID-19 (see Table 1) examined on two scanners from different vendors. We retrospectively included 36 patients from two sites ($n = 17/19$) of our German Level-I university center, who were treated between March 30 and April 22, 2020. All patients included were positive for SARS-CoV-2 (RT-PCR of nasopharyngeal and oropharyngeal swab samples; patients with a negative RT-PCR test result were excluded (Fig. 1)). Maximum axial and sagittal body diameters of patients' chest CTs were measured to assess body size.

2.2. Technical CT parameters

We established chest CT examinations with new low-dose protocols immediately when the first cases of COVID-19 appeared. Parameters for the protocols were selected on the basis of published data and our center's experience with clinical CT protocols (Table 1) [14,21–24]. At each site of our center, all patients who were positive for SARS-CoV-2 or highly suspected of having COVID-19 were examined on a CT scanner equipped with these low-dose-protocols (Table 1).

2.3. Subjective image quality

Two experienced radiologists with 5 and 10 years of expertise in the evaluation of chest CTs independently read the scans and scored image quality/diagnostic confidence regarding the presence of typical pulmonary COVID-19 CT findings (peripheral GGO, consolidations, etc.) on a 3-point Likert scale (1-no diagnosis possible, 2-limited diagnostic confidence, 3-full diagnostic confidence).

Table 1

Detailed technical parameters of the two CT scanners investigated: The parameters were chosen on the basis of published experience and experience at our center.

	GE Light-Speed VCT	Canon Aquilion Prime
Voltage	100 kVp	100 kVp
Tube current	20–120 mA	10–120 mA
Noise parameter	NI: 40	SD: 27
Rotation time	0.4 s	0.35 s
Pitch	1.375	1.388
Recon IR level	ASIR 50	AIDR 3D standard
Collimation	64 × 0.625 mm	80 × 0.5 mm
ATCM	on	on
Recon mode	slice (axial)	volume 1/0.8
Recon section interval	0.625 mm	1 mm
Field of view	DFOV: depending on patient size SFOV: 50 cm	DFOV: depending on patient size SFOV: 50 cm

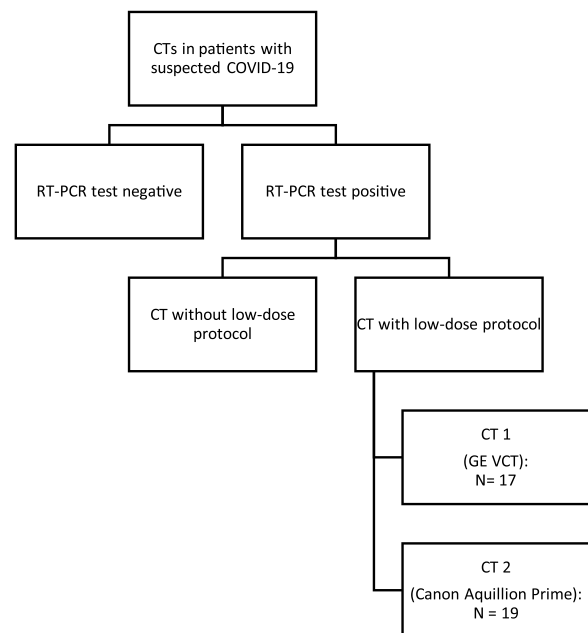


Fig. 1. Patient cohort.

We retrospectively enrolled 36 patients from two sites ($n = 17/19$) of our central European Level-I university center. All patients included were positive for SARS-CoV-2 (RT-PCR of nasopharyngeal and oropharyngeal swab samples); patients with a negative RT-PCR test result were excluded.

2.4. Objective image quality

For objective image quality analysis, two experienced readers in consensus manually placed circular regions of interest (ROIs) in normal lung, surrounding air, and, if present, GGO and consolidation while carefully avoiding interfering structures such as larger blood vessels or airways. Example positions of ROIs are shown in Fig. 2.

We calculated ROI-based signal-to-noise ratio (SNR) of normal lung and contrast-to-noise ratios (CNRs) of GGO to normal lung and consolidations to normal lung.

SNR was defined as:

$$SNR = \frac{|mean\ HU\ normal\ lung|}{SD\ HU\ surrounding\ air}$$

CNR_{GGO to lung} as:

$$CNR_{GGO\ to\ lung} = \frac{|mean\ HU\ normal\ lung - mean\ HU\ GGO|}{SD\ HU\ surrounding\ air}$$

CNR_{consolidation to lung} as:

$$CNR_{consolidation\ to\ lung} = \frac{|mean\ HU\ normal\ lung - mean\ HU\ consolidation|}{SD\ HU\ surrounding\ air}$$

Measurements were done in lung kernel reconstructions of 0.625 mm (GE Lightspeed VCT) or 1 mm (Canon Aquilion Prime) slice thickness, according to our clinical standards.

2.5. Applied dose

Effective dose (ED) was estimated with CT-Expo 2.5® software (Dr. rer. nat. Georg Stamm, Medizinische Hochschule Hannover, Hannover, Germany) based on the CTDI_{vol} and DLP extracted from the dose reports. It was in line with calculations by multiplying the dose-length-product (DLP) by 0.0144 mSv/mGy cm as the conversion factor for thoracic imaging according to ICRP (International Commission on Radiological Protection) 103 [25].

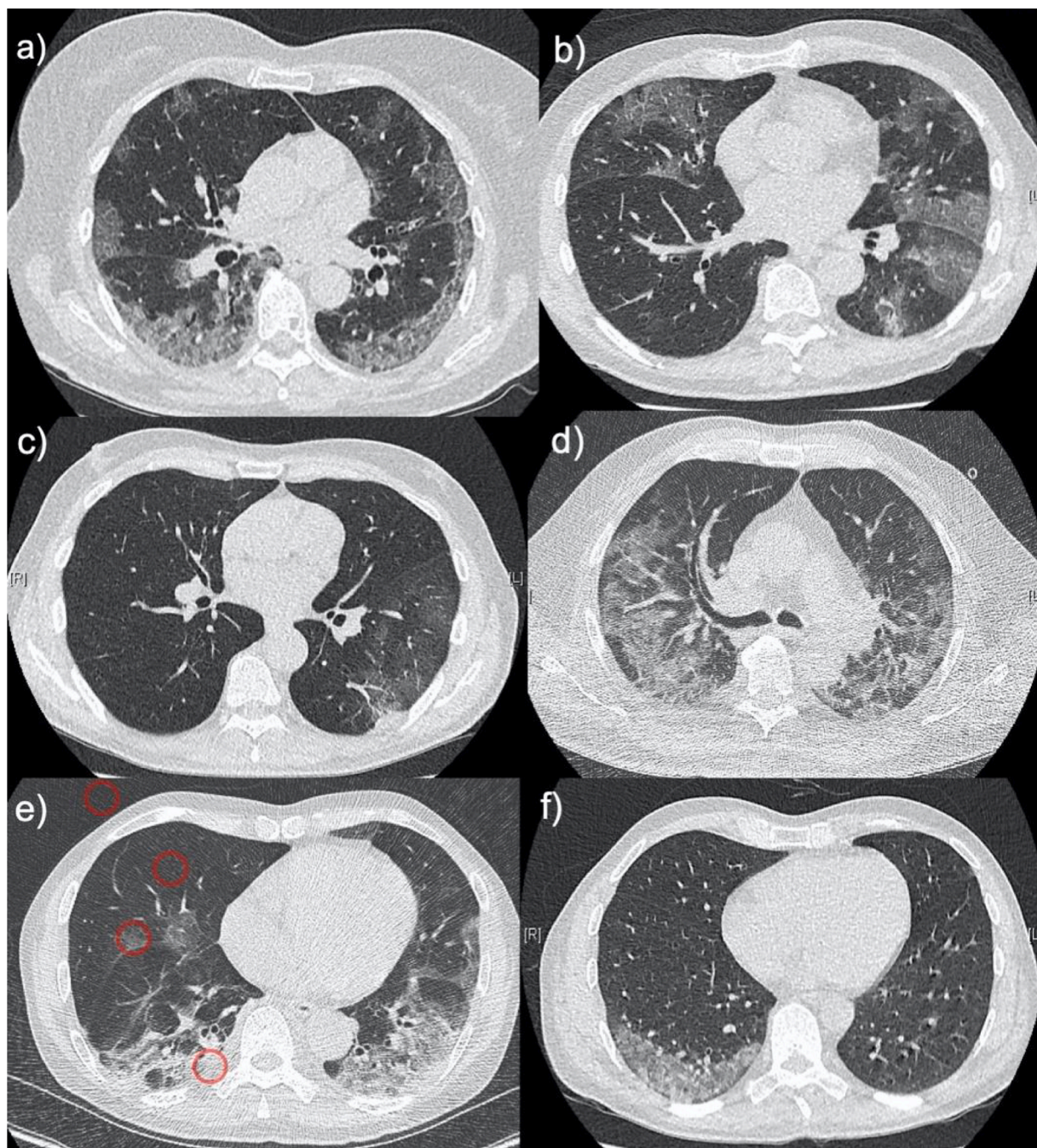


Fig. 2. Example cases of six patients with typical findings of COVID-19 in low-dose-chest CT.

a): 75-year-old woman with peripheral GGO, ED 0.5 mSv

b): 78-year-old man with peripheral GGO, ED 0.4 mSv

c): 71-year-old man with peripheral GGO, ED 0.4 mSv

d): 62-year-old man with mixed GGO and reticular pattern, ED 0.4 mSv

e): 67-year-old man with peripheral GGO and consolidations, ED 0.4 mSv

The red circles in E show the positions of ROIs for measurement of objective image quality

f): 51-year-old man with peripheral GGO, ED 0.4 mSv.

2.6. Statistical analysis

Calculations and graphs were created with GraphPad Prism v. 5 ® (GraphPad Software, San Diego, CA, USA). Based on parameter scale and the outcome of the Shapiro-Wilk test for normal distribution, results are given as mean and standard deviation (SD) or median and interquartile range (IQR).

3. Results

3.1. Patient cohort

The study population consisted of a total of 36 patients (men: $n = 27$ (75 %), women: $n = 9$ (25 %)) with a mean age of 59.2 ± 15.4 years (range: 24–90 years) (Fig. 3). Thirty-four of 36 patients (94 %) had findings typical for COVID-19 in CT imaging.

Maximum patient diameters were 24.7 ± 3.2 mm and 24.6 ± 3.3 mm (sagittal and axial orientation) (Fig. 3).

3.2. Subjective image quality

Thirty-four of 36 patients had typical findings of COVID-19 including peripheral GGO, consolidations, and/or crazy paving; however, all 36 CT studies were rated for diagnostic confidence. The two independent raters scored all scans as completely confident (3 ± 0).

3.3. Objective image quality

Calculated SNR/CNR values for the assessment of objective image quality were in line with expectations based on our earlier experience and are consistent with subjective scoring. For all cases taken together, we obtained the following ratios: $\text{SNR}_{\text{lung}}: 17.0 \pm 5.9$, $\text{CNR}_{\text{GGO to lung}}: 7.5 \pm 5.0$, and $\text{CNR}_{\text{consolidation to lung}}: 15.3 \pm 6.1$. For further details see Fig. 4.

3.4. Applied dose

CTDI_{vol} was 0.9 ± 0.3 mGy, retrospectively resulting in a DLP of 35 ± 10.2 mGy*cm and a median ED of 0.5 mSv (IQR: 0.2 mSv, range: 0.3–0.9 mSv) (Fig. 5). Mean ED was 0.5 ± 0.2 mSv (Fig. 5).

4. Discussion

As CT is frequently used in patients with COVID-19 the risks associated with radiation exposure should be taken into account, especially in younger patients [14]. Following the ALARA principle, a low-dose approach to CT scanning is necessary without sacrificing the diagnostic confidence. The aim of our study was therefore to identify CT parameter settings that fulfil these requirements.

The sex distribution of COVID-19 patients in our study - 75 % men and 25 % women - fits to results in literature [26]. In the study of Huang et al., 73 % of patients with COVID-19 were male, whereas in the study of Itelman et al., 65 % of the affected patients were male [4,27].

The mean age of our patients was 59.2 ± 15.4 years (range 24–90 years), which is consistent with the results of other studies such as that of Yang et al., who showed that COVID-19 affects all age groups. In their multicenter study on 8.866 patients, including 4.021 confirmed COVID-19 patients, nearly half of the patients (47.7 %) were older than 50 years, Yi et al. reported [19]. Itelman et al. found a mean age of 52 ± 20 years in 162 patients in Israel [27].

In our study, 94 % of the patients (34/36) with positive RT-PCR testing had typical pulmonary CT findings associated with COVID-19. Pan et al. analyzed typical findings in patients with COVID-19 over time from initial diagnosis to recovery. They concluded that pulmonary

manifestations were most severe 10 days after the first symptoms [28]. Of note, four patients did not have typical findings in their initial chest CT but later on [28]. Kanne et al. also show that up to around 50 % of patients with COVID-19 do not have abnormal CT scans in the first two days after onset of symptoms [29]. Thus, the two negative CT scans in our study may be attributable to an early stage of the disease.

In our study the readers consistently assigned the highest diagnostic confidence to all scans. Dangis et al. also investigated subjective evaluation of CT images and concluded, that submillisievert chest CT allows for assessment of COVID-19 in patients at the emergency room (ER) [21].

In our study, we additionally determined CNR and SNR for objective image quality assessment, and the results underline our subjective impression. SNR_{lung} was 17.0 ± 5.9 , $\text{CNR}_{\text{GGO to lung}}$ 7.5 ± 5.0 , and $\text{CNR}_{\text{consolidation to lung}}$ 15.3 ± 6.1 . Comparable to our results, Agostini et al. found a median SNR_{lung} of 12.2 (range 9.83–14.21) [22]. Kang et al. reported an SNR of 0.47 and CNR of 1.09 for their low-dose protocol but did not give details on calculation [14].

In each of our 36 patients, ED was lower than 1 mSv with a median of 0.5 mSv (IQR: 0.2mSv, range: 0.3–0.9 mSv) and a mean ED of 0.5 ± 0.2 mSv. Kang et al. compared two adult patients with COVID-19 of similar height, body size, and age examined in a Siemens scanner. One was examined with a low-dose CT protocol, the other with a standard-dose protocol. ED in the low-dose-protocol was 0.203 mSv whereas, in our study of 36 patients, the lowest ED was 0.3 mSv. Furthermore, Kang et al. only examined two patients and did not report details of patients' age, height, and body size [14]. Agostini et al. examined ten patients with COVID-19 using a standard-dose and a low-dose protocol. Median ED was 0.28 mSv (range 0.25–0.42 mSv) with their low-dose protocol at 100 kVp on a Siemens scanner [22]. Dangis et al. achieved a mean ED of 0.58 ± 0.25 mSv in chest CT examinations with a low-dose protocol of 83 patients with COVID-19, which is comparable to our results [21]. Our mean CTDI_{vol} was 0.9 ± 0.3 mGy, which is higher than that of 0.39 mGy reported by Kang et al. [14]. The median CTDI_{vol} in the study of Agostini et al. was also lower at 0.64 mGy (range 0.47–1.12 mGy) [22]. Dangis et al. had a higher mean CTDI_{vol} of 1.33 ± 0.55 mGy in a group of 83 patients with COVID-19 [21]. Our mean DLP was 35 ± 10.2 mGy*cm, which is again above that of Kang et al. [14], which was 14.5 mGy*cm, and the median DLP reported by Agostini et al. was also lower at 19.5 mGy*cm (17.5–29.02 mGy*cm) [22]. Our median DLP was lower than that of 41.4 ± 17.7 mGy*cm reported by Dangis et al. in a group of 83 patients with COVID-19 [21]. In sum, published results for ED, CTDI_{vol} and DLP are comparable to our results and thus appear to be robust for a mid-European patient collective. Differences may be due to variations in patient size or other technical parameter settings (e.g. iterative reconstruction level). Of course, if CT is not performed for COVID-19 diagnosis alone and there are additional questions to be answered (e.g.,

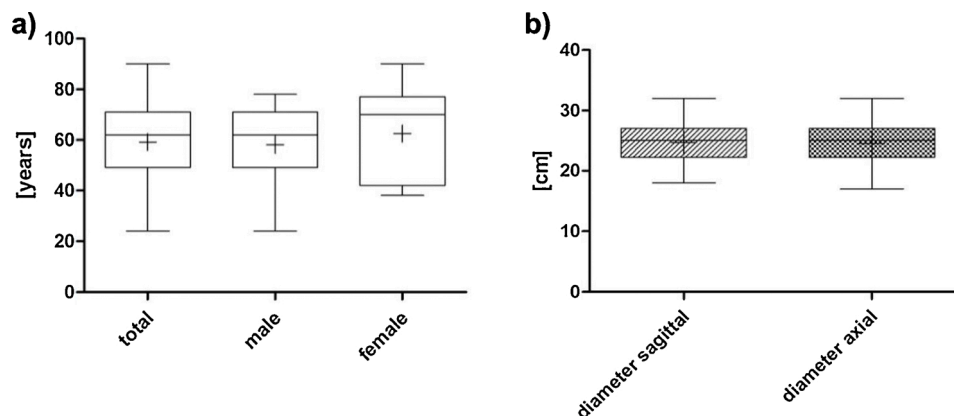


Fig. 3. a) Age and b) body diameter distribution in the patient population. Mean patient age was 59.2 years; mean diameters were 24.7 cm and 24.6 cm in a sagittal and axial orientation, respectively.

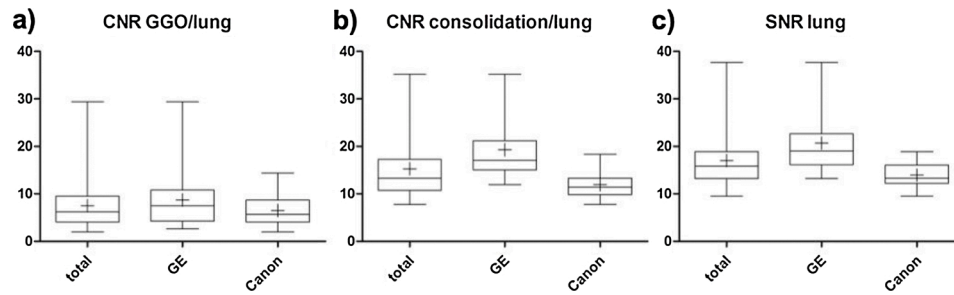


Fig. 4. a-c: CNRs for a) pulmonary GGO, b) consolidations and c) SNR for total lung. The mean SNR_{lung} was 17.0, the mean CNR_{GGO} to lung: 7.5 and the mean $CNR_{consolidation}$ to lung: 15.3

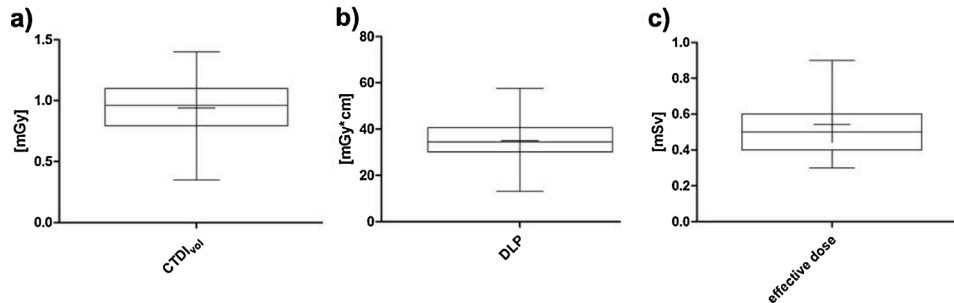


Fig. 5. a-c: Applied doses as a) CTDI, b) DLP and c) ED. Mean $CTDI_{vol}$ was 0.9 mGy, mean DLP 35 mGy*cm, and mean ED 0.5 mSv. $CTDI_{vol}$: volume computed tomography dose index, DLP: dose length product, ED: effective dose

pulmonary embolism), administration of contrast medium and use of higher dose settings could be necessary.

The main limitation of our study is the small sample size of 36 patients and the retrospective, single-center design. Furthermore, we only evaluated two CT scanners, and the readers were not blinded to technical parameters or the diagnosis. We only included patients > 18 years and did not compare low-dose with normal-dose chest CT. In addition, the results probably cannot be transferred to patients with larger body diameters and dedicated studies should be performed.

In conclusion, the presented parameter settings allow acquisition of chest CT scans with dose exposure in the submillisievert range on the two CT scanners used in our study without sacrificing diagnostic confidence regarding the presence of typical pulmonary changes associated with COVID-19.

Credit author statement

CMH and GB analyzed and interpreted the data and were responsible for the manuscript writing. GB was the major contributor to the conceptualization of the study. BH was the major contributor to the administration. GB, FD, NT and OS supported the project's administration. HMT, LB, FNF, OS, FD and NT supported the conceptualization of this study and the manuscript writing.

Ethical statement

This retrospective study was approved by the Local Ethics Committee of our hospital (EA4/074/20).

Funding

We acknowledge support from the German Research Foundation (DFG) and the Open Access Publication Funds of Charité – Universitätsmedizin Berlin.

Declaration of Competing Interest

The authors declare no conflict of interest.

References

- [1] H. Shi, X. Han, N. Jiang, Y. Cao, O. Alwalid, J. Gu, et al., Radiological findings from 81 patients with COVID-19 pneumonia in Wuhan, China: a descriptive study, *Lancet Infect. Dis.* 20 (4) (2020) 425–434.
- [2] N. Zhu, D. Zhang, W. Wang, X. Li, B. Yang, J. Song, et al., A novel coronavirus from patients with pneumonia in China, 2019, *N. Engl. J. Med.* 382 (8) (2020) 727–733.
- [3] N. Chen, M. Zhou, X. Dong, J. Qu, F. Gong, Y. Han, et al., Epidemiological and clinical characteristics of 99 cases of 2019 novel coronavirus pneumonia in Wuhan, China: a descriptive study, *Lancet.* 395 (10223) (2020) 507–513.
- [4] C. Huang, Y. Wang, X. Li, L. Ren, J. Zhao, Y. Hu, et al., Clinical features of patients infected with 2019 novel coronavirus in Wuhan, China, *Lancet* 395 (10223) (2020) 497–506.
- [5] A. Bernheim, X. Mei, M. Huang, Y. Yang, Z.A. Fayad, N. Zhang, et al., Chest CT findings in coronavirus Disease-19 (COVID-19): relationship to duration of infection, *Radiology.* (2020).
- [6] J. Wang, J. Liu, Y. Wang, W. Liu, X. Chen, C. Sun, et al., Dynamic changes of chest CT imaging in patients with corona virus disease-19 (COVID-19), *Zhejiang Da Xue Xue Bao Yi Xue Ban* (2020).
- [7] M. Chung, A. Bernheim, X. Mei, N. Zhang, M. Huang, X. Zeng, et al., CT imaging features of 2019 novel coronavirus (2019-nCoV), *Radiology* 295 (1) (2020) 202–207.
- [8] F. Song, N. Shi, F. Shan, Z. Zhang, J. Shen, H. Lu, et al., Emerging 2019 novel coronavirus (2019-nCoV) pneumonia, *Radiology* 295 (1) (2020) 210–217.
- [9] W.J. Guan, Z.Y. Ni, Y. Hu, W.H. Liang, C.Q. Ou, J.X. He, et al., Clinical characteristics of coronavirus disease 2019 in China, *N. Engl. J. Med.* 382 (18) (2020) 1708–1720.
- [10] A. Chen, J. Huang, Y. Liao, Z. Liu, D. Chen, C. Yang, et al., Differences in clinical and imaging presentation of pediatric patients with COVID-19 in comparison with adults, *Radiol.: Cardiothoracic Imaging* (2020).
- [11] M. El Homsy, M. Chung, A. Bernheim, A. Jacobi, M.J. King, S. Lewis, et al., Review of chest CT manifestations of COVID-19 infection, *Eur. J. Radiol. Open* 7 (2020), 100239.
- [12] A. Jajodia, L. Ebner, B. Heidinger, A. Chaturvedi, H. Prosch, Imaging in corona virus disease 2019 (COVID-19)-A scoping review, *Eur. J. Radiol. Open* 7 (2020), 100237.
- [13] P. Lomoro, F. Verde, F. Zerboni, I. Simonetti, C. Borghi, C. Fachinetti, et al., COVID-19 pneumonia manifestations at the admission on chest ultrasound, radiographs, and CT: single-center study and comprehensive radiologic literature review, *Eur. J. Radiol. Open* 7 (2020), 100231.

- [14] Z. Kang, X. Li, S. Zhou, Recommendation of low-dose CT in the detection and management of COVID-2019, *Eur. Radiol.* (2020).
- [15] X. Xie, Z. Zhong, W. Zhao, C. Zheng, F. Wang, J. Liu, Chest CT for typical 2019-nCoV pneumonia: relationship to negative RT-PCR testing, *Radiology* (2020).
- [16] Z.Y. Zu, M.D. Jiang, P.P. Xu, W. Chen, Q.Q. Ni, G.M. Lu, et al., Coronavirus disease 2019 (COVID-19): a perspective from China, *Radiology* (2020).
- [17] A. Esposito, A. Palmisano, G.M. Scotti, M.J. Morelli, D. Vignale, F. De Cobelli, et al., Why is chest CT important for early diagnosis of COVID-19? Prevalence matters, *medRxiv* (2020).
- [18] A. Radpour, H. Bahrami-Motlagh, M.T. Taaghi, A. Sedaghat, M.A. Karimi, A. Hekmatnia, et al., COVID-19 evaluation by low-dose high resolution CT scans protocol, *Acad. Radiol.* (2020).
- [19] Y. Yi, P.N.P. Lagniton, S. Ye, E. Li, R.H. Xu, COVID-19: what has been learned and to be learned about the novel coronavirus disease, *Int. J. Biol. Sci.* 16 (10) (2020) 1753–1766.
- [20] M.-Y. Ng, E.Y.P. Lee, M.-Y. Yang, M.-Y. Yang, X. Li, M.-Y. Wang, et al., Imaging profile of the COVID-19 infection: radiologic findings and literature review, *Radiology: Cardiothoracic Imaging* (2020).
- [21] A. Dangis, C. Gieraerts, Y.D. Bruecker, L. Janssen, H. Valgaeren, D. Obbels, et al., Accuracy and reproducibility of low-dose submillisievert chest CT for the diagnosis of COVID-19, *Radiology: Cardiothoracic Imaging*. (2020).
- [22] A. Agostini, C. Floridi, A. Borgheresi, M. Badaloni, P. Esposto Pirani, F. Terilli, et al., Proposal of a low-dose, long-pitch, dual-source chest CT protocol on third-generation dual-source CT using a tin filter for spectral shaping at 100 kVp for Coronavirus Disease 2019 (COVID-19) patients: a feasibility study, *Radiol. Med.* 125 (4) (2020) 365–373.
- [23] Y. Ohno, H. Koyama, S. Seki, Y. Kishida, T. Yoshikawa, Radiation dose reduction techniques for chest CT: principles and clinical results, *Eur. J. Radiol.* 111 (2019) 93–103.
- [24] A. Ahmed, N. Verma, I. Barreto, T.L. Mohammed, Low-dose lung cancer screening at an academic medical center: initial experience and dose reduction strategies, *Acad. Radiol.* 25 (8) (2018) 1025–1030.
- [25] P.D. Deak, Y. Smal, W.A. Kalender, Multisection CT protocols: sex- and age-specific conversion factors used to determine effective dose from dose-length product, *Radiology* 257 (1) (2010) 158–166.
- [26] P. Conti, A. Younes, Coronavirus COV-19/SARS-CoV-2 affects women less than men: clinical response to viral infection, *J. Biol. Regul. Homeost. Agents* (2020).
- [27] E. Itelman, Y. Wasserstrum, A. Segev, C. Avaky, L. Negru, D. Cohen, et al., Clinical characterization of 162 COVID-19 patients in Israel: preliminary report from a large tertiary center, *Isr. Med. Assoc. J.* 22 (5) (2020) 271–274.
- [28] F. Pan, T. Ye, P. Sun, S. Gui, B. Liang, L. Li, et al., Time course of lung changes at chest CT during recovery from Coronavirus Disease 2019 (COVID-19), *Radiology* 295 (3) (2020) 715–721.
- [29] J.P. Kanne, B.P. Little, J.H. Chung, B.M. Elicker, L.H. Ketaj, Essentials for radiologists on COVID-19: an update-radiology scientific expert panel, *Radiology* (2020).