

# Author's Accepted Manuscript

Prostate Radiofrequency Focal Ablation (ProRAFT) trial: a prospective development study evaluating a bipolar radiofrequency device to treat prostate cancer

Orczyk C, Barratt D, Brew-Graves C, HU YP, Freeman A, McCartan N, Potyka I, Ramachandran N, Rodell R, Williams NR, Emberton M, Ahmed HU

DOI: [10.1097/JU.0000000000001567](https://doi.org/10.1097/JU.0000000000001567)

Reference: JU-20-611

To appear in: *The Journal of Urology*

Accepted Date: 01 December 2020

Please cite this article as: Orczyk C, Barratt D, Brew-Graves C, HU YP, Freeman A, McCartan N, Potyka I, Ramachandran N, Rodell R, Williams NR, Emberton M, Ahmed HU, Prostate Radiofrequency Focal Ablation (ProRAFT) trial: a prospective development study evaluating a bipolar radiofrequency device to treat prostate cancer, *The Journal of Urology*® (2019), doi: [10.1097/JU.0000000000001567](https://doi.org/10.1097/JU.0000000000001567).

**DISCLAIMER:** This is a PDF file of an unedited manuscript that has been accepted for publication. As a service to our subscribers we are providing this early version of the article. The paper will be copy edited and typeset, and proof will be reviewed before it is published in its final form. Please note that during the production process errors may be discovered which could affect the content, and all legal disclaimers that apply to The Journal pertain.

**Prostate Radiofrequency Focal Ablation (ProRAFT) trial: a prospective development study  
evaluating a bipolar radiofrequency device to treat prostate cancer**

Clement Orczyk [1,2], Dean Barratt [3], Chris Brew-Graves [4], Yi Peng HU[3], Alex Freeman [5],  
Neil McCartan [1], Ingrid Potyka [1], Navin Ramachandran [7], Rachael Rodell [8], Norman R.  
Williams[1], Mark Emberton[1,2] \*, Hashim U. Ahmed [9,6,1] \*

\* Joint senior authors

**Affiliations**

1. Division of Surgery and Interventional Sciences, University College London, London, UK
2. Department of Urology, UCLH NHS Foundation Trust, London, UK
3. Centre for Medical Image Computing (CMIC), University College London, London, UK
4. Centre for Medical Imaging, Division of Medicine, Faculty of Medicine, University College London, UK
5. Department of Histopathology, UCLH NHS Foundation Trust, London, UK
6. Imperial Prostate, Division of Surgery, Department of Surgery and Cancer, Faculty of Medicine, Imperial College London, London, UK
7. Department of Radiology, UCLH NHS Foundation Trust, London, UK
8. SmartTarget Ltd, London, UK
9. Imperial Urology, Charing Cross Hospital, Imperial College Healthcare NHS Trust, London; UK

Address for correspondence:

Mr Clement Orczyk, MD PhD DESC(Urol) FRCS MPH  
Associate Professor of Urology, Honorary Consultant Urological Surgeon  
Division of Surgery and Interventional Science  
University College London

Charles Bell House  
43-45 Foley Street  
London  
W1W 7TS  
[c.orczyk@ucl.ac.uk](mailto:c.orczyk@ucl.ac.uk)

## **Abstract:**

### **Purpose**

To determine early efficacy of bipolar radiofrequency ablation with a coil design (bRFA) for focal ablation of clinically significant localised prostate cancer (sPCa) visible at mpMRI.

### **Material and methods**

A prospective IDEAL phase 2 development study (NCT02294903) recruited treatment naive patients with a single focus of localised sPCa (Gleason 7 or 4mm or more of Gleason 6) concordant with a lesion visible on multi-parametric MRI. Intervention was a focal ablation with a bRFA system (Encage®, Trod Medical) encompassing the lesion and a predefined margin using non-rigid MRI-ultrasound fusion. Primary outcome was the proportion of men with absence of sPCa on biopsy at 6 months. Trial follow up comprised serum PSA, mpMRI at 1 week, 6 and 12 months post ablation. Validated patient reported outcome measures (PROMs) for urinary, erectile and bowel functions and adverse events monitoring system were used. Analyses were done on a per-protocol basis.

### **Results**

20 of 21 patients recruited received the intervention. Baseline characteristics were a median age of 66 years (IQR 63-69), pre-operative median PSA of 7.9ng/ml (5.3-9.6), 18 (90%) had Gleason 7 with median maximum cancer of 7mm (IQR 5-10) for a median 2.8cc mpMRI lesions (IQR 1.4-4.8). Targeted biopsy of the treated area (median number of cores = 6, IQR 5-8) showed absence of sPCa in 16/20 men (80%), concordant with mpMRI. There was a low profile of side effects at PROMs analysis and no serious adverse events.

## **Conclusions**

Focal therapy of sPCa associated with an MRI lesion using bRFA showed early efficacy to ablate cancer with low rates of genitourinary and rectal side-effects.

## **Funding**

The study was funded through a commercial grant awarded to UCL by Trod Medical.

Clement Orczyk received a grant from the European Association of Urology (EUSP Scholarship)

ACCEPTED UNEDITED MANUSCRIPT

## Introduction

Focal therapy of localised prostate cancer is an emerging treatment that aims to limit the side effects of standard whole-gland prostatectomy or radiotherapy [1–3] whilst retaining acceptable cancer control. The rationale is based on the current rather unfavourable therapeutic ratio when early prostate cancer is treated radically [4,5]. A recent systematic review and subsequent case series showed focal therapy using a number of different ablative modalities had low side-effect profiles with encouraging short to medium term oncological results[6–9].

There has been a shift in the last decade[10] to propose focal therapy as an alternative to men who would otherwise need radical therapy rather than it being an alternative to active surveillance [11,12]. Different ablative energies have been reported with some limitations in efficacy to ablate anterior and posterior disease, which has led to some proposing an ‘a la carte’ approach to optimize either energy delivery or limit damage to critical anatomical structures like the rectum[13].

Successful cancer ablation with radiofrequency has been already reported in many different organs, like kidney[14] or liver[15], including the prostate gland. Radiofrequency ablation using the coiled Encage device (Trod Medical) (bRFA) may be effective in safely and effectively ablating lesions in all locations in the prostate due to the coil design allowing a very sharp transition of up to 0.06mm from ablated to non-ablated tissue [16,17].

The primary objective of the study was to assess early efficacy of bRFA for cancer control in patients with clinically significant prostate cancer localised to the prostate. To our knowledge, this is the first report of an ethics committee approved, prospectively registered study evaluating the Encage® device for focal ablation of prostate.

## Material and methods

### *Study design*

The Prostate Radiofrequency Focal Ablation (ProRAFT) trial was a stage II prospective development study according to IDEAL framework [18] for surgical innovation which was registered prior to first patient recruited (clinicaltrials.gov NCT02294903) and underwent ethical approval (NRES London-Riverside 15/LO/009). Enrolment started in May 2015 and closed in March 2016 with follow up until August 2017.

*Cancer localization and risk stratification:* Patients with clinically significant prostate cancer using UCL definition 2 (Gleason Score 3+4 or Maximum Cancer Core Length [MCCL]  $\geq$  4mm) on transperineal biopsy concordant with an mpMRI lesion were eligible. mpMRI followed a standardized acquisition protocol with T2 weighted imaging (WI), diffusion weighted imaging (DWI) and dynamic contrast enhanced (DCE) sequences and were interpreted by experienced radiologists. Only lesions with a Likert Score  $\geq$  3 were eligible for ablation. The presence of insignificant foci was permitted outside of the planned treatment zone (Gleason Score 6 and MCCL  $<$  4mm). Men with multiple lesions at mpMRI were eligible for the study, provided all those locations were sampled and only one mpMRI harboured significant cancer

*Treatment planning:* it was lesion-based as the technology allowed the shaping of the treatment zone. Lesion amenability with the Encage technology was defined as a lesion accessible to complete ablation including a margin between 5mm and 9mm [19] and sparing critical anatomical structures using a combination of multiple coils and additional probes inserted around the coil if necessary as shown in figure 1. MRI lesions and margin were contoured manually from MRI sequence which demonstrated the most extensive lesion volume (Osirix®). An additional 5mm to 9mm intraprostatic margin was incorporated [20,21].

Bipolar radiofrequency ablation: Focal ablation with the Encage device was performed either under general or spinal anaesthesia in lithotomy position with antibiotic prophylaxis. The whole procedure is described in supplementary 1. To summarize, we used a customised needle delivery system calibrated for use with the ultrasound-MRI non-rigid fusion device (customized version of the Smart Target®). The procedure included acquisition of 3D ultrasound images which were then registered with the MRI contours, allowing overlay of the lesion and its margin. Treatment was delivered by a combination of coils and extra needles as depicted in Figure 1. cbRFA is applied consecutively to the coils until complete coverage of the lesion and the margin were achieved. A urethral catheter was placed at the end of the procedure. The same procedure was conducted in case of retreatment.

*Follow up:* A mpMRI was carried out between 3 and 10 days post-operatively after catheter removal. Early post-treatment MRI was performed to ensure absence of early complications and assess treatment coverage. Clinical reviews were organised at 6 weeks and 3, 6, 9 and 12 months concomitant with PSA measurements. At each follow-up visit, patients were asked to complete validated questionnaires which included IIEF-15, UCLA-EPIC urinary continence questionnaire, EPIC Bowel Questionnaire, IPSS, IPSS-QoL, EQ-5D and FACT-P Version 4 [22]. Adverse events were graded using the NCI CTC classification system (v4). Use of PDE-5 for erectile function was recorded.

mpMRIs at 6 and 12 months were evaluated for residual cancer or emergence of new lesions. The 6 month mpMRI was used to guide targeted biopsies of the treated area with an approximate density of a minimum of 1 core per 1ml tissue and any new lesions.

In case of retreatment, another early post-treatment mpMRI was acquired after catheter removal. Biopsy of the re-treated area at 6 months from retreatment also occurred (see supplementary 3).

### *Objectives*

The primary objective was treatment efficacy as assessed on histology from transperineal targeted biopsy of the treated area at 6 months. Treatment success was defined by histological absence of clinically significant prostate cancer in the treated area. Secondary objectives were to determine the achievement of trifecta status for patient with good baseline functions, side effect profile of bRFA, urinary, erectile and rectal toxicity, disease control in case of retreatment, time to secondary prostate cancer intervention treating the whole gland, proportion of visible lesion at 1 week, 6 and 12 months, the role of mpMRI in follow up and assessment of the US-MRI fusion workflow for treatment planning. Good baseline potency function was defined prior analysis as score of 4 or 5 at question 2 of IIEF-15. Trifecta was defined as persistence of those functional features for continence and erectile function with absence of clinically significant prostate cancer on biopsy at trial completion.

#### *Statistical analysis*

A sample size of 20 was chosen as this maximized the increase in precision to detect a proportion of 80% of patients with a successful ablation at 6 months. There was an increase in the precision estimate from n=10 to n=20 with little further gain in precision beyond 20 men, something that was consistent with previous studies [23]. With a sample size of 20 and an expected proportion of 80% achieving the primary outcome, the precision would be  $\pm 17.5$  (95% Confidence interval).

A pre-specified Statistical Analysis Plan was written and approved prior to database lock and analyses (Supplementary 4).

## **Results**

#### *Baseline demographics*

Of the 21 recruited men, 20 received the procedure and these data were available for analysis of the primary outcome (Table 1). One patient was withdrawn on the operating table because of



combination of his perineal anatomy (thickness of fat layer) and length of the probe (too short to reach the base of the 33cc gland). Two (10%) and 18 (90%) had D'Amico low and intermediate risk prostate cancer. All met criteria for UCL definition 2 clinical significance at minimum. Median mpMRI cancer volume was 2.8cc (IQR 1.4-4.8) for a median MCCL of 7mm (IQR 5-10). Ten (50%) patients had anterior and 10 (50%) posterior cancers. Mean distance of the cancer boundaries to apex of the gland was 3mm (IQR 0-6). Anterior and posterior diseases presented significantly different morphometric characteristics at MRI analysis (Table 1). This illustrates the different critical anatomic structures to avoid to damage like the rectum posteriorly or the pubic bone and bladder neck anteriorly (figure 2) while delivering appropriate energy delivery to pursue a complete ablation. Eleven (55%) patients were eligible at baseline for assessment of the trifecta status after PROMS analysis using predetermined criteria. Those 11 patients eligible for assessment of trifecta status were continent (no leakage and no use pad) before treatment **with** a good baseline erectile function defined as a score of 4 or 5 at question 2 of IIEF-15 (erection sufficient for intercourse reported as 'always' or 'most of the time'). No subject withdrew consent, died, or was lost to follow-up.

### *Procedure*

Characteristics of the procedure are presented in Table 2. The development aspect of the technique is detailed in supplementary 2, in compliance with the IDEAL framework for surgical innovations. The coils of 8 and 12mm in diameter were found to be the more appropriate for prostate ablation. The median time to complete the fusion US-MRI using the Smart Target and treatment planning was 9 min (IQR 5.5-13.5). The median time to deliver the ablation was 89 min (IQR 66-118). Figure 3 shows pre, intra and post operative imaging.

### *Outcomes*

*Primary:* There were 16 (80%) patients free of clinically significant prostate cancer on targeted transperineal biopsy of the treated area at 6 months. A median number of 6 (IQR ; range 4-11) cores were taken from the ablated area, resulting in a sampling density of 3.3 cores per 1ml (IQR; 0.65-4.71) of lesion to treat at baseline. In all cases, the ablated zone and its inherent shrinkage was discernable in both mpMRI and ultrasound guiding the biopsy. Figure 4 depicts shrinkage of the gland, histology of coagulation necrosis and a sharp transition to undamaged tissue on a targeted biopsy of the ablated area at 6 months from treatment. Absence of any cancer was noted in 15 (75%) and 1 patient was considered clinically insignificant as per protocol due to MCCL of 1 mm and Gleason 6. Retreatment as per protocol was delivered in 2 patients and 2 preferred active surveillance for 4mm of Gleason 6 and 1mm of Gleason 3+4=7 with a 5% component of grade 4. There was no difference in the proportion of patients failing the primary objective when stratified by location of the disease (anterior vs posterior) (Table 2). Serum PSA decreased from median 7.6ng/ml (IQR 5.3-9.6) at baseline to 2.7ng/ml (IQR 0.3-3.75) ( $p<0.0001$  mean difference 4.41 [2.98; 5.85]).

### *Secondary*

Per protocol analysis, 94% (16/17) of patients were free of significant cancer 6 months after the last treatment, including retreatment. 3 patients did not fully comply with the protocol after the Visit 6 (biopsy), 2 entered into surveillance ( no retreatment) and 1 declined 6 months biopsy post retreatment. No patient transitioned to another treatment within the timeframe of the study. No new significant cancer outside the treatment zone nor new lesion progression as expected in the time frame of the study (out of field recurrence) occurred during the trial. Performances of mpMRI in the post-operative are in supplementary 5.

The absence of erectile dysfunction, defined by an inability to have erections sufficient for intercourse, at 12 months, as measured by the IIEF-15 questionnaire with or without the use of PDE-5, in those with absence of erectile dysfunction at baseline, was seen in 91.7% (11/12) (Figure 5). The return to baseline occurred by 6 weeks as assessed by PROMS. There was no change in scores for

intercourse satisfaction, in sexual desire, in overall sexual satisfaction and orgasmic function for patients with available data (Figure 5).

Absence of urinary incontinence (any pad usage plus any leakage of urine) as determined by the EPIC urinary continence questionnaire, at 12 months, in those men with no urinary incontinence at baseline, was seen in 89% (16/18). Two patients reported to use one pad a day, one for bladder overactivity pad one at 6 months from the procedure. (supplementary 5). There was no change in scores measuring lower urinary tract symptoms, bowel habit, general health and prostate health related quality of life as determined by IPSS and IPSS-QoL, EPIC Bowel Questionnaire and EQ-5D and FACT-P scores at 12 months, compared to baseline; in men with data available (Figure 5). ANOVA testing only detected significant changes across the length of the study for IPSS ( $p=0.017$ ) and EPIC urinary domain ( $p=0.013$ ) even if at 12 months the change from baseline in score were respectively 0 (IQR -3 to 0) and 0 (IQR -6.6 to 5.2). Figure 5 shows that changes are captured at 6 weeks with a return to baseline by 3 months post treatment. Of the 11 patients eligible for assessment of the trifecta status, all of them (11/11; 100%) completed it at 1 year.

There were 40 adverse events (AE) reported during the year of follow up for the entire cohort. There were 11 (27.5%) CTC AE Grade 1, 29 (72.5%) grade 2 and none were grades 3, 4 or 5. The most reported AE was urinary tract obstruction reported 8 times. None of the 3 serious AE were related to the intervention and were classified CTC AE 2. Presence of recto-urethral fistula and severe (grade III-type) or mild-moderate (grade I-II) rectal toxicity, was not reported in any men (0%). Two patients developed urethral stricture which were managed successfully by endoscopic procedures and one man had a perineal skin tear which required immediate repair as a result of use of a larger 16 mm double coil (which we subsequently stopped using) (Supplementary 2). This AE resolved without complications.

The early post treatment mpMRI depicted confluent necrosis in all cases with a mean volume of 16cc.

As a development study, phase 2 according to IDEAL framework for surgical innovation[18], iteration of the procedures permitted to refine the surgical technique and workflow. This is documented in supplementary 2.

## **Discussion**

In summary, we report the first successful study of coil bipolar radiofrequency ablation to deliver focal therapy to ablate clinically significant prostate cancer associated with a mpMRI lesion. This lends support to conducting an IDEAL therapeutic confirmatory study. The results show that not only can this technology destroy prostate cancer cells, but also can adapt to the challenging anatomical environment of the prostate gland and match the morphometry of significant cancers eligible for focal therapy. Most anterior and posterior lesions, including the necessary margin around an MRI lesion, can be ablated successfully with this device. While some strategies recommend the choice of energy by location of the disease [13], the main limitation of this technology would refer to the detectability of the cancer as significant using a transperineal biopsy through a brachytherapy grid as a proxy to accessibility for ablation to this technology, potentially excluding anterior lesions in large glands (>100cc) where the interference with the pubic arch could be problematic. We also confirm the low rate of side-effects and complications that can occur from focal therapy, with no differences from baseline.

The specific design of an asymmetric bipolar radiofrequency system using a coil, visible under ultrasound, permitted the delivery of a uniform zone of coagulative necrosis where it was planned for. A previous phase 1 study using radiofrequency as an energy source but a different device design reported large variability in induced necrotic lesions, abortion of case due to concern of the rectal wall and the need for thermoprobes to control treatment[24,25]. We did not experience those limitations of the radiofrequency energy with the coil design and did not use thermoprobes.

The sharpness of the transition zone between ablated and intact tissue (figure3) and its predictability limit the challenge of focal ablation to placement of the coils and delivery of the treatment planning.

The development of a stabilized technique required multiple refinements in this IDEAL phase 2 trial. Operators had significant experience in transperineal procedures under US guidance, which is a prerequisite to deliver the intervention. Otherwise, the learning curve would be considerable. Iterative changes were needed as detailed in supplementary 2 to develop a new intervention specific for the prostate using this coil-based design. One of the most significant findings was the use of the needle electrode outside the coil to create a bipolar system permitting to extend the margin outside the coil. Outside critical anatomic zones to be preserved, this was very useful to quickly perform an additional ablation in contiguity with the intra coil ablation to extend the margin by inserting a needle through an already positioned hole of the coil holder. Even going through those refinements steps and a learning curve, we achieved in this first use in men trial very good efficacy of 80% free of significant disease. In this area of treatment guidance, the study benefited from the use of the non-rigid MRI-US fusion platform system adapted for the study to ensure lesion and margin coverage to overcome our limited experience with this device. In the 20% of cases with failure, there was more residual disease on the boundaries of the ablated area rather than within the centroid of the ablated zone. The urethral stricture rate should be carefully assessed in further larger exploratory study.

The design of this study follows the recommendations from focal therapy consensus panels to treat patients presenting with clinically significant prostate cancer, intermediate risk, and not those who would be eminently suitable for active surveillance. As a limitation, the current results cannot be generalised to this whole risk category. One of the main entry criteria was the presence of a single MRI visible lesion confirmed by transperineal sampling with significant cancer matching inclusion criteria. Lesion amenability with the device was assessed based on MRI, which could have impaired the morphometric characteristics of the ablated lesions. However, those characteristics match both in shape or volume what has been described in contemporary detailed analysis of cancer foci of radical prostatectomy series[20,21]. For example, median index tumour volume of 2.8ml was in the same range as the 2.2ml described by Haffner et al[20].

In comparison to other technologies tested in phase 2 studies for which systematic sampling was obtained, cbRFA shows the same range of success with 80% of absence of disease in this first of its kind trial[6]. Previous lesion-based focal ablation studies not including an appropriate margin failed to achieve similar results to those presented here with a higher failure rate of up to 75%.[26][27][28]

### **Conclusion**

Focal therapy of an MRI lesion associated with clinically significant prostate cancer using bipolar radiofrequency ablation showed early efficacy to ablate cancer and had low rates of genitourinary and rectal side-effects.

### **Authorship**

CO, HUA and NRW were responsible for data collection, analysis of the data. HUA and CO were responsible for production of the first draft. CO and NW completed the data analysis. All authors were involved in data collection, manuscript preparation/drafting and approval of the final draft. HUA

and ME had full access to all of the data in the study and takes responsibility for the integrity of the data and the accuracy of the data analysis. HUA is guarantor of the study.

**Acknowledgment:**

The authors wish to thank the participants who volunteered to take part in this study, and Ms Carol Roach and Ms Bina Shah of the UCL Surgical & Interventional Trials Unit for coordination of the study

**Declaration of Interests**

Ahmed and Emberton received a commercial grant from Trod Medical for this trial.

Ahmed's research is supported by core funding from the United Kingdom's National Institute of Health Research (NIHR) Imperial Biomedical Research Centre. Ahmed currently receives funding from the Wellcome Trust, Prostate Cancer UK, MRC (UK), Cancer Research UK, The BMA Foundation, The Urology Foundation, The Imperial Health Charity, Sonacare Inc., Trod Medical and Sophiris Biocorp for trials in prostate cancer. Ahmed is a paid medical consultant for Sophiris Biocorp, Sonacare Inc., BTG/Galil and Boston for work in trials or registries as well as training HIFU, cryotherapy and Rezum procedures.

Emberton receives research support from the United Kingdom's National Institute of Health Research (NIHR) UCLH/UCL Biomedical Research Institute. He is an NIHR Senior Investigator. Emberton receives funding from NIHR-i4i, MRC, Cancer Research UK, Sonacare Inc., Trod Medical, Cancer Vaccine Institute and Sophiris Biocorp for trials in prostate cancer. Emberton is a medical consultant to Sonacare Inc., Sophiris Biocorp, Steba Biotech, Exact Imaging and Profound Medical.

Emberton and Freeman have loan notes/stock options in Nuada Medical Ltd (UK).

C.ORCZYK received a grant from the European Association Urology as a Scholarship for the study in 2016. C. Orczyk performs consultancy for TROD Medical through UCL Consultancy from

02/2019 to 02/2020. C.Orczyk is an official proctor for focal cryotherapy of the prostate for Endocare LLC.

### Role of Funding Source

The funder of this trial, Trod Medical, was the Sponsor and therefore had input into the design and protocol as well as conducting data validation and monitoring. Trod Medical approved the statistical analysis plan without modifications. The final analysis that forms the findings for this manuscript were carried out independently by Norman Williams and none other than the authors had input into the interpretation of the data nor the preparation, review of the manuscript. TROD medical did not exercise its right to delay submission of the manuscript.

### References

- [1] Hu JC, Gu X, Lipsitz SR, Barry MJ, D'Amico AV, Weinberg AC, et al. Comparative effectiveness of minimally invasive vs open radical prostatectomy. *JAMA* 2009;302:1557–64. <https://doi.org/10.1001/jama.2009.1451>.
- [2] Sanda MG, Dunn RL, Michalski J, Sandler HM, Northouse L, Hembroff L, et al. Quality of life and satisfaction with outcome among prostate-cancer survivors. *N Engl J Med* 2008;358:1250–61. <https://doi.org/10.1056/NEJMoa074311>.
- [3] Chen RC, Basak R, Meyer A-M, Kuo T-M, Carpenter WR, Agans RP, et al. Association Between Choice of Radical Prostatectomy, External Beam Radiotherapy, Brachytherapy, or Active Surveillance and Patient-Reported Quality of Life Among Men With Localized Prostate Cancer. *JAMA* 2017;317:1141. <https://doi.org/10.1001/jama.2017.1652>.
- [4] Bill-Axelson A, Holmberg L, Garmo H, Taari K, Busch C, Nordling S, et al. Radical Prostatectomy or Watchful Waiting in Prostate Cancer — 29-Year Follow-up. *N Engl J Med* 2018;379:2319–29. <https://doi.org/10.1056/NEJMoa1807801>.
- [5] Donovan JL, Hamdy FC, Lane JA, Mason M, Metcalfe C, Walsh E, et al. Patient-Reported Outcomes after Monitoring, Surgery, or Radiotherapy for Prostate Cancer. *N Engl J Med* 2016;375:1425–37. <https://doi.org/10.1056/NEJMoa1606221>.
- [6] Valerio M, Cerantola Y, Eggener SE, Lepor H, Polascik TJ, Villers A, et al. New and Established Technology in Focal Ablation of the Prostate: A Systematic Review. *Eur Urol* 2017;71:17–34. <https://doi.org/10.1016/j.eururo.2016.08.044>.
- [7] Guillaumier S, Peters M, Arya M, Afzal N, Charman S, Dudderidge T, et al. A Multicentre Study of 5-year Outcomes Following Focal Therapy in Treating Clinically Significant Nonmetastatic Prostate Cancer. *Eur Urol* 2018;74:422–9. <https://doi.org/10.1016/j.eururo.2018.06.006>.



- [8] Stabile A, Orczyk C, Hosking-Jervis F, Giganti F, Arya M, Hindley RG, et al. Medium-term oncological outcomes in a large cohort of men treated with either focal or hemi-ablation using high-intensity focused ultrasonography for primary localized prostate cancer. *BJU Int* 2019. <https://doi.org/10.1111/bju.14710>.
- [9] Shah TT, Peters M, Eldred-Evans D, Miah S, Yap T, Faure-Walker NA, et al. Early-Medium-Term Outcomes of Primary Focal Cryotherapy to Treat Nonmetastatic Clinically Significant Prostate Cancer from a Prospective Multicentre Registry. *Eur Urol* 2019. <https://doi.org/10.1016/j.eururo.2018.12.030>.
- [10] Orczyk C a, Emberton M a, Ahmed HU a. What tumours should we treat with focal therapy based on risk category, grade, size and location?. *Curr Opin Urol* 2015;25:212–9. <https://doi.org/10.1097/MOU.000000000000170>.
- [11] Donaldson IA, Alonzi R, Barratt D, Barret E, Berge V, Bott S, et al. Focal Therapy: Patients, Interventions, and Outcomes—A Report from a Consensus Meeting. *Eur Urol* 2015;67:771–7. <https://doi.org/10.1016/j.eururo.2014.09.018>.
- [12] van den Bos W, Muller BG, Ahmed H, Bangma CH, Barret E, Crouzet S, et al. Focal Therapy in Prostate Cancer: International Multidisciplinary Consensus on Trial Design. *Eur Urol* 2014;65:1078–83. <https://doi.org/10.1016/j.eururo.2014.01.001>.
- [13] Sivaraman A, Barret E. Focal Therapy for Prostate Cancer: An “À la Carte” Approach. *Eur Urol* 2016;69:973–5. <https://doi.org/10.1016/j.eururo.2015.12.015>.
- [14] Pan X-W, Cui X-M, Huang H, Huang Y, Li L, Wang Z-J, et al. Radiofrequency ablation versus partial nephrectomy for treatment of renal masses: A systematic review and meta-analysis. *Kaohsiung J Med Sci* 2015;31:649–58. <https://doi.org/10.1016/j.kjms.2015.09.007>.
- [15] Lencioni R, de Baere T, Martin RC, Nutting CW, Narayanan G. Image-Guided Ablation of Malignant Liver Tumors: Recommendations for Clinical Validation of Novel Thermal and Non-Thermal Technologies - A Western Perspective. *Liver Cancer* 2015;4:208–14. <https://doi.org/10.1159/000367747>.
- [16] Richstone L, Ziegelbaum M, Okeke Z, Faure A, Kaye JD, Sette MJ, et al. Ablation of bull prostate using novel bipolar radiofrequency ablation probe. *J Endourol Endourol Soc* 2009;23:11–6. <https://doi.org/10.1089/end.2008.0105>.
- [17] Okhunov Z, Roy O, Duty B, Waingankar N, Herati A, Morgenstern N, et al. Clinical evaluation of a novel bipolar radiofrequency ablation system for renal masses. *BJU Int* 2012;110:688–91. <https://doi.org/10.1111/j.1464-410X.2012.10940.x>.
- [18] McCulloch P, Altman DG, Campbell WB, Flum DR, Glasziou P, Marshall JC, et al. No surgical innovation without evaluation: the IDEAL recommendations. *The Lancet* 2009;374:1105–12. [https://doi.org/10.1016/S0140-6736\(09\)61116-8](https://doi.org/10.1016/S0140-6736(09)61116-8).
- [19] Le Nobin J, Rosenkrantz AB, Villers A, Orczyk C, Deng F-M, Melamed J, et al. Image Guided Focal Therapy for Magnetic Resonance Imaging Visible Prostate Cancer: Defining a 3-Dimensional Treatment Margin Based on Magnetic Resonance Imaging Histology Co-Registration Analysis. *J Urol* 2015;194:364–70. <https://doi.org/10.1016/j.juro.2015.02.080>.
- [20] Haffner J, Potiron E, Bouye S, Puech P, Leroy X, Lemaitre L, et al. Peripheral zone prostate cancers: location and intraprostatic patterns of spread at histopathology. *Prostate* 2009;69:276–82.
- [21] Bouye S, Potiron E, Puech P, Leroy X, Lemaitre L, Villers A. Transition zone and anterior stromal prostate cancers: zone of origin and intraprostatic patterns of spread at histopathology. *Prostate* 2009;69:105–13.
- [22] Hamoen EHJ, De Rooij M, Witjes JA, Barentsz JO, Rovers MM. Measuring health-related quality of life in men with prostate cancer: A systematic review of the most used questionnaires and their validity. *Urol Oncol Semin Orig Investig* 2015;33:69.e19-69.e28.

<https://doi.org/10.1016/j.urolonc.2013.10.005>.

[23] Ahmed HU, Freeman A, Kirkham A, Sahu M, Scott R, Allen C, et al. Focal therapy for localized prostate cancer: a phase I/II trial. *J Urol* 2011;185:1246–54.

<https://doi.org/10.1016/j.juro.2010.11.079>.

[24] Zlotta, Djavan, Matos, Noel, Peny, Silverman, et al. Percutaneous transperineal radiofrequency ablation of prostate tumour: safety, feasibility and pathological effects on human prostate cancer. *Br J Urol* 1998;81:265–75. <https://doi.org/10.1046/j.1464-410X.1998.00504.x>.

[25] Shariat SF, Raptidis G, Masatoschi M, Bergamaschi F, Slawin KM. Pilot study of radiofrequency interstitial tumor ablation (RITA) for the treatment of radio-recurrent prostate cancer. *The Prostate* 2005;65:260–7. <https://doi.org/10.1002/pros.20242>.

[26] Oto A, Sethi I, Karczmar G, McNichols R, Ivancevic MK, Stadler WM, et al. MR Imaging-guided Focal Laser Ablation for Prostate Cancer: Phase I Trial. *Radiology* 2013;267:932–40. <https://doi.org/10.1148/radiol.13121652>.

[27] Valerio M, Dickinson L, Ali A, Ramachandran N, Donaldson I, McCartan N, et al. Nanoknife Electroporation Ablation Trial: A Prospective Development Study Investigating Focal Irreversible Electroporation for Localized Prostate Cancer. *J Urol* 2017;197:647–54. <https://doi.org/10.1016/j.juro.2016.09.091>.

[28] Natarajan S, Raman S, Priester AM, Garritano J, Margolis DJA, Lieu P, et al. Focal Laser Ablation of Prostate Cancer: Phase I Clinical Trial. *J Urol* 2016;196:68–75. <https://doi.org/10.1016/j.juro.2015.12.083>.

ACCEPTED UNEDITED MANUSCRIPT

Table 1. Baseline Characteristics

<b>Patient demographics</b>		
Median age (years) (IQR)	66.5	63-69
Median PSA (ng/ml) (IQR)	7.9	5.3-9.6
Median prostate volume (ml) (IQR)	42.2	30.5-50.9
<b>Biopsy strategy (%) (median positive cores per lesion)</b>		
5mm transperineal mapping	3(15%)	9
Transperineal systematic and targeted	4(20%)	5
Targeted only	13(65%)	3
<b>Pre treatment Biopsy Histology of lesion to treat</b>		
Median max Ca core length (mm) (IQR)	7	5-10
No. Gleason score (%):		
3+3=6	2	10%
3+4=7	17	85%
4+3=7	1	5%
<b>Untreated cancer focus outside treated area at baseline (%)</b>		
Median Maximum Core length of Gleason 6 (mm)	1	
<b>No D'Amico risk group(%):</b>		
low	2	10%
Intermediate	18	90%
High	0	
<b>No. per threshold of significance of UCL definition (%):</b>		
Insignificant	0	
Matching only Definition 2 (G ≥ 3+4 or MCCL ≥4mm)	13	65%
Definition 1 (G ≥ 4+3 or MCCL ≥10mm)	7	35%
<b>MRI Lesion characteristics</b>		
<b>MRI Likert score (%):</b>		
Score 3	3	15%
Score 4	10	50%

Score 5	7	35%
Median lesion MRI volume (ml) (IQR)	2.7	1.4-4.8
Median lesion width (mm) (IQR)	16	13-19
Median distance of the lesion from apex (mm) (IQR)	3	0-6
Lesion abutting the apex with distance equal to 0 mm to apex (%)	9	45%
Median distance of the lesion from base (mm) (IQR)	10	2-12
Lesion abutting the base with distance equal to 0 mm to base (%)	5	25%
<b>Location of MRI lesion</b>		
<u>Anterior Cancer (%)</u>	10	50%
Mean distance from posterior capsule to most anterior part of cancer lesions in mm (IQR)	35*	32-37
Mean distance from posterior capsule to most posterior part of cancer lesions in mm (IQR)	13**	9-14
<u>Posterior Cancer (%)</u>		
<u>Posterior Cancer (%)</u>	10	50%
Mean distance from posterior capsule to most anterior part of lesion (mm) (IQR)	19*	16-20
Mean distance from posterior capsule to most posterior part of lesion (mm) (IQR)	0**	0-0
* significant difference T test p<0.0001; 6.2 mm 95%[10.8569 ; 21.7431]		
** significant difference T test p<0.0001; 5.1 mm 95%[6.8251 ; 16.1749]		

Table 2. Procedure characteristics, histology and mpMRI Results

<b>Procedure characteristics</b>		
General Anesthesia (%)	15	(75%)
Spinal Anesthesia (%)	5	(25%)
Median Time (minutes), for Smart Target US-MRI treatment planning (IQR)	9	5.5-13.5
Median Time (minutes), for treatment delivery (IQR)	89	66-118
<b>RFA Probe use</b>		
Median No. Coil/pt (IQR)	2	2-3
Median No. pull back/pt (IQR)	2	2-4
Median No. extraneedles/pt (IQR)	11	7-14
Ultrasound changes* detected during the ablation	100%	
Change in impedance superior to 10 times pre ablation impedance**	95%	
<b>6 months biopsy (Primary Outcome)</b>		
Number of cores/ ablated zone (IQR)	6	5-8
Mean Density of cores per ml of ablated tissue (IQR)	0.9	0.7-1.4
Mean Density of cores per ml of initial tumour volume (IQR)	3.3	1.4-4.7
<b>Negative for clinically significant cancer (%)</b>		
<b>16 80%</b>		
Negative for any cancer (%)	15	75%
Fibrosis-necrosis present (%)	20	100%
Median (mm), maximum core length residual cancer (IQR)	4	1-4
Gleason score in residual cancer		
Gleason 3+3=6	3	
Gleason 3+4=7	2	
Failure with anterior disease (% of anterior cancers)	2	(2/10 ; 20%)
Failure with posterior disease (% of posterior cancers)	2	(2/10 ; 20%)
<b>mpMRI changes</b>		
Median MRI volume of necrosis (ml)	14.7	11.1-21
Complete coverage (%)	16	80%
Residual lesion (%)	4	20%
Median lesion residual volume (6 months MRI)(IQR) (ml) n=4	0.7	0.08-0.8
Reduction in size of MRI lesion in patient with positive biopsy (%)	5/5	100%

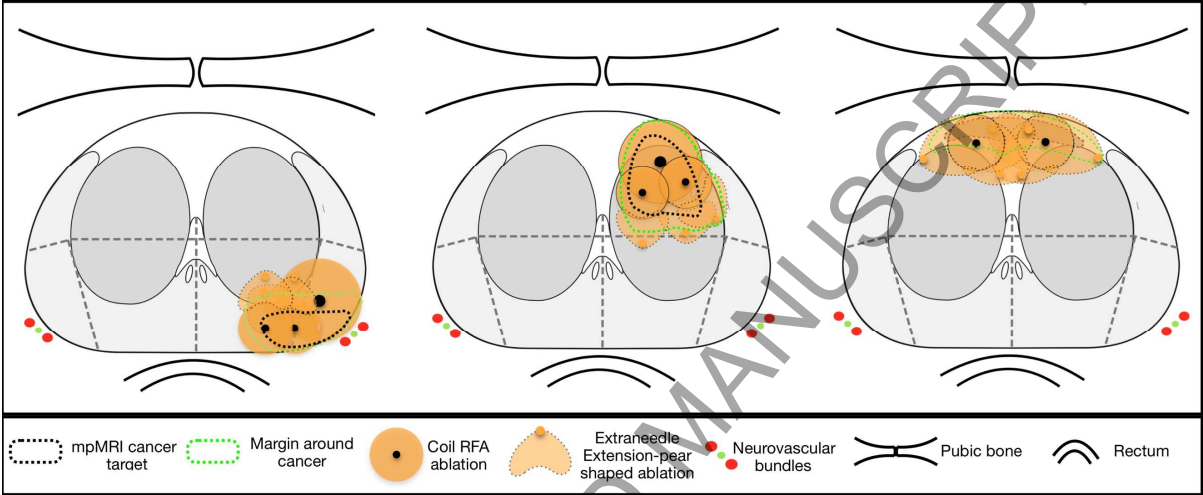
\*ultrasound changes are hyperechogenic features seen within the coil during the ablation and shortly after completion.

\*\*Increase in impedance of power between electrodes of the bipolar system characterise dehydration of tissue and therefore coagulation necrosis. For Patient 1, 1 ablation did not reach this threshold of 10 times the start impedance.

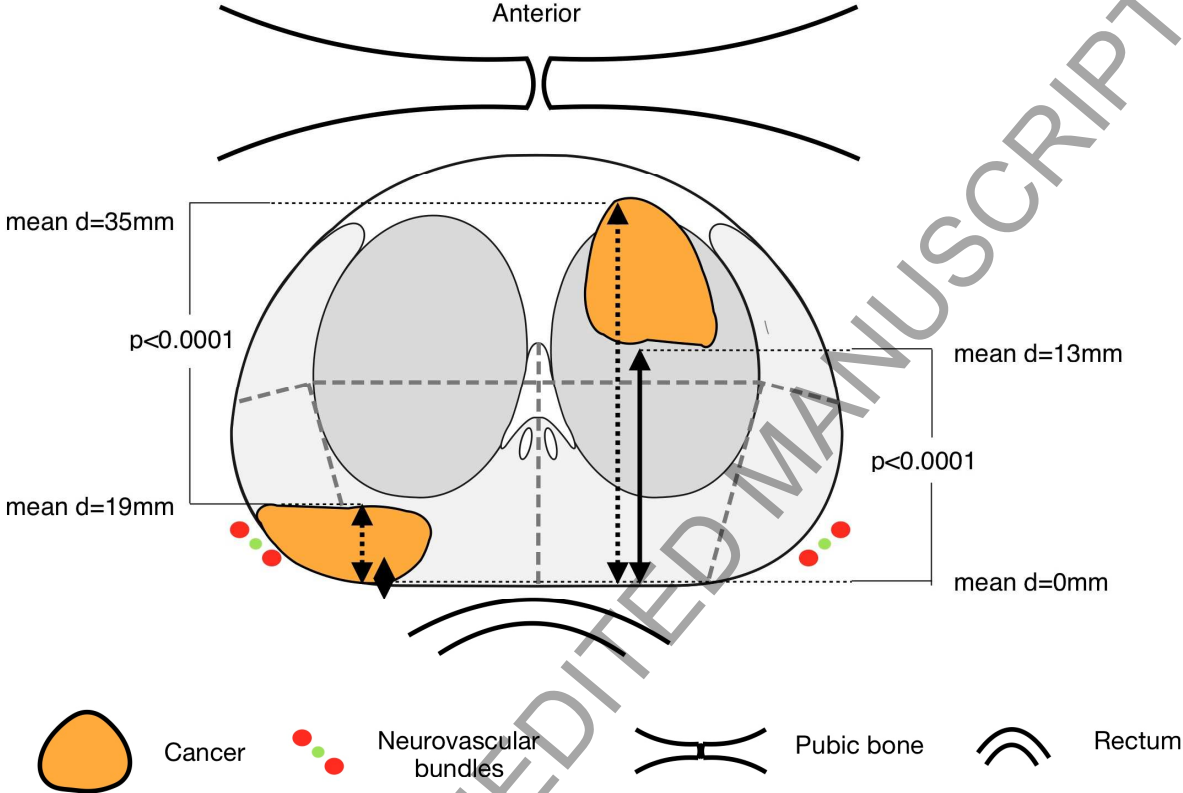
ACCEPTED UNEDITED MANUSCRIPT

Figure 1 Focal Treatment planning and delivery based on location of cancer focus using bipolar RFA and relationship to critical anatomic structures (pubic bone, rectum, neurovascular bundles and urethra).

- A. Left peripheral zone cancer
- B. Left transition zone cancer
- C. Crossing midline cancer from anterior fibromuscular stroma.



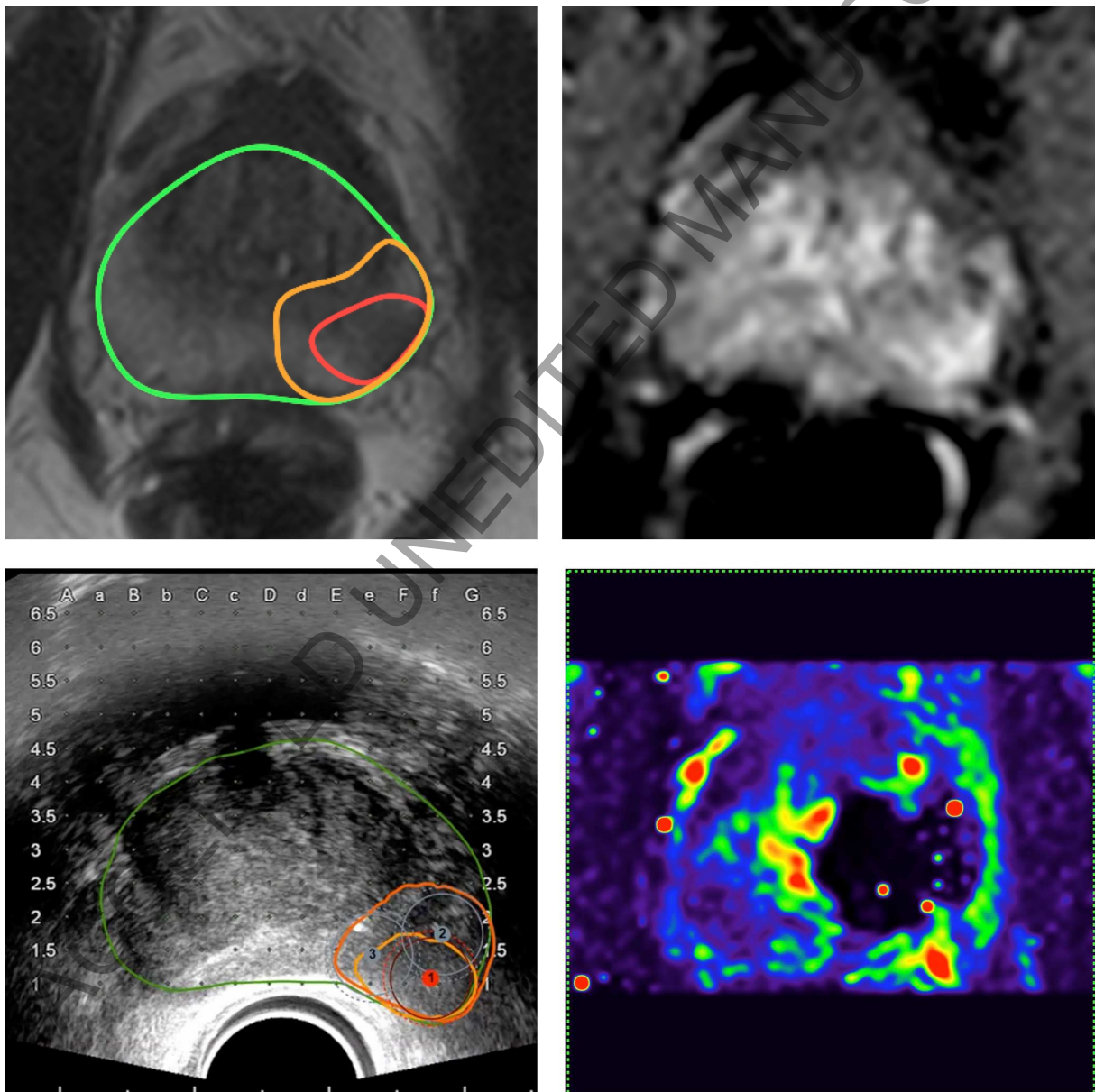
**Figure 2** Differences in morphometric characteristics between anterior and posterior cancer based on mpMRI analysis. Distances are measured from the posterior edge of the prostate in axial plan for the most anterior and most posterior component of the cancer to ablate. 10 anterior and 10 posterior cancers are compared using non paired one sided T-test.



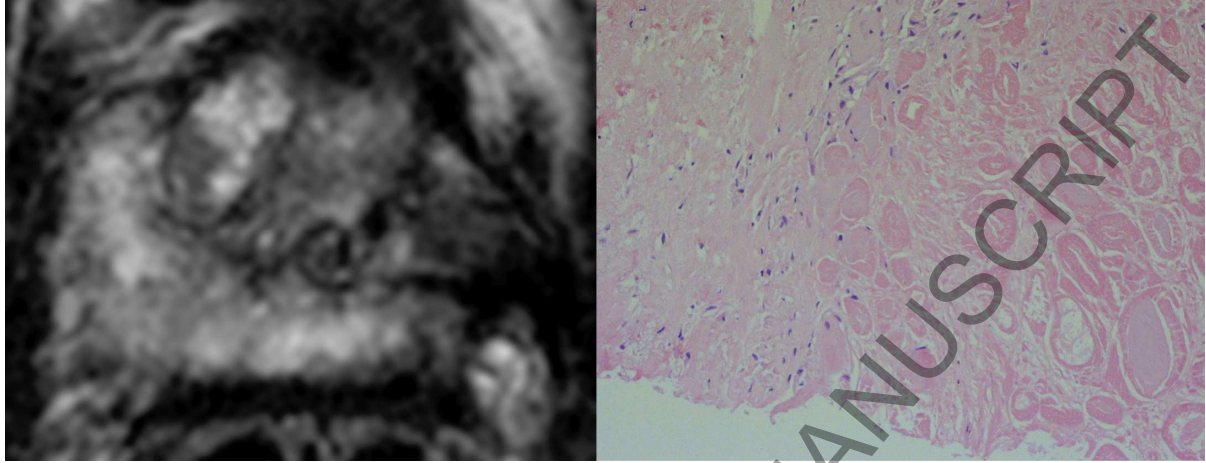


**Figure 3** 68 years old enrolled patient presenting localized prostate cancer Gleason 7 (3+4) with a maximum core length of 11mm of the left peripheral zone.

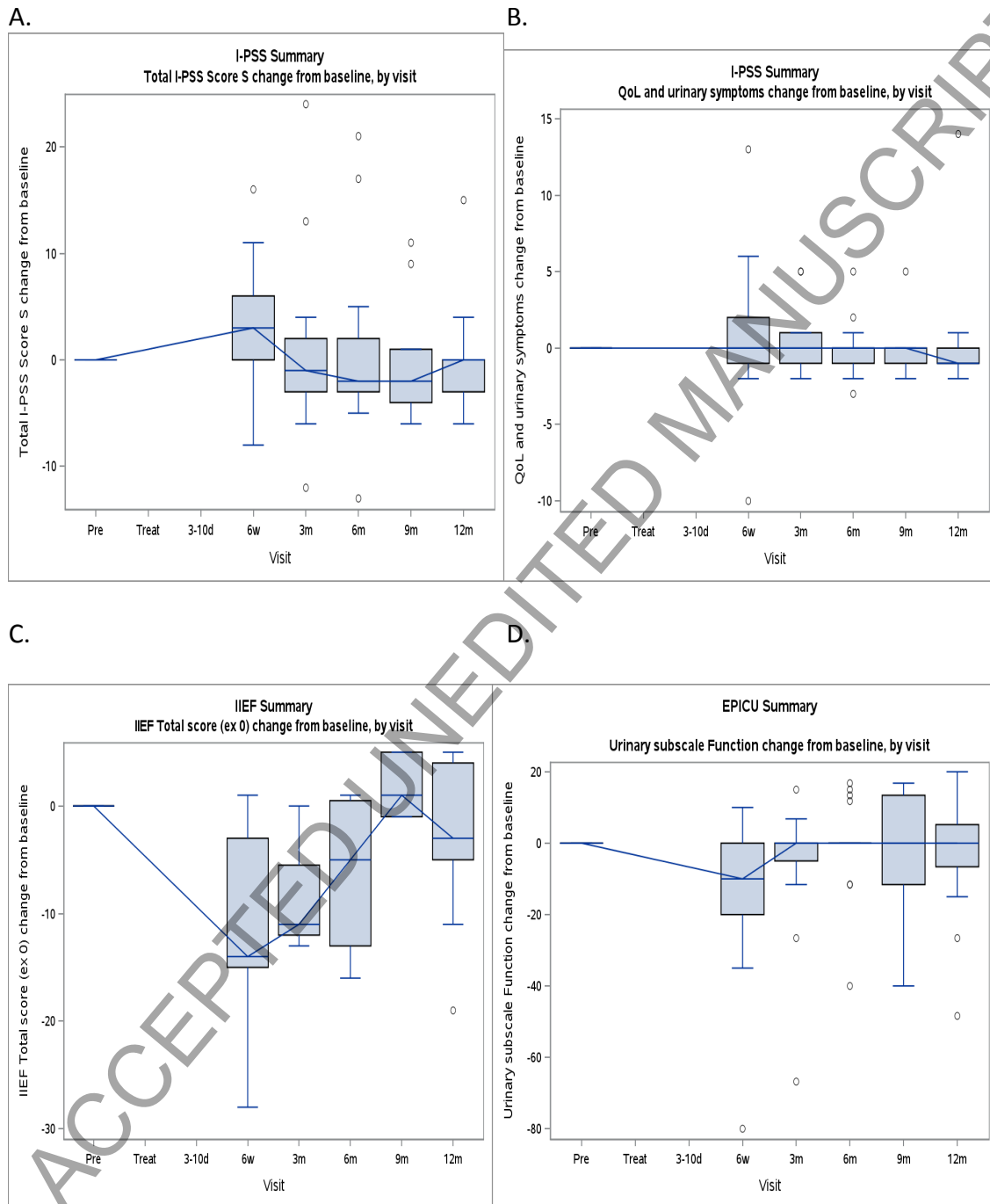
- A. T2WI with segmented lesion (red line) augmented by pre planned margin (orange line).
- B. DCE WI at matching level of A.
- C. Intraoperative Ultrasound with fused MRI-derived lesion with compensation of deformation induced by the endorectal probe. Circles 1, 2 and 3 represent treatment planning and coils to be inserted to perform complete ablation of cancer with a margin.
- D. mpMRI- DCEWI at 5 days post treatment showing necrosis in the location of the targeted cancer and living tissue around.



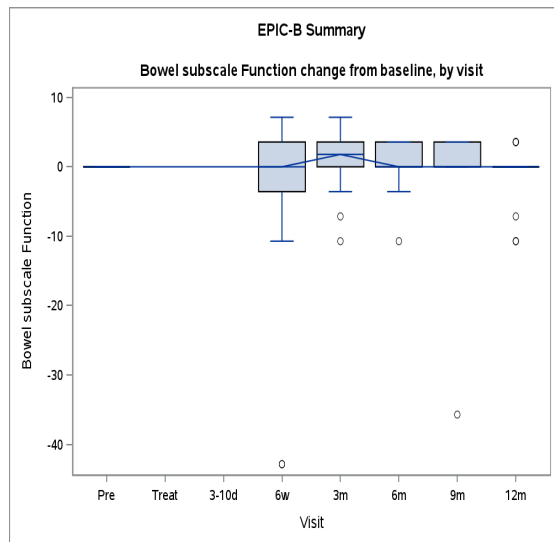
**Figure 4.** Example at 6 months follow up from treatment from enrolled patient. A. T2WI showing localised shrinkage in place of previous ablation B. Magnification X40 of biopsy core taken ablated area and surroundings. Lesion of coagulation necrosis on the right with sharp transition to healthy tissue showing persistent staining in nuclei (on the left).



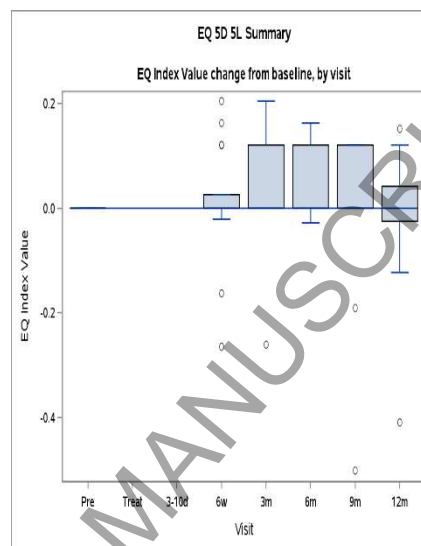
**Figure 5. Functional outcomes after focal therapy using bipolar radiofrequency with a coil design described as changes to baseline. Box and whiskers plots indicate median with IQR (boxes), and range (whiskers). Dots are outlier.**



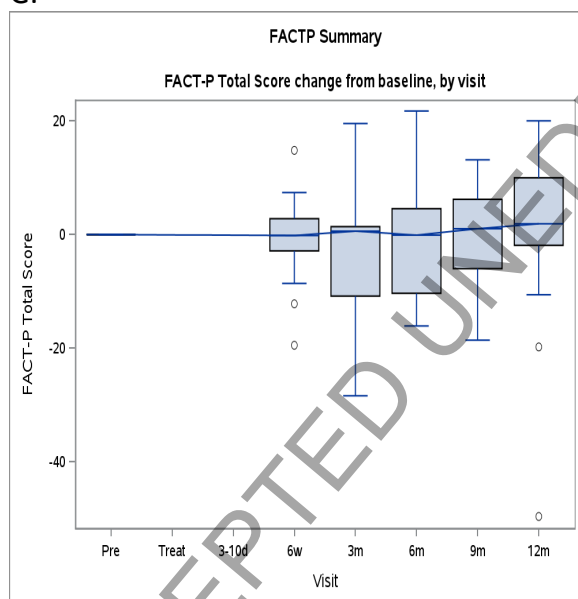
E.



F.



G.



A. Total I-PSS Score: ANOVA  $p=0.01707$ , the median (IQR) change from baseline to 12 months was 0 (-3 to 0) ( $n=17$ ).

B. IPSS QoL: ANOVA  $p=0.13067$ , the median (IQR) change from baseline to 12 months was -1 (-1 to 0) ( $n=20$ )

C. IIEF Total score: ANOVA  $p=0.10376$ , the median (IQR) change from baseline to 12 months was -3 (-5 to 4) ( $n=20$ )

D. EPIC Urinary domain: ANOVA  $p=0.01303$ , the median (IQR) change from baseline to 12 months was 0(-6.6 to 5.2) ( $n=19$ )

E. EPIC Bowel Domain: ANOVA  $p=0.12909$ , the median (IQR) change from baseline to 12 months was 0.89 (-1.79 to 1.79) ( $n=14$ )

F. EQ 5D 5L: ANOVA  $p=0.28635$ , the median (IQR) change from baseline to 12 months was 0 (-0.02 to 0.04)

(n=19)

G. FACT P: ANOVA  $p=0.69594$ , the median (IQR) change from baseline to 12 months was 1.9 (-1.9 to 10) (n=16)

ANOVA was calculated using the nonparametric analysis of longitudinal data method described in Brunner et al. (2002) with SAS version 9.4

Brunner, E., Domhof, S, & Langer, F. (2002). *Nonparametric analysis of longitudinal data in factorial experiments* / E. Brunner, S. Domhof and F. Langer. (Expanded and translated ed., Wiley series in probability and statistics). New York: J. Wiley.

ACCEPTED UNEDITED MANUSCRIPT