

# **Brown-Vialetto-Van Laere and Fazio-Londe Syndromes: *SLC52A3* mutations with puzzling phenotypes and inheritance**

Santhalingam Gayathri <sup>a</sup>, Vykuntaraju K Gowda <sup>b</sup>, Tamilarasan Udhayabanu <sup>a</sup>, Benjamin O'Callaghan <sup>c</sup>, Stephanie Efthymiou <sup>c</sup>, Perumal Varalakshmi <sup>a</sup>, Naveen Benakappa <sup>b</sup>, Henry Houlden <sup>c</sup>, Balasubramaniam Ashokkumar <sup>a\*</sup>

<sup>a</sup> School of Biotechnology, Madurai Kamaraj University, Madurai - 625021, India

<sup>b</sup> Department of Pediatric Neurology, Indira Gandhi Institute of Child Health, Bangalore, India

<sup>c</sup> Department of Neuromuscular Diseases, Institute of Neurology, University College London, London, WC1N 3BG, UK

**Running title: *SLC52A3* mutations with puzzling phenotypes**

**Total word count: 3370**

**\*Balasubramaniam Ashokkumar**

Department of Genetic Engineering, School of Biotechnology,  
Madurai Kamaraj University, Madurai - 625 021, India.

TEL: (91) 452-2459115

E.mail: rbashokkumar@yahoo.com

This article has been accepted for publication and undergone full peer review but has not been through the copyediting, typesetting, pagination and proofreading process, which may lead to differences between this version and the [Version of Record](#). Please cite this article as [doi: 10.1111/ENE.14682](https://doi.org/10.1111/ENE.14682)

This article is protected by copyright. All rights reserved

MR. BENJAMIN JOHN O'CALLAGHAN (Orcid ID : 0000-0002-1323-6843)

DR. BALASUBRAMANIAM ASHOKKUMAR (Orcid ID : 0000-0003-2213-5400)

Article type : Original Article

**Brown-Vialetto-Van Laere and Fazio-Londe Syndromes:  
*SLC52A3* mutations with puzzling phenotypes and inheritance**

Santhalingam Gayathri <sup>a</sup>, Vykuntaraju K Gowda <sup>b</sup>, Tamilarasan Udhayabanu <sup>a</sup>, Benjamin O'Callaghan <sup>c</sup>, Stephanie Efthymiou <sup>c</sup>, Perumal Varalakshmi <sup>a</sup>, Naveen Benakappa <sup>b</sup>, Henry Houlden <sup>c</sup>, Balasubramaniam Ashokkumar <sup>a\*</sup>

<sup>a</sup> School of Biotechnology, Madurai Kamaraj University, Madurai - 625021, India

<sup>b</sup> Department of Pediatric Neurology, Indira Gandhi Institute of Child Health, Bangalore,  
India

<sup>c</sup> Department of Neuromuscular Diseases, Institute of Neurology, University College London,  
London, WC1N 3BG, UK

**Running title: *SLC52A3* mutations with puzzling phenotypes**

**Total word count: 3370**

**\*Balasubramaniam Ashokkumar**

Department of Genetic Engineering, School of Biotechnology,  
Madurai Kamaraj University, Madurai - 625 021, India.

TEL: (91) 452-2459115

E.mail: rbashokkumar@yahoo.com

## Abstract

**Background:** Brown-Vialetto-Van Laere Syndrome (BVVLS) and Fazio-Londe Disease (FLD) are rare neurological disorders presenting with pontobulbar palsy, muscle weakness, and respiratory insufficiency. Mutations in *SLC52A2* (hRFVT-2) or *SLC52A3* (hRFVT-3) genes can be responsible for these disorders with an autosomal recessive pattern of inheritance. The aim of this study is to screen for mutations in *SLC52A2* and *SLC52A3* among Indian families diagnosed with BVVLS and FLD.

**Methods:** *SLC52A2* and *SLC52A3* were screened in one FLD and three BVVLS patients by exon-specific amplification using PCR and sequencing. *In silico* predictions using bioinformatics tools and confocal imaging using HEK-293 cells were performed to determine the functional impact of identified mutations.

**Results:** Genetic analysis of a mother and son with BVVLS was identified with a novel homozygous mutation c.710C>T (p.Ala237Val) in *SLC52A3*. This variant was found to have autosomal pseudo-dominant pattern of inheritance, which was neither listed in the Exome variant server or in 1000 genomes database. *In silico* analysis and confocal imaging of the p.Ala237Val variant showed higher degree of disorderness in hRFVT3 that could affect riboflavin transport. Furthermore, a common homozygous mutation c.62A>G (p.Asn21Ser) was identified in other BVVLS and FLD patients. Despite having different clinical phenotypes, both BVVLS and FLD disorder can be attributed to this mutation.

**Conclusion:** A rare and peculiar pattern of autosomal pseudo-dominant inheritance is observed for the first time in two genetically related BVVLS cases with Indian origin and a common mutation c.62A>G (p.Asn21Ser) in *SLC52A3* can be responsible for both BVVLS and FLD with variable phenotypes.

**Key words:** Brown-Vialetto-Van Laere syndrome, Fazio-Londe disease, riboflavin transporter deficiency, *SLC52A2*, *SLC52A3*, Autosomal pseudo-dominance.

## Short Abstract

- Novel missense mutation c.710C>T (p.A237V) in hRFVT-3 is identified in BVVLS cases of Indian ethnicity for the first time.
- Pseudo-dominance pattern of inheritance is identified for the first time among BVVLS cases.
- Confocal cell imaging of the variant p.A237V showed abrogated expression on the cell surface compared to the wild-type.



- Though BVVLS and FLD share overlapping phenotypes, a common mutation c.62A>G (p.Asn21Ser) identified in both cases suggesting that they can be caused by the same hRFVT3 mutation.

## Introduction

Brown-Vialetto-Van Laere syndrome (BVVLS) is an entity marked by the variable involvement of cranial nerve motor nuclei 7<sup>th</sup> to 12<sup>th</sup> and rarely 3<sup>rd</sup>, 5<sup>th</sup> and 6<sup>th</sup> motor nuclei [1,2]. Clinical features of the BVVLS generally include pontobulbar palsy, muscle weakness, progressive sensorineural deafness and respiratory insufficiency. BVVLS is shown to be genetically heterogeneous, as it occurs in an autosomal recessive, autosomal dominant and even X-linked inheritance pattern [3]. Mutations in the riboflavin transporter genes *SLC52A2* (hRFVT-2), or *SLC52A3* (hRFVT-3) are known to be associated with this intriguing disorder [3,4], which are referred to as riboflavin transporter deficiency (RTD) type-2 (OMIM#614707) and type-3 (OMIM#211530), respectively. The onset of BVVLS is generally during infancy or early childhood, however individuals with late onset (in the third decade) have been documented only to carry RTD-3 mutations. These two transporters along with *SLC52A1* (hRFVT-1) are distributed in the human intestine and facilitate the uptake of riboflavin available from external sources such as diet and microbial sources. Of these, hRFVT-3 is highly expressed in the intestine compared to other RFVTs under normal physiological condition. It plays a crucial role in the intestinal riboflavin absorption, whereas the expression of hRFVT-2 is high in the brain and appears to be involved mainly in the riboflavin homeostasis of the nervous system [5]. Fazio-Londe disease (FLD; OMIM#211500), is another rare neurological disorder resembling BVVLS but without sensorineural deafness, also associated with riboflavin deficiency [6]. Global incidence of BVVLS is quite low and there have been 110 cases reported worldwide by 2019 [7] with female to male ratio of approximately 3:1.

Riboflavin (vitamin B2) and its active coenzyme forms such as flavin adenine dinucleotide (FAD) and flavin mononucleotide (FMN) play a vital role in many metabolic pathways such as amino acids, fatty acids and purines, and various oxidation-reduction reactions that are essential for normal cellular growth and development. Metabolic studies of BVVLS patients had shown a significant reduction of blood plasma levels of riboflavin, FAD and FMN, which is not due to nutritional riboflavin deficiency. High-dose supplementation of riboflavin has been shown to improve the clinical signs and biochemical abnormalities dramatically in genetically confirmed neuronopathies associated with riboflavin transporter deficiency [8]. Interestingly, the response of patients to riboflavin supplementation was also highly variable and some patients show no improvement on high doses [9]. Since the effect of

genetic mutations in the functionality of riboflavin transporters is poorly understood, the impact of riboflavin therapy remains unclear.

To date, several disease-associated mutations in *SLC52A2* and *SLC52A3* have been described in BVVLS patients originating from various ethnic groups. Herein, we present an unusual case of a boy with his mother and two unrelated patients of Indian ethnicity, who presented with complex phenotypes characterized by progressive muscle weakness, pontobulbar palsy, sensorineural deafness and respiratory insufficiency. In the unusual case of the boy, we report a 'pseudo-dominant inheritance', with extensive consanguinity, where the mother is affected while the father is a clinically healthy carrier. The affected individuals are found to carry mutations in *SLC52A3*, which are functionally defective in riboflavin transport function after which *in silico* predictions and membranous expression analysis were carried out *in vitro*.

## **Methods**

### **Standard Protocol Approvals, Patient Enrolment and Patient Consents**

The study was approved and performed under the ethical guidelines issued by the Institutional Ethical Committee of Madurai Kamaraj University, Madurai, India. The patients with classical symptoms of BVVLS were enrolled at Indira Gandhi Institute of Child Health, Bangalore and the peripheral blood samples were obtained from the probands and their family members after signing an informed consent. Clinical examinations were performed according to the Hospital's Ethical Committee. Detailed clinical records of medical history and scientific examinations were taken and kept with the hospital.

### **Genotyping**

Genomic DNA was isolated from the peripheral blood samples using HiPurA blood genomic DNA isolation kit (HiMedia, India). Using genomic DNA as template and exon specific primers, all eight exons corresponding to *SLC52A2* and *SLC52A3* including intron-exon junctions were PCR amplified using previously optimized conditions [8]. The amplicons were bidirectionally sequenced (AgriGenome, India) and then genotyped by comparing with the DNA sequences of wild-type *SLC52A2* (Gene ID 79581) and *SLC52A3* (Gene ID 113278).

### ***In silico* Analysis**

To determine the functional effect of the identified mutations in *SLC52A3*, *in silico* tools such as Mutation Taster, Predict SNP, SIFT, Polyphen, MAPP, SNAP and PANTHER [1,2] were used. The evolutionary conservation of the mutated amino acid residues of this variant was investigated by multiple sequence alignment using ClustalW2 program (EMBL, Cambridge, UK). RNAfold online server was used to predict the secondary structures of the mRNA and minimum free energies of the wild-type and the *SLC52A3* variant. Comparative amino acid analysis was performed for the human hRFVT-3 protein with its orthologs from human, mice, dog, cow, zebra fish, rhesus and cat (www.ebi.ac.uk; ClustalW analysis) to delineate the conserved nature of the mutations.

### **Generation of pEGFP-C3-*SLC52A3* Mutant Constructs**

To generate the mutant construct, site-directed mutagenesis was performed by *DpnI* method [8] using a pEGFP-C3-hRFVT-3 plasmid (generously gifted by Dr. Said HM from University of California, Irvine, USA). The mutagenesis primer sets used were: C710T forward 5'-TCCACTCCATCCGGCTGCGGAAGAGAATGA-3'; reverse 5'-TCATTCTCTCCCGCAGCCGGATGGAGTGGGA-3'. To ensure no other mutations were introduced, the wild-type and the mutant hRFVT-3 constructs generated were sequence verified.

### **Cell Culture, Transient Transfection and Confocal Imaging**

Human embryonic kidney cells (HEK-293) obtained from ATCC were maintained in DMEM supplemented with 10% FBS, glutamine (0.29 g/L), sodium bicarbonate (2.2 g/L), penicillin (100,000 U/L), and streptomycin (10 mg/L) at 37 °C in a 5% CO<sub>2</sub>-95% air atmosphere. HEK-293 cells were seeded onto poly-lysine coated 15 mm glass coverslips and transfected with wild-type and mutant constructs of *SLC52A3* using Lipofectamine 2000. Following 24 h of post transfection, cells were fixed with 4% w/v formaldehyde in phosphate buffered saline (PBS) before incubation in blocking and permeabilisation solution (BPS) consisting of 10% v/v donkey serum and 0.1% w/v triton-X-100 in PBS. Cells were then incubated with a primary antibody diluted in BPS targeting the endoplasmic reticulum (ER) marker binding immunoglobulin protein (BiP) (Abcam #ab21685; 1:500 dilution, 1h, RT) followed by Alexa Fluor 568 conjugated secondary antibody diluted in BPS (Thermofisher #A10042; 1:1000 dilution, 1h, RT). Coverslips were imaged using a Zeiss 710 LSM confocal microscope and a 63X oil objective. Fluorophores were excited using a 488 nm line from an argon ion laser, and emitted fluorescence was monitored with a 530 ± 20 nm band pass (GFP), while the red fluorescent protein [BiP (ER)] was excited with a HeNe ion laser at 543 nm.

Accepted Article

## Results

### Clinical Manifestations of the Patients

The present study reports on 4 patients of Indian origin, of which one was diagnosed with FLD (case 4), and the other 3 cases were diagnosed with BVVLS (Fig. 1a). Overall summary of clinical symptoms of the cases included in this study is outlined in Table 1. The age of onset of the disease among the cases was between 2-10 years. All the probands were born to consanguineously married couples. Other than case 4, all the others were reported to have hearing impairment, which manifested between the ages of 6 to 12 years. Muscle wasting and thinning was found as a common symptom in all the cases. Tone decrease in all four limbs was found in all three BVVLS cases, but not in the FLD one. Except case 2, the remaining cases were presented with tongue fasciculation. Difficulty in respiration was observed only in the FLD case at the age of 3. Neurological examination showed that all 4 cases suffer from symptoms of bulbar palsy, caused by impaired functioning of cranial nerve IX-XII. This is due to lower motor neuron and lower cranial nerve lesions leading to dysphagia, dysphonia, slurring of speech, difficulty in chewing and muscle weakness (lower, upper and neck muscles). The onset of muscle weakness started around the age of 10 to 11 years, except for case 2, where the onset of muscle weakness was at the age of 30. Other than the FLD case, all other cases have ataxia. Cases 3 and 4 have speech difficulties while cases 1, 2 and 4 have dysphonia. Brain neuroimaging (MRI) and Tandem Mass Spectrometry (TSM) was normal in all the cases. Riboflavin supplementation was recommended for all cases, and the dose varied depending on the response of the patients to the treatment. The recommended doses for daily twice were: for case 1: 300 mg, case 2: high dose of 400 mg, case 3: 200 mg, and case 4: 100 mg. All cases responded well with riboflavin supplementation and showed progressive improvement in their motor function skills and muscle strength.

### Genetic and functional analysis of *SLC52A3* mutations

Genetic screening by Sanger sequencing of exonic regions including intron-exon boundaries corresponding to *SLC52A3* gene revealed a novel missense mutation c.710C>T in exon-3 leading to an amino acid change from Alanine to Valine (p.Ala237Val) in both BVVLS cases 1 and 2. From the chromatograms (Fig. 1c), it is evident that both the patients (boy and mother) were homozygous for this mutation, while father was a heterozygous carrier, who is asymptomatic. The family pedigree is shown in Figure 1b. According to the transmembrane predictions, Alanine at amino acid position 237 is predicted to localize in the 6<sup>th</sup> transmembrane helix (TMH), which is highly conserved among all three riboflavin

transporters of the *SLC52A* family in humans and also extremely preserved across other species (Fig. 2a). This variant c.710C>T; p.Ala237Val has been identified for the first time in a BVVLS patient from Indian ethnicity and has not been reported earlier elsewhere. The identified mutation (c.710C>T; p.Ala237Val) was neither listed in the Exome Variant Server (<http://evs.gs.washington.edu/EVS/>) nor in the 1000 Genomes project database (<http://www.1000genomes.org/>) or in the dbSNP (build144), thus suggesting that it is extremely rare and highly likely the disease-causing variant for the BVVLS disease pathology in the patients.

Furthermore, impairment of the hRFVT-3 mutant p.Ala237Val was analysed *in silico* using different algorithms including Mutation Taster, Predict SNP, SIFT, Polyphen, MAPP, SNAP and PANTHER, which predicted the identified variant as ‘deleterious’ and ‘probably damaging’ (Fig. 2b-c). Subsequent analysis with RNAfold server revealed that the secondary structure of c.710C>T variant mRNA was misfolded and also the minimum free energy ( $\Delta G$ ) was less negative for the c.710C>T variant (-566.90 Kcal/mol) when compared to the minimum free energy for wild-type *SLC52A3* mRNA (-562.70 Kcal/mol). The change in the positional entropy was clearly depicted through the change in colour and structure of the computationally designed RNAs and the same was substantiated by Mountain plots that determine the distortions in the secondary structure of RNAs (Fig.3a and 3b).

Genetic testing in case 3 (BVVLS) and 4 (FLD) revealed a known missense mutation c.62A>G in exon-3 of *SLC52A3* in both cases, that leads to an amino acid change from Asparagine to Serine (p.Asn21Ser). From the chromatograms it was observed that the mutation was homozygous in both cases (Fig. 1c). The family pedigrees are shown in Figure 1b. Both the parents of the case 3 were asymptomatic heterozygous carriers of this mutation. For FLD case, the mother was heterozygous for this mutation, while the father was unavailable for genetic testing.

### **Imaging of hRFVT-3 mutant p.Ala237Val by Confocal Microscopy**

Membranous expression studies were performed on HEK-293 cells transiently transfected with wild-type hRFVT3-GFP and variant Ala237Val-hRFVT3-GFP by confocal imaging 24 h post transfection. The results of confocal microscopy revealed that the cells transfected with wild-type constructs (WT-hRFVT3-GFP) showed higher expression in the cell surface uniformly whereas the expression of mutant Ala237Val-hRFVT3-GFP displayed a varied phenotype. Few of the cells showed expression at the cell surface, while others showed

diminished and abrogated expression on the cell surface (Fig. 4). These observations clearly indicate impairment in cell surface expression of mutant hRFVT-3 protein.

## Discussion

BVVLS and FLD are rare, clinically overlapping and genetically heterogeneous motor neuron disorders, which have been diagnosed with a great spectrum of pathogenic mutations in the *SLC52A2* and *SLC52A3* genes in at least 110 patients [7]. BVVLS is generally characterized by sensorineural deafness, respiratory difficulty, and pontobulbar palsy and muscle weakness due to the involvement of cranial nerves VII, IX and XII. Phenotypically, hearing loss and muscle weakness are the most common presenting symptoms at onset in BVVLS cases harbouring mutations in either *SLC52A2* or *SLC52A3*. The most frequent phenotypes associated with *SLC52A2* mutations include ataxia, optic atrophy, weakness in upper limb and neck and deafness [10], while pontobulbar palsy, sensorineural deafness, respiratory failure and generalised limb weakness are common phenotypes among patients with *SLC52A3* mutations. FLD is phenotypically similar except the deafness, which is absent here. Recently, BVVLS and FLD have been grouped as Riboflavin Transporter Deficiencies (RTDs)[7]. FLD is mostly caused by mutations in *SLC52A3* and no mutations in *SLC52A2* or *SLC52A1* have been so far diagnosed among FLD patients. To date, there are 42 mutations reported in *SLC52A3* causing BVVLS or FLD [11], 24 mutations in *SLC52A2* causing BVVLS and 3 mutations in *SLC52A2* that cause spinocerebellar ataxia with blindness and deafness type-2 (SCABD2) [7].

The present study investigated the clinical presentations and the associated disease-causing mutations in *SLC52A2* and *SLC52A3* from a boy and his mother, as well as two other unrelated cases of Indian origin. Albeit, most of the clinical observations are compatible with BVVLS and FLD, noticeable differences were observed in some clinical findings, their age of onset and disease progression, even within the pedigree. Both patients 1 (boy) and 2 (mother) were born to consanguineous marriages. The mutational analysis identified a novel homozygous variant p.Ala237Val in *SLC52A3* in both of them, whereas father was an asymptomatic heterozygous carrier, thus the mode of inheritance appears to be autosomal dominant with reduced penetrance. Pseudo-dominance usually occurs in pedigree with multiple consanguineous marriages [12,13], which corroborates with the index case, wherein five consanguineous marriages are observed in this seven-generation pedigree, which could suggest possible pseudo-dominant inheritance. Though BVVLS has been described with variable inheritance [3], autosomal recessive is the most commonly observed inheritance



pattern, which is primarily considered as the foremost feature in the diagnosis of the disease. To our knowledge, this is the first report of pseudo-dominant inheritance in BVVLS with a novel homozygous variant in *SLC52A3* in a pedigree of Indian ethnicity.

Early-onset of the disease often has a rapidly progressive course with respiratory compromise leading to early death in many patients. In this study, patient 2 was diagnosed to have BVVLS only at the age of 36. She was found to have an onset of bulbar symptoms from the age of 7 and she is surviving till 36 years without any treatment. Both son and mother were found to have same clinical spectrum except tongue fasciculation, which is absent in the latter. Previously, it has been evidenced that there is a possibility of early onset and delayed progression of BVVLS, more precisely with genetic defects in *SLC52A3*. A 60-year-old Japanese woman was diagnosed with BVVLS having an onset of symptoms including sensorineural deafness, weakness and atrophy at the age of 15 [14]. Likewise, a 32-year-old woman was reported with BVVLS having the symptom bilateral hypoacusia at the age of 10 and survived till the age of 42 [15]. Further there are several reports suggesting that the survival time of patients may vary from years to decades [16]. Nevertheless, late-onset of BVVLS has also been reported in two women at the age of 34 years with disease associated mutations in *SLC52A3* [17,18]. These observations show that the onset, severity and the mortality rate of BVVL patients greatly varies from case to case.

To analyse the clinical pathogenicity of the identified mutation, computational profiling of mutation was carried out. The effect of the identified mutation was assessed by comparing various databases. mRNA stability assay with RNA fold server showed c.710C>T to be deleterious in nature that substantiated the genetic cause behind the occurrence of BVVLS in both patients. So far, several disease causing mutations has been identified and functionally characterized in the protein-coding sequences of *SLC52A3*. However the mutation (c.710C>T;p.Ala237Val) identified in this study is a novel disease-causing variant, found for the first time in patients of Indian ethnicity and also has not been reported previously elsewhere. *In silico* predictions strongly suggest that the identified variant is deleterious and probably impacting the functionality of the transporter. The effect of the identified mutation in the membranous expression of the hRFVT3 variant was analysed using cell imaging. hRFVT3 is predominantly expressed in the apical side of epithelial cells of enterocytes that mediate cellular uptake of riboflavin in the enterocytes exclusively. Based on membrane topology predictions using TMHMM, hRFVT3 is a transmembrane protein that contains 11 transmembrane helices (TMH) with NH<sub>2</sub> termini facing the cytoplasmic region and the COOH termini facing the extracellular region [19]. Accordingly, alanine at 237<sup>th</sup>

position appears to be located in the 6<sup>th</sup> domain of hRFVT3 transporter, hence the identified variant p.Ala237Val of hRFVT3 could alter the structure of the transporter possibly, which may affect the functional transport of riboflavin. Moreover, protein structure and folding studies have revealed that alanine is commonly the best helix-forming amino acid, whose side chain has straight-chain aliphatic regions, while valine is a  $\beta$ -branched and poor helix-forming amino acid [20]. Thus, it is quite obvious that substitution of alanine by valine could be disastrous. Previously, two other mutations such as Pro224Ile and Pro220His were reported in the same hRFVT3 domain, among which the former was considered to be a deleterious mutation and the patient died at an early age [3], while the latter is a rare disease associated polymorphism [16]. In both cases, neither live cell imaging nor functionality studies were performed. The results of cell imaging in the present investigation strongly suggest that the identified mutation affects the expression of the hRFVT3 in the cell membrane.

RTD patients are usually being treated with riboflavin supplements. Nearly 70% of the patients treated with riboflavin supplement showed an improvement in muscle strength and motor abilities [7]. To date, no death has been reported in patients treated with riboflavin [9]. However, deaths have been reported in patients who discontinued riboflavin supplementation during their treatment and also in the patients who were supplemented with riboflavin in the later days after onset of disease [21,22]. RTD patients are usually treated with riboflavin supplements ranging between 10-80 mg/kg/day [7]. In this series all the patients were treated with oral riboflavin supplementation (100 mg to 400 mg/twice a day) and showed significant improvement in all clinical symptoms upon supplementation. However, the amount of riboflavin varies greatly depending upon the severity and the response of the patient.

Both BVVLS and FLD shows highly overlapping clinical symptoms with the lack of sensorineural deafness in FLD, which is the defining feature that distinguishes both BVVLS and FLD. Phenotypic and genotypic correlations in patients harbouring p.Asn21Ser mutation from the previous reports is summarized in Table 2. Case 3 and case 4 clinically diagnosed as BVVLS and FLD respectively, share the same homozygous mutation (p.Asn21Ser). The same mutation in *SLC52A3* had been previously reported in two BVVLS and two FLD patients. In a BVVLS patient from Iran, this mutation was diagnosed in a compound heterozygous state for the first time (c.A62G/p.Asn21Ser and c.C935T/p.Ala312Val) [16]. Later, it was detected in a BVVLS patient from India, who harboured c.A62G/p.Asn21Ser mutation in *SLC52A3* at a homozygous state along with another homozygous mutation

c.C421A/p.Pro141Thr in *SLC52A2* [19]. However, the same mutation c.A62G was identified to cause FLD in a sibling from Indian ethnicity [23]. These observations clearly indicate that the prevalence of c.A62G mutation in *SLC52A3* is quite common among BVVLS and FLD cases of Indian ethnicity.

In summary, this is the first report to our knowledge about pseudo-dominant inheritance of BVVLS and the first report of the likely pathogenic variant p.Ala237Val in *SLC52A3*. Functional analysis by *in silico* predictions and cell imaging studies strongly demonstrated that the mutation p.Ala237Val is a highly deleterious one and strongly affects the functionality of hRFVT. This study seeks to provide evidence on pseudo-dominant patterns of inheritance in BVVLS with variable phenotypes. It is a rare condition, with challenging diagnosis, which entails a combination of thorough clinical examination and genetic testing to diagnose and manage BVVLS correctly. In addition, the common mutation p.Asn21Ser found in both BVVLS and FLD patients justifies that both syndromes share overlapping phenotypes and suggest that they can be caused by the same mutation in hRFVT3.

#### **Acknowledgements**

Authors gratefully acknowledge the Council of Scientific & Industrial Research (CSIR), India [No. 27(0351)/19/EMR-II] and the Indian Council of Medical Research (ICMR), India [INDO/ FRC/452/ (Y-83)/ 2016-17/IHD] for the International Fellowship to BA. We also thank DST-PURSE, UGC-UPE and UGC-SAP programs of Madurai Kamaraj University for their infrastructure and other facilities.

#### **Data availability statement**

The data that support the findings of this study are available on request from the corresponding author. The data are not publicly available due to privacy or ethical restrictions.

#### **References:**

1. Davenport RJ, Mumford CJ. The Brown-Vialetto-van Laere syndrome: a case report and literature review. *Eur J Neurol* 1994; **1(1)**: 51-4.
2. Mégarbané A, Desguerres I, Rizkallah E, *et al.* Brown-Vialetto-van Laere syndrome in a large inbred Lebanese family: Confirmation of autosomal recessive inheritance? *Am J Med Genet* 2000; **92(2)**: 117-21.

- Accepted Article
- Green P, Wiseman M, Crow YJ, *et al.* Brown-Vialetto-Van Laere syndrome, a pontobulbar palsy with deafness, is caused by mutations in c20orf54. *Am J Hum Genet* 2010; **86(3)**: 485-9.
  - Johnson JO, Gibbs JR, Van Maldergem L, Houlden H, Singleton AB. Exome sequencing in Brown-Vialetto-van Laere syndrome. *Am J Hum Genet* 2010; **87(4)**: 567-9.
  - Yao Y, Yonezawa A, Yoshimatsu H, Masuda S, Katsura T, Inui K. Identification and comparative functional characterization of a new human riboflavin transporter hRFT3 expressed in the brain. *J Nutr* 2010; **140**: 1220-1226.
  - Sathasivam S. Brown-Vialetto-Van Laere syndrome. *Orphanet J Rare Dis* 2008; **3**: 9.
  - O'Callaghan B, Bosch A, Houlden H. An update on the genetics, clinical presentation and pathomechanisms of human riboflavin transporter deficiency. *J Inherit Metab Dis* 2019; **42(4)**: 598-607.
  - Bosch AM, Abeling NG, Ijlst L, *et al.* Brown-Vialetto-Van Laere and Fazio Londe syndrome is associated with a riboflavin transporter defect mimicking mild MADD: a new inborn error of metabolism with potential treatment. *J Inherit Metab Dis* 2011; **34(1)**: 159-64.
  - Jaeger B, Bosch AM. Clinical presentation and outcome of riboflavin transporter deficiency: mini review after five years of experience. *J Inherit Metab Dis* 2016; **39(4)**: 559-564.
  - Foley AR, Menezes MP, Pandraud A, Gonzalez MA, Al-Odaib A, Abrams AJ, Hughes I. Treatable childhood neuronopathy caused by mutations in riboflavin transporter RFVT2. *Brain* 2014; **137(1)**: 44-56.
  - Rabbani B, Bakhshandeh MK, Navaeifar MR, Abbaskhanian A, Soveizi M, Geravandpoor S, Mahdieh N. Brown-Vialetto-Van Laere syndrome and Fazio-Londe syndrome: A novel mutation and *in silico* analyses. *J Clin Neurosci* 2020; **72**: 342-349.
  - Naveed M, Al-Ali MT, Murthy SK, Al-Hajali S, Al-Khaja N, Deutsch S, Radhakrishna U. Ectrodactyly with aplasia of long bones (OMIM; 119100) in a large inbred Arab family with an apparent autosomal dominant inheritance and reduced penetrance: clinical and genetic analysis. *Am J Med Genet Part A* 2006; **140(13)**: 1440-1446.
  - Hornby SJ, Dandona L, Jones RB, Stewart H, Gilbert CE. The familial contribution to non-syndromic ocular coloboma in south India. *Br J Ophthalmol* 2003; **87(3)**: 336-340.
  - Nemoto H, Konno S, Nomoto N, Wakata N, Kurihara T. A case of Brown-Vialetto-van Laere (BVVL) syndrome in Japan. *Rinsho Shinkeigaku* 2005; **45(5)**: 357-61.

- Accepted Article
15. Sztajzel R, Kohler A, Reichart M, Djientcheu VP, Chofflon M, Magistris MR. Brown-Vialetto-Van Laere syndrome: a case with anti-ganglioside GM1 antibodies and literature review. *Revue Neurologique* 1998; **154(1)**: 51-54.
  16. Dezfouli MA, Yadegari, S Nafissi, S, Elahi E. Four novel C20orf54 mutations identified in Brown-Vialetto-Van Laere syndrome patients. *J Hum Genet* 2012; **57(9)**: 613-617.
  17. Bashford JA, Chowdhury FA, Shaw CE. Remarkable motor recovery after riboflavin therapy in adult-onset Brown-Vialetto-Van Laere syndrome. *Pract Neurol* 2017; **17(1)**: 53-56.
  18. Camargos S, Guerreiro R, Bras J, Mageste LS. Late-onset and acute presentation of Brown-Vialetto-Van Laere syndrome in a Brazilian family. *Neurol Genet* 2018; **4(1)**: E215.
  19. Udhayabanu T, Subramanian VS, Teafatiller T, *et al.* SLC52A2 [p. P141T] and SLC52A3 [p. N21S] causing Brown-Vialetto-Van Laere Syndrome in an Indian patient: First genetically proven case with mutations in two riboflavin transporters. *Clin Chim Acta* 2016; **462**: 210-4.
  20. Gregoret LM, Sauer RT. Tolerance of a protein helix to multiple alanine and valine substitutions. *Folding and Design* 1998; **3**: 119-126.
  21. Chaya S, Zampoli M, Gray D, Booth J, Riordan G, Nondo A, van der Westhuizen F. The first case of riboflavin transporter deficiency in sub-Saharan Africa. *Seminars in Pediatric Neurology* 2018; **26**: 10-14.
  22. Forman EB, Foley AR, & King MD. Dramatic improvement of a rare syndrome with high dose riboflavin treatment. *Pediatr Neurol* 2018; **86**: 77.
  23. Gowda VK, Udhayabanu T, Varalakshmi P, Srinivasan VM, Ashokkumar B. Fazio-Londe syndrome in siblings from India with different phenotypes. *Brain Dev* 2018; **40**: 582-586.

## Legends to Figures

**Fig. 1.** Clinical observations and genetic testing of BVVLS and FLD probands. a) Photographs of cases 1-4 showing facial muscle weakness. b) Pedigree of cases 1-4 showing the inheritance of disease across generations (filled circle and square represent affected proband and half-filled circle and square represent carriers), c) Chromatogram showing novel homozygous mutation c.710C>T (p.Ala237Val) in *SLC52A3* in two genetically related BVVLS patients (case 1 and 2) and homozygous mutation c.62A>G (p.Asn21Ser) in both BVVLS (case 3) and FLD (case 4) patients.

**Fig. 2.** *In silico* analysis of clinical mutations identified in the probands. a) Alignment by ClustalW demonstrates that Alanine at 237<sup>th</sup> position is highly conserved among the orthologs from other species. (b) Prediction of the effect of the mutation on the stability of hRFVT3 using Mutation Taster, (c) Predict SNP database and (d) Polyphen analysis.

**Fig. 3.** mRNA secondary structure prediction for *SLC52A3* mRNA using RNAfold server. Predictions according to positional entropy and its corresponding mountain plot for **a)** wild-type *SLC52A3* and **b)** variant *SLC52A3:c.710C>T*. Prediction is based on the sequence according to NCBI accession number NM\_033409.3.

**Fig. 4.** Cellular expression of hRFVT-3 mutant p.Ala237Val in HEK-293 cells by confocal microscopy. Wild-type constructs (WT-hRFVT3-GFP) showed higher expression in the cell surface uniformly whereas the expression of mutant c.Ala237Val-hRFVT3-GFP displayed a varied phenotype, with only few cells showing expression at the cell surface, while others showing a diminished and abrogated expression.

Table 1. Clinical findings of the patients enrolled in this study.

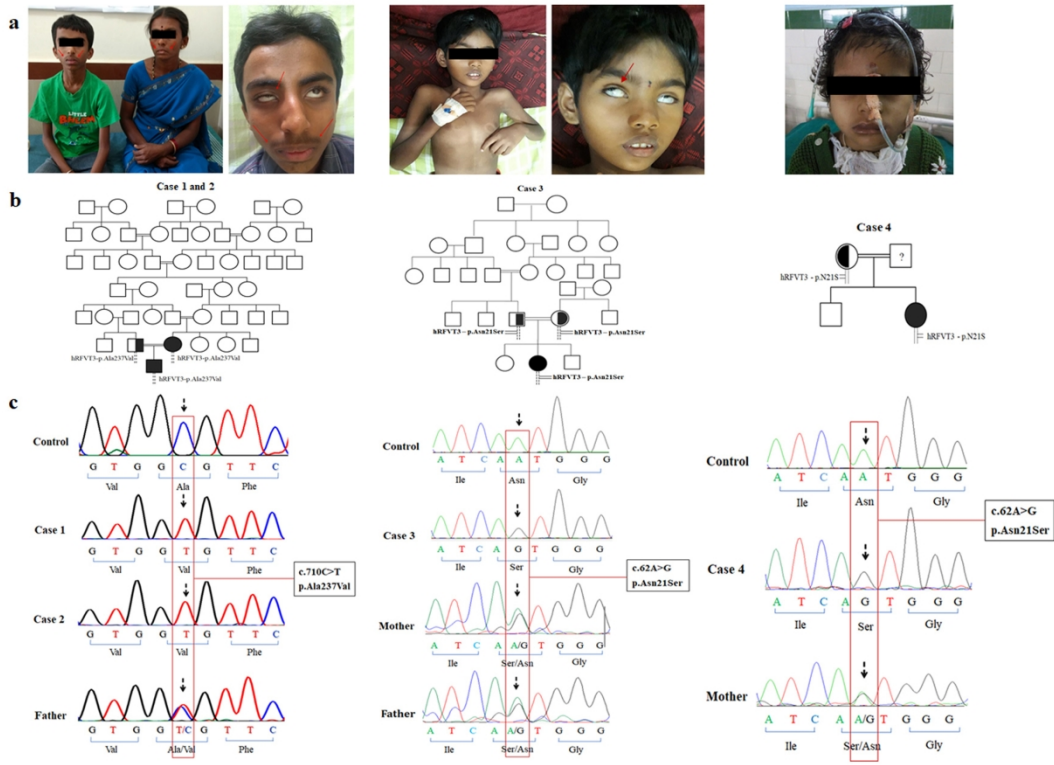
Clinical observations	Affected individuals			
	Case-1	Case-2	Case-3	Case-4
Sex	Male	Female	Female	Female
Age at examination	11 years	36 years	8 years	8 years
Age of onset	10 years	7 years	5 years	2 years
Consanguinity	3 <sup>rd</sup> degree	2 <sup>nd</sup> degree	3 <sup>rd</sup> degree	2 <sup>nd</sup> degree
Hearing loss	Yes	Yes	Yes	No
Facial palsy	Yes	Yes	Yes	Yes
Dysphagia	Yes	Yes	Yes	Yes
Tongue fasciculation	Yes	No	Yes	Yes
Neck muscle weakness	Yes	Yes	Yes	Yes
Difficulty in closing eyelids	Yes	Yes	No	Yes
Difficulty in speaking	No	No	Yes	Yes
Dysphonia	Yes	Yes	No	Yes
Upper limb muscle weakness	Yes	Yes	Yes	Yes
Lower limb weakness	Yes	Yes	Yes	Yes
Hypotonia	Yes	Yes	Yes	No
Muscle atrophy	Yes	Yes	Yes	Yes
Cranial nerve palsies	Yes	Yes	Yes	Yes
Ataxia	Yes	Yes	Yes	No
Respiratory insufficiency	No	No	No	Yes
Progression	Yes	Yes	Yes	Yes
Riboflavin supplementation	Yes	Yes	Yes	Yes
Alive/dead	Alive	Alive	Alive	Alive
Mutation identified	p.Ala237Val	p.Ala237Val	p.Asn21Ser	p.Asn21Ser

Table 2. Genotype-phenotype correlations in patients with c.A62G mutation in *SLC52A3*.

S.No	Genotype	Phenotype	Disease entity	Reference
1	c.62A>G/ c. 935C> T	Muscle wasting, Epilepsy, Dysphagia, Depression and Breathing difficulty.	BVVLS	Dezfouli <i>et al.</i> , 2012
2	c.62A>G / c.62A>G & c.421C>A/ c.421C>A * (* <i>SLC52A2</i> )	Bulbar palsy, Dysphagia, Nasal regurgitation, Deafness, Facial weakness, Thinning and Wasting of muscle	BVVLS	Udhayabanu <i>et al.</i> , 2016
3	c.62A>G / c.62A>G	Breathing difficulty, Facial weakness, Wasting of tongue muscle, Tongue fasciculation, Bulbar palsy and Deep tendon reflex.	FLD	Gowda <i>et al.</i> , 2018
4	c.62A>G / c.62A>G	Difficulty in closing eyelids, Bulbar palsy, Facial weakness, Wasting of tongue muscle, Tongue fasciculation and Deep tendon reflex.	FLD	Gowda <i>et al.</i> , 2018
5	c.62A>G / c.62A>G	Hearing loss, facial palsy, Bulbar palsy, Tongue fasciculation, Lower and upper limb weakness, Difficulty in closing eyelids and ataxia.	BVVL	This study
6	c.62A>G / c.62A>G	Facial palsy, cranial nerve palsy, Dysphagia, neck muscle weakness, upper and lower limb weakness and tongue fasciculation	FLD	This study



		with stridor		
--	--	--------------	--	--




ene\_14682\_f1.jpg

**p.Ala237Val**

**a**

Species common name			*		*	*			
Human	C	C	L	V	A	F	F	L	Q
Mice	C	C	L	V	A	F	F	V	Q
Dog	C	C	L	V	A	F	F	V	Q
Cow	C	C	L	T	A	F	F	L	Q
Zebra fish	C	C	L	A	A	F	F	A	Q
Rhesus	I	S	L	G	A	F	L	I	L
Cat	C	C	L	A	A	F	F	V	L

**b**



**mutation t@sting** [documentation](#)

**Prediction** **disease causing** Model: simple\_jaa, prob: 0.9999999844196 [\(explain\)](#)

Summary [hyperlink](#)

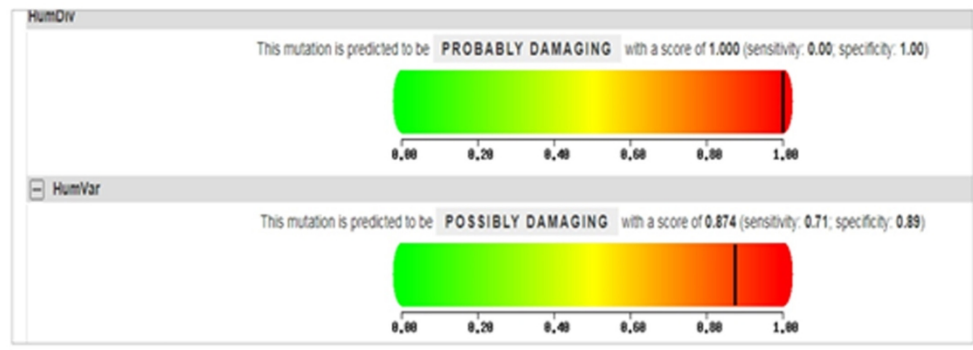
- amino acid sequence changed
- protein features (might be) affected
- splice site changes

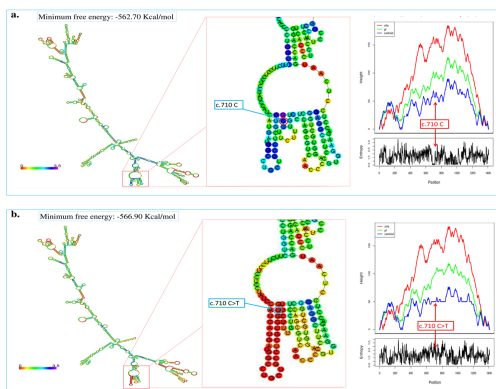
analysed issue	analysis result
name of alteration	no title
alteration (phys. location)	chr20:744505G>A <a href="#">show variant in all transcripts</a> <a href="#">IGV</a>
HGNC symbol	<a href="#">SLC52A3</a>
Ensembl transcript ID	<a href="#">ENST00000217254</a>
Genbank transcript ID	<a href="#">NM_033409</a>
UniProt peptide	<a href="#">Q2N040</a>
alteration type	single base exchange
alteration region	CDS
DNA changes	c.710C>T cDNA.952C>T g.4627C>T
AA changes	A237V Score: 64 <a href="#">(explain scores)</a>

**c**

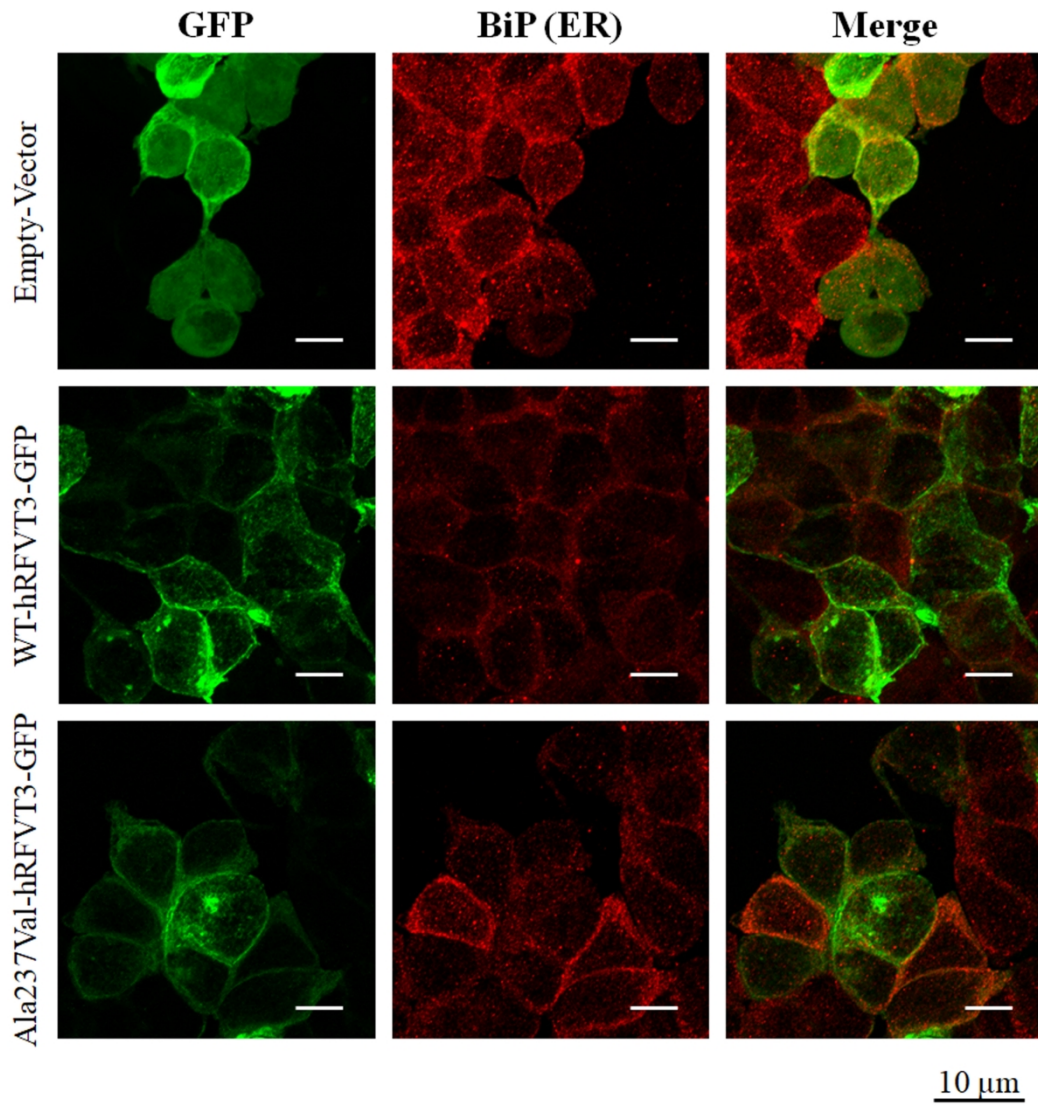
RESULTS		neutral	deleterious	XX % expected accuracy				Expand all annotations		
Annotation	Mutation	PredictSNP	MAPP	PhD-SNP	PolyPhen-1	PolyPhen-2	SIFT	SNAP	nsSNPAnalyzer	PANTHER
	A237V	72 %	78 %	73 %	67 %	55 %	79 %	62 %	-	71 %

**d**





ene\_14682\_f3.jpg



ene\_14682\_f4.jpg



# THE IMPORTANCE OF GREY AND WHITE MATTER

In Multiple Sclerosis



Visit [GreyAndWhiteMS.com](https://www.GreyAndWhiteMS.com) for more information.