



UNIVERSITY
OF WOLLONGONG
AUSTRALIA

University of Wollongong
Research Online

Faculty of Science, Medicine and Health - Papers

Faculty of Science, Medicine and Health

2014

Severe, steroid-responsive, myositis mimicking necrotizing fasciitis following orthopedic surgery: a pyoderma variant with myonecrosis

Alistair Reid

University of Wollongong

Peter Stanley

St Vincent'S Hospital, Melbourne

Damien Grinsell

St Vincent'S Hospital, Melbourne

John R. Daffy

St Vincent'S Hospital, Melbourne

Publication Details

Reid, A. B., Stanley, P., Grinsell, D. & Daffy, J. (2014). Severe, steroid-responsive, myositis mimicking necrotizing fasciitis following orthopedic surgery: a pyoderma variant with myonecrosis. *Plastic and Reconstructive Surgery Global Open*, 2 (6), e175-1-e175-5.

Research Online is the open access institutional repository for the University of Wollongong. For further information contact the UOW Library:
research-pubs@uow.edu.au

Severe, steroid-responsive, myositis mimicking necrotizing fasciitis following orthopedic surgery: a pyoderma variant with myonecrosis

Abstract

Postoperative pyoderma gangrenosum is a rare neutrophilic dermatosis that may be confused for necrotizing fasciitis. The inflammatory response is triggered by the trauma of surgery and thus must be managed nonsurgically. Clinical and pathological findings in the 2 diseases can be identical, leading to misdiagnosis and massive surgical defects from the ensuing surgery. This report documents a severe case of postsurgical pyoderma following an elective rotator cuff repair presenting with myositis and myonecrosis. The patient was initially treated as having an infection, which resulted in multiple aggressive surgical debridements. Despite this, the patient continued to deteriorate and was in a critical and hemodynamically unstable condition. Following administration of high-dose intravenous corticosteroids, the patient made a dramatic recovery and went on to have internal fixation of the shoulder and closure of the wound with a combination of a free flap and a rotational flap. Extensive myositis, as seen in this case, has not been previously reported in postoperative pyoderma gangrenosum variants. Clinicians should be aware that the presence of myositis and myonecrosis should not preclude this diagnosis.

Disciplines

Medicine and Health Sciences | Social and Behavioral Sciences

Publication Details

Reid, A. B., Stanley, P., Grinsell, D. & Daffy, J. (2014). Severe, steroid-responsive, myositis mimicking necrotizing fasciitis following orthopedic surgery: a pyoderma variant with myonecrosis. *Plastic and Reconstructive Surgery Global Open*, 2 (6), e175-1-e175-5.

Severe, Steroid-responsive, Myositis Mimicking Necrotizing Fasciitis following Orthopedic Surgery: A Pyoderma Variant with Myonecrosis

Alistair B. Reid, FRACP*†
 Peter Stanley, FRACP‡
 Damien Grinsell, FRACCS§
 John R. Daffy, FRACP‡

Summary: Postoperative pyoderma gangrenosum is a rare neutrophilic dermatosis that may be confused for necrotizing fasciitis. The inflammatory response is triggered by the trauma of surgery and thus must be managed nonsurgically. Clinical and pathological findings in the 2 diseases can be identical, leading to misdiagnosis and massive surgical defects from the ensuing surgery. This report documents a severe case of postsurgical pyoderma following an elective rotator cuff repair presenting with myositis and myonecrosis. The patient was initially treated as having an infection, which resulted in multiple aggressive surgical debridements. Despite this, the patient continued to deteriorate and was in a critical and hemodynamically unstable condition. Following administration of high-dose intravenous corticosteroids, the patient made a dramatic recovery and went on to have internal fixation of the shoulder and closure of the wound with a combination of a free flap and a rotational flap. Extensive myositis, as seen in this case, has not been previously reported in postsurgical pyoderma gangrenosum variants. Clinicians should be aware that the presence of myositis and myonecrosis should not preclude this diagnosis. (*Plast Reconstr Surg Glob Open* 2014;2:e175; doi: 10.1097/GOX.000000000000124; Published online 24 June 2014.)

Necrotizing fasciitis, a known complication of elective surgery, is an infection characterized by tissue destruction and systemic toxicity with a high mortality that requires aggressive surgical management. By contrast, pyoderma gangrenosum

is a rare neutrophilic dermatosis that presents as an inflammatory and ulcerative disorder of the skin with a reported incidence of 0.63 cases per 100,000 person years.¹ Postoperative pyoderma is a very rare subset of this disorder where the inflammatory response is triggered by the trauma of surgery and thus must be managed nonsurgically. Clinical and pathological findings in the 2 diseases can be identical leading to misdiagnosis and massive surgical defects from the ensuing surgery.² This report documents a severe case of postsurgical pyoderma presenting with myositis and myonecrosis.

From the *Infectious Diseases Unit, Wollongong Hospital, NSW, Australia; †University of Wollongong, NSW, Australia; ‡Infectious Diseases Unit, St Vincent's Hospital Melbourne, VIC, Australia; and §Plastic Surgery Department, St Vincent's Hospital Melbourne, VIC, Australia.

Received for publication February 10, 2014; accepted April 29, 2014.

Copyright © 2014 The Authors. Published by Lippincott Williams & Wilkins on behalf of The American Society of Plastic Surgeons. *PRSGO* is a publication of the American Society of Plastic Surgeons. This is an open-access article distributed under the terms of the Creative Commons Attribution-NonCommercial-NoDerivatives 3.0 License, where it is permissible to download and share the work provided it is properly cited. The work cannot be changed in any way or used commercially.

DOI: 10.1097/GOX.000000000000124

CASE REPORT

We present the case of a 55-year-old right-handed man who underwent elective rotator cuff and Bankart repair to the left shoulder. He is a nonsmoker

Disclosure: The authors have no financial interest to declare in relation to the content of this article. The Article Processing Charge was paid for by the Wollongong Hospital research unit.

with no comorbidities and taking no medications before surgery. Ten days postoperatively, he presented with pus discharging from the surgical wound. He was not systemically unwell and had no pain or limitation of range of movement.

The patient underwent washout and debridement of the wound, leaving a 14 cm × 7 cm skin defect covered with a vacuum dressing. Flucloxacillin and gentamycin were started postoperatively. The patient returned to theater the following day for repeat shoulder washout despite being clinically well. There was no evidence of necrosis, and the joint appeared normal at both operations. Three days following admission, the patient was febrile to 39°C. Metronidazole and benzylpenicillin were added. On day 4, the patient's condition declined, and he was again febrile and underwent a third washout. Following surgery, he went into type 1 respiratory failure and required transfer to the critical care unit.

Microscopy and culture to this point were nondiagnostic. Computed tomographic scans performed on day 5 were suggestive of myositis with no gas seen and no collection. The patient's general condition declined with worsening renal function, fevers, and respiratory deterioration. Antibiotics were changed to ticarcillin/clavulanic acid and vancomycin on day 7. The patient was transferred to our tertiary center on day 12.

On arrival, the patient had a temperature of 39°C, pulse of 100 bpm, and blood pressure of 140/80. On examination, a red, edematous, tender arm was not-

ed with a 15 cm × 7 cm ulcer over the left shoulder. Tissue surrounding the ulcer was woody to touch. The C-reactive protein was 403, and the white cell count was 42,500/mm³. Magnetic resonance imaging showed features of a diffuse myositis, maximal within the deltoid, pectoralis major, coracobrachialis, and serratus anterior, with areas suggesting necrosis within the deltoid and coracobrachialis. The antibiotics were broadened to vancomycin, meropenem, and clindamycin.

The provisional diagnosis was an infective process, either necrotizing fasciitis or myositis, and thus, the patient underwent an extensive washout and radical debridement including pectoralis major, deltoid, serratus anterior, and coracobrachialis. Pathology of these specimens showed acute necrotizing myositis with a mixed inflammatory infiltrate and extensive necrosis and abscess formation. No organisms were isolated.

Postoperative magnetic resonance imaging showed progressive myositis within all rotator cuff muscles, biceps, triceps, and latissimus dorsi (Fig. 1). Despite extensive debridement and 8 operations over 17 days, broad-spectrum antibiotics, hyperbaric oxygen, and silver-coated vacuum dressings, the patient continued to deteriorate and developed hemodynamic instability. The patient was transferred to the intensive care unit for ventilation and inotrope support.

At this point, the diagnosis was not clear. No microorganisms had been identified, including on frozen sections sent during surgery. Rapidly advanc-

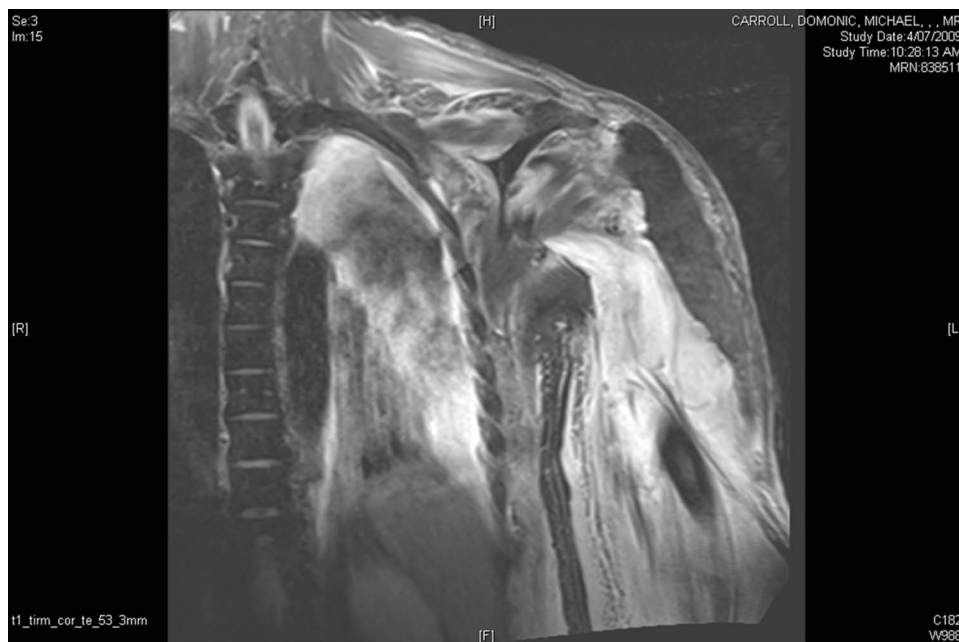

Fig. 1. Magnetic resonance imaging showing defect due to debridement of pectoralis major, deltoid, serratus anterior, and coracobrachialis with enhancement representing myositis within all rotator cuff muscles, biceps, triceps, and latissimus dorsi.

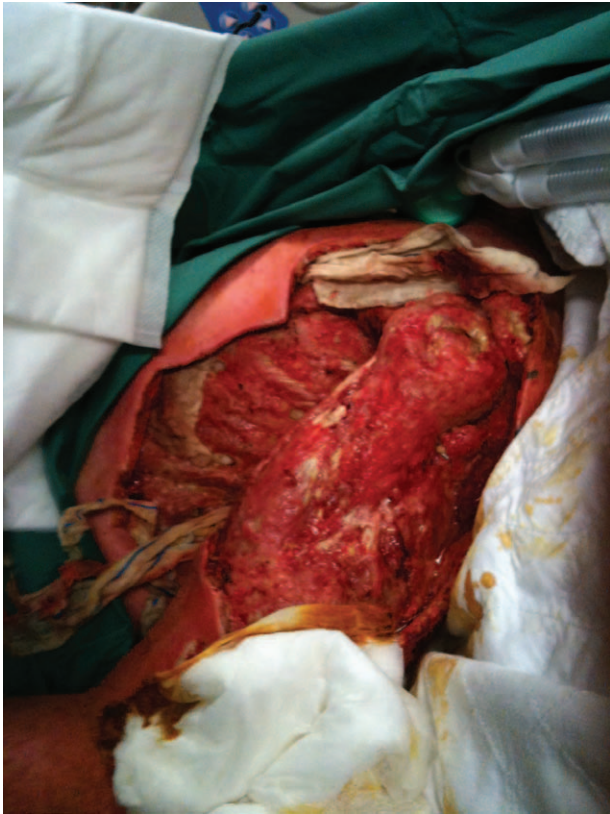


Fig. 2. Inflamed ulcer with erythematous edge and wet base before administration of steroids.

ing life-threatening systemic toxicity had ensued despite aggressive surgical and medical management. A diagnosis of variant postoperative pyoderma gangrenosum was considered, and the patient was started on hydrocortisone 200 mg IV 6 hourly. Initial improvement was seen within 12 hours, and at 36 hours, the patient had made a dramatic improvement, inotropes were ceased, and the patient had been extubated. Interestingly, the wound changed dramatically and actually looked worse taking on a gray color, which looked like dead tissue; however, it subsequently granulated and showed signs of healing. The patient made a full recovery including internal fixation of the shoulder and closure of the wound with a combination of a free flap and a rotational flap. Reparative surgery was performed under steroid cover (Figs. 2–4).

DISCUSSION

Pyoderma gangrenosum most commonly involves the skin and subcutaneous tissues and rarely involves the underlying muscle. Extensive myositis, as seen in this case, has not been previously reported in postoperative pyoderma gangrenosum variants.^{3–21} Postoperative pyoderma has occurred following a wide range of surgeries including breast, abdominal, or-

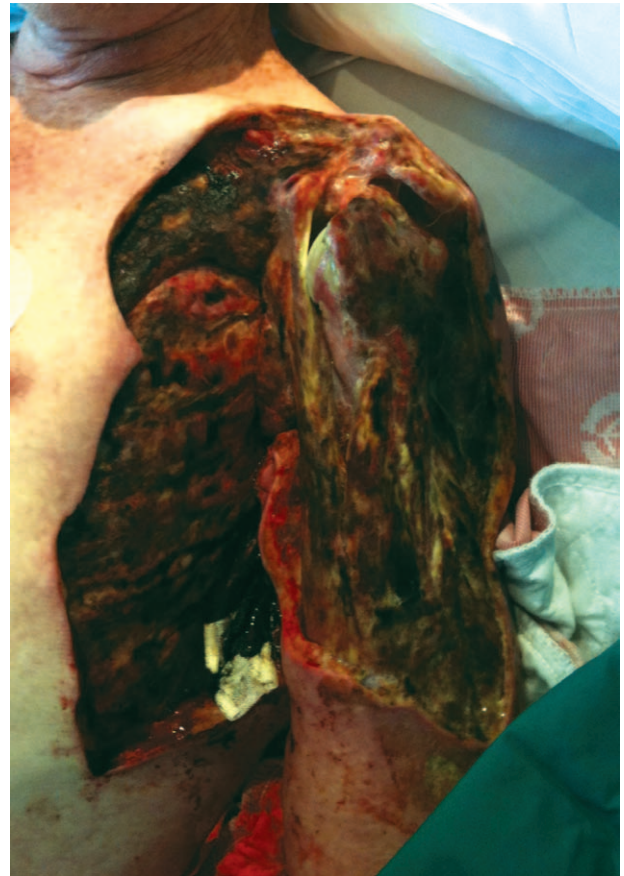


Fig. 3. A dry ulcer with no erythema of the surrounding tissues after administration of steroids.

thopedic, cutaneous, thyroid, ophthalmic surgery, and permanent pacemaker insertion. It is thought to be mediated by aberrant neutrophil tracking, and the cause is unknown.²² Clinical features include a latency of 6–14 days postoperatively, an inflamed ulcer with an undermined border, and a necrotic base.²³ The ulcer is usually well demarcated and may have surrounding erythematous haloes. New lesions may be found at sites of trauma away from the initial lesion. Diagnosis is largely based on clinical features. The failure to isolate pathogenic bacteria on repeated wound and tissue cultures and a failure to respond to broad-spectrum antibiotics would suggest the possibility of pyoderma gangrenosum with an ulcerating surgical wound. The very aggressive course with extensive involvement of muscle resulted in a delay in diagnosis in our case. The slow progression over several weeks and the absence of severe pain also suggested a noninfectious cause. The drastic response to corticosteroid confirmed the diagnosis of postoperative pyoderma gangrenosum variant.

Histopathology may not be helpful as the classic appearance is nonspecific and the necrotizing leukocytoclastic vasculitis with edema and massive

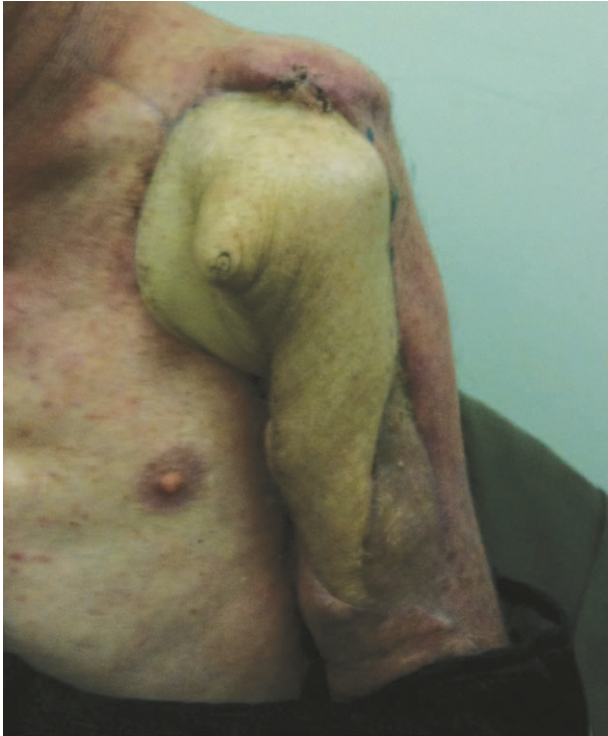

Fig 4. Image of the shoulder 3 months following resolution of disease and free flap coverage.

neutrophil infiltrate may be indistinguishable from infection. Engorgement and thrombosis of small- and medium-sized vessels with tissue necrosis, hemorrhage, and abscess formation may also be seen.²⁴ Clues to an infectious cause include rapid progression, pain out of proportion to clinical findings, and tissue changes to purple or purple-black.²⁵ In approximately 50% of cases, pyoderma gangrenosum is associated with underlying conditions including rheumatoid arthritis, inflammatory bowel disease, or hematological malignancy.²⁶ We made our diagnosis based on a lack of response to broad-spectrum antibiotics and radical surgical debridement, with multiple tissue biopsies being unrevealing for any sign of infection.

Treatment is largely empirical or based on small series or local experience. Immunosuppressive therapy is the mainstay primarily using corticosteroids or cyclosporine A.²³ A small randomized trial of infliximab in standard pyoderma showed benefit over placebo and may be useful in more difficult cases.²⁷

CONCLUSIONS

Postoperative pyoderma is a potentially devastating disease that should be considered in the differential diagnosis of postoperative wound infection. This case had many features of postoperative pyoderma gangrenosum, but extensive involve-

ment of muscle caused a delay in diagnosis. The presence of myositis and myonecrosis should not preclude the diagnosis of postoperative pyoderma gangrenosum.

Alistair B. Reid, FRACP

Infectious Diseases Department
Level 1
Lawson House
Wollongong Hospital
Crown Street
Wollongong
NSW 2500
Australia

E-mail: alistair.reid@sesiahs.health.nsw.gov.au

REFERENCES

1. Langan SM, Groves RW, Card TR, et al. Incidence, mortality, and disease associations of pyoderma gangrenosum in the United Kingdom: a retrospective cohort study. *J Invest Dermatol.* 2012;132:2166–2170.
2. Mahajan AL, Ajmal N, Barry J, et al. Could your case of necrotising fasciitis be pyoderma gangrenosum? *Br J Plast Surg.* 2005;58:409–412.
3. Marie I, Levesque H, Joly P, et al. Neutrophilic myositis as an extracutaneous manifestation of neutrophilic dermatosis. *J Am Acad Dermatol.* 2001;44:137–139.
4. Cullen TS. A progressively enlarging ulcer of the abdominal wall involving skin and fat, following drainage of an abdominal abscess apparently from appendiceal origin. *Surg Gynecol Obstet.* 1924;38:579–582.
5. Ferrandiz-Pulido C, Bartralot R, Fuente MJ, et al. Postoperative pyoderma gangrenosum: diagnostic value of 16s ribosomal RNA sequencing and review of the literature. *Clin Exp Dermatol.* 2009;34:598–602.
6. Kolios L, Hirche C, Ryssel H, et al. [Pyoderma gangraenosum as a major complication in breast reconstruction with free double-DIEP-flap]. *Handchir Mikročir Plast Chir.* 2012;44:89–92.
7. Iosifescu AG, Boianu CI, Comănescu CM, et al. Pyoderma gangrenosum—a postoperative “pseudo-infection”. *Chirurgia (Bucur).* 2012;107:119–121.
8. Wanich T, Swanson AN, Wyatt AJ, et al. Pyoderma gangrenosum following patellar tendon repair: a case report and review of the literature. *Am J Orthop (Belle Mead NJ).* 2012;41:E4–E9.
9. Al Ghazal P, Dissemond J. [Multilocular pyoderma gangrenosum after uterus resection]. *Chirurg* 2012;83:254–257.
10. Esteve-Martínez A, Coto-Segura P, Garcia-Rabasco A, et al. Pyoderma gangrenosum after thoracic surgery. *Ann Thorac Surg.* 2011;92:741.
11. Reddy R, Favreau T, Stokes T, et al. Pyoderma gangrenosum following breast reconstructive surgery: a case report of treatment with immunosuppression and adjunctive xenogeneic matrix scaffolds. *J Drugs Dermatol.* 2011;10:545–547.
12. de Thomasson E, Caux I. Pyoderma gangrenosum following an orthopedic surgical procedure. *Orthop Traumatol Surg Res.* 2010;96:600–602.
13. Campbell W, Baird E, Murtagh K, et al. Post-operative pyoderma gangrenosum in association with ileal carcinoid tumour. *Ulster Med J.* 2010;79:102–103.
14. Baldea A, Gamelli RL. Postoperative pyoderma gangrenosum after elective abdominoplasty: a case report and review of the literature. *J Burn Care Res.* 2010;31:959–963.

15. Attar S, Spanghel MJ, Casey WJ, et al. Pyoderma gangrenosum complicating bilateral total knee arthroplasty. *Orthopedics* 2010;33:441.
16. Strauss A, Storim J, Germer CT, et al. Pyoderma gangraenosum as rare complication of incisional hernia repair in a patient with Werlhof's disease. *Hernia* 2011;15:709–712.
17. Hawryluk EB, Penn SK, Wasko MC, et al. Treatment of postsurgical pyoderma gangrenosum with a high-potency topical steroid. *Ear Nose Throat J*. 2010;89:E5–E7.
18. Schoemann MB, Zenn MR. Pyoderma gangrenosum following free transverse rectus abdominis myocutaneous breast reconstruction: a case report. *Ann Plast Surg*. 2010;64:151–154.
19. Hornez E, Monchal T, Ottomani S, et al. [Pyoderma gangrenosum mimicking abdominal sepsis after colorectal surgery]. *J Chir (Paris)*. 2009;146:576–578.
20. Sebastian VA, Carroll BT, Jessen ME. Pyoderma gangrenosum associated with chronic idiopathic myelofibrosis after coronary artery bypass graft surgery. *Interact Cardiovasc Thorac Surg*. 2010;10:135–137.
21. Duncan A, Bharati A, Wu J, et al. Pyoderma gangrenosum following pacemaker insertion. *Clin Exp Dermatol*. 2009;34:444–445.
22. Wollina U. Pyoderma gangrenosum—a review. *Orphanet J Rare Dis*. 2007;2:19.
23. Schöfer H, Baur S. Successful treatment of postoperative pyoderma gangrenosum with cyclosporin. *J Eur Acad Dermatol Venereol*. 2002;16:148–151.
24. Ruocco E, Sangiuliano S, Gravina AG, et al. Pyoderma gangrenosum: an updated review. *J Eur Acad Dermatol Venereol*. 2009;23:1008–1017.
25. Barr KL, Chhatwal HK, Wesson SK, et al. Pyoderma gangrenosum masquerading as necrotizing fasciitis. *Am J Otolaryngol*. 2009;30:273–276.
26. Crowson AN, Mihm MC Jr, Magro C. Pyoderma gangrenosum: a review. *J Cutan Pathol*. 2003;30:97–107.
27. Brooklyn TN, Dunnill MG, Shetty A, et al. Infliximab for the treatment of pyoderma gangrenosum: a randomised, double blind, placebo controlled trial. *Gut* 2006;55:505–509.